



Received: 2016.02.01

Accepted: 2016.02.29

Published: 2016.11.04

**Authors' Contribution:**

- A** Study Design
- B** Data Collection
- C** Statistical Analysis
- D** Data Interpretation
- E** Manuscript Preparation
- F** Literature Search
- G** Funds Collection

## The Role of Computed Tomography in the Diagnostics of Diaphragmatic Injury After Blunt Thoraco-Abdominal Trauma

Agata Gmachowska<sup>1ABCDEF</sup>, Ryszard Pachol<sup>1,2ABCDEF</sup>, Agnieszka Anysz-Grodzicka<sup>1ABCDEF</sup>, Leopold Bakoń<sup>1,2BCDF</sup>, Maria Gorycka<sup>1,2BCDF</sup>, Wawrzyniec Jakuczun<sup>3BCDF</sup>, Waldemar Patkowski<sup>4ABDF</sup>

<sup>1</sup> Department of Radiology, Military Institute of Aviation Medicine, Warsaw, Poland

<sup>2</sup> 2<sup>nd</sup> Department of Clinical Radiology, Medical University of Warsaw, Poland

<sup>3</sup> Department of General and Thoracic Surgery, Medical University of Warsaw, Warsaw, Poland

<sup>4</sup> Department of General, Transplant and Liver Surgery, Medical University of Warsaw, Warsaw, Poland

**Author's address:** Agata Gmachowska, Department of Radiology, Military Institute of Aviation Medicine, Warsaw, Poland, e-mail: agmachowska@op.pl

**Background:**

Diaphragmatic injuries occur in 0.8-8% of patients with blunt trauma. The clinical diagnosis of diaphragmatic rupture is difficult and may be overshadowed by associated injuries.

Diaphragmatic rupture does not resolve spontaneously and may cause life-threatening complications.

The aim of this study was to present radiological findings in patients with diaphragmatic injury.

**Material/Methods:**

The analysis of computed tomography examinations performed between 2007 and 2012 revealed 200 patients after blunt thoraco-abdominal trauma. Diaphragmatic rupture was diagnosed in 13 patients. Twelve of these patients had suffered traumatic injuries and underwent a surgical procedure that confirmed the rupture of the diaphragm. Most of diaphragmatic ruptures were left-sided (10) while only 2 of them were right-sided. In addition to those 12 patients there, another patient was admitted to the emergency department with left-sided abdominal and chest pain. That patient had undergone a blunt thoracoabdominal trauma 5 years earlier and complained of recurring pain. During surgery there was only partial relaxation of the diaphragm, without rupture.

The most important signs of the diaphragmatic rupture in computed tomography include: segmental discontinuity of the diaphragm with herniation through the rupture, dependent viscera sign, collar sign and other signs (sinus cut-off sign, hump sign, band sign).

**Results:**

In our study blunt diaphragmatic rupture occurred in 6% of cases as confirmed intraoperatively.

In all patients, coronal and sagittal reformatted images showed herniation through the diaphragmatic rupture. In left-sided ruptures, herniation was accompanied by segmental discontinuity of the diaphragm and collar sign. In right-sided ruptures, predominance of hump sign and band sign was observed.

Other signs were less common.

**Conclusions:**

The knowledge of the CT findings suggesting diaphragmatic rupture improves the detection of injuries in thoraco-abdominal trauma patients.

**MeSH Keywords:**

Diaphragm • Hernia, Diaphragmatic, Traumatic • Wounds, Nonpenetrating

**PDF file:**

<http://www.polradiol.com/abstract/index/idArt/897866>

## Background

Diaphragmatic injuries are rare complications of high-energy multiorgan trauma. In most cases, they are observed in young males after motor vehicle accidents. They are also encountered in patients after falls from big heights. The incidence of diaphragmatic injuries in patients after blunt thoraco-abdominal trauma is estimated at 0.8 to 8% [1–8]. Blunt trauma leads to diaphragmatic injuries that are more extensive than those observed in the more common penetrating wounds such as gunshot or puncture wounds [1–5,8].

No cases of spontaneous healing of the diaphragm have been reported to date [1]. Early diagnosis of diaphragmatic injury is important due to the risk of potential complications such as strangulation and necrosis of displaced intestine loops (characterized by mortality rate of up to 66%), respiratory failure, pneumonia, pleural effusion and empyema, pericardial tamponade, and others [1,3,6].

The diagnosis of diaphragmatic injury may be difficult, both due to the non-specific clinical presentation and concomitant injuries of other organs, and to the difficulties in appropriate interpretation of imaging results. The preliminary diagnosis of post-traumatic diaphragm injury may be made on the basis of X-ray imaging that visualizes the displacement of abdominal organs into the thorax.

Computed tomography (TK) facilitates a more accurate assessment of post-traumatic lesions. It is highly sensitive and specific in the emergency diagnostics of diaphragmatic injuries. The appropriate interpretation of CT scans is based on the analysis of transverse cross-sections and reconstructed images (multiplanar reconstructions, volumetric 3D and maximum saturation images).

The available literature lists a number of symptoms of diaphragmatic injury as seen in CT scans, which have been classified by Desir and Ghaye [1] into four groups of direct symptoms, herniation-related symptoms, symptoms associated with the lack of separation between the thoracic and abdominal cavity, as well as uncertain symptoms. Symptoms from the first two of these groups appear to be of the highest importance.

Direct diaphragmatic symptoms include the segmental continuity defect, the dangling diaphragm sign, and complete lack of diaphragmatic visualization. Indirect symptoms related to the presence of hernia include the collar sign, the hump sign, and the band sign. They also include the dependent viscera sign and sinus cut-off sign. Indirect symptoms of diaphragmatic injury may also include elevation of and peripheral visualization of abdominal organs with relation to the diaphragm and the lungs. The third group includes the indirect symptoms resulting from the lack of separation between the abdominal and the thoracic cavity such as the presence of peritoneal fluid and abdominal cavity organs around the thoracic organs, pneumothorax and/or pneumoperitoneum, and hemothorax and/or hemoperitoneum). Also included in the classification are the uncertain symptoms including diaphragmatic thickening, reduced diaphragmatic support and fractured ribs.

The objective of the study was to present the usefulness of CT scans in the diagnostics of diaphragmatic injuries along with the description of individual symptoms.

## Material and Methods

Retrospective analysis was carried out on CT scans performed on two 16-slice devices (Lightspeed GE Medical Systems) between October 2007 and April 2012. In this period, a total of 200 scans were acquired in patients after blunt thoraco-abdominal trauma, mostly the victims of motor vehicle accidents. Diaphragmatic rupture was diagnosed in 13 patients. In 12 patients, diaphragmatic rupture was confirmed intraoperatively. Radiological symptoms of diaphragmatic injuries were analyzed on the basis of the list developed by Desir and Ghaye [1].

## Results

Diaphragmatic injury was confirmed intraoperatively in 12 out of 13 patients with preliminary diagnosis made on the basis of CT scans. This accounted for 6% of the total population of 200 patients examined for blunt thoraco-abdominal trauma. In 10 cases (83%), the rupture was observed within the left hemidome (83%) as opposed to 2 cases (17%) of ruptures within the right hemidome. In one case, the radiological diagnosis of diaphragmatic injury was not confirmed intraoperatively. The group of patients with diaphragmatic injury confirmed during the surgery consisted of 4 females and 8 males. The mean age was 36 years (22 to 56 years).

Most common concomitant injuries included fractures within the pelvic girdle (8/12), rib fractures (6/12), and intraperitoneal bleeding (8/12). Following concomitant injuries were observed within the thoracic cavity: pulmonary contusion (4/12), intrapleural bleeding (7/12), and post-traumatic thoracic aortic injury (3/12). Post-traumatic lesions within the central nervous system were observed in 2 patients (2/12). Two patients in the reported group died due to the trauma incurred.

Table 1 presents the radiological symptoms of diaphragmatic injuries analyzed on the basis of the list developed by Desir and Ghaye [1]. Included in parentheses are the percentage incidence rates of individual symptoms in the diaphragmatic injury cases confirmed in the course of the surgery.

Diaphragmatic continuity defects accompanied by hernias entrapping abdominal organs (Figure 1) were observed in all cases. Organ dislocation is explained by the difference in pressures within the thoracic and the abdominal cavity. It may occur either immediately after the trauma, or in the later course of the disorder.

The dangling diaphragm sign consists in the broken part of the diaphragm being folded, thickened, and hanging gravitationally [10]. In our study material, this sign was observed in 2 patients (Figure 2A, 2B). No cases of complete lack of diaphragmatic dome within the CT image were observed in either of the cases.

**Table 1.** Radiological signs of diaphragm injury.

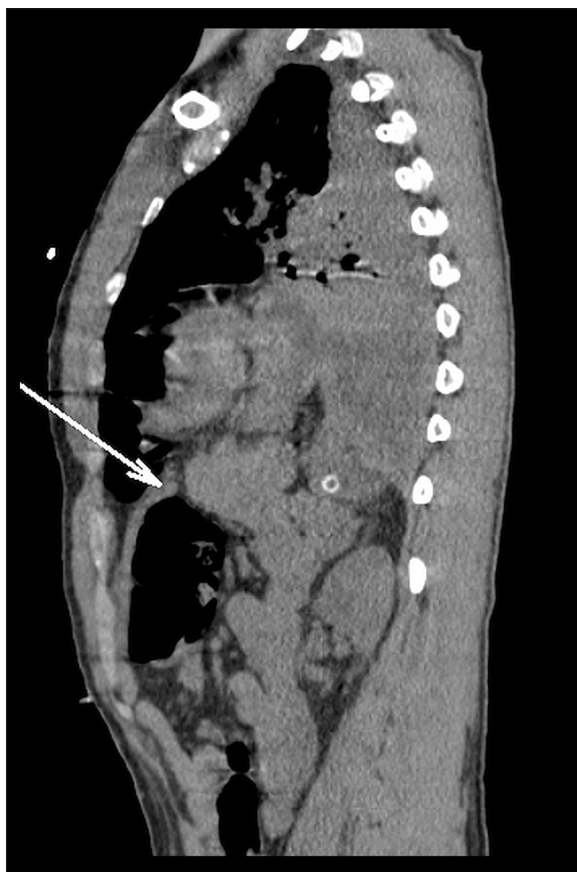List of diaphragmatic injury symptoms	Number of patients (%)	
Direct:		
1. Diaphragmatic outline continuity defect	10	(83)
2. Dangling diaphragm sign	2	(17)
3. Complete lack of diaphragmatic visualization	0	(0)
(0) Indirect hernia-related symptoms:		
1. Abdominal hernia through a diaphragmatic rupture	12	(100)
2. Collar sign	10	(83)
3. Hump sign	2	(17)
4. Band sign	2	(17)
5. Dependent viscera sign	10	(83)
6. Sinus cut-off [11]	6	(50)
7. Abdominal organs localized peripherally in relation to the diaphragm or the lungs	12	(100)
8. Elevation of abdominal organs	12	(100)
Indirect symptoms resulting from the lack of separation between the abdominal and the thoracic cavity:		
1. Peritoneal fluid surrounding thoracic organs	0	(0)
2. Abdominal organs surrounding the fluid or thoracic organs	0	(0)
3. Pneumothorax and/or pneumoperitoneum	3/0	(25/0)
4. Hemothorax and/or hemoperitoneum	7/8	(58/67)
Uncertain symptoms:		
1. Diaphragmatic thickening	4	(33)
2. Peridiaphragmatic extravasation of contrasted blood	0	(0)
3. Reduced diaphragmatic support	0	(0)
4. Fractured rib	6	(50)

The collar sign consists in segmental narrowing of the displaced organ at the site of crossing the damaged diaphragm (Figure 3). Most common is the "sand-clock"-like narrowing of stomach being displaced into the thoracic cavity. Also encountered are cases of dislocated intestinal loops, spleen, or omentum.

The dependent viscera sign is defined as the displaced abdominal organs being located adjacent to the posterior wall of the thoracic cavity (Figure 4). It is observed in patients with left-sided damage of the posterior part of the diaphragm and evident displacement of abdominal organs into the thoracic cavity. The symptom may also be visible in case of extensive injury of the right hemidiaphragm and hernia involving a large part of the liver of an intestine loop. The symptom is not observed in case of small hernias and injuries to the anterior part of the diaphragm including small hernias. It should be noted that the symptom may also be evident in case of large congenital hernias and therefore should not be considered the only exponent of the diagnosis of diaphragmatic injury. In case of large

quantities of fluid (blood) within the pleura, the displaced organs would not be located adjacent to the posterior thoracic wall. If the pleural fluid is visualized medially in relation to the displaced organs or is divided by these organs, the presentation is referred to as sinus cut-off sign [7].

In case of the injuries of the right hemidiaphragm it may be difficult to visualize the entire diaphragmatic continuity defect due to the fact that the tracking of this continuity is difficult as a result of the vicinity of the liver. Also the presence of abnormal solid lesions within the adjacent pulmonary parenchyma may cause difficulties in accurate tracking of diaphragmatic continuity. Correct diagnosis of diaphragmatic injury can be made easier by a part of the liver being embossed by the continuity defect. This is best visualized in multiplanar reconstructions and referred to as the hump sign. It is similar to the collar sign observed in the injuries of the left diaphragm. The term "band sign" refers to a thin band of poorer enhancement of liver parenchyma at the narrowing (reduced perfusion due to segmental impingement). Since the band sign may be misdiagnosed



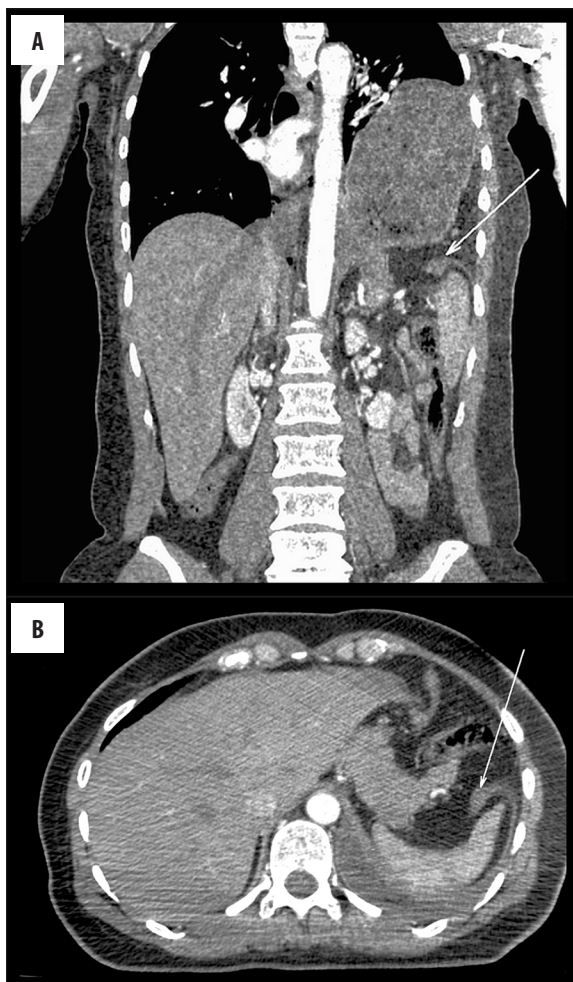
**Figure 1.** Left hemidiaphragmatic rupture in a 29-year-old man after a motor vehicle accident. Sagittal reformatted CT image shows segmental diaphragmatic defect with thickening of the diaphragm (arrow) and herniation. Left hemidiaphragmatic rupture was confirmed during surgery, with almost 75% of the hemidiaphragm being torn. Large intestine loops, stomach, part of the left lobe of the liver and omentum were herniated into the thorax. Coexisting post-traumatic changes included: subdural hematoma, fractures of the facial skeleton, instable fracture of the dens of C2, fractures of the pelvis.

as a result of motion artifacts [4], the diagnosis of right-sided hemidiaphragmatic injury should be confirmed by the coexistence of the hump sign. In our study material, the band sign and the hump sign were reported in two patients (Figure 5A, 5B).

In one case, the radiological diagnosis of diaphragmatic injury was not confirmed intraoperatively (Figure 6A, 6B). The diagnosis was made in a patient who had been admitted to the hospital due to strong pain within the left epigastrium and chest. According to medical history data, the culprit factor was the distant blunt thoraco-abdominal trauma and exercise of abdominal muscles. Diaphragmatic relaxation with no rupture was observed intraoperatively.

## Discussion

The diagnosis of post-traumatic injury of the diaphragm requires the knowledge of diaphragmatic structure and the most typical mechanism of diaphragmatic damage [1–5,8,9].

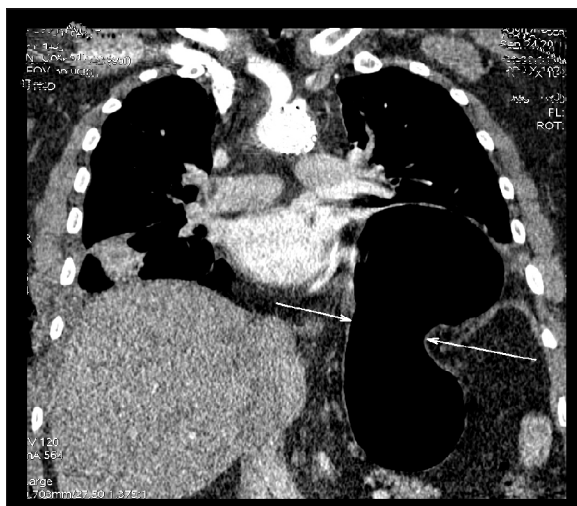

**Figure 2.** (A, B) A 40-year-old female who had been involved as a passenger in a motor vehicle accident. CT images show a dangling diaphragm sign and herniation of the stomach. Right-sided pneumothorax and fractured ribs and pelvis were also demonstrated (not shown). Left hemidiaphragmatic rupture was confirmed during surgery; the tear was about 12–15 cm long. Stomach and small intestine loops were herniated into the thorax.

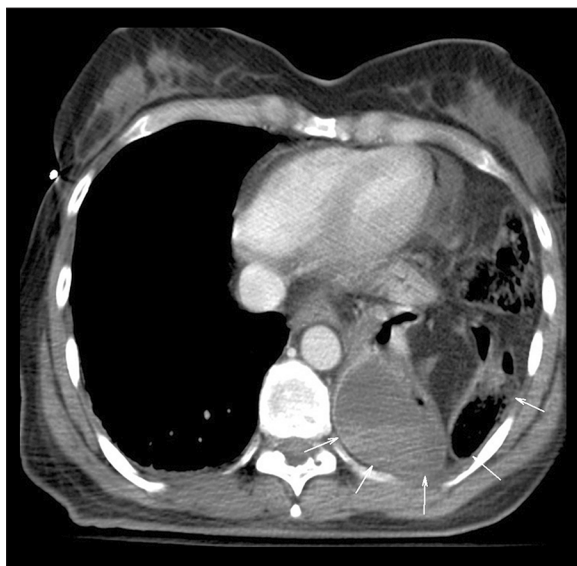The diaphragm is a double-domed musculotendinous partition between the thoracic and abdominal organs. It consists of the central tendinous part and the peripheral muscular part. The muscular parts are classified according to the attachment site into the strongest lumbar part (consisting of the left and the right branch), two costal parts (attached to ribs VII–XII) and the smallest sternal part. The diaphragm features natural openings including the aortic hiatus, the esophageal hiatus, and the vena caval hiatus. Three arcuate ligaments are identified: medial arcuate ligaments (between the body and the transverse process of L1 or L2, above the psoas major muscle), lateral arcuate ligament (between the transverse process of L1 and rib XII above the quadratus lumborum muscle) and the median arcuate ligament (around the aortic hiatus).

Physiologically weaker regions of the diaphragm include the right and the left costosternal angle and costolumbar angles. Cognate hernias should be taken into account when





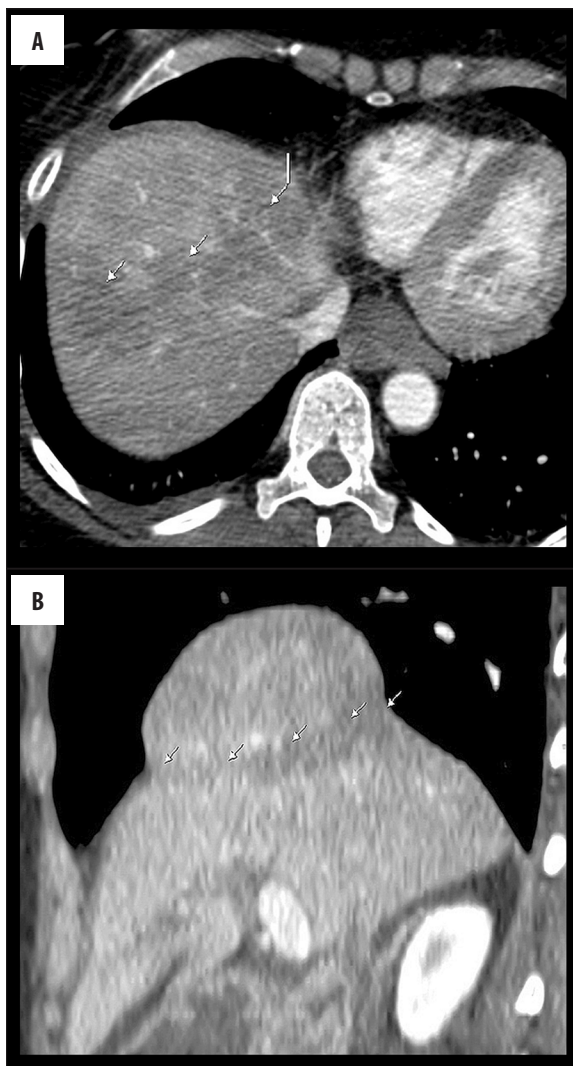
**Figure 3.** A 34-year-old patient after blunt trauma. Coronal reformatted CT image shows constriction of the herniated stomach at the level of the ruptured diaphragm (collar sign).



**Figure 4.** A 45-year-old female after severe blunt trauma. CT image shows rupture of the left hemidiaphragm. Stomach was herniated into the thorax and is located near the posterior chest wall, without interposition of the lung (dependent viscera sign). A 10-cm-long tear on the anterior-medial border of the central tendon of the left diaphragm was found at surgery. Almost the whole of the stomach, a large part of the omentum and a loop of the large intestine were herniated into the thorax. Other post-traumatic findings included multiple fractures of the pelvis.

differentiating between post-traumatic lesions within the diaphragm. Bochdalek hernia is most commonly observed within the left costolumbar angle in ca. 6% of adults (usually without any accompanying symptoms) while Morgagni hernia is observed within the costosternal angle [1,5].

Post-traumatic injuries of the diaphragm are usually located within the posterolateral parts of the diaphragm where the highest forces are at work during high-energy trauma.

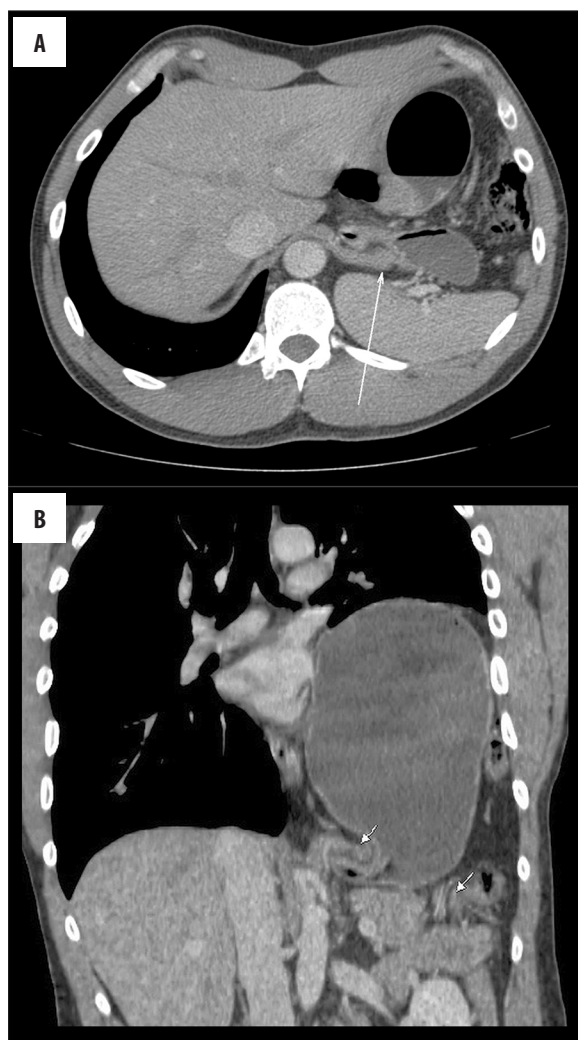


**Figure 5.** (A, B) A 56-year-old female pedestrian hit by a car. Right-sided diaphragmatic tear was suspected because of hump sign and band sign. Rupture was confirmed at surgery. Other post-traumatic findings included fracture of the left scapula, retroperitoneal hematoma, fractures of the pelvis.

Most commonly, two mechanisms of diaphragmatic injury are described depending on the direction and distribution of forces acting during the high-energy trauma.

Lateral impact results in forces twisting the thorax and leading to diaphragmatic rupture or attachment damage. This is the most common mechanism responsible for diaphragmatic injury in blunt thoraco-abdominal trauma; it involves the diaphragm being damaged on the side of the acting force (e.g. on the side of the vehicle door involved in the crash) [1]. The diaphragm may also be damaged by the fractured ribs.

Frontal impact (e.g. driver's impact on the driving wheel) results in a significant increase in abdominal pressure transferred by the organs onto the diaphragm, possibly leading to its damage and to the dislocation of abdominal organs into the thoracic cavity.



**Figure 6.** (A, B) A 25-year-old man admitted to ER with gradually worsening left-sided abdominal and chest pain, which started after exercises of the abdomen. Patient's history revealed a blunt abdominal trauma 5 years earlier. CT images show left-sided diaphragm defect with herniation of the stomach, spleen and part of the large intestine into the thorax. Radiological diagnosis was not confirmed at surgery – there was no rupture of the diaphragm, only diaphragmatic relaxation and dilatation of esophageal hiatus.

Injuries of the left hemidiaphragm are more common (3:1) [1,2,4,5]; this is explained by the protective effect being exerted by the liver on the right hemidiaphragm. Left-sided injuries are also favored by the presence of esophageal hiatus within the left hemidiaphragm. In addition, an important role is played by the right-sided traffic mode being more common worldwide; in this model, the vehicle door is on the driver's left, which favors direct trauma being more frequently inflicted on the left side of the body). Bilateral diaphragmatic ruptures are rare [1,2,4].

The differential diagnostics of diaphragmatic injuries should account for acquired diaphragmatic defects, most commonly observed within the posterior parts and the branches of the diaphragm. Such fenestrations are usually

small in size (1 mm–1 cm) and more common on the left side. They are encountered in older patients, more often in females of emphysema patients [1,2,4,5].

The hernia of the esophageal hiatus, particularly when large in diameter, may lead to diagnostic uncertainties in patients after multiorgan injuries. Similar uncertainties may be encountered in case of segmental diaphragmatic relaxation combined with elevation, e.g. due to phrenic nerve damage.

When interpreting the CT scans, one should also remember that the muscle fibers are subject to gradual atrophy occurring with age and are replaced by fibrous tissue. In such cases, diaphragmatic eventration may occur [1,4,5].

Of among the symptoms visualized in the CT scans of patients included in the study, the most important was the visualization of diaphragmatic dome continuity disruption with accompanying dislocation of abdominal organs into the thoracic cavity. Depending on the size of the injury, the other symptoms could also be observed. Frontal and sagittal reconstructions proved very helpful in visualization of diaphragmatic injuries.

The more common injuries of the left hemidiaphragm turned out also to be easier to diagnose using the CT scans. The visualized segmental diaphragmatic continuity defect was additionally confirmed by the presence of hernia through the rupture and impingement of dislocated organs at the herniation site (the collar sign). Correct diagnosis may be difficult in case of smaller diaphragmatic injuries without accompanying hernias, presence of pleural fluid, or the occurrence of motion artifacts [1,4,5].

Also in the case of right-sided injuries, correct diagnosis may be hampered in case of small injuries not leading to dislocation of liver parenchyma or intestinal loops across the rupture. In case of more extensive injuries, the diagnosis is easier; however, it requires the knowledge of typical signs observed in CT scans, i.e. the hump sign and the band sign).

No cases of complete lack of diaphragmatic dome within the CT image were observed in either of the cases. This may be due to the fact that such extensive injuries are burdened with higher mortality rates, with patients dying before being subjected to diagnostic imaging examinations.

CT may not be decisive in making the proven diagnosis of diaphragmatic injuries. Isolated elevation of abdominal organs and their presence above the diaphragm as secondary to the diaphragmatic continuity defect is a non-specific symptom being also observed in other nosocomial entities, such as phrenic nerve palsy. Therefore, organ elevation is not by itself an unambiguous sign of diaphragmatic injury. The possibility of diagnostic mistakes is also illustrated by the aforementioned case of a patient in whom despite the visualized lack in diaphragmatic continuity and displacement of abdominal organs into the thoracic cavity, no diaphragmatic rupture could be confirmed intraoperatively and the presentation was due to segmental diaphragmatic relaxation.

## Conclusions

In our study material, diaphragmatic injuries due to blunt thoraco-abdominal trauma were observed in 6% of patients, which was in line with the incidence reported in the literature. Most patients were young males after motor vehicle accidents, presenting with damage of the left hemidiaphragm.

Post-traumatic diaphragmatic injury is a relatively rare complication of extensive motor vehicle accidents, often accompanying complex trauma to the chest and abdomen. Diaphragmatic injury may be difficult to diagnose on the basis of the clinical presentation, as it may initially be asymptomatic or as the concomitant injuries may obscure the symptoms due to the injured diaphragm.

CT is an important element in the emergency diagnostics of patients after extensive thoraco-abdominal trauma. Evaluation for potential diaphragmatic injury requires three-dimensional reconstruction of images that allows for the dual dome shape of the diaphragm being taken into consideration.

The failure to diagnose the discontinuity of the diaphragm may lead to inappropriate treatment being administered as part of emergency intervention. The knowledge of radiological signs of diaphragmatic injury allows for an early diagnosis, qualification for surgical treatment and elimination of future complications.

## References:

1. Desir A, MD, Ghaye B MD: CT of blunt diaphragmatic rupture. *Radiographics*, 2012; 32: 477-98
2. Shanmuganathan K, Mirvis SE: CT diagnosis of diaphragm injuries. *Emerg Radiol*, 2001; 8: 6-14
3. Boccini G, Guida F, Sica G et al: Diaphragmatic injuries after blunt trauma: Are they still a challenge? *Am Soc Emergency Radiol*, 2012; 19: 225-35
4. Iochum S, Ludig T, Walter F et al: Imaging of diaphragmatic injury: A diagnostic challenge? *Radiographics*, 2002; 22: S103-16
5. Mirvis SE, Shanmuganathan K: Imaging hemidiaphragmatic injury. *Eur Radiol*, 2007; 17: 1411-21
6. Nchimi A, Szapiro D, Ghaye B et al: Helical CT of blunt diaphragmatic rupture. *Am J Roentgenol*, 2005; 184: 24-30
7. Kaya SO, Karabulut N, Yuncu G et al: Sinus cut-off sign: A helpful sign in the CT diagnosis of diaphragmatic rupture associated with pleural effusion. *Eur J of Radiol*, 2006; 59: 253-56
8. Shackleton KL, Stewart ET, Taylor AJ: Traumatic diaphragmatic Injuries: Spectrum of radiographic findings. *Radiographics*, 1998; 18: 49-59
9. Oikonomou A, Prassopoulos P: CT imaging of blunt chest trauma. *Insights Imaging*, 2011; 2: 281-95
10. Desser TS, Edwards B, Hunt S et al: The dangling diaphragm sign: Sensitivity and comparison with existing CT signs of blunt traumatic diaphragmatic rupture. *Emerg Radiol*, 2010; 17: 37-44