

Surgical Strategy for Skull Base Chordomas : Transnasal Midline Approach or Transcranial Lateral Approach

Benlin Wang,¹ Qi Li,¹ Yang Sun,² Xiaoguang Tong^{1,3}

School of Medicine,¹ Nankai University, Tianjin, China

Clinical College of Neurology,² Neurosurgery and Neurorehabilitation, Tianjin Medical University, Tianjin, China

Department of Neurosurgery,³ Tianjin Huanhu Hospital, Tianjin, China

Objective : The clinical management paradigm of skull base chordomas is still challenging. Surgical resection plays an important role of affecting the prognosis. Endonasal endoscopic approach (EEA) has gradually become the preferred surgical approach in most cases, but traditional transcranial surgery cannot be completely replaced. This study presents a comparison of the results of the two surgical strategies and a summary of the treatment algorithms for skull base chordomas.

Methods : We retrospectively analyzed the surgical outcomes and follow-up data of 48 patients with skull base chordomas diagnosed pathologically who received transnasal midline approaches (TMA) and transcranial lateral approaches (TLA) from 2010 to 2020.

Results : Among the 48 patients, 36 cases were adopted TMA and 12 cases were performed with TLA. In terms of gross total resection (GTR) rate, 27.8% in TMA and 16.7% in TLA and with EEA alone it was increased to 38.9%, while 29.7% in primary surgery. In TMA, the cerebrospinal fluid (CSF) leak remains the most common complication (13 cases, 36.1%), other main complications included death, cranial nerve palsy, hypopituitarism, all the comparisons were no statistical significance. The Karnofsky Performance Scale scores in TMA were all better than those in TLA at different time, and the overall survival (OS) and recurrence free survival/progression free survival was just the reverse.

Conclusion : The EEA for skull base chordomas resection has improved the GTR rate, but transcranial approach is still an alternative approach. It is necessary to select an appropriate surgical approach based on the location and the pattern of tumor growth in order to obtain the best surgical outcomes.

Key Words : Chordoma, skull base · Endoscopy · Craniotomy · Surgical outcome.

INTRODUCTION

Chordomas are pathologically benign tumors that originate from the notochord remnant which are typically midline and extradural lesion. Because of their location, ventral to the brain stem and invasive nature with vital neurovascular struc-

tures, skull base chordomas are difficult to treat, especially for gross total resection (GTR), hence the reason for recurrence. An aggressive surgical approach to attempt *en-bloc* resection and subsequent postoperative radiation therapy is recommended as the current therapeutic algorithm¹³. The surgical resection has a definitive role in the management of skull base

• Received : July 21, 2021 • Revised : August 24, 2021 • Accepted : September 2, 2021

• Address for reprints : Xiaoguang Tong

Department of Neurosurgery, Tianjin Huanhu Hospital, 6 Jizhao Road, Jinnan District, Tianjin 300350, China

Tel : +86-13820088121, Fax : +86-59065622, E-mail : tongxg8121@163.com, ORCID : <https://orcid.org/0000-0003-1747-802X>

This is an Open Access article distributed under the terms of the Creative Commons Attribution Non-Commercial License (<http://creativecommons.org/licenses/by-nc/4.0>) which permits unrestricted non-commercial use, distribution, and reproduction in any medium, provided the original work is properly cited.

chordomas. More extensive tumor removal has been associated with better prognosis^{23,28}. Furthermore, selection of the surgical approach is also a significant factor for achieving radical resection. Most otorhinolaryngologists and neurosurgeons traditionally use the midline and lateral approaches in order to gain access to the skull base chordomas. The anterior midline approaches consist of extended subfrontal, transmaxillary, transmandibular, transsphenoidal, endonasal endoscopic, transoral, and transcervical approaches^{3,6-8,20,27}. Transcranial lateral approaches (TLA) include frontotemporal transcavernous, orbitozygomatic, anterior transpetrosal, preauricular infratemporal, and extreme lateral transcondylar approaches^{17,19,21,24,25}. All surgical approaches should be selected with the goal of GTR and minimal morbidity and mortality at the same time. However, when the tumors extend to more than one contiguous anatomical areas of skull base, radical removal may be difficult to achieve with a single approach, two or more surgical procedures are required¹.

The purpose of this study is to analyze the surgical outcomes of transnasal midline approaches (TMA) and TLA for the treatment of skull base chordomas over the last 10 years in our institute, and to summarize the appropriate surgical approach according to the growth pattern of tumors in order to obtain the best surgical outcomes.

MATERIALS AND METHODS

Patients

This retrospective study was in accordance with the ethical standards and approved by the Institutional Review Board (IRB) of Tianjin Huanhu Hospital (IRB No. 2022-002). We retrospectively reviewed 48 patients with histopathologically diagnosed skull base chordoma in our institution between January 2010 and September 2020. Data for all patients are obtained from patients' medical records, radiological imaging data, and telephone interviews if necessary. All patients were assessed with Karnofsky Performance Scale (KPS) scores on admission, at discharge and 6 months after surgery.

Imaging assessment

All patients underwent a preoperative workup including magnetic resonance imaging (MRI), computed tomography (CT) and CT angiography to evaluate the characteristics of the

tumor. The primary characteristics are listed as follows : 1) location and size in three dimensions, their volumes are calculated by $A \times B \times C$ where A, B, and C are the maximum diameters of the chordoma in axial, coronal, and sagittal; 2) the extent of tumor invasion into surrounding tissues including the relationship between tumor and internal carotid artery (ICA), vertebral artery (VA), basilar artery (BA) and brainstem. Vascular involvement is defined as displaced, steno-occlusion or encased by tumor; and 3) the extent of bony infiltration and vascular involvement. The postoperative gadolinium enhanced MRI within 3 days was obtained to assess for any tumor residual. Extent of resection was categorized as GTR if there was no apparent residual tumor on postoperative MRI, and as subtotal resection (STR) for any radiographic residual (tumor removal greater than 90%), and as partial resection (PR) for most of the tumor residual (removal between 50% and 90% of the tumor).

Surgical procedure

The surgical approaches are divided into two types : TMA and TLA. The former included endonasal microscopic approach (EMA) in the early stage and endonasal endoscopic approach (EEA) at a later stage. The latter, depending on the location of the tumor, consists of frontotemporal approach, transcavernous approach, combined approach, extreme lateral transcondylar approach. The procedure of the EEA is as follows which performed by both neurosurgeons and otorhinolaryngologists. The basic indications for surgical approach selection is that the TMA was preferred for patients whose tumor was located in the midline ventral skull base with a small lateral extension or not. However, the TLA was preferred primarily because the tumors extend widely to the lateral skull base, such as invasion of the middle cranial fossa, petrous bone, infratemporal fossa, close relationship with important intracranial vessels or extensive intradural invasion and obvious brainstem compression. On the other hand, the decision was sometimes made based on the surgeon's familiarity with different skull base approaches.

The patient is placed in a supine position with the trunk elevated 10° and the head turned 10° toward the surgeon. Prepared a fat and/or fascia lata grafts in the anterolateral thigh or abdomen to repair bone and dural defects. A straight 4-mm endoscope for tumor removal and angled scopes for observation. Both nasal cavities were filled with adrenaline saline cottonoids to enlarge the space between turbinates and nasal sep-

tum to obtain decongestion of the nasal mucosa. The binostril four-hand technique was applied if necessary, especially in cases with cavernous sinus (CS) invasion and subdural extension. The right middle turbinate was resected and a vascularized nasoseptal flap was prepared and placed around nasopharynx, then the posterior segment of the nasal septum was removed. When the entire anterior wall of the sphenoid sinus was visible, bone punches or a microdrill was used to enlarge circumferentially. The anterior wall of the sphenoid sinus should be widely removed before reaching the sella. The sphenoid sinus floor was drilled down to the clivus recess, a wide sphenoidotomy and posterior etmoidectomy was performed to form a corridor between the maxillary sinus and the sphenoid sinus. At this time, some important anatomical landmark need to be identified, including optic nerve, optocarotid recess (OCR), cavernous segment and paraclival segment of ICA. The epidural portion of tumors can be identified and removed after the eroded bone was drilled. The cases with subdural extension that adjacent to the BA and brainstem should be resected carefully with four-hand technique. At the end of the procedure, the skull base defect was reconstructed using a multilayer graft harvested by fat, fascia lata, and vascularized nasoseptal flap. Finally, fibrin glue was used at the edges of the bone in order to fix the whole reconstruction.

Statistical analysis

IBM SPSS Statistics ver. 25 (IBM, Corp., Armonk, NY, USA) was used for statistical analysis. The chi-square test or Fisher's exact test was utilized to evaluate the categorical data. The differences in medians between two variables were evaluated with Mann-Whitney U test. Kaplan-Meier analyses was used to analyze cumulative survival rates and cumulative recurrence free survival/progression free survival (RFS/PFS). All of *p*-values are 2-sided and 2-tailed and *p*<0.05 was considered statistically significant.

RESULTS

Demographic and clinical characteristics

Table 1 summarized the patients' demographic information and clinical symptoms of the two groups. Among the 48 patients, there were 22 males and 14 females in the TMA group; four males and eight females in the TLA group. No statistical

Table 1. Demographics and symptoms of two approaches

	TMA (n=36)	TLA (n=12)	Total	<i>p</i> -value
Sex				
Male	22	4	26	0.181
Female	14	8	22	
Age (years)	58.0 (10–71)	39.5 (20–61)		0.014
Symptoms				
Headache	15	4	19	0.865
Dysopia	12	3	15	0.857
Abducens nerve palsy	4	1	5	1.000
Facial numbness	1	1	2	1.000
Dysphagia	2	0	2	1.000
Incidental	2	0	2	1.000
Limbs weakness	0	2	2	0.059
Hypacusis	0	1	1	0.250

Values are presented as median (range) or number. TMA : transnasal midline approaches, TLA : transcranial lateral approaches

difference was reached in gender. The median age was 58.0 (10–71) and 39.5 (20–61), respectively. Patients in TMA group were older than that in TLA, and reached a statistical difference (*p*=0.014). In TMA group, symptoms leading to diagnosis were headache in 15 cases (41.7%), dysopia in 12 cases (33.3%), abducens nerve palsy in four cases (11.1%), facial numbness in one case (2.8%), dysphagia in two cases (5.6%), incidental found in two cases (5.6%); in TLA group, headache in four cases (33.3%), dysopia in three cases (25%), abducens nerve palsy in one case (8.3%), facial numbness in one case (8.3%), limbs weakness in two cases (16.7%) and one case with hypacusis (8.3%). There was no statistical difference in all symptoms between the two groups.

Comparison in surgical outcomes between the two approaches

Table 2 displayed the detailed comparisons of the two approaches; the tumor location and extension based on imaging data were also listed. The tumor extension was primarily focus on the relationship between tumor and CS, ICA, VA, BA, dura matter and brainstem. There was no statistical significance in tumor location and extension between the two groups. Among the 36 patients in the TMA group, 18 underwent EMA and 18 performed by EEA (primary surgery in 28 cases and recurrent surgery in eight cases); while among the

12 patients in the TLA group, nine cases with primary surgery and three cases with recurrent surgery. The median tumor

volume was 27.1 cm³ (2.7–159.1 cm³) in TMA group and 46.1 cm³ (15.1–232.0 cm³) in TLA group. The tumor volume in the

Table 2. Detailed comparisons between TMA and TLA

	TMA (n=36)	TLA (n=12)	Total	p-value
Tumor location				
Sellar and parasellar	13	7	20	0.310
Clivus	16	2	18	0.168
Both involvement	5	1	6	1.000
Others	2	2	4	0.546
Tumor extension				
CS/ICA	14	2	16	0.289
VA/BA/DM/BS	8	2	10	1.000
Both of them*	13	8	21	0.131
None	1	0	1	
Surgery				
Primary	28	9	37	1.000
Recurrent	8	3	11	
TV (cm ³)	27.1 (2.7–159.1)	46.1 (15.1–232.0)		0.063
EOR				
GTR	10	2	12	0.700
STR	21	9	30	0.491
PR	5	1	6	1.000
LOPHS (days)	9.0 (6–45)	19.5 (12–46)		0.006
Complications				
Death	2	0	2	1.000
CSF leak	13	1	14	0.142
CN palsy	2	3	5	0.173
Hypopituitarism	2	2	4	0.546
Others [†]	0	2	2	0.059

Values are presented as median (range) or number. *At least one CS/ICA and one VA/BA/DM/BS were involved. [†]Epilepsy and epidural hematoma. TMA : transnasal midline approaches, TLA : transcranial lateral approaches, CS : cavernous sinus, ICA : internal carotid artery, VA : vertebral artery, BA : basilar artery, DM : dura matter, BS : brainstem, TV : tumor volume, EOR : extent of resection, GTR : gross total resection, STR : subtotal resection, PR : partial resection, LOPHS : length of postoperative hospital stay, CSF : cerebrospinal fluid, CN : cranial nerve

Table 3. The number of GTR in different conditions

	Primary	Recurrence	EMA	EEA
GTR	11 (29.7)	1 (9.1)	3 (16.7)	7 (38.9)
STR/PR	26 (70.3)	10 (90.9)	15 (83.3)	11 (61.1)
Total	37 (100.0)	11 (100.0)	18 (100.0)	18 (100.0)
p-value	0.322		0.264	

Values are presented as number (%). GTR : gross total resection, EMA : endonasal microscopic approach, EEA : endonasal endoscopic approach, STR : subtotal resection, PR : partial resection

TLA group was larger than that in the TMA group with no statistically significant ($p=0.063$).

In terms of the extent of resection, the overall number of GTR was 12, STR was 30 and PR was 6, among which 10 cases reached GTR, 21 cases of STR and five cases of PR in the TMA group; in TLA group, there were two cases of GTR, nine cases of STR, and one case of PR. The GTR rate was 27.8% vs. 16.7% ($p=0.700$). However, there are some differences in GTR rates under different conditions, as shown in Table 3. For the primary surgery, the GTR rate was 29.7%, and for the surgery after tumor recurrence, the GTR rate was only 9.1% ($p=0.322$). In the midline approaches, the GTR rate was increased to 38.9% via EEA compared with 16.7% followed by EMA ($p=0.264$).

Complications

As seen from Table 2. In the TMA group, cerebrospinal fluid (CSF) leakage was the most common complication, accounting for 36.1% (13 cases). Of the 13 cases, two of them

led to intracranial infection and improved after antibiotic treatment. Lumbar drainage was performed in seven cases and a surgical repair in one case due to a persistent leakage. The others included two deaths during the operation, mainly caused by intraoperative CS hemorrhage and brainstem failure because of delayed intracerebral hemorrhage respectively, cranial nerve (CN) palsy in two cases and two cases of hypopituitarism. On the other hand, in the TLA group, there were no deaths during the surgery, only one patient had CSF leak and ceased after the lumbar drainage in 2 weeks, CN palsy in three cases, hypopituitarism in two cases, and one epilepsy and one epidural hematoma that required surgical removal. The comparison of all complications did not reach statistical significance. The mean length of postoperative hospital stay was longer in TLA group than that in TMA group (19.5 vs. 9.0 days, $p=0.006$).

Life status and follow up

The KPS scores in each group during different periods were shown in Fig. 1. The mean KPS score can more intuitively reflect the life status, which was slightly higher in the TMA group than that of TLA group before surgery, at discharge and 6 months later after discharge, and the KPS score at discharge was statistically significant. The median follow-up period of the two groups was 35.0 months (6–126 months) and 64.5 months (6–124 months), respectively ($p=0.296$) (Table 4). During the follow-up period, 19 patients in TMA group and six patients in TLA group were found to tumor recurrence, the number of deaths added to six in TMA and two in TLA, seven of whom died from disease progression with no further treatment and one patient died after two more surgeries in another hospital. The median overall survival (OS) was 37.0 months (8–129 months) in the TMA group and 82.5 months (7–192 months) in the TLA group ($p=0.050$), and the median

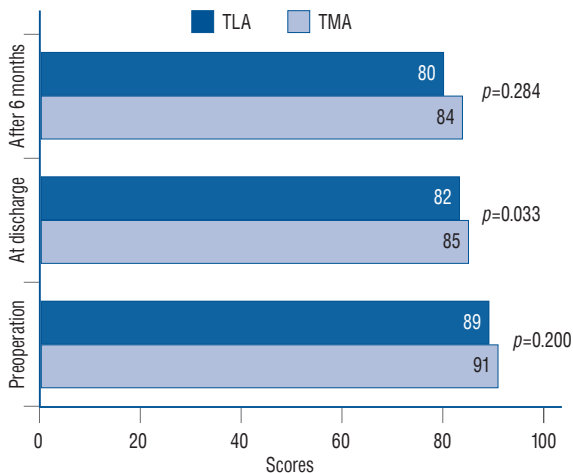


Fig. 1. The KPS scores and p -values in two groups at different period of time. TLA : transcranial lateral approaches, TMA : transnasal midline approaches, KPS : Karnofsky Performance Scale.

Table 4. Follow up information of two groups

	TMA (n=36)	TLA (n=12)	p-value
FU (months)	35.0 (6–126)	64.5 (6–124)	0.296
Recurrence	19	6	0.423
Died during FU	6	2	1.000
OS (months)	37.0 (8–129)	82.5 (7–192)	0.050
RFS/PFS (months)	15.0 (3–72)	24.0 (12–57)	0.094

Values are presented as median (range) or number. TMA : transnasal midline approaches, TLA : transcranial lateral approaches, FU : follow up, OS : overall survival, RFS : recurrence free survival, PFS : progression free survival

RFS/PFS was 15.0 months (3–72 months) and 24.0 months (12–57 months), respectively ($p=0.094$). Fig. 2 shows the cumulative survival rate ($p=0.552$) and cumulative RFS/PFS ($p=0.144$) of the two groups, and there were no statistical dif-

ferences.

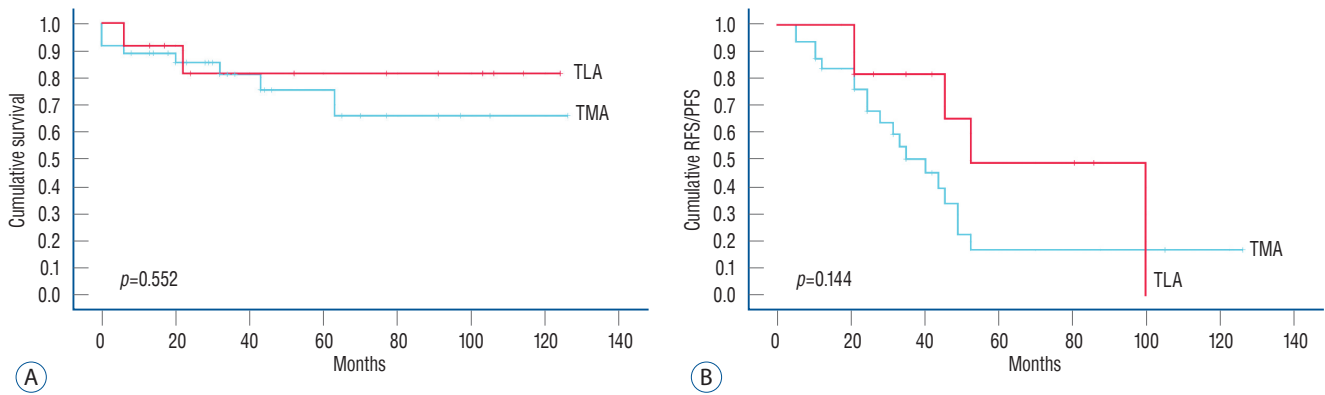


Fig. 2. Kaplan-Meier analysis of TMA and TLA for cumulative survival (A) and cumulative RFS/PFS (B). TLA : transcranial lateral approaches, TMA : transnasal midline approaches, RFS/PFS : recurrence free survival/progression free survival.

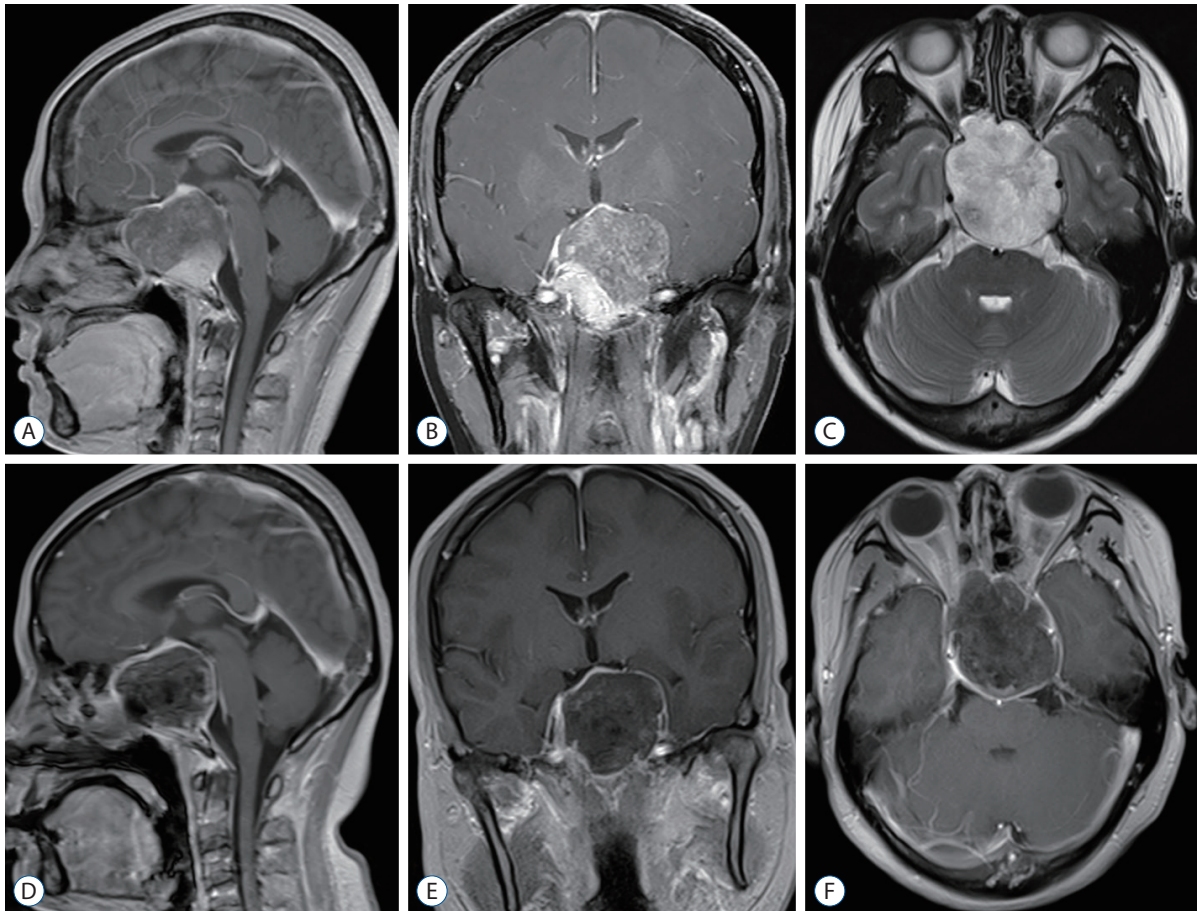


Fig. 3. Preoperative sagittal (A), coronal (B), and axial (C) magnetic resonance imaging (MRI) scans revealed a large tumor was located on sellar, sphenoid sinus and clivus areas with bilateral cavernous sinus and carotid artery involvement. Postoperative MRI (D-F) showed a subtotal resection was accomplished.

Illustrative cases

Case 1

This case is presented to illustrate the EMA to remove skull base chordoma. A 29-year-old woman clinically presented with dysopia in both eyes for half a month and mild headache. Physical examination revealed binocular dysopia and bilateral visual field defects. Preoperative MRI scans showed a large and destructive mass in the sellar-sphenoid-clivus area with CS and carotid artery involvement bilaterally (Fig. 3A-C). Her preoperative KPS score was 90. The lesion was removed by EMA with STR achieved (Fig. 3D-F). The symptom was somewhat restored immediately after surgery, considering that most of the tumor had been removed and complete optic nerve decompression was performed. Postoperatively, there was no CSF leak but slight hypopituitarism. The KPS score at discharge was 90 with no postoperative radiotherapy admin-

istered. The visual impairment has not completely recovered in the follow-up period.

Case 2

This case is presented to illustrate the EEA for treating skull base chordoma. A 65-year-old woman presented with intermittent headache for a half year and XIIth CN palsy, KPS score was 90 on admission. A preoperative MRI scan revealed an inferior clival chordoma with right medulla compression (Fig. 4A-C). She underwent a GTR by EEA (Fig. 4D-F). CSF leak occurred during the operation, and the subcutaneous fascia lata was harvested for plugging. Lumbar drainage was performed postoperatively, which was removed 5 days later. The KPS score at discharge was also 90 and remained XIIth CN palsy. No radiotherapy was administered because the tumor was completely resected.

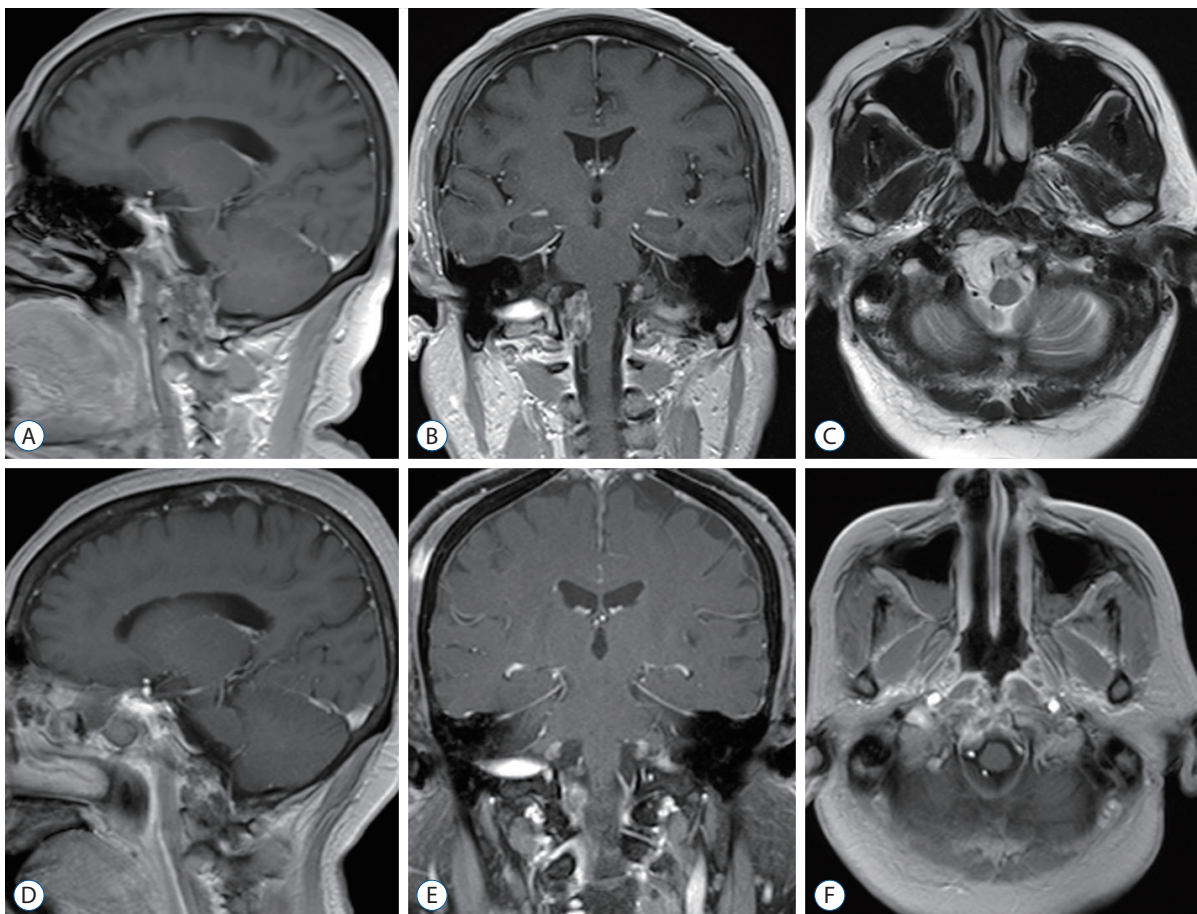


Fig. 4. Preoperative sagittal (A), coronal (B), and axial (C) magnetic resonance imaging (MRI) scans revealed the tumor is located on the right side of the lower clivus, compressing the medulla. Postoperative MRI (D-F) indicated complete removal of tumor.

Case 3

This case is presented to illustrate a case where the tumor progressed again after eight previous surgeries. This is the ninth operation via combined TLA. A 31-year-old man initially presented with IXth and Vth CN palsy, headache, and limbs weakness in 2013. After eight previous operations in other institutes, the clinical manifestation of this time (July 2019) was right limb weakness. The preoperative KPS was 80. On MRI scans, a destructive tumor was revealed extending from the upper-clivus to the craniocervical junction (CVJ) (Fig. 5A-C); the medulla was compressed and involved the left temporal and infratemporal fossa upward. This tumor was mostly removed by combining an extreme lateral transcondylar approach and infratemporal fossa approach for palliative purposes (Fig. 5D-F) with residual tumor in lower-clivus. No CSF leak occurred but the IXth, Xth and XIth CNs were injured. He was discharged from hospital with a 50 KPS score,

indicating that the part of life can be self-care, but often need someone to take care of. Postoperative radiotherapy was not received in consideration of his life status and KPS score remains unchanged during the follow up.

DISCUSSION

Chordomas are rare, slow-growing, locally destructive mid-line tumors. Although pathologically considered to a benign neoplasm, chordomas have a rate of recurrence, their invasive growth pattern is often more typical of a malignancy. Headaches, dysopia and CNs palsy are the most clinical presentations and neurological signs. Surgical resection is one of the pivotal factors affecting the prognosis. Many publications have supported that radical resection is generally considered the best treatment^{1,5,22,23,28}. For all this, taking the difficulty of

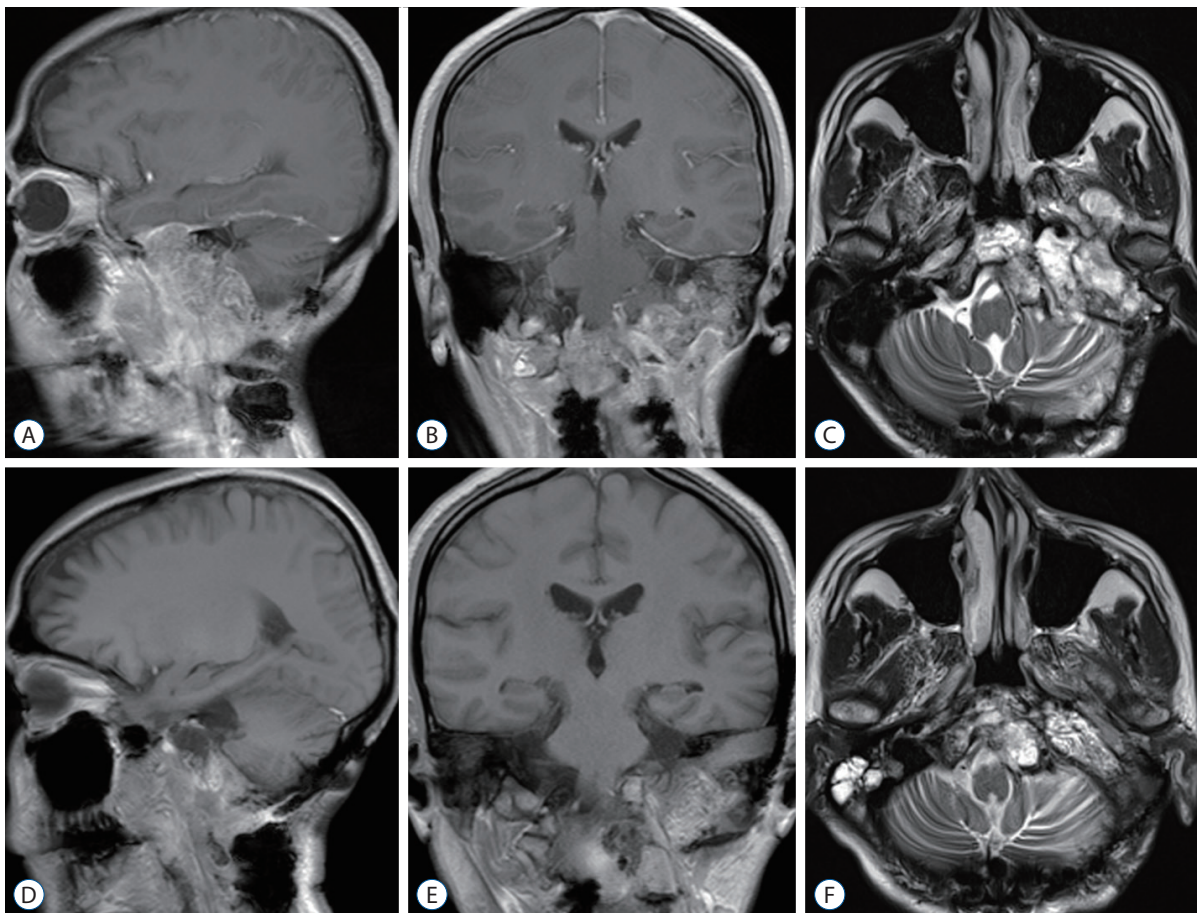


Fig. 5. Preoperative sagittal (A), coronal (B), and axial (C) magnetic resonance imaging (MRI) scans revealed a huge mass extending from the upper-clivus to the craniocervical junction with medulla, left temporal lobe and infratemporal fossa involvement. Postoperative MRI (D-F) displayed subtotal resection of tumor with residual in lower-clivus.

accomplishing a GTR and the potential high morbidity related to aggressive tumor removal into account, safe cytoreduction with radiotherapy or staged surgical procedures seems to be another acceptable option, especially suitable for cases that are difficult to remove in a single surgery. Meanwhile, when considering to perform a staged surgery, based on the location and growth pattern of the tumor, it is crucial to select an appropriate surgical approach in the first operation to remove as much tumor as possible in preparation for the later second operation.

EMA

In view of most skull base chordomas have a center in the vicinity of the midline (Fig. 6), the transsphenoidal route often provides the most direct corridor and minimally invasive approach for lesion resection. As a matter of fact, when the endoscopy had not widely used in the treatment of skull base chordomas, EMA was used infrequently. Several literatures had reported a series of results through this approach. Maira et al.¹⁵⁾ reported a series of 12 clival chordomas, GTR was achieved in nine cases (75%). In a report of 18 patients with clival chordo-

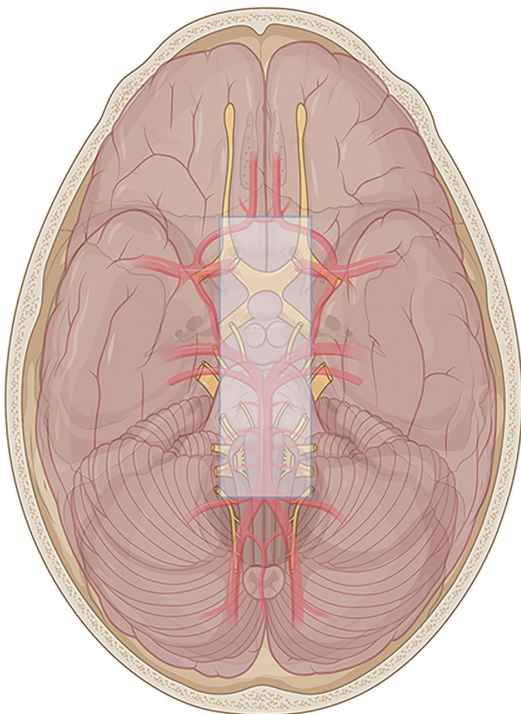


Fig. 6. Schematic diagram of skull base: the shadow area represents the midline area of the skull base roughly, with the boundary from rostral to caudal is the median orbital wall, lateral wall of the cavernous sinus, jugular tuberculum, hypoglossal nerve hole, and occipital condyle.

mas treated with extended microsurgical transsphenoidal approach by Couldwell et al.⁶⁾, GTR was achieved in 12 (66.7%). Fatemi et al.⁹⁾ reported 14 cases of clival chordomas with microsurgical transsphenoidal, GTR was achieved in 43%. Meanwhile, they pointed out that the use of the endoscope was associated with gross total or near-total tumor removal. In our series of 18 EMA cases, 16.7% with GTR and 66.7% with STR. The reasons why using EMA in the early stage are because of the fact that their tumor epicenter in the clivus or sellar with relatively few cases extending laterally, no open surgery and brain retraction are required, and the lack of experience in the use of endoscopy in the treatment of skull base chordoma. Given the limited lateral exposure, they were not sufficient for complete removal under most circumstances.

EEA

With the advent of endoscopic technology, it has been increasingly used to treat midline skull base lesions. The approach that averts brain retraction, large vessel and nerve manipulation was developed initially for intrasellar lesions and had been proved to obtain a good outcome. Recent advances in endoscopic facilities combined with neuronavigation and good cooperation with otolaryngologists have expanded the scope of endoscopic skull base surgery, clival chordomas are one of them. Furthermore, proficient mastery of the binostril approach as well as the four-hand technique makes the procedure more flexible under endoscopy. Recently, an increasing number of publications reported the EEA for skull base chordomas^{2,10,12,14,30)}. The GTR rate ranged from 33% to 86%¹⁶⁾, of which for primary tumors this can be as high as 80%, while that of recurrent tumors reduced to less than 50%^{2,14)}. In contrast to microsurgery, the endoscopy enables a panoramic view rather than a narrow microscopic view. The access to entire ventral skull base is available by EEA. The rationale of this approach is that the neurovascular and brainstem are always posterior or lateral to the tumor. Fig. 6 reveals the midline areas within the shadow, connecting the median wall of orbit, lateral wall of the CS, internal auditory canal, jugular tuberculum, hypoglossal nerve hole and occipital condyle. EEA should be the first choice for lesions removal in this area. However, if the tumor extends laterally to this area, it does not mean that the EEA is a contraindication, but it is possible to increase the risk of damaging the neurovascular during the surgery that requires an experienced neurosurgeon or otolar-

ngologist to perform the procedure. For instance, when the tumor extends laterally to the optic nerve and lateral wall of the CS, even with carotid artery encasement, careful dissection and protection of the cavernous segment of the ICA is essential, as the rupture of ICA at this situation is often fatal, such as in one of our dead cases. This process would probably across the OCR, which would also go against Kassam's philosophy : when possible, do not across the plant of CN²⁷. With great care not to traumatize the lateral wall of CS as CNs (III, IV, V, and VI) situated at its inner aspect. If the anterior clinoid process has become an obstacle in the surgical field, endoscopic removal is also limited which may cause damage to the ophthalmic artery or/and CN III. Lateral extension of the chordoma at the level of the upper clivus and dorsum sellar requires a pituitary gland transposition superiorly with preservation of the pituitary stalk, which may affect the integrity and function of the pituitary gland, and not recommended by Gui et al.¹². Lateral extension of the tumor at the level of the lower clivus even to the CVJ, the lateral extend is limited by hypoglossal nerve. The endonasal transpterygoid and transcondylar approaches provide access to the petrous apex, infrapetrous area, lateral and lower of the tumor. Maxillotomomy and eustachian tube resection is necessary and it is an important landmark for the parapharyngeal ICA. When more than half of the occipital condyle was resected, occipitocervical fusion may be required which is not appropriate for this manipulation with endoscopy. In addition, the tumor size is also one of the reasons for limiting GTR with EEA when tumors with a diameter >4.0 cm or a volume >80 cm³^{10,18}. As the results of our series showed, the tumor diameter in the TLA group was significantly larger, which may be one of the reasons for the lower GTR rate than TMA or EEA.

TLA

Even though the EEA has many advantages and considerable GTR rates, TLAs are unable to be replaced completely up to now. Generally, the EEA and the lateral approach should complement each other, rather than substitute one for another. In a series of lateral approaches reported in the literatures, the GTR fluctuated. Such as reported by Colli and Al-Mefty⁴, the total resection was 45.3% in 53 cases with skull base chordomas. Tzortzidis et al.²⁸ reported the GTR rate was 71.6% of their 74 patients. Gay et al.¹¹ achieved GTR in 47% of their 46 skull base chordoma patients. The merit of microscopic-as-

sisted lateral approach is to make up for the insufficiency of EEA, especially for lateralized to the paramedian area or tightly involved the ICA, CS or have intradural extension with brainstem, vertebral and BA involved^{4,23,28}. Furthermore, TLA is more suitable for extremely delicate manipulations than EEA, and allow safer dissection between the tumor and BA and brainstem²³. The following TLAs are the most frequently used for skull base chordomas resection, alone or in combination : 1) Frontoorbitozygomatic approach. It is used for upper clivus lesions and extending laterally into the ICA, middle fossa, petrous apex, and provides excellent intradural access to the CS and intradural structures. However, the disadvantage of this approach is the limited visualization and does not address any bony infiltration, which may require a second approach to facilitate resection such as frontotemporal and/or transcavernous approach. 2) Subtemporal-infratemporal approach/Extended middle fossa approach. It provides a shorter access to middle skull base, petrous apex, upper clivus. It is an excellent approach to treat the lesions of infratemporal fossa and temporal fossa. When combined with the transpetrosal approach, clival chordoma that extends laterally to the petrous bone can be reached. And 3) extreme lateral transcondylar approach. It is used for chordomas involving the lower clivus, foramen magnum, occipital condyle, and extending laterally to the CVJ²⁴. This approach facilitates the control of the VA and performed occipitocervical fixation if necessary, which is difficult to achieved by EEA.

Complications

CSF leak and CNs palsy are the most frequent postoperative complications^{4,23,28}. CSF leak usually occurred in EEA owing to the dura was eroded by tumor or by the surgical approach occasionally and the persistent leak can cause predispose to intracranial infection and pneumocephalus. In most cases, multilayer skull base reconstruction with fat, fascia lata, and vascularized nasoseptal flap to plug the leakage and/or with lumbar drainage can significantly reduce the incidence of postoperative CSF leak. Excessive opening of the dura outside the tumor area should be avoided and only the eroded dura was opened to reduce the risk of CSF leak. On the other hand, working through spaces between CNs, the TLA may increase the likelihood of functional impairment (three of 12 cases in our series).

Tumor recurrence and radiotherapy

Regardless of the treatment modality, local recurrence of skull base chordoma is still common and affected by many factors, such as age, tumor location and size, the extent of surgical resection, postoperative radiotherapy, and tumor pathology and histological subtypes. Nevertheless, an aggressive surgical resection has been supposed to have a better prognosis^{23,28}. In the meantime, advances in radiation technology have led to some consensus that radiation therapy in combination with surgery provides an additional advantage, consequently, adjuvant radiotherapy is recommended after surgery, even for inoperable patients^{26,29}. In our study, the differences in median OS, median RFS, and median PFS may be due to the difference in follow-up time between the two groups.

There are some limitations in our research : this was a retrospective study, not all the surgeries were performed by the same neurosurgeon, and the concepts and the selection of surgical approach they are familiar with were different. Moreover, there were relatively few cases in the TLA group, which may lead to no statistical significance to some extent and the statistical differences in age between the two groups. Each patients' data needs to be reevaluated after their 5 and 10 years during the follow-up.

CONCLUSION

Despite the management of skull base chordomas has changed from microscopic to endoscopic surgery gradually, a direct comparison between the two approaches is difficult, because there is no absolute boundary and both are essential for modern skull base surgeons. With the development of various surgical techniques, the combination of microscope-assisted lateral approach and EEA may further improve the GTR rate, which requires more researches on large number of patients. However, lacking of consensus on the optimal treatment for skull base chordomas makes treatment strategies varied from each center. A multidisciplinary collaboration of neurosurgeons, otorhinolaryngologists, and neuroradiologists is conducive to a comprehensive assessment of skull base chordomas.

AUTHORS' DECLARATION

Conflicts of interest

No potential conflict of interest relevant to this article was reported.

Informed consent

This type of study does not require informed consent.

Author contributions

Conceptualization : BW; Data curation : BW, QL, YS; Formal analysis : BW; Funding acquisition : XT; Methodology : BW; Project administration : XT; Visualization : BW; Writing - original draft : BW; Writing - review & editing : XT

Data sharing

None

Preprint

None

ORCID

Benlin Wang	https://orcid.org/0000-0002-8358-3154
Qi Li	https://orcid.org/0000-0001-9433-7154
Yang Sun	https://orcid.org/0000-0002-9519-4199
Xiaoguang Tong	https://orcid.org/0000-0003-1747-802X

References

1. al-Mefty O, Borba LA : Skull base chordomas: a management challenge. **J Neurosurg** **86** : 182-189, 1997
2. Chibbaro S, Cornelius JF, Froelich S, Tigan L, Kehrl P, Debry C, et al. : Endoscopic endonasal approach in the management of skull base chordomas--clinical experience on a large series, technique, outcome, and pitfalls. **Neurosurg Rev** **37** : 217-224; discussion 224-225, 2014
3. Choi D, Melcher R, Harms J, Crockard A : Outcome of 132 operations in 97 patients with chordomas of the craniocervical junction and upper cervical spine. **Neurosurgery** **66** : 59-65; discussion 65, 2010
4. Colli B, Al-Mefty O : Chordomas of the craniocervical junction: follow-up review and prognostic factors. **J Neurosurg** **95** : 933-943, 2001
5. Colli BO, Al-Mefty O : Chordomas of the skull base: follow-up review and prognostic factors. **Neurosurg Focus** **10** : E1, 2001
6. Couldwell WT, Weiss MH, Rabb C, Liu JK, Apfelbaum RI, Fukushima

- T : Variations on the standard transsphenoidal approach to the sellar region, with emphasis on the extended approaches and parasellar approaches: surgical experience in 105 cases. **Neurosurgery** 55 : 539-547; discussion 547-550, 2004
7. Delgado TE, Garrido E, Harwick RD : Labiomandibular, transoral approach to chordomas in the clivus and upper cervical spine. **Neurosurgery** 8 : 675-679, 1981
 8. DeMonte F, Diaz E Jr, Callender D, Suk I : Transmandibular, circumglossal, retropharyngeal approach for chordomas of the clivus and upper cervical spine. Technical note. **Neurosurg Focus** 10 : E10, 2001
 9. Fatemi N, Dusick JR, Gorgulho AA, Mattozo CA, Moftakhar P, De Salles AA, et al. : Endonasal microscopic removal of clival chordomas. **Surg Neurol** 69 : 331-338, 2008
 10. Fraser JF, Nyquist GG, Moore N, Anand VK, Schwartz TH : Endoscopic endonasal transclival resection of chordomas: operative technique, clinical outcome, and review of the literature. **J Neurosurg** 112 : 1061-1069, 2010
 11. Gay E, Sekhar LN, Rubinstein E, Wright DC, Sen C, Janecka IP, et al. : Chordomas and chondrosarcomas of the cranial base: results and follow-up of 60 patients. **Neurosurgery** 36 : 887-896; discussion 896-897, 1995
 12. Gui S, Zong X, Wang X, Li C, Zhao P, Cao L, et al. : Classification and surgical approaches for transnasal endoscopic skull base chordoma resection: a 6-year experience with 161 cases. **Neurosurg Rev** 39 : 321-332; discussion 332-333, 2016
 13. Ito E, Saito K, Okada T, Nagatani T, Nagasaka T : Long-term control of clival chordoma with initial aggressive surgical resection and gamma knife radiosurgery for recurrence. **Acta Neurochir (Wien)** 152 : 57-67; discussion 67, 2010
 14. Koutourousiou M, Gardner PA, Tormenti MJ, Henry SL, Stefko ST, Kassam AB, et al. : Endoscopic endonasal approach for resection of cranial base chordomas: outcomes and learning curve. **Neurosurgery** 71 : 614-624; discussion 624-625, 2012
 15. Maira G, Pallini R, Anile C, Fernandez E, Salvinelli F, La Rocca LM, et al. : Surgical treatment of clival chordomas: the transsphenoidal approach revisited. **J Neurosurg** 85 : 784-792, 1996
 16. Mangussi-Gomes J, Beer-Furlan A, Balsalobre L, Vellutini EA, Stamm AC : Endoscopic endonasal management of skull base chordomas: surgical technique, nuances, and pitfalls. **Otolaryngol Clin North Am** 49 : 167-182, 2016
 17. Margalit NS, Lesser JB, Singer M, Sen C : Lateral approach to anterolateral tumors at the foramen magnum: factors determining surgical procedure. **Neurosurgery** 56(2 Suppl) : 324-336; discussion 324-336, 2005
 18. Saito K, Toda M, Tomita T, Ogawa K, Yoshida K : Surgical results of an endoscopic endonasal approach for clival chordomas. **Acta Neurochir (Wien)** 154 : 879-886, 2012
 19. Salas E, Sekhar LN, Ziyal IM, Caputy AJ, Wright DC : Variations of the extreme-lateral craniocervical approach: anatomical study and clinical analysis of 69 patients. **J Neurosurg** 90(2 Suppl) : 206-219, 1999
 20. Sekhar LN, Nanda A, Sen CN, Snyderman CN, Janecka IP : The extended frontal approach to tumors of the anterior, middle, and posterior skull base. **J Neurosurg** 76 : 198-206, 1992
 21. Sekhar LN, Schramm VL Jr, Jones NF : Subtemporal-preauricular infratemporal fossa approach to large lateral and posterior cranial base neoplasms. **J Neurosurg** 67 : 488-499, 1987
 22. Sen C, Triana A : Cranial chordomas: results of radical excision. **Neurosurg Focus** 10 : E3, 2001
 23. Sen C, Triana AI, Berglind N, Godbold J, Shrivastava RK : Clival chordomas: clinical management, results, and complications in 71 patients. **J Neurosurg** 113 : 1059-1071, 2010
 24. Sen CN, Sekhar LN : An extreme lateral approach to intradural lesions of the cervical spine and foramen magnum. **Neurosurgery** 27 : 197-204, 1990
 25. Sen CN, Sekhar LN : The subtemporal and preauricular infratemporal approach to intradural structures ventral to the brain stem. **J Neurosurg** 73 : 345-354, 1990
 26. Stacchiotti S, Sommer J; Chordoma Global Consensus Group : Building a global consensus approach to chordoma: a position paper from the medical and patient community. **Lancet Oncol** 16 : e71-e83, 2015
 27. Stippler M, Gardner PA, Snyderman CH, Carrau RL, Prevedello DM, Kassam AB : Endoscopic endonasal approach for clival chordomas. **Neurosurgery** 64 : 268-277; discussion 277-278, 2009
 28. Tzortzidis F, Elahi F, Wright D, Natarajan SK, Sekhar LN : Patient outcome at long-term follow-up after aggressive microsurgical resection of cranial base chordomas. **Neurosurgery** 59 : 230-237; discussion 230-237, 2006
 29. Walcott BP, Nahed BV, Mohyeldin A, Coumans JV, Kahle KT, Ferreira MJ : Chordoma: current concepts, management, and future directions. **Lancet Oncol** 13 : e69-e76, 2012
 30. Zoli M, Milanese L, Bonfatti R, Faustini-Fustini M, Marucci G, Tallini G, et al. : Clival chordomas: considerations after 16 years of endoscopic endonasal surgery. **J Neurosurg** 128 : 329-338, 2018