

Delayed diagnosis of myelitis in a patient with Vogt-Koyanagi-Harada disease: a case report

Journal of International Medical Research
49(3) 1–5

© The Author(s) 2021

Article reuse guidelines:

sagepub.com/journals-permissions

DOI: 10.1177/03000605211001633

journals.sagepub.com/home/imr



Dongwoo Yu¹, Tae Uk Kim² and
Min Cheol Chang³ 

Abstract

A case of myelitis following Vogt-Koyanagi-Harada (VKH) disease is reported, in which diagnosis and treatment were delayed. A 43-year-old male patient diagnosed with VKH disease presented at the Spine Centre of Yeungnam University Hospital, Daegu, Republic of Korea, with motor weakness, sensory deficit in both lower extremities, and dysuria for the previous 3 months. VKH disease had been diagnosed 15 months previously, based on vision loss in both eyes and the presence of bilateral nontraumatic granulomatous iridocyclitis, exudates, and retinal oedema. The patient exhibited severe motor weakness (right lower extremity, Medical Research Council (MRC) muscle scale, grade 2–0; left lower extremity, MRC grade 0). On cervical magnetic resonance imaging, a high-intensity T2 signal was observed in the spinal cord C4–C7 segments. Cerebrospinal fluid analysis revealed slightly elevated white blood cell counts. The patient was diagnosed with myelitis complicating VKH disease. Intravenous and oral corticosteroid therapy was administered. After steroid treatment, the patient's motor function in the right lower extremity was significantly improved (MRC grade 4–3). However, the left lower extremity did not show any improvement (MRC grade 0). To achieve a good treatment outcome, the diagnosis and treatment of myelitis in VKH disease should not be delayed.

Keywords

Vogt-Koyanagi-Harada disease, myelitis, diagnosis, steroid, muscle weakness, vision loss, motor function

Date received: 1 February 2021; accepted: 18 February 2021

¹Department of Neurosurgery, Spine Centre, College of Medicine, Yeungnam University, Daegu, Republic of Korea

²Department of Rehabilitation Medicine, Dankook University College of Medicine, Cheonan, Republic of Korea

³Department of Physical Medicine and Rehabilitation, Spine Centre, College of Medicine, Yeungnam University, Daegu, Republic of Korea

Corresponding author:

Min Cheol Chang, Department of Physical Medicine and Rehabilitation, Spine Centre, College of Medicine, Yeungnam University 317-1, Daemyungdong, Namku, Taegu 705-717, Republic of Korea.
Email: wheel633@gmail.com



Introduction

Vogt-Koyanagi-Harada (VKH) disease is an idiopathic, multisystem autoimmune disorder affecting pigmented tissues in the ocular, auditory, skin, and central nervous systems.¹ Severe bilateral diffuse granulomatous uveitis is the most typical feature of VKH disease, which leads to a rapid loss of vision.² VKH disease is known to predominantly affect Asian and Hispanic populations.^{1,2} In addition, women are reported to be more frequently affected than men, and most patients are in the second to fifth decades of life at the onset of disease presentation.² The incidence of VKH disease varies; among all cases of uveitis, the incidence of VKH disease is approximately 1–4%, 7%, and 3% in the USA, Japan, and Brazil, respectively.² Over half of patients with VKH exhibit at least one neurological manifestation, known to be usually caused by aseptic meningitis, cranial nerve neuropathy, encephalitis, or encephalomyelitis.³ There are few reports about the occurrence of myelitis in patients with VKH disease.^{4–6} Myelitis is an inflammatory disorder of the spinal cord. Patients with myelitis show diffuse immune derangement in the spinal cord and spinal fluid.⁷ Increased production of cytokines (such as interleukin [IL]-6, tumour necrosis factor- α , and IL-1 β) following myelitis, mediates signal transduction between immune cells, and induces immune-cell growth and differentiation, leading to inflammatory reactions in the spinal cord.⁸

Inflammation in the spinal cord may cause damage to the myelin and axons, resulting in motor weakness, sensory disturbance, and autonomic dysfunction of varying degrees.⁷ In previous publications, patients with neurological deficits following myelitis were reported to have recovered well, due to the early systemic administration of corticosteroids,^{4,5} which can

suppress acute inflammation and prevent the recurrence of myelitis.⁵ However, many clinicians are unaware of VKH disease and the possibility of the occurrence of myelitis in patients with VKH disease. Hence, the diagnosis might be delayed.

Vogt-Koyanagi-Harada disease is divided into four stages: prodromic, acute uveitic, convalescent, and chronic recurrent stage.² The prodromal stage lasts for a few days. In this stage, patients present with fever, headache, nausea, vertigo, tinnitus, orbital pain, photophobia, and phonophobia. The acute uveitic stage typically occurs within 3–5 days of the prodromal stage and lasts for several weeks. In this stage, there is occurrence of exudative detachment of the neurosensory retina secondary to diffuse choroidal inflammation, and patients experience acute blurring of vision in both eyes. The convalescent stage following the acute uveitic stage is characterized by depigmentation of the integument and choroid. Vitiligo, alopecia, and poliosis may manifest. In the chronic recurrent stage, ocular complications, including cataract, glaucoma, retinal/choroidal fibrosis, and choroidal neovascularization may be observed.

The present report describes a case of myelitis following VKH disease, in which the diagnosis and treatment were delayed.

Case report

A 43-year-old male patient presented at the Spine Centre of Yeungnam University Hospital, Daegu, Republic of Korea, in August 2020, with motor weakness and sensory deficit in both lower extremities. The patient provided written informed consent for treatment and for this case report to be published, and the report was approved by the review board of Yeungnam University Hospital (approval No. 2020-10-022). This case report was produced following CARE case report guidelines.

Fifteen months prior to the hospital visit, he had developed sudden, spontaneous blurred vision in both eyes. Three months following the initial occurrence of symptoms, he developed loss of vision in both eyes. In Kyungpook University Hospital, the patient was diagnosed with VKH disease by an ophthalmologist, based on the loss of vision in both eyes, bilateral non-traumatic granulomatous iridocyclitis, presence of exudates, and retinal oedema.² Other than visual loss, he had headache, tinnitus, and vitiligo. Treatment with 60 mg oral prednisolone was initiated, and tapered over a period of 3 months. However, there was no improvement in his symptoms.

Twelve months following the initial development of symptoms (and 3 months prior to presentation at Yeungnam University Hospital), he developed sudden motor weakness with a tingling sensation and numbness in the lower extremities. Over 1 month after the initiation of motor weakness, the symptoms gradually worsened. Thereafter, the patient was unable to walk and was dependent on a wheelchair. He reported that the motor weakness had continuously deteriorated, even until prior to presenting at Yeungnam University Hospital. On physical examination and assessment of muscle power using the Medical Research Council (MRC) muscle scale (graded 0–5, where lower grade equates to increased muscle weakness), the patient was found to have severe motor weakness: right lower extremity, MRC grade 2–0; right hip flexor and knee extensor, MRC grade 2; ankle dorsiflexor, MRC grade 0; and left lower extremity, MRC grade 0. There was also a decrease in tactile sensation and perception of pain over the T7 to S5 dermatomes on both sides of the body. Deep tendon reflexes of both lower limbs were increased (3+), with presence of Babinski signs. He also had dysuria. Mentally, the patient was alert and the

Kernig's sign was absent. On the nerve conduction test, no abnormal findings suggestive of peripheral nerve lesions were observed. Visual evoked potential was also normal.

Magnetic resonance imaging (MRI) of the thoracolumbar spine and brain showed no abnormalities. On cervical MRI, a high-intensity T2 signal in the C4–C7 segments of the spinal cord was observed (Figure 1). However, gadolinium enhancement was not observed in the cervical cord. The results of routine laboratory investigations were within normal limits. Screening for connective-tissue disease, including C-reactive protein, rheumatic factor, antinuclear antibody, anti-double-stranded DNA, and anti-cardiolipin antibodies revealed normal or negative results. Analysis of the cerebrospinal fluid (CSF) revealed a slightly elevated white blood cell count of 9 cells/ μ l (normal, 0–5 cells/ μ l) with no protein elevation (31.72 mg/dl; normal, 15–45 mg/dl). A CSF bacterial culture showed negative results.

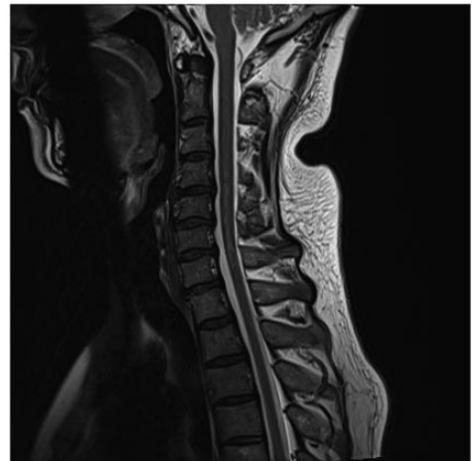


Figure 1. Representative sagittal T2-weighted magnetic resonance image of the cervical spine obtained at 3 months after the onset of myelitis symptoms, showing a high T2 signal in C4 to C7 segments of the spinal cord.

Anti-aquaporin-4 antibody was also negative. The patient was consequently diagnosed with myelitis complicating VKH disease. Pulse corticosteroid therapy was initiated (comprising 500 mg methylprednisolone, intravenously, once daily for 5 days) and a tapering course of 60 mg oral prednisolone over a 3-month period. At 7 days after the completion of intravenous steroid administration, the patient's motor function in the right lower extremity was significantly improved (right hip flexor and right knee extensor, MRC grade 4; and right ankle dorsiflexor, MRC grade 3). However, the left lower extremity did not show any improvement (MRC grade 0). Sensory disturbance persisted on both sides of the body (from the T7 to S5 dermatomes). In addition, dysuria did not improve.

At 3 months after the completion of intravenous methylprednisolone administration, the degree of motor weakness was the same as at 7 days after administration. Sensory disturbance and dysuria also persisted.

Discussion

This case report presents a case of weakness in both the lower extremities due to VKH disease-related myelitis. Evaluation of the patient and his symptoms suggests that he was in the convalescent stage of VKH disease. After treatment with corticosteroid, although the motor weakness in the left lower extremity did not recover, the right lower extremity showed good recovery. Corticosteroid therapy is the treatment of choice for myelitis,⁵ as it has anti-inflammatory and immunosuppressive properties,⁹ and reduction of inflammation by corticosteroids may prevent damage to the spinal cord. Therefore, before the spinal cord is significantly damaged, early treatment with corticosteroids should be initiated to achieve a good therapeutic response. Moreover, if motor weakness following the

spinal cord lesion is severe, the prognosis of motor recovery tends to be relatively poor.¹⁰ Thus, corticosteroids should be administered before the spinal cord is severely damaged by the inflammation, and at least before it progresses to the chronic phase of myelitis. Considering that, in the present case, motor function of the right lower extremity was preserved to some extent, the right side of the spinal cord seems to have been only partially damaged. Therefore, there was a potential for recovery of motor function in the right lower extremity following corticosteroid treatment. In contrast, the left lower extremity was completely paralyzed. Severe damage to the left side of the spinal cord, and delayed diagnosis and treatment, would have led to the poor motor recovery observed in the left lower extremity.

To the best of the authors' knowledge, there have been three previously published reports regarding the occurrence of cervical myelitis in a patient with VKH disease.⁴⁻⁶ In 2009, Dahbour et al.⁴ reported a case of acute myelitis in a 37-year-old female patient with VKH disease, who displayed mild weakness in the muscles of the right lower limb (MRC grade 4), sensory deficit, and dysuria. She was administered 500 mg intravenous methylprednisolone for 5 days, followed by a tapering course of 60 mg of prednisolone over 8 weeks. Her neurological symptoms following acute myelitis completely subsided after the treatment. In 2010, Tang et al.⁶ reported the development of myelitis in a 16-year-old female patient with VKH disease. She had mild weakness in both the lower extremities, and dysuria for 6 months. Oral prednisolone (45 mg/day) and immunosuppressive therapy with cyclophosphamide and cyclosporin A were administered (the duration of treatment was not described), and her motor weakness significantly improved; however, the urinary symptoms did not subside. In 2013, Gu et al.⁵ reported the case of a 50-year-old female patient with VKH

disease with a sudden onset of motor weakness in the lower extremity (the degree of motor weakness was not described), numbness on the left side of the body, and difficulty in urination for 6 days previously due to acute myelitis. She was administered intravenous methylprednisolone at 1 g/day for 3 days, 500 mg/day for 10 days, 250 mg/day for 10 days, and oral prednisolone for 6 months. Following treatment, her neurological symptoms significantly improved. In the reports by Dahbour et al. and Gu et al.,^{4,5} the patients had acute myelitis, and their neurological symptoms completely subsided after corticosteroid treatment. However, Tang et al.⁶ initiated treatment at 6 months following the onset of symptoms of myelitis. Poor recovery of urinary symptoms in their patient may have been due to the late initiation of corticosteroid treatment.

In the present patient, since the initiation of treatment was delayed due to the late diagnosis, inflammation in the spinal cord seems to have severely damaged the left side of the spinal cord, leading to poor treatment outcome in the left lower extremity. Considering the therapeutic outcomes described in previous case reports, early treatment of VKH disease-related myelitis with corticosteroids might result in a good improvement of neurological symptoms. Hence, clinicians should be aware of the occurrence of myelitis in patients with VHK disease, so that immediate treatment can be initiated for inflammation in the spinal cord.

Declaration of conflicting interest

The authors declare that there is no conflict of interest.

Funding

This work was supported by a National Research Foundation of Korea grant funded by the Korean government (grant No. NRF2019M3E5D1A02068106).

ORCID iD

Min Cheol Chang  <https://orcid.org/0000-0002-7629-7213>

References

1. Moorthy RS, Inomata H and Rao NA. Vogt-Koyanagi-Harada syndrome. *Surv Ophthalmol* 1995; 39: 265–292.
2. Lavezzo MM, Sakata VM, Morita C, et al. Vogt-Koyanagi-Harada disease: review of a rare autoimmune disease targeting antigens of melanocytes. *Orphanet J Rare Dis* 2016; 11: 29.
3. Smith JR and Rosenbaum JT. Neurological concomitants of uveitis. *Br J Ophthalmol* 2004; 88: 1498–1499.
4. Dahbour SS. MRI documented acute myelitis in a patient with Vogt-Koyanagi-Harada syndrome: first report. *Clin Neurol Neurosurg* 2009; 111: 200–202.
5. Gu S, Liu Y, Song Z, et al. Acute myelitis in a patient with Vogt-Koyanagi-Harada disease: case report and review of the literature. *J Clin Neurol* 2013; 9: 61–64.
6. Tang Y, Wang X, Ding Y, et al. Longitudinal lesion of the spinal cord in a patient with Vogt-Koyanagi-Harada disease. *J Neurol Neurosurg Psychiatry* 2010; 81: 941–942.
7. Kaplin AI, Deshpande DM, Scott E, et al. IL-6 induces regionally selective spinal cord injury in patients with the neuroinflammatory disorder transverse myelitis. *J Clin Invest* 2005; 115: 2731–2741.
8. Zhong XP, Shin J, Gorenlla BK, et al. Receptor signaling in immune cell development and function. *Immunol Res* 2011; 49: 109–123.
9. Coutinho AE and Chapman KE. The anti-inflammatory and immunosuppressive effects of glucocorticoids, recent developments and mechanistic insights. *Mol Cell Endocrinol* 2011; 335: 2–13.
10. Annunziata P, Masi G, Cioni C, et al. Clinical, laboratory features, and prognostic factors in adult acute transverse myelitis: an Italian multicenter study. *Neurol Sci* 2019; 40: 1383–1391.