



Arthroscopic Technique for the Treatment of Pigmented Villonodular Synovitis of the Hip

Simon Lee, M.P.H., Marc S. Haro, M.D., M.S.P.T., Andrew Riff, M.D.,
Charles A. Bush-Joseph, M.D., and Shane J. Nho, M.D., M.S.

Abstract: Open synovectomy remains the treatment of choice for pigmented villonodular synovitis (PVNS) of the hip but has shown modest results compared with the treatment of other joints. Recent advances in hip arthroscopy permit a thorough evaluation of the joint surfaces, improved access, and decreased postoperative morbidity. We describe an arthroscopic synovectomy technique for PVNS of the hip. The use of additional arthroscopic portals and creation of a large capsulotomy enable successful visualization and extensive synovectomy of the entire synovial lining of the hip. The T-capsulotomy enables extensive soft-tissue retraction for complete exposure. The midanterior portal enables use of an arthroscopic grasper and shaver to directly access and excise the synovial lining of the peripheral compartment while avoiding damage to the medial and lateral retinacular vessels. Technical innovations in hip arthroscopy have enhanced visualization in the central and peripheral compartments, as well as instrument management and diagnostic evaluation of the capsule, therefore allowing enhanced management of PVNS of the hip.

Pigmented villonodular synovitis (PVNS) is a benign, locally aggressive proliferative disorder of the synovium involving a joint, bursa, or tendon sheath.¹ It is characterized by exuberant proliferation of synovium, and although its etiology is unknown, it shows characteristics consistent with a neoplastic process.² PVNS most commonly affects individuals aged 20 to 40 years; the gender distribution of this disease is uncertain, with reports in the literature ranging from a 2:1 male-female ratio to a slight female predominance.³ It has a predilection for large joints, with the knee involved in up to 80% of cases and the hip involved in 15% of cases, followed by the shoulder and ankle.⁴ PVNS may occur in either a diffuse or a localized form; diffuse PVNS and localized PVNS are histologically identical but have very different clinical presentations. In the hip the disease typically presents as

the diffuse villonodular type, but the localized type has also been reported.

Treatment Options

Treatment of PVNS typically involves early surgical resection to limit articular destruction and the potential for recurrence. Open synovectomy remains the treatment of choice for PVNS of the hip,⁴ but it has shown modest results compared with the treatment of other joints. Mankin et al.⁵ reported that 11 of 12 patients (92%) with hip PVNS required eventual total hip arthroplasty because of extensive joint damage. Similarly, Vastel et al.⁴ reported high rates of revision surgery, osteoarthritis progression, and arthroplasty. Adjuvant external beam radiation and intra-articular radioisotope injection also have been proposed with promising results for specific indications.

Arthroscopy is widely used to treat PVNS of the knee and ankle, and it has been postulated that hip arthroscopy can provide successful treatment with less morbidity compared with open procedures. Hip arthroscopy is still in relative nascency; therefore there is a steep learning curve to obtain the appropriate exposure with arthroscopy. However, recent advances in the technique have permitted a thorough evaluation of the joint surfaces, improved access for synovectomy, and decreased postoperative morbidity. In a cohort of 32 patients with PVNS of the hip, Chen et al.⁶ showed significant improvement in hip function and only 2

From Rush University Medical Center, Chicago, Illinois, U.S.A.

The authors report the following potential conflict of interest or source of funding: S.J.N. receives support from Össur, Stryker, AlloSource, Arthrex, Athletico, DJ Orthopaedics, Linvatec, Miomed, Smith & Nephew.

Received July 3, 2014; accepted November 5, 2014.

Address correspondence to Shane J. Nho, M.D., M.S., Hip Preservation Center, Division of Sports Medicine, Department of Orthopedic Surgery, Rush University Medical Center, Rush Medical College of Rush University, 1611 W Harrison St, Ste 300, Chicago, IL 60612, U.S.A. E-mail: Shane.Nho@rushortho.com

© 2015 by the Arthroscopy Association of North America. Open access under CC BY-NC-ND license.

2212-6287/14554

<http://dx.doi.org/10.1016/j.eats.2014.11.003>

Table 1. Pearls and Pitfalls for Arthroscopic Treatment of PVNS of Hip

	Pearls	Pitfalls
Imaging	Plain radiographs may show soft tissue, as well as juxta-articular erosions with sclerotic margins and subchondral cyst formation. MRI generally shows low signal intensity on both T1- and T2-weighted sequences because of the high lipid content and hemosiderin deposition. Characteristic MRI findings include synovial hyperplasia with thick fibrous tissue, bony erosions, and preserved bone density and joint space.	The joint space is typically spared, and osteophytes or periarticular osteopenia is typically absent in early disease.
Preoperative assessment	Localized PVNS is often more episodic with asymptomatic intervals. Diffuse PVNS presents slowly and gradually, with insidious pain, swelling, and stiffness ranging in duration from months to years. During exacerbations, patients often maintain the hip in a flexed and externally rotated position to maximize capsular volume and minimize intra-articular pressure.	Diffuse PVNS and/or extensive posterior capsular disease may be too extensive at the time of clinical presentation to be treated sufficiently with hip arthroscopy and may indicate open debridement.
Intraoperative management	Adequate exposure is needed for thorough debridement. Careful patient positioning and traction should be used to allow for 1 cm of joint distraction. Accurate portal placement is essential to allow for thorough evaluation of the joint. A T-capsulotomy allows for improved visualization of the central and peripheral compartments. The use of switching sticks as arthroscopic retractors improves visualization of the joint. Excessive debridement of the capsule should be avoided to allow for complete capsular closure.	Inaccurate portal placement makes joint evaluation and debridement difficult or impossible. Overly aggressive capsular debridement/capsulectomy may cause capsular closure to be difficult, impossible, or overly tensioned. Poor capsular closure can lead to iatrogenic instability. Overly tensioned closure can lead to postoperative hip stiffness.
Postoperative rehabilitation		Prevent hip extension or external rotation because it may over-stress the capsular repair.

MRI, magnetic resonance imaging; PVNS, pigmented villonodular synovitis.

recurrences of disease. Similarly, Byrd et al.⁷ showed a significant increase of 27 points in modified Harris Hip Scores with no complications at 63 months in patients undergoing arthroscopic management for PVNS of the hip. In a recent long-term outcome analysis, arthroscopic treatment resulted in lower PVNS recurrence rates across all joints, mostly because of better joint visualization for tumor eradication.⁴ The purpose of this article is to describe an arthroscopic technique for treating PVNS of the hip ([Video 1](#), [Tables 1 and 2](#)).

Arthroscopic Surgical Technique

At our institution, the patient is placed in the supine position and general endotracheal anesthesia is initiated. Well-padded boots and an offset padded perineal post are placed. A sequential compression device is placed on the nonsurgical side, and preoperative antibiotics are administered before incision. Gentle traction in neutral extension using adduction maneuvers of the operative hip is applied until 1 cm of joint distraction is achieved, which is verified fluoroscopically (Hip Positioning System; Smith & Nephew, London, England).

The surgical area is subsequently prepared and draped in the standard surgical fashion.

Three portals are used for this procedure: anterolateral, midanterior, and distal anterolateral accessory (DALA) portals. These portals are created in standard fashion using cannulated instruments (spinal needle, guidewire, and metal trocars). Typically, the anterolateral portal is the viewing portal and the DALA portal is the working portal. Initially, an anterolateral portal is created under fluoroscopic guidance. The tip of the greater trochanter is identified, and an anterolateral portal is established approximately 1 cm anterior and 1 cm proximal to the anterior aspect of the greater trochanter. A spinal needle is introduced into the central compartment, followed by a guidewire and 4.5-mm metal cannula. By use of a 70° arthroscope (Stryker, Kalamazoo, MI) through this initial portal, a midanterior portal is created under direct visualization over the vastus ridge, and an arthroscopic shaver is introduced through this portal. Visual inspection of the central compartment should be performed before arthrotomy to determine the presence or absence of

Table 2. Surgical Steps in Arthroscopic Technique for Treatment of PVNS of Hip

1. Position the patient supine with well-padded boots and an offset padded perineal post.
2. Apply gentle traction in neutral extension using adduction maneuvers until 1 cm of joint distraction is achieved (verified fluoroscopically).
3. Establish the anterolateral, midanterior, and distal anterolateral accessory portals.
4. Perform interportal capsulotomy, followed by diagnostic arthroscopy.
5. Perform a thorough synovectomy within the central compartment of the hip.
6. Perform a T-capsulotomy perpendicular to the midpoint of the interportal capsulotomy, extending distally approximately 4 cm.
7. Passively articulate the hip joint to gain better circumferential access around the femoral head and neck.
8. Perform a thorough synovectomy within the peripheral compartment of the hip.
9. Address any coexisting intra-articular hip pathology, such as femoroacetabular impingement deformities.
10. Completely close the T-capsulotomy and interportal capsulotomy.

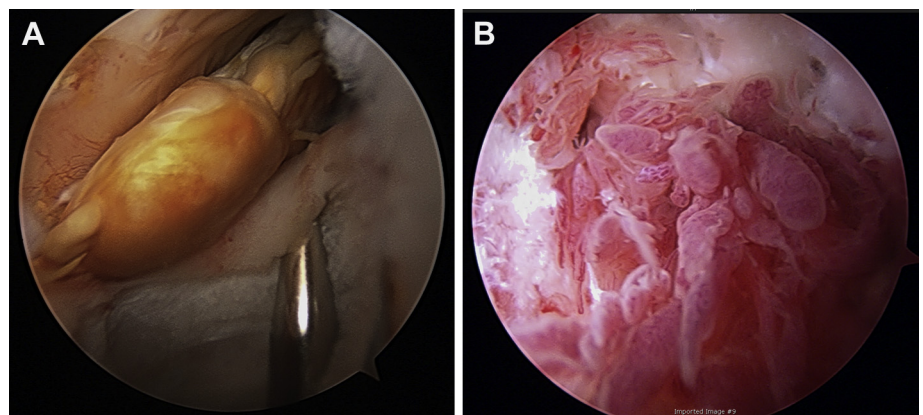
PVNS within the intra-articular space. An interportal arthrotomy using an arthroscopic scalpel (Samurai Blade; Pivot Medical, Sunnyvale, CA) between these first 2 portals is then performed with the use of a midanterior portal to gain access to the central compartment. The length of the incision will depend on whether the disease is focal or diffuse (longer for diffuse PVNS). The DALA portal is then established 4 cm distal to the anterolateral portal for instrumentation.

Diagnostic arthroscopy is performed to characterize the extent of disease. The tumor may appear as a discrete mass (Fig 1A) or as a more diffuse villonodular synovitis (Fig 1B). If focal PVNS is identified within the central compartment, the mass can be retrieved with a Wishbone handle tissue grasper (Arthrex, Naples, FL) and removed from the field as a specimen. If diffuse PVNS is found, a 4.0-mm arthroscopic suction shaver (Tomcat; Stryker) may be used to perform a synovectomy in the perilabral areas (Fig 2). With placement of

the 70° arthroscope in the midanterior portal, the pulvinar can be inspected to ensure that there is no evidence of diffuse PVNS that requires excision. Once the central compartment has been thoroughly inspected, a T-capsulotomy may be performed with an arthroscopic scalpel (Samurai Blade) to achieve better visualization and access to the peripheral compartment of the hip. With the arthroscope in the midanterior portal, traction can be released and the hip can be flexed to approximately 30°. A spinal needle, followed by a 5.0-mm metal cannula, may be placed in the DALA portal, which is 4 cm distal to and in line with the anterolateral portal. The T-capsulotomy is performed at the midpoint of the interportal capsulotomy and continued perpendicularly through the iliofemoral ligament to the intertrochanteric line, extending approximately 4 cm (Fig 3). A Wissinger rod is then placed through the anterolateral portal to retract the lateral leaflet of the iliofemoral ligament so that the entire synovial lining of the joint capsule can be visualized. By use of the DALA portal, the villonodular synovium is thoroughly debrided with a 4.0-mm suction shaver and tissue grasper (Fig 4). The T-capsular arthrotomy increases the mobility of the arthroscopic instruments, enabling the surgeon to reach the pathologic areas of PVNS within a wide range at least 180° and in most cases approximately 270° around the femoral head and neck (Fig 5). The extensile exposure in conjunction with manipulative articulation of the hip joint allows the surgeon optimal exposure of the synovial lining, and areas of synovitis that are otherwise inaccessible are readily visualized and debrided. If additional soft-tissue pathology, such as labral damage, is identified, repair, debridement, or reconstruction may be performed in the same setting. In addition, if abnormal osseous morphology, such as femoroacetabular impingement, is found, acetabular rim trimming or femoral osteochondroplasty may be performed.

Once all the procedures have been performed, it is imperative that a complete capsular closure be

Fig 1. Representative arthroscopic images of (A) localized and (B) diffuse pigmented villonodular synovitis of hip.



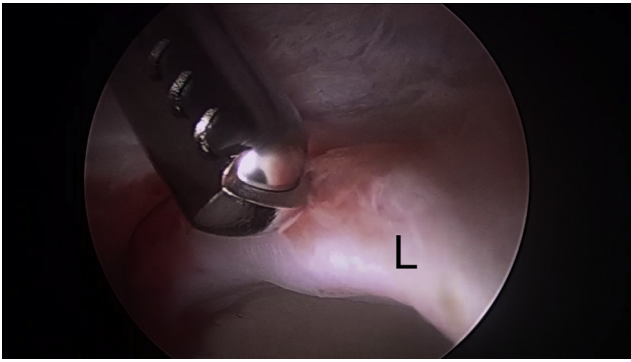


Fig 2. Debridement of a left-sided pigmented villonodular synovitis of the hip in the central compartment through the distal anterolateral accessory portal with an arthroscopic suction shaver. (L, labrum.)

performed. Our preference is to use a 2-portal technique with an 8.25 × 90-mm cannula in the anterolateral portal and an 8.25 × 110-mm cannula in the DALA portal. By use of a suture shuttling device (Spectrum; Linvatec, Largo, FL) through the lateral leaflet of the iliofemoral ligament through the anterolateral portal and a tissue penetrator through the medial leaflet of the iliofemoral ligament through the DALA portal, No. 2-0 nonabsorbable high-strength sutures are used to fully repair the vertical portion of the T-capsulotomy. The

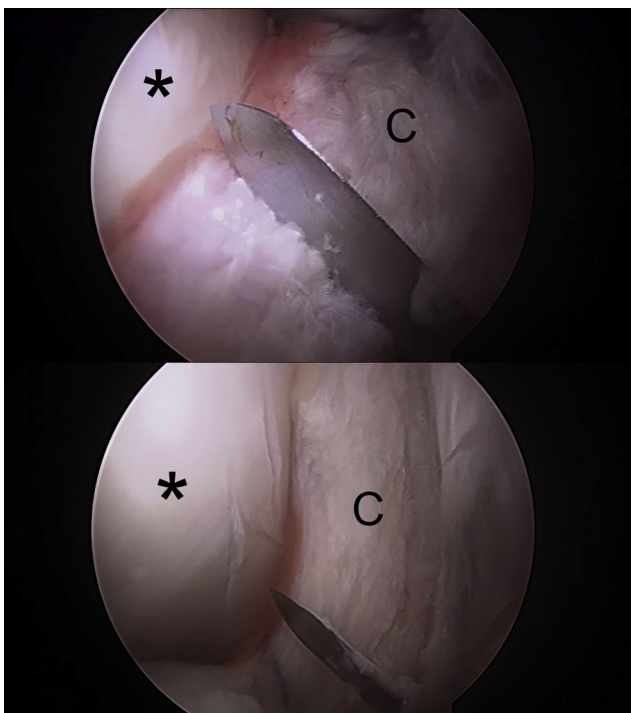


Fig 3. T-capsulotomy performed with arthroscopic blade. The incision is made perpendicular from the midpoint of the interportal capsulotomy and extended approximately 4 cm distally. The asterisks indicate the position of the femoral head. (C, hip capsule.)

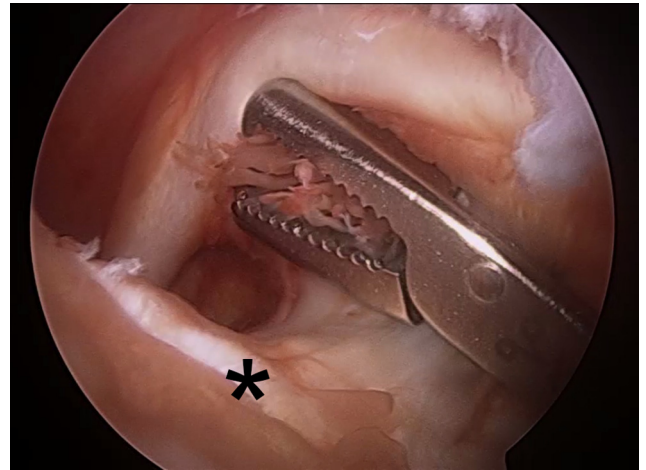


Fig 4. Debridement of a left-sided pigmented villonodular synovitis of the hip in the peripheral compartment through the distal anterolateral accessory portal with an arthroscopic grasper. The asterisk indicates the position of the femoral head.

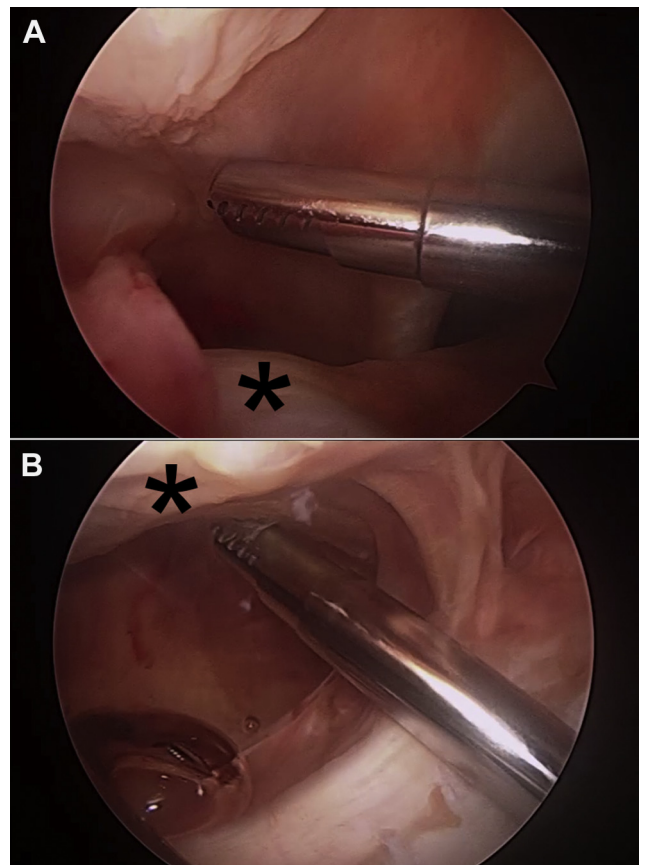
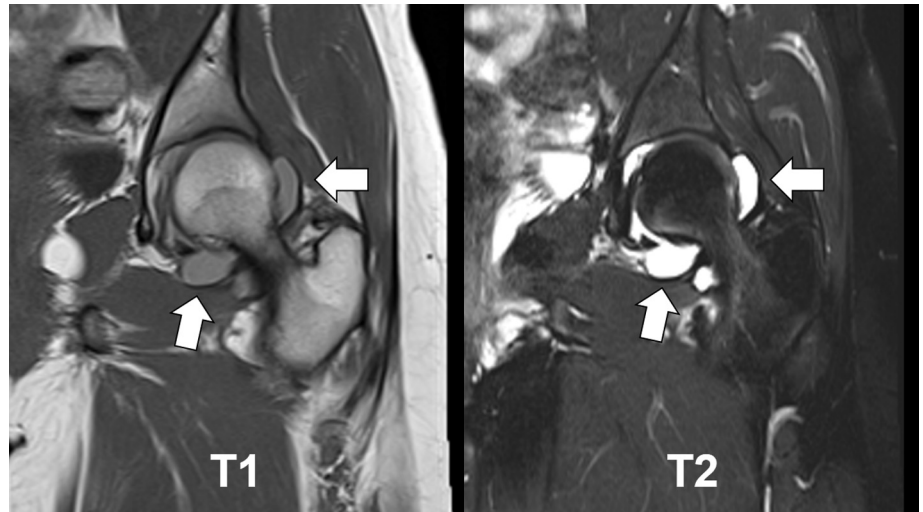


Fig 5. T-capsular arthrotomy increases the mobility of the arthroscopic instruments, enabling the surgeon to reach pathologic areas of pigmented villonodular synovitis within a wide range at least 180° and in most cases approximately 270° around the femoral head and neck. (A) Arthroscopic shaver superior to femoral neck. (B) Arthroscopic shaver inferior to femoral neck. The asterisks indicate the position of the femoral head.

Fig 6. T1- and T2-weighted coronal magnetic resonance images of a left-sided pigmented villonodular synovitis (PVNS) lesion of the hip. The structure of the lesion is clearly defined on the T1-weighted image, whereas the high lipid and hemosiderin content of the lesion appears hyperintense on the T2-weighted image. The arrows indicate areas of PVNS.



interportal capsulotomy is repaired with a capsular closure device (InJector; Stryker) to completely close the capsulotomy. Vicryl No. 3-0 sutures (Ethicon, Somerville, NJ) followed by No. 2-0 Prolene (Ethicon) are used to close the subcutaneous tissue in a layered fashion. Finally, all portals are irrigated and closed with nylon sutures and sterile bandages are applied.

Discussion

One of the foremost challenges of hip arthroscopy, particularly important in the setting of tumor excision, is obtaining adequate exposure. However, recent technical innovations have improved arthroscopic visualization. Specifically, the use of additional arthroscopic portals and creation of large capsulotomies enable successful visualization and resection of hip synovial proliferative disease. The T-capsulotomy enables extensive soft-tissue retraction for comprehensive exposure. Furthermore, the midanterior portal enables use of an arthroscopic grasper and shaver to directly access and excise the areas of pathology while avoiding damage to local neurovascular structures. In this way, technical innovations in hip arthroscopy have enhanced intracapsular visualization, as well as instrument management and diagnostic evaluation of the synovium. These improvements have been reflected in a recent systematic review that showed decreasing morbidity and complications in hip arthroscopy.⁸

Literature on PVNS in the hip is sparse and primarily comprises case reports. Byrd et al.⁷ recently published the largest clinical case series on arthroscopic management of PVNS of the hip in 13 patients with a mean follow-up period of 63 months. They reported favorable outcomes in this cohort and reported that the mean improvement in the modified Harris Hip Score was 27 points, with a range from 3 to 56 points, with similar improvement in patients with localized disease and those with diffuse disease.

Although arthroscopic management of PVNS has many advantages, caution must be exercised when deciding between arthroscopic and open excision of diffuse PVNS of the hip. Tumors in harder-to-access areas, such as the posterior capsule, may be best addressed with an open excision depending on the surgeon's level of expertise with hip arthroscopy. In addition, the recurrence rate for PVNS in any joint is variable and has been reported to be as high as 60%. Recurrence after the index surgery remains a primary complication, especially in large joints and for the diffuse type of PVNS.⁹ However, studies on the recurrence rate in the hip are lacking. Vastel et al.⁴ reported only 1 recurrence in a cohort of 16 patients undergoing complete hip synovectomy for PVNS; however, they also found a high incidence of secondary osteoarthritis.

PVNS of the hip is an uncommon pathology of the hip; however, it may be very locally destructive if present. Symptoms can usually be vague and insidious, prompting a high index of clinical suspicion. Diagnosis is typically suspected based on plain radiographs and magnetic resonance imaging findings and ultimately confirmed with biopsy (Fig 6). Arthroscopic management of hip PVNS has shown positive results, but caution must be used when selecting the appropriate patients for the procedure. PVNS, especially the diffuse variety, may be too extensive at the time of clinical presentation to be treated sufficiently with hip arthroscopy. For these patients, open synovectomy remains the treatment of choice. Further work is required to better characterize the arthroscopic treatment of PVNS within the hip.

References

1. Jaffe H, Lichtenstein L, Sutro C. Pigmented villonodular synovitis, bursitis and tenosynovitis. *Arch Pathol* 1941;31: 731-765.

2. Sciot R, Rosai J, Dal Cin P, et al. Analysis of 35 cases of localized and diffuse tenosynovial giant cell tumor: A report from the Chromosomes and Morphology (CHAMP) study group. *Mod Pathol* 1999;12:576-579.
3. Kallas KM, Vaughan L, Haghighi P, Resnick D. Pigmented villonodular synovitis of the hip presenting as a retroperitoneal mass. *Skeletal Radiol* 2001;30:469-474.
4. Vastel L, Lambert P, De Pinieux G, Charrois O, Kerboull M, Courpied J-P. Surgical treatment of pigmented villonodular synovitis of the hip. *J Bone Joint Surg Am* 2005;87:1019-1024.
5. Mankin H, Trahan C, Hornicek F. Pigmented villonodular synovitis of joints. *J Surg Oncol* 2011;103:386-389.
6. Chen J, Chen S, Wu Z, Li H. Arthroscopic synovectomy and synoviorthesis for pigmented villonodular synovitis in hip. *Arthroscopy* 2013;29:e124 (suppl, abstr).
7. Byrd JWT, Jones KS, Maiers GP II. Two to 10 years' follow-up of arthroscopic management of pigmented villonodular synovitis in the hip: A case series. *Arthroscopy* 2013;29:1783-1787.
8. Harris JD, McCormick FM, Abrams GD, et al. Complications and reoperations during and after hip arthroscopy: A systematic review of 92 studies and more than 6,000 patients. *Arthroscopy* 2013;29:589-595.
9. Sharma V, Cheng EY. Outcomes after excision of pigmented villonodular synovitis of the knee. *Clin Orthop Relat Res* 2009;467:2852-2858.