



# Arthroscopic Technique for Bone Augmentation With Suture Button Fixation for Anterior Shoulder Instability

Jeffrey D. Hassebrock, M.D., Julianna R. Starkweather, B.S., and John M. Tokish, M.D.

**Abstract:** Glenoid bone loss remains a significant risk factor for recurrent instability after shoulder dislocation. Several options exist for glenoid bone graft augmentation, including autograft and allograft options. Strengths and weaknesses exist for each. Graft fixation with screws remains a key concern for technical viability requiring a medial portal as well as the risk of graft osteolysis. Suture button suspensory fixation is a new technique recently described for arthroscopic iliac crest bone graft; however, no description exists concerning osteochondral graft fixation. We describe an arthroscopic technique for distal tibial allograft glenoid augmentation with suspensory suture button fixation. The rationale and technical aspects of this procedure are discussed.

**G**lenoid bone loss remains a key risk factor for recurrent shoulder instability after dislocation.<sup>1-5</sup> Previous literature has examined critically the amount of bone loss required to increase risk of instability; however, it is widely accepted that bone loss exceeding 15% to 20% increases risk for recurrence significantly.<sup>2,4,6-8</sup> Because of the increased risk for recurrent instability, many techniques have been described to augment bone loss and thus decrease recurrent instability risk including the Latarjet, coracoid transfers, iliac crest bone graft, distal clavicle osteochondral autograft, and the Bristow.<sup>5,9-15</sup> Most of these have been described being fixed with screws, which presents a unique set of challenges. Technically, because screws require perpendicular

placement, they are difficult to place arthroscopically, and, when done, must be placed far medially in proximity to the brachial plexus.<sup>16</sup> In addition, because bone osteolysis has been described, especially around the superior screw, painful hardware can result.<sup>17-23</sup> These open techniques are not without complication, and more recent arthroscopic techniques to augment bone loss have been described.<sup>21,24-30</sup> Despite the advent of these techniques, difficulty with fixation arthroscopically remains a concern.<sup>21,31,32</sup> Fixation using suspensory cortical buttons has recently been described for the Bristow procedure and may be an attractive alternative to eliminate the complications associated with screw fixation.<sup>16,31,33</sup>

Recently, the literature has reported suspensory fixation using iliac crest autograft; however, we discuss a technique for arthroscopic distal tibia allograft osteochondral fixation using suture button device.<sup>33</sup> The purpose of this technique is to describe the rationale and technical considerations behind the technique of osteochondral bone grafting of glenoid bone defects using a simple arthroscopic technique with suspensory fixation. The advantage of this technique is that it delivers an osteochondral source arthroscopically using similar techniques and instrumentation that the arthroscopic surgeon is already familiar with. In addition, because the graft can be delivered through standard anterior portals, the risk and technical difficulty with working medial to the coracoid or splitting the subscapularis are completely avoided.

From the Department of Orthopedics (J.D.H., J.M.T.), Mayo Clinic, Phoenix, Arizona, U.S.A.; and University of Arizona (J.S.), Tucson, Arizona, U.S.A.

The authors report the following potential conflicts of interest or sources of funding: J.M.T. is a consultant for Arthrex, outside the submitted work. Full ICMJE author disclosure forms are available for this article online, as [supplementary material](#).

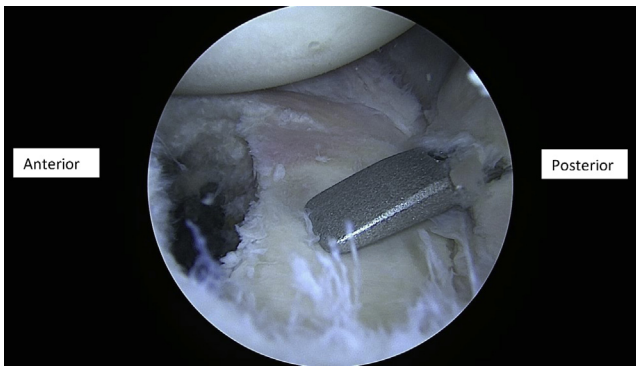
Received July 24, 2019; accepted September 2, 2019.

Address correspondence to Jeffrey D. Hassebrock, M.D., Department of Orthopedics, Mayo Clinic, 5777 East Mayo Blvd, Phoenix, AZ 85054 U.S.A. E-mail: [Hassebrock.jeffrey@mayo.edu](mailto:Hassebrock.jeffrey@mayo.edu)

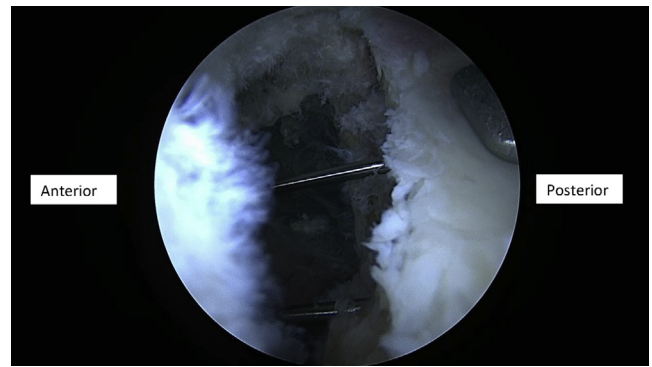
© 2019 by the Arthroscopy Association of North America. Published by Elsevier. This is an open access article under the CC BY-NC-ND license (<http://creativecommons.org/licenses/by-nc-nd/4.0/>).

2212-6287/19923

<https://doi.org/10.1016/j.eats.2019.09.016>



**Fig 1.** Intraarticular measurement and confirmation of glenoid bone loss through the posterior portal as viewed from the anterosuperior portal.



**Fig 3.** Visualization of the glenohumeral joint through the anterosuperior portal of 2 k-wires drilled from posterior to anterior.

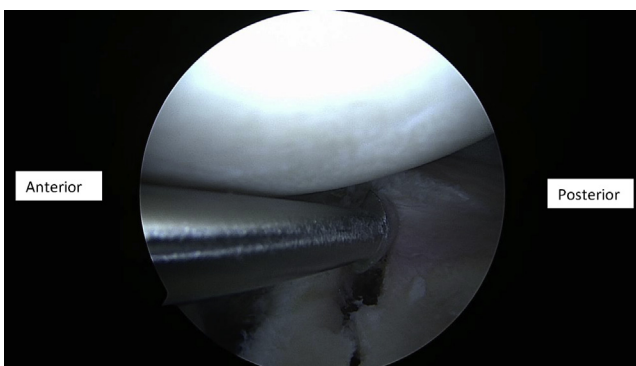
## Surgical Technique

### Step 1: Preoperative Workup

Patients who present with glenohumeral instability undergo a standardized workup including a detailed history and physical as well as advanced imaging to critically assess soft tissues and glenoid bone loss. The exact degree of glenoid bone loss is calculated in each patient and, in conjunction with history and physical examination, used to determine eligibility for the outlined procedure. Bone loss of 20% is a relative indication for a bone augmentation procedure.

### Step 2: Positioning

After examination under general anesthesia in the operating theater, the patient is positioned in the lateral decubitus position using a bean bag. The arm is held in position as is standard at our institution, with a padded arm sleeve and traction device with a lateral distractor (STAR sleeve; Arthrex, Naples, FL). Standard portals are established including the posterior portal (1-cm medial and 2-cm distal to the posterolateral acromial border) and the anterosuperior and mid-glenoid portals.<sup>1</sup> The arthroscope is inserted posteriorly after

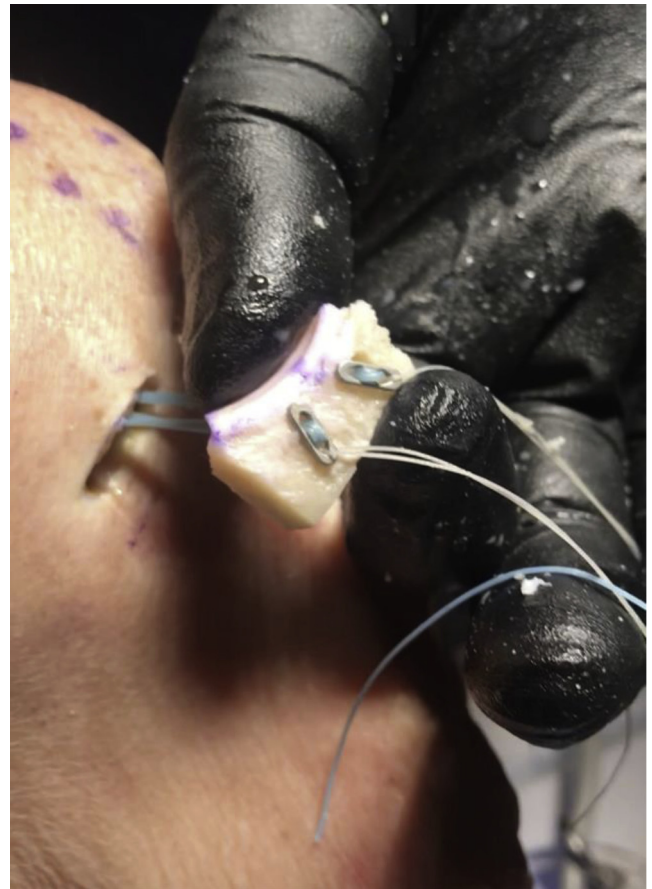


**Fig 2.** Aggressive labral elevation from anterior glenoid through the mid-glenoid portal as viewed from the anterosuperior portal.

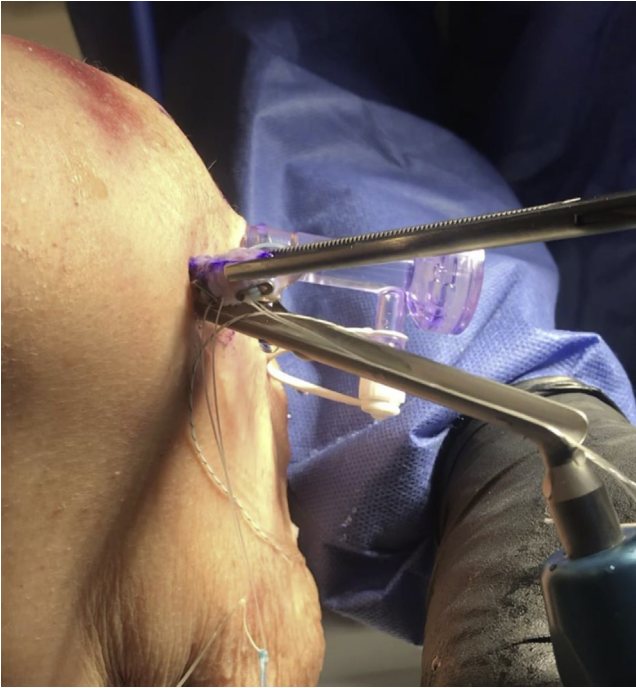creation of the posterior portal and the remaining portals are established under direct visualization using an outside-in technique.

### Step 3: Diagnostic Arthroscopy, Biologic/Fixation Preparation

In sequential order, a diagnostic arthroscopy is performed to confirm previously diagnosed pathology.

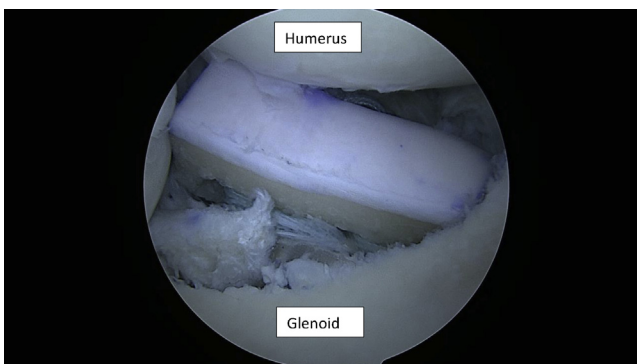


**Fig 4.** Deployment of suture buttons external to mid-glenoid portal in preparation of graft passage.



**Fig 5.** Delivery of graft through mid-glenoid portal using a clamp anteriorly and gradual tension removing slack on the suture construct posteriorly.

Attention is then turned to the area of bone loss visualized on imaging preoperatively. The arthroscope is removed from the posterior portal and inserted anteriorly while a probe is placed under visualization through the posterior portal and intraarticular measurements are taken to confirm bone loss exceeding 20% (Fig 1). After confirmation of bone loss and documentation, aggressive labral and capsular liberation is undertaken (Fig 2). The anterior glenoid surface is prepared down to viable bone with the goal of creating a flush surface for graft placement. Particular care is taken to ensure sufficient room for graft fixation within the raised labrum.



**Fig 6.** Visualization of intraarticular graft delivery as viewed from posterior portal. Gross tension on suture construct posteriorly roughly aligns graft to anterior glenoid surface.

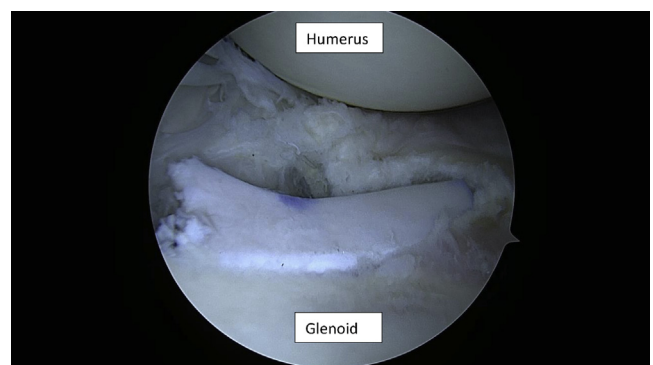
Next, a spinal needle is used to localize posteriorly so that, when placed, the drill guide will come perpendicular to the desired position of the graft. An Arthrex Latarjet guide (4- to 6-mm offset) is placed through an enlarged skin incision posteriorly at the level of the equator. This should fit flush on the anterior glenoid prepared surface and perpendicular to desired graft position. Next, with the arthroscope in the anterosuperior portal, 2 k-wires are drilled through the guide in the back and visualized emerging through the front of the glenoid (Fig 3). These k-wires may remain in place while attention is turned to graft preparation.

#### Step 4: Graft Preparation

The distal tibial allograft is a versatile graft and carries with it the significant advantage of a chondral component. The osteochondral allograft is cut to the appropriate size based off of preoperative imaging calculations as well as intraoperative confirmation (in most cases, 7- to 8 mm is sufficient to restore approximately 30% of bone loss).<sup>1,8</sup> The same arthroscopic drill guide is used to create 2 identical tunnels through the allograft to ensure exactly analogous holes to the graft's glenoid counterpart both in terms of depth from the articular surface and distance apart. Next, using the lead suture, the buttons are passed through the bone graft outside of the shoulder and deployed (Fig 4) so that they are in the fixed or "flipped position."

#### Step 5: Graft Delivery and Fixation

A cannulated drill is passed over the k-wires remaining in the glenoid from step 3 to create tunnels for the suspensory fixation. The cannulated drill can then be removed and FiberStick red tubes are inserted over the k-wires to ensure proper positioning. The wires are then removed, leaving the tubes behind and the FiberStick sutures are used to go through these drill holes in the glenoid. The sutures can be retrieved through the mid-glenoid portal for management.



**Fig 7.** Visualization intraarticularly of the final positioning of graft with appropriate tensioning creating a congruent osteochondral construct with overlying labrum before labral reapproximation.



**Table 1.** Advantages and Disadvantages of Common Glenoid Bone Grafts

	Advantages	Disadvantages
Iliac crest autograft	Anatomic restoration of contouring, incorporation, availability, cost	No chondral surface, donor site morbidity risk
Distal clavicle autograft	Osteochondral, availability, incorporation, cost	Donor site morbidity, prior acromioclavicular arthritis is a limiting factor
Latarjet/Bristow coracoid transfers	Availability, cost, sling effect	Nonanatomic solution, technically challenging, no chondral surface
Distal tibial allograft	Osteochondral, restoration of contouring, no donor site morbidity	Incorporation, cost, availability

Next, the posterior suture is attached to the Arthrex mini-tightrope. Pulling from the front delivers the button through the glenoid and out the midglenoid portal. This process is repeated for the superior tunnel. Next, the graft is delivered through the rotator interval. This is achieved by use of a large clamp to assist the graft passage through rotator interval (Fig 5). While the graft is being passed, slack is removed by pulling the construct posteriorly to deliver the graft into the joint free of suture tangles. Using a combination of arthroscopic grasper through the mid-glenoid portal as well as variable tension on superior and inferior sutures posteriorly allows for gross alignment of the graft to the prepared anterior glenoid surface (Fig 6). Fine-tuned placement of the graft can be accomplished while holding manual tension on the sutures posteriorly. Once the graft is in position, the mini-tightropes are tensioned sequentially to eliminate any gaps between the graft and the native glenoid (Fig 7). Five half hitches under tension are tied posteriorly to ensure no slippage of the graft once tightened.

### Step 6: Labral Restoration

Now that the graft is firmly fixed in place, attention is turned to restoration of the labrum over the osteochondral allograft surface. Suture anchors can be added to restore the normal labral junction above and below the graft. Additionally, extra sutures may be left in the buttons themselves to allow incorporation of the labrum against the graft. After restoration, all

arthroscopic instruments are removed and the skin is closed and dressed sterilely.

### Step 7: Rehabilitation Protocol

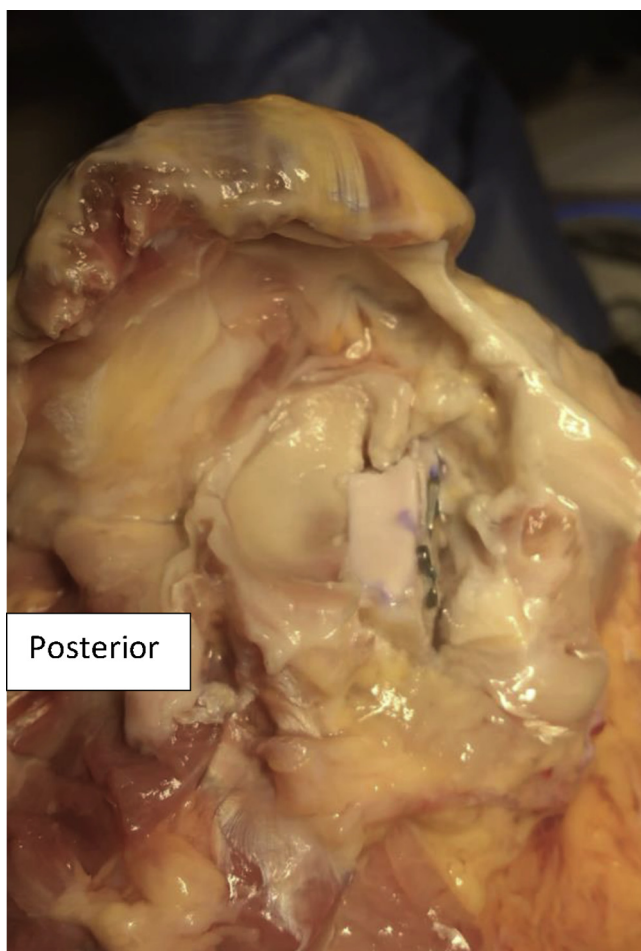
Patients are placed in standard Latarjet protocol for our institution, which includes a neutral rotation sling for 6 weeks. Patients may come out of the sling to begin pendulum movements immediately with graduation to passive motion at 3 weeks. At 8 weeks, follow-up imaging is obtained, and our goal is for complete range of motion to be restored at this time. If graft incorporation on imaging is observed, active range of motion is begun. Strengthening is added at 16 weeks postoperatively and full activity return is 6 months postoperatively after final radiographs are obtained.

### Discussion

Glenoid bone loss remains a key factor in determining the overall risk of shoulder instability recurrence after dislocation.<sup>2-5</sup> Bone loss exceeding 15% to 20% has been shown to significantly increase risk of recurrent shoulder instability after surgical fixation if not addressed.<sup>5,7,8</sup> Several open and arthroscopic options for glenoid bone graft augmentation exist, each with certain benefits and disadvantages.<sup>2,5,7,9</sup> However, the ideal graft for the treatment of shoulder instability secondary to bone loss would be osteochondral, autograft, amenable to arthroscopic placement, affordable, minimally morbid, and technically feasible/reproducible.

**Table 2.** Pearls and Pitfalls of Arthroscopic Suture Button Fixation of Distal Tibial Allograft for Shoulder Instability

Pearls	Pitfalls
<ul style="list-style-type: none"> <li>- Obtain a sufficiently wide exposure.</li> <li>- Use a spinal needle to localize where to place the graft (standard portal may be too low).</li> <li>- View from the anterosuperior portal when drilling from the back; may use a curette to protect the wires from inadvertently advancing during drilling.</li> <li>- Use the same drill guide for the glenoid and for the graft to ensure proper matching and alignment.</li> <li>- Use handheld tensioners to apply generous pressure to ensure graft conformity.</li> </ul>	<ul style="list-style-type: none"> <li>- Avoid inadequate exposure of the glenoid and labrum. Failure to expose or properly prepare the native bone will result in difficult graft placement and inadequate conformity.</li> <li>- Avoid inadequate opening of the rotator interval otherwise the graft will be difficult to pass.</li> <li>- Make sure to properly localize the position of the posterior drill guide, it should be perpendicular to the defect and placed at the center of the defect (superior/inferior).</li> <li>- Failure to manage sutures may result in a tangle and prevent graft passage.</li> <li>- Failure to appropriately tension the graft may result in poor congruity of the construct.</li> </ul>



**Fig 8.** Cadaveric dissection after arthroscopic procedure demonstrating solid fixation of osteochondral allograft with suture button fixation.

Of the most commonly described arthroscopic techniques in the literature (Latarjet, iliac crest autograft, distal tibial allograft, and distal clavicular autograft), each has significant benefits and drawbacks to consider (Table 1).<sup>15,24,27,33</sup> Specifically, prior work has demonstrated the neurologic involvement of the Latarjet procedure, and arthroscopic screw fixation of bone graft often requires a far medial portal theoretically placing neurovascular structures at increased risk.<sup>34-36</sup> Although clinical risk of true neurologic injury remains low, screw fixation of bone graft also carries the risk of graft osteolysis, cut out, and symptomatic hardware.<sup>16,17,19,23,26</sup>

Suspensory fixation has been described previously in the literature through an open technique as an alternative to screw fixation of with a similar biomechanical strength.<sup>16,31</sup> Recently, Kalogrianitis et al.<sup>33</sup> described an arthroscopic technique of iliac crest autograft bone augmentation with suspensory suture button fixation. However, the limitations of this graft include the lack of a chondral surface and significant donor site

morbidity.<sup>15,37,38</sup> We consider the proposed technique to have several advantages when compared with other common bone-restoring procedures (Table 1).

The goal of this paper was to describe a reproducible technique for the arthroscopic placement and suture button fixation of an osteochondral graft while also outlining its limitations (Table 2). The technique details distal tibial allograft fixation (Fig 8). However, the technique of suture button fixation may be applicable for other types of graft fixation per the surgeon's preference such as distal clavicular osteochondral fixation as well (Video 1). The benefits of this technique are stable fixation without risk of graft osteolysis from screws and avoidance of a far medial portal placement. The limitations include its technical difficulty, as well as the limitations of the graft choice (incorporation of allograft and cost). Future studies will need to look at clinical outcomes of suspensory fixation to validate initial promising biomechanical reports. The authors would consider an open Latarjet procedure as a salvage option in the case of a failed bone block.

## References

1. Tokish JM, Fitzpatrick K, Cook JB, Mallon WJ. Arthroscopic distal clavicular autograft for treating shoulder instability with glenoid bone loss. *Arthrosc Techn* 2014;3:e475-e481.
2. Burkhart SS, De Beer JF. Traumatic glenohumeral bone defects and their relationship to failure of arthroscopic Bankart repairs: Significance of the inverted-pear glenoid and the humeral engaging Hill-Sachs lesion. *Arthroscopy* 2000;16:677-694.
3. Boileau P, Villalba M, Héry J-Y, Balg F, Ahrens P, Neyton L. Risk factors for recurrence of shoulder instability after arthroscopic Bankart repair. *J Bone Joint Surg Am* 2006;9:1755-1763.
4. Mologne TS, Provencher MT, Menzel KA, Vachon TA, Dewing CB. Arthroscopic stabilization in patients with an inverted pear glenoid: Results in patients with bone loss of the anterior glenoid. *Am J Sports Med* 2007;35:1276-1283.
5. Provencher CMT, Bhatia S, Ghodadra NS, et al. Recurrent shoulder instability: current concepts for evaluation and management of glenoid bone loss. *J Bone Joint Surg Am* 2010;92:133-151 (Suppl 2).
6. Piasecki DP, Verma NN, Romeo AA, Levine WN, Bach BR, Provencher MT. Glenoid bone deficiency in recurrent anterior shoulder instability: Diagnosis and management. *J Am Acad Orthop Surg* 2009;17:482-493.
7. Lo IK, Parten PM, Burkhart SS. The inverted pear glenoid: an indicator of significant glenoid bone loss. *Arthroscopy* 2004;20(2):169-174.
8. Shaha JS, Cook JB, Song DJ, et al. Redefining "critical" bone loss in shoulder instability: Functional outcomes worsen with "subcritical" bone loss. *Am J Sports Med* 2015;43:1719-1725.
9. Waterman BR, Chandler PJ, Teague E, Provencher MT, Tokish JM, Pallis MP. Short-term outcomes of glenoid bone block augmentation for complex anterior shoulder

- instability in a high-risk population. *Arthroscopy* 2016;32:1784-1790.
10. Provencher MT, Frank RM, Golijanin P, et al. Distal tibia allograft glenoid reconstruction in recurrent anterior shoulder instability: Clinical and radiographic outcomes. *Arthroscopy* 2017;33:891-897.
  11. Helfet AJ. Coracoid transplantation for recurring dislocation of the shoulder. *J Bone Joint Surg Br* 1958;40:198-202.
  12. Latarjet M. Treatment of recurrent dislocation of the shoulder. *Lyon Chir* 1954;49:994-997.
  13. Hutchinson JW, Neumann L, Wallace WA. Bone buttress operation for recurrent anterior shoulder dislocation in epilepsy. *J Bone Joint Surg Br* 1995;77:928-932.
  14. Warner JJ, Gill TJ, O'Hollerhan JD, Pathare N, Millett PJ. Anatomical glenoid reconstruction for recurrent anterior glenohumeral instability with glenoid deficiency using an autogenous tricortical iliac crest bone graft. *Am J Sports Med* 2006;34:205-212.
  15. Kwapisz A, Fitzpatrick K, Cook JB, Athwal GS, Tokish JM. Distal clavicular osteochondral autograft augmentation for glenoid bone loss: A comparison of radius of restoration versus latarjet graft. *Am J Sports Med* 2018;46:1046-1052.
  16. Gendre P, Thélu C-E, d'Ollonne T, Trojani C, Gonzalez J-F, Boileau P. Coracoid bone block fixation with cortical buttons: An alternative to screw fixation? *Orthop Traumatol Surg Res* 2016;102:983-987.
  17. Di Giacomo G, Costantini A, de Gasperis N, et al. Coracoid graft osteolysis after the Latarjet procedure for antero-inferior shoulder instability: A computed tomography scan study of twenty-six patients. *J Shoulder Elbow Surg* 2011;20:989-995.
  18. Di Giacomo G, de Gasperis N, Costantini A, De Vita A, Beccaglia MAR, Pouliart N. Does the presence of glenoid bone loss influence coracoid bone graft osteolysis after the Latarjet procedure? A computed tomography scan study in 2 groups of patients with and without glenoid bone loss. *J Shoulder Elbow Surg* 2014;23:514-518.
  19. Balestro J-C, Young A, Maccioni C, Walch G. Graft osteolysis and recurrent instability after the Latarjet procedure performed with bioabsorbable screw fixation. *J Shoulder Elbow Surg* 2015;24:711-718.
  20. Haeni DL, Opsomer G, Sood A, et al. Three-dimensional volume measurement of coracoid graft osteolysis after arthroscopic Latarjet procedure. *J Shoulder Elbow Surg* 2017;26:484-489.
  21. Gupta A, Delaney R, Petkin K, Lafosse L. Complications of the Latarjet procedure. *Curr Rev Musculoskel Med* 2015;8:59-66.
  22. Bhatia S, Frank RM, Ghodadra NS, et al. The outcomes and surgical techniques of the Latarjet procedure. *Arthroscopy* 2014;30:227-235.
  23. Zhu Y-M, Jiang C-Y, Lu Y, Li F-L, Wu G. Coracoid bone graft resorption after Latarjet procedure is underestimated: A new classification system and a clinical review with computed tomography evaluation. *J Shoulder Elbow Surg* 2015;24:1782-1788.
  24. Amar E, Konstantinidis G, Coady C, Wong IH. Arthroscopic treatment of shoulder instability with glenoid bone loss using distal tibial allograft augmentation: Safety profile and short-term radiological outcomes. *Orthop J Sports Med* 2018;6:2325967118774507.
  25. Kraus N, Amphansap T, Gerhardt C, Scheibel M. Arthroscopic anatomic glenoid reconstruction using an autologous iliac crest bone grafting technique. *J Shoulder Elbow Surg* 2014;23:1700-1708.
  26. Shah AA, Butler RB, Romanowski J, Goel D, Karadagli D, Warner JJ. Short-term complications of the Latarjet procedure. *J Bone Joint Surg Am* 2012;94:495-501.
  27. Lafosse L, Boyle S. Arthroscopic Latarjet procedure. *J Shoulder Elbow Surg* 2010;19:2-12 (Suppl 2).
  28. Scheibel M, Kraus N, Diederichs G, Haas NP. Arthroscopic reconstruction of chronic antero-inferior glenoid defect using an autologous tricortical iliac crest bone grafting technique. *Arch Orthop Trauma Surg* 2008;128:1295-1300.
  29. Taverna E, D'Ambrosi R, Perfetti C, Garavaglia G. Arthroscopic bone graft procedure for anterior inferior glenohumeral instability. *Arthrosc Techniques* 2014;3:e653-e660.
  30. Taverna E, Ufenast H, Broffoni L, Garavaglia G. Arthroscopically assisted Latarjet procedure: A new surgical approach for accurate coracoid graft placement and compression. *Int J Shoulder Surg* 2013;7:120-123.
  31. Provencher MT, Aman ZS, LaPrade CM, et al. Biomechanical comparison of screw fixation versus a cortical button and self-tensioning suture for the Latarjet procedure. *Orthop J Sports Med* 2018;6:2325967118777842.
  32. Shin JJ, Hamamoto JT, Leroux TS, et al. Biomechanical analysis of Latarjet screw fixation: Comparison of screw types and fixation methods. *Arthroscopy* 2017;33:1646-1653.
  33. Kalogrianitis S, Tsouparopoulos V. Arthroscopic iliac crest bone block for reconstruction of the glenoid: A fixation technique using an adjustable-length loop cortical suspensory fixation device. *Arthrosc Techniques* 2016;5:e1197-e1202.
  34. Moga I, Konstantinidis G, Wong IH-B. The safety of a far medial arthroscopic portal for anatomic glenoid reconstruction: A cadaveric study. *Orthop J Sports Med* 2018;6:2325967118795404.
  35. Delaney RA, Freehill MT, Janfaza DR, Vlassakov KV, Higgins LD, Warner JJP. 2014 Neer Award Paper: Neuromonitoring the Latarjet procedure. *J Shoulder Elbow Surg* 2014;23(10):1473-1480. <https://doi.org/10.1016/j.jse.2014.04.003>.
  36. Rimmke NA, Jones GL, Bishop JY. Intraoperative nerve monitoring with a handheld intraoperative biphasic stimulator: Evaluation of use during the Latarjet procedure. *Techniques Orthop* 2018;33:e5-e8.
  37. Ahlmann E, Patzakis M, Roidis N, Shepherd L, Holtom P. Comparison of anterior and posterior iliac crest bone grafts in terms of harvest-site morbidity and functional outcomes. *JBJS* 2002;84(5):716-720.
  38. Myeroff C, Archdeacon M. Autogenous Bone Graft: Donor Sites and Techniques. *The J Bone Joint Surg Am* 2011;93:2227-2236.