



Since January 2020 Elsevier has created a COVID-19 resource centre with free information in English and Mandarin on the novel coronavirus COVID-19. The COVID-19 resource centre is hosted on Elsevier Connect, the company's public news and information website.

Elsevier hereby grants permission to make all its COVID-19-related research that is available on the COVID-19 resource centre - including this research content - immediately available in PubMed Central and other publicly funded repositories, such as the WHO COVID database with rights for unrestricted research re-use and analyses in any form or by any means with acknowledgement of the original source. These permissions are granted for free by Elsevier for as long as the COVID-19 resource centre remains active.



IMAGES IN INTENSIVE MEDICINE

Pneumomediastinum in critically ill adult with COVID-19

Neumomediastino en adultos en estado critico con COVID-19

N. Collercandy^{a,*}, A. Guillon^{a,b}

Available online 4 July 2020

^a CHU de Tours, service de médecine intensive réanimation, université de Tours, Tours, France

^b INSERM, Centre d'Etude des Pathologies Respiratoires (CEPR), Université de Tours, France

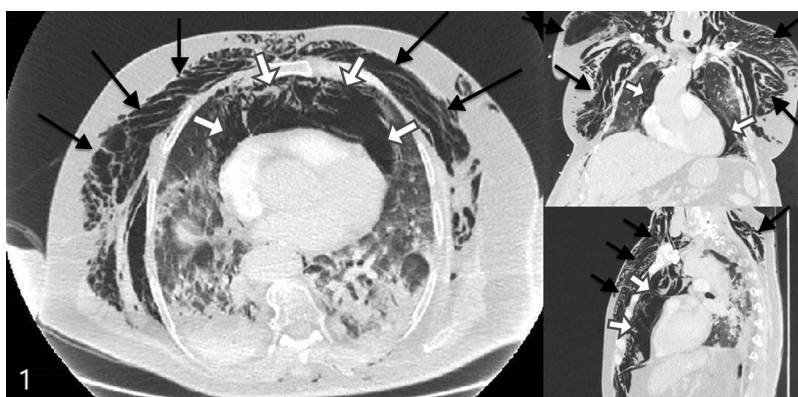


Figure 1

A 77-year-old man was admitted for moderate acute respiratory distress syndrome (ARDS) requiring invasive mechanical ventilation, with PCR confirmed SARS-Cov-2 infection. Protective ventilation strategy included: tidal volume of 6 mL/kg (ideal body weight), Positive End Expiratory Pressure (PEEP) titration with plateau pressure inferior to 28 cmH₂O, neuromuscular blockers, and prone position. At day 5 of ventilation, we observed acute chest and collar subcutaneous emphysema associated with bradycardia at 47 bpm. Chest CT scan revealed diffuse pneumomediastinum (white arrows) with diffuse subcutaneous emphysema (black arrows) (Fig. 1). There was no pneumothorax and no evidence for tracheal or esophageal perforation. No intervention was required. Pneumomediastinum are observed in critically ill coronavirus disease 2019 (COVID-19) patients. Whether or not this complication is related to the mechanical ventilation or to the COVID-19 pathogeny *per se* remains an unanswered question.

Acknowledgements

The authors thank the patient, whom relative gave full written permission for this report.

* Corresponding author.

E-mail addresses: nived.collercandy@yahoo.fr (N. Collercandy), antoine.guillon@univ-tours.fr (A. Guillon).