



## A Novel Skin Incision for Posterior Fossa Midline and Paramedian Lesions: A Technical Note and Case Series

Mohammad Sadegh Masoudi<sup>1</sup>, Sina Zoghi<sup>1</sup>, Reza Taheri<sup>1</sup>, Adrina Habibzadeh<sup>1</sup>, Ali Ansari<sup>1\*</sup>

<sup>1</sup>Department of Neurosurgery, Shiraz University of Medical Sciences, Shiraz, Iran

\*Corresponding author: Ali Ansari

Address: Department of Neurosurgery, Shiraz University of Medical Sciences, Shiraz, Iran.

e-mail: Aliansari37700@gmail.com

Received: September 9, 2023

Revised: October 16, 2023

Accepted: October 21, 2023

### ABSTRACT

Approaching posterior fossa pathologies is fairly challenging. Poor exposure, cerebrospinal fluid (CSF) leak following surgery, post-operative suboccipital and neck pain, as well as wound healing are all common complications following traditional suboccipital midline incision. Herein, we present a novel incision for approaching posterior fossa pathologies. The incision is shaped like a question mark and makes a musculofascial flap supplied by the occipital artery on top as well as a wide area for craniotomy. In our technique, the dura is also incised in a question mark-shaped manner. The new incision was used to operate on three patients who had masses in the posterior fossa. Following surgeries, none of the patients experienced any adverse events such as CSF leak, wound complications, severe suboccipital pain, and neck instability. This new incision not only facilitates approaching pathologies in the posterior fossa by providing wider exposure but also enables us to perform watertight dural closure, which reduces CSF leak. Furthermore, as the muscular incision provides a sufficient area for craniotomy, muscular retraction can be minimized to reduce post-operative pain. Moreover, unlike the midline avascular incision, the flap is well supplied by the occipital artery, which facilitates the healing procedure.

**Keywords:** Suboccipital craniotomy; Posterior fossa; Skin incision; Muscular incision; Musculofascial flap.

Please cite this paper as:

Masoudi MS, Zoghi S, Taheri R, Habibzadeh A, Ansari A. A Novel Skin Incision for Posterior Fossa Midline and Paramedian Lesions: A Technical Note and Case Series. *Bull Emerg Trauma*. 2024;12(1):42-45. doi: 10.30476/BEAT.2023.100324.1465.

### Introduction

In the pediatric central nervous system, the posterior fossa is the most prevalent site of tumor involvement [1]. Surgical access to the pathologies of this area is one of the most challenging issues in neurological surgery [2]. The current convention for midline suboccipital approach to posterior fossa pathologies, including lesions in the craniovertebral

junction (CVJ) and lesions in or around the fourth ventricle, begins with a midline suboccipital skin incision [3, 4].

Despite the extensive adoption of midline suboccipital skin incisions, there have been concerns regarding postoperative wound healing and aesthetics. The midline linear incision is located in an avascular plane, which is associated with poor wound healing due to insufficient blood supply [3, 5].

Moreover, a substantial number of patients who require surgery for pathologies in the posterior fossa will further need radiotherapy and chemotherapy, all of which are known to disrupt the wound-healing process [6].

Another limitation of the midline incision is insufficient surgical exposure, which makes it difficult to reach paramedial pathologies, such as those around medulla oblongata or in foramen magnum, and CVJ [2]. As a result, the midline incision is extended to at least the C2 spinous process to improve craniotomy and exposure of underlying tissues [3, 7]. Besides, suboccipital muscle retraction and dissection are used to enhance the exposure; however, this might damage the muscles, destabilize CVJ, and cause neck pain [8, 9].

Finally, a Y-shaped dural incision is frequently performed, after the skin incision. Suturing and closing the Y-shaped dura might be difficult, resulting in a post-operative cerebrospinal fluid (CSF) leak that can induce complications such as an incisional leak, meningitis, pseudo meningocele, and infections [10-12].

The decreased rate of CSF leak in anterior skull base surgery utilizing vascularized flaps, particularly the nasoseptal flaps and pericranial flaps, prompted us to investigate whether scalp flaps are effective in diminishing CSF leak following posterior fossa procedures [13, 14].

Herein, we present our experience with a novel surgical technique for approaching the posterior fossa midline and paramedian lesions, which seems to have overcome the mentioned challenges.

## Illustrative Cases and Surgical Technique

### Case 1

The patient was a six-year-old boy with no significant medical history, who was presented to the emergency department with severe headache, nausea, and vomiting. His pre-operative magnetic resonance imaging (MRI) revealed an enhancing

mass with central necrosis in the midline of the posterior fossa, in favor of medulloblastoma. After discussions concerning his management in our unit, he underwent surgical resection of the tumor.

### Case 2

The patient was a nine-year-old girl with no past significant medical history, who was admitted to our unit with complaints of diplopia, headache, nausea, and vomiting. Her pre-operative MRI indicated a medulloblastoma-like mass at the level of the fourth ventricle, posterior to pons and medulla oblongata. After discussions about her management in our unit, surgical resection of the tumor was recommended for her.

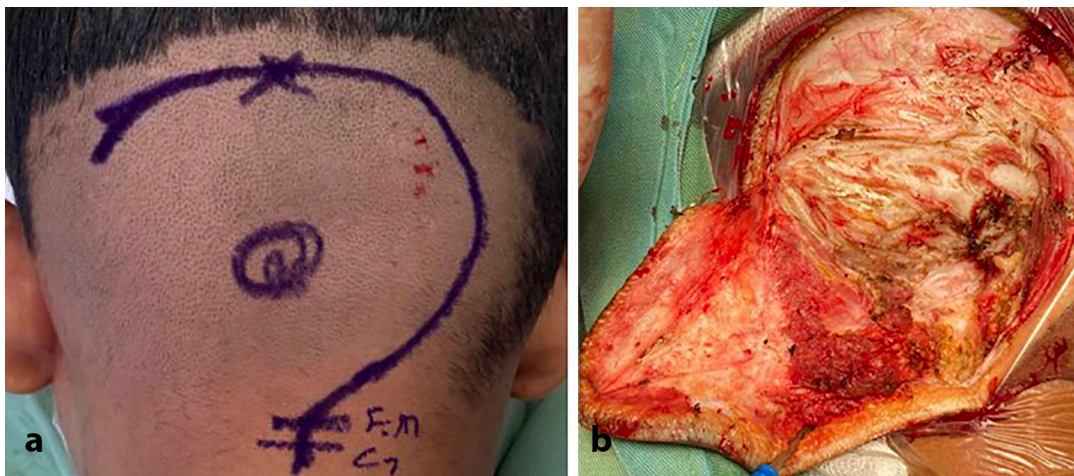
### Case 3

Due to hydrocephalus, an eight-year-old girl presented to our unit with a previously inserted right anterior ventriculoperitoneal shunt. She was suffering from vertigo and ataxia. Her pre-operative MRI demonstrated a heterogeneous mass in the posterior fossa, which was distended in the fourth ventricle. The mass was most likely compatible with medulloblastoma. After discussions about her management in our unit, surgical resection of the tumor was recommended for her.

### Surgical Technique

After safely placing the patient in a prone position, padding, and securing the patient to the bed, we shaved the occipital area from above the superior nuchal line to the level of the foramen magnum and extended the shaving to the lateral sides to prepare the skin for planning the incision. The border of the foramen magnum, C1 and C2 vertebrae, superior nuchal line, and external occipital protuberance and the limits of underlying pathology were determined, and its center was marked on the skin. Following that, the pathway of a question mark-shaped incision was planned (Figure 1).

The base of the incision began at the same level as



**Fig. 1.** Intra-operative photographs taken from a patient with medulloblastoma. **a.** The question mark-shaped pathway of the incision is started from the same level of the C1 vertebra. The superior nuchal line is considered the upper limit of the incision. **b.** The rotated musculofascial flap is made by performing skin and muscular incisions.

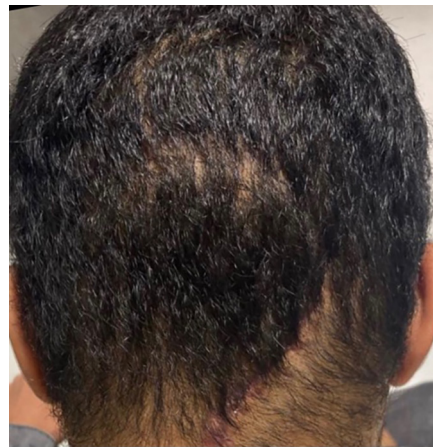the C1 vertebra, and the upper border of the incision touched the superior nuchal line. The incision was horizontally extended 1cm lateral to the sides of the midline lesion. It should be considered that in the paramedian approach, the incision should also be extended 1cm lateral to the margins of the lesion. However, the symmetrical advancement to the contralateral side is not required. Indeed, by making this incision, we made a musculocutaneous flap based on the occipital artery that was entirely rotated (Figure 1). Craniotomy was planned and performed while keeping the location of pathology and its borders. Craniotomy was performed using two burr holes. The dura was incised in a curvilinear manner resembling a question mark. Then, the mass was resected. After hemostasis, duraplasty was performed at the end of surgery. The pericranial fascia was applied as a secondary dural graft to improve dural healing. After sealing the dura, cranioplasty was performed. The muscles and the fascia were then restored, and the skin was sutured.

### Progress

No post-operative CSF leak was recorded in any of the patients. During the one-month outpatient clinic follow-up, all three patients' neurological symptoms improved, their neck posture and stability were preserved, and their parents reported no annoying occipital and neck pain or neck instability. Additionally, the patient's surgical wounds healed well without any complications (Figure 2). During the 12-month outpatient clinic follow-up, no complications regarding interruption of the nuchal musculature were observed in any of the patients.

### Discussion

Suboccipital craniotomy through a midline skin incision has been the most extensively accepted surgical approach for achieving pathologies in the posterior fossa and CVJ [3, 4, 7]. Using this approach, the surgeon and the patient might experience difficulties, which we attempted to solve with our novel technique. In this technique, a question mark-shaped incision is performed rather than a midline incision in an avascular plan, which primarily makes a well-vascularized musculocutaneous flap supplied by the occipital artery. Therefore, it improves the wound-healing process by enhancing the blood supply. Moreover, the incision begins at the level of the C1 vertebra and is not extended to the C2 vertebra, where the origins of suboccipital muscles such as rectus capitis posterior major and obliquus capitis inferior are located [15]. As a result, these muscles remain virtually intact, reducing the risk of damage and maintaining neck stability. In this new incision, the pathway of the muscular incision provides a wide area for craniotomy with adequate



**Fig. 2.** Post-operative photograph taken from well healed wound of a patient. No sign of wound complication is visible.

access to structures in the posterior fossa, even poor accessible structures located in lateral borders, without requiring additional muscular retraction. Postoperative neck and occipital pain can also be alleviated by reducing muscle retraction and surgical stress [8, 9]. Furthermore, the wide access to the dura allows us to incise the dura in a curvilinear shape. Therefore, the dura can be repaired easily at the end of the surgery. A further advantage of this technique is that the flap is capable of reducing the CSF leak, as it is proven to do in other neurosurgical procedures. Thus, there is a lower risk of complications caused by CSF leak [14].

Despite the traditional approach, in which the linear incision crosses the midline at the level of the C1 vertebra, in this technique, the curvilinear incision is initiated from C1 in a superolateral pathway. Thus, it is critical to explore the underlying area with a finger to preserve the vertebral artery in each step of performing this incision.

### Declaration

**Ethics approval and consent to participate:** Written informed consent was obtained from the patient's parents.

**Consent for publication:** The authors provide consent for publication.

**Conflict of Interest:** The authors declare no conflict of interest.

**Funding:** None declared.

**Authors' Contribution:** The study was designed by M.M. and R.T. The main manuscript was written by A.A., S.Z. and A.H. A.A and S.Z. collected the data and prepared the figures. The final manuscript was read and approved by all authors.

**Acknowledgment:** Not applicable.



## References

1. L. E. Becker and W. C. Halliday. Central nervous system tumors of childhood. *Perspect Pediatr Pathol.* 1987;**10**:86–134.
2. M. Schott, D. Suhr, and J.-P. A. H. Jantzen. Perioperative challenges during posterior fossa surgery. in *Essentials of Neurosurgical Anesthesia & Critical Care*, Springer. 2012:213–222.
3. A. della Puppa, O. Rustemi, and R. Scienza. The suboccipital midline approach to foramen magnum meningiomas. *Acta Neurochir (Wien)*. 2015;**157**(5):869–873.
4. Amil Nanda: Principles of posterior fossa surgery. *Thieme (New York, Stuttgart)*. 2012; (ISBN 978-1-58890-663-2)
5. J. A. D. Berry *et al.* The neurosurgical wound and factors that can affect cosmetic, functional, and neurological outcomes. *Int Wound J.* 2019;**16**(1):71–78.
6. W. G. Payne *et al.* Wound healing in PatientsWith cancer. *Eplasty.* 2008; **8**.
7. P. C. Bucy. Exposure of the posterior or cerebellar fossa. *J Neurosurg.* 1966;**24**(4):820–832.
8. J. M. McPartland, R. R. Brodeur, and R. C. Hallgren. Chronic neck pain, standing balance, and suboccipital muscle atrophy--a pilot study. *J Manipulative Physiol Ther.* 1997;**20**(1):24–29.
9. S. de Benedittis, A. Lorenzetti, M. Migliore, D. Spagnoli, F. Tiberio, and R. M. Villani. Postoperative pain in neurosurgery: a pilot study in brain surgery. *Neurosurgery.* 1996; **38**(3):466–470.
10. Z. Djordjevic and B. Milosavljevic. Postoperative cerebrospinal fluid fistulas and their treatment. *J Neurosurg Sci.* 1974;**18**(2):109–111.
11. J. A. Grotenhuis. Costs of postoperative cerebrospinal fluid leakage: 1-year, retrospective analysis of 412 consecutive nontrauma cases. *Surg Neurol.* 2005;**64**(6):490–493.
12. M. W. Hawk and K. D. Kim. Review of spinal pseudomeningoceles and cerebrospinal fluid fistulas. *Neurosurg Focus.* 2000;**9**(1):1–8.
13. M. E. Johns, H. R. Winn, W. C. McLean, and R. W. Cantrell. Pericranial flap for the closure of defects of craniofacial resections. *Laryngoscope.* 1981;**91**(6):952–959.
14. G. Hadad *et al.* A novel reconstructive technique after endoscopic expanded endonasal approaches: vascular pedicle nasoseptal flap. *Laryngoscope.* 2006;**116**(10):1882–1886.
15. G. la Rocca, R. Altieri, L. Ricciardi, A. Olivi, and G. M. della Pepa. Anatomical study of occipital triangles: the ‘inferior’ suboccipital triangle, a useful vertebral artery landmark for safe postero-lateral skull base surgery. *Acta Neurochir (Wien)*. 2017;**159**(10):1887–1891.

**Open Access License**

All articles published by Bulletin of Emergency And Trauma are fully open access: immediately freely available to read, download and share. Bulletin of Emergency And Trauma articles are published under a Creative Commons license (CC-BY-NC).