



Case report

Patch graft using collagen matrix (Ologen) for glaucoma drainage device exposure in a patient with Boston Keratoprosthesis type 1

Samir Jabbour^{a,*}, Mark R. Lesk^{a,b}, Mona Harissi-Dagher^{a,c}^a Department of Ophthalmology, Université de Montréal, Montreal, QC, Canada^b Department of Ophthalmology, Hôpital Maisonneuve-Rosemont, Montreal, QC, Canada^c Department of Ophthalmology, Centre Universitaire de l'Université de Montréal (CHUM), Montreal, QC, Canada

ARTICLE INFO

Keywords:

Boston Kpro
 Glaucoma drainage device
 Tube exposure
 Ologen

ABSTRACT

Purpose: To report the first successfully treated case of recurrent tube exposure in a patient with the Boston Keratoprosthesis type 1 with a collagen matrix patch graft (Ologen).

Observations: A 50 year-old female with a Boston Keratoprosthesis type 1 and a history of Axenfeld-Reiger syndrome presents to our department with recurrent glaucoma drainage device exposure in her left eye. After failed spontaneous closure with topical antibiotics and lubricants, she undergoes tube exposure repair using an Ologen patch graft. Surgery was successful and the patient did not have any recurrence up to last follow-up two years post-operatively.

Conclusion: Collagen matrix patch graft seems to be advantageous in treating glaucoma tube exposure in the Boston KPro eye, which is often a more challenging entity to treat.

Importance: Collagen matrix patch graft could be considered as a primary patch graft in treating tube exposure in eyes with the Boston KPro.

1. Introduction

The use of glaucoma drainage devices (GDD) to treat complicated glaucoma has gained widespread popularity over the last decades.¹ These silicone tubes are usually placed in the anterior chamber (AC) and drain aqueous humor to a reservoir plate covered by Tenon's and conjunctiva. In order to prevent erosion of the tube through conjunctiva, several graft types, most commonly partial thickness scleral grafts,² have been used to cover the tube. However, in some cases, tube exposure results despite adequate coverage, predisposing the eye to endophthalmitis.³ A revision surgery is often warranted and involves coverage of the exposed tube with patch graft material, including scleral, corneal, or pericardial tissue.^{4–6} In some cases, removal of the tube is required.

In Boston Keratoprosthesis (B-KPro) population, glaucoma continues to be one of the most difficult complications to manage.⁷ GDD have become the most common surgical option to control glaucoma in these patients when medical therapy is insufficient. However, GDDs exposure has been shown to be much more prevalent in this patient population, and is often at a higher risk of recurrence despite adequate surgical revision.⁸

In this report, we describe the use of a collagen matrix for recurrent

tube exposure revision in an eye with B-KPro type 1.

2. Case report

2.1. History of the disease

A 50-year-old female with a history of Axenfeld-Reiger syndrome presented to our department with new-onset ocular discomfort and redness in the left eye. The patient was followed for advanced glaucoma in this eye. She had had a penetrating keratoplasty and trabeculectomy surgery done twenty years ago, followed by implantation of an Ahmed glaucoma valve (AGV) in the AC ten years ago. Five years later, she developed AGV tube exposure that was treated with tube repositioning to the pars plana, with coverage of the exposed part of the tube with a conjunctival autograft and a scleral patch. Two years later, she developed primary graft failure secondary to multiple intraocular surgeries and underwent implantation of a B-KPro type 1 after being deemed at high risk of graft rejection.

On presentation, she was found to have a best-corrected visual acuity (BCVA) of 20/100 and an intra-ocular pressure (IOP) of 20 mmHg in the left eye on palpation. On slit-lamp examination, a conjunctival buttonhole of 4 × 2 mm with exposed tube was found a

* Corresponding author. Department of Ophthalmology, CHUM, 850 Saint-Denis, H2X 0A9, Montreal, QC, Canada.

E-mail address: samir.jabbour2@gmail.com (S. Jabbour).

<https://doi.org/10.1016/j.ajoc.2018.08.003>

Received 26 December 2017; Received in revised form 22 April 2018; Accepted 14 August 2018

Available online 18 August 2018

2451-9936/© 2018 Published by Elsevier Inc. This is an open access article under the CC BY-NC-ND license

(<http://creativecommons.org/licenses/by-nc-nd/4.0/>).

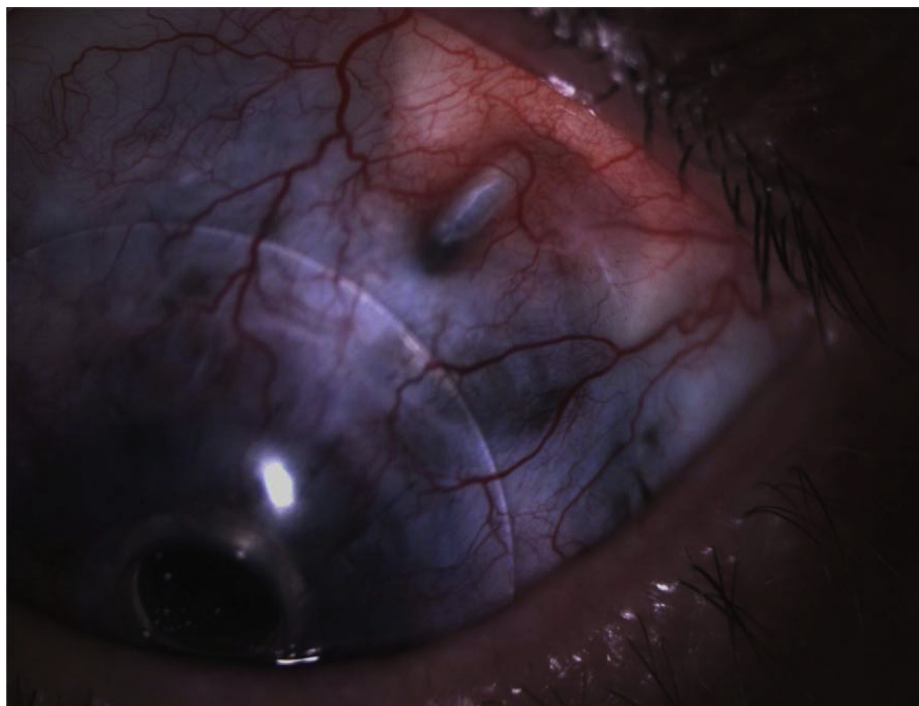


Fig. 1. Exposed glaucoma drainage device through conjunctiva at the edge of the bandage contact lens.

few millimeters posterior to the limbus, at the edge of the bandage contact lens (BCL) (Fig. 1). There were no signs of endophthalmitis. It was decided to remove the contact lens and put the patient on topical moxifloxacin QID and topical artificial tears six times a day. She was observed for 3 months, at which time she spontaneously closed which is believed to be due to the cessation of friction of the BCL on the ocular surface and to increased surface lubrication. Two weeks later, the area re-opened. It was then decided to bring the patient to the operating room for tube coverage using a collagen matrix graft (Ologen).

2.2. Surgical technique

In the operating room, a superotemporal oval subconjunctival pocket beginning with the existing open conjunctiva and extending approximately 2–3 mm beyond the edge of the exposed tube in every direction was carried out with Westcott scissors. An Ologen sheet that comes as a $10 \times 10 \times 2$ mm sheet was cut in the proper dimensions of 6×8 mm and placed in the subconjunctival pocket to fully cover the area of tube exposure. No sutures were needed at the time as the collagen quickly becomes adherent to the moist scleral bed and remains immobile once properly covered. After careful measurement of the conjunctival opening, a conjunctival autograft of 5×3 mm is dissected from the super-nasal quadrant, which was deemed to have sufficient healthy conjunctival tissue with adequate surgical exposure. The autograft was then placed on the Ologen matrix. Using 10-0 nylon sutures, the autograft along with underlying Ologen implant were secured to the sclera. Every effort was made to ascertain that the collagen was not exposed and that the conjunctiva was well secured in place. The bed of the conjunctival autograft was primarily closed using 10-0 Vicryl sutures. Finally an amniotic membrane was carefully cut to cover an area twice as large as the area of tube exposure. The amniotic membrane was then placed on the conjunctival autograft and secured using 10-0 Vicryl sutures.

3. Results

Overall, the surgery was well tolerated and there were no serious

intra-operative complications. On post-operative day 1, BCVA remained stable at 20/100, IOP was 20 mmHg and the tube was adequately and completely covered with no signs of wound dehiscence. There were no signs of ologen-specific side-effects, such as allergy or translocation of the implant. Two years post-operatively, there are no signs of tube exposure recurrence and the ologen implant is not visible anymore on examination (Fig. 2). BCVA and IOP remained stable over the entire examination period.

4. Discussion

GDDs are very useful adjunct for the treatment of refractory glaucoma. However these devices come with an array of potential serious complications.⁹ The most common delayed complication is exposure of the tube overlying eroded conjunctiva.^{10,11} Tube exposure can be multifactorial, related to either dehiscence of the suture in early cases, or to scleral/graft patch melting in later cases. Mechanical factors due to blinking and ocular movements are believed to also influence the occurrence of late tube exposure.¹²

Late-onset tube exposure is even more prevalent in eyes with the B-KPro type 1, ranging from 14.6% to more than 50% of cases, and is often harder to treat.^{8,13} It was found that one important risk factor for tube erosion is the duration that the tube has been in place before surgery, with older glaucoma drainage devices more likely to develop erosions.⁸ Another risk factor is the chronic wear of BCL (typically a 16.0 mm Kontur contact lens), which is believed to cause conjunctival breakdown at the edge of the contact lens.¹⁴ Finally, the ocular surface of patients requiring Boston KPro implantation is already compromised and may lead to melts.^{15,16}

Different patch graft material have been described in the literature for tube exposure repair, including autologous fascia lata,¹⁷ donor pericardium,¹⁸ sclera,² cornea,^{5,19} and dura mater.²⁰ In 2012, Rosentreter et al.²¹ reported the first successful case of tube exposure revision surgery using a novel biodegradable collagen implant, the ologen implant. The ologen implant is a porous material consisting of > 90% lyophilized porcine atelocollagen, a highly purified pepsin-treated type I collagen and < 10% lyophilized porcine glycosaminoglycan with a

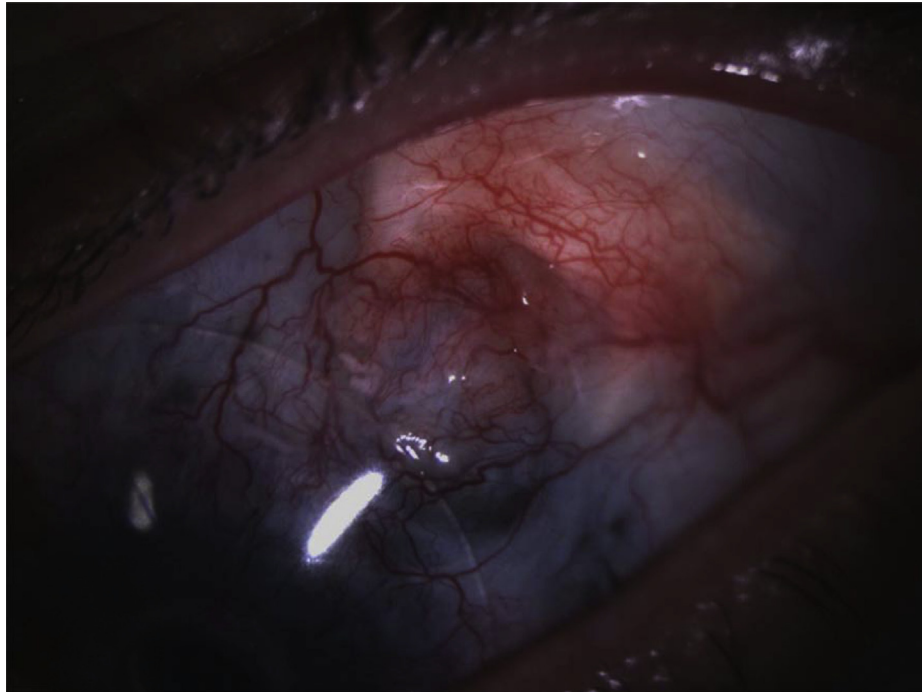


Fig. 2. Results at two year post-operatively demonstrating proper tube coverage and adequate cosmesis.



Fig. 3. Ologen implant.

pore size of 10–300 μm (Fig. 3). Some advantages of the ologen implant is that it has a low immunogenicity profile because it is free of telopeptides, it does not need to be harvested from human donors, and it has improved cosmesis compared to other materials.^{21,22} It avoids direct contact between the conjunctiva and the tube and acts as a wound-healing scaffold. More recently, Stephens et al.²³ demonstrated that the ologen implants might be successfully used as a primary patch graft in GDD surgery. In 43 eyes, only two developed tube erosion at 4 months and 26 months respectively, which is believed to be due to inappropriate coverage of the graft material during the surgery.

To our knowledge, there have been no reported cases of the use of the ologen implant for tube exposure in an eye with the B-KPro. In our case, the implant was used following a recurrent exposure despite initial adequate scleral graft usage and moving the insertion of the GDD from the AC to the vitreous cavity. Of particular interest, the ologen implant could provide advantage for B-KPro eyes who have damaged conjunctiva from various diseases such as cicatrizing processes, including chemical burns, that are more at risk of melts. Amniotic membrane was used to further promote healing and decrease post-operative inflammation. Over a follow-up period of two years, our patient is still doing well with no signs of recurrent tube exposure. Hence, the

use of the ologen matrix seems to be promising in the B-KPro population. A prospective, controlled clinical trial would be needed to further evaluate and compare the erosion rates between the ologen implant and other patch grafts in B-KPro eyes.

Patient consent

Consent to publish the case report was not obtained. This report does not contain any personal information that could lead to the identification of the patient.

Acknowledgments

No funding or grant support.

The following authors have no financial disclosures: SJ, ML, MHD.

All authors attest that they meet the current ICMJE criteria for Authorship.

Appendix A. Supplementary data

Supplementary data related to this article can be found at <https://doi.org/10.1016/j.ajoc.2018.08.003>.

References

- Gedde SJ, Schiffman JC, Feuer WJ, et al. Tube versus Trabeculectomy Study Group. Treatment outcomes in the tube versus trabeculectomy study after one year of follow-up. *Am J Ophthalmol.* 2007;143(1):9–22.
- Freedman J. Scleral patch grafts with Molteno setons. *Ophthalmic Surgery, Lasers and Imaging Retina.* 1987;18(7) 532–4.
- Minckler DS, Francis BA, Hodapp EA, et al. Aqueous shunts in glaucoma: a report by the American Academy of Ophthalmology. *Ophthalmology.* 2008;115(6) 1089–98.
- Lama PJ, Fechtner RD. Tube erosion following insertion of a glaucoma drainage device with a pericardial patch graft. *Arch Ophthalmol.* 1999;117(9) 1243–4.
- Rojanapongpun P, Ritch R. Clear corneal graft overlying the seton tube to facilitate laser suture lysis. *Am J Ophthalmol.* 1996;122(3) 424–5.
- Aslanides IM, Spaeth GL, Schmidt CM, et al. Autologous patch graft in tube shunt surgery. *J Glaucoma.* 1999;8(5):306–309.
- Talajic JC, Agoumi Y, Gagné S, et al. Prevalence, progression, and impact of glaucoma on vision after Boston type 1 keratoprosthesis surgery. *Am J Ophthalmol.* 2012;153(2):267–274.
- Li JY, Greiner MA, Brandt JD, et al. Long-term complications associated with

- glaucoma drainage devices and Boston keratoprosthesis. *Am J Ophthalmol.* 2011;152(2):209–218.
9. Gedde SJ, Scott IU, Tabandeh H, et al. Late endophthalmitis associated with glaucoma drainage implants. *Ophthalmology.* 2001;108(7):1323–1327.
 10. Souza C, Tran DH, Loman J, et al. Long-term outcomes of Ahmed glaucoma valve implantation in refractory glaucomas. *Am J Ophthalmol.* 2007;144(6):893–900.
 11. Wishart PK, Choudhary A, Wong D. Ahmed glaucoma valves in refractory glaucoma: a 7-year audit. *Br J Ophthalmol.* 2010;94(9):1174–1179.
 12. Oana S, Vila J. Tube exposure repair. *J Curr Glaucoma Pract.* 2012;6(3):139.
 13. Patel S, Takusagawa H, Shen L, et al. Long-term complications associated with glaucoma drainage devices and Boston keratoprosthesis. *Am J Ophthalmol.* 2012;154(1):207–208.
 14. Chew HF, Ayres BD, Hammersmith KM, et al. Boston keratoprosthesis outcomes and complications. *Cornea.* 2009;28(9):989–996.
 15. Robert MC, Dohlman CH. A review of corneal melting after Boston keratoprosthesis. *Semin Ophthalmol.* 2014;29(5–6):349–357.
 16. Robert MC, Harissi-Dagher M. Boston type 1 keratoprosthesis: the CHUM experience. *Can J Ophthalmol.* 2011;46(2):164–168.
 17. Tanji TM, Lundy DC, Minckler DS, et al. Fascia lata patch graft in glaucoma tube surgery. *Ophthalmology.* 1996;103(8):1309–1312.
 18. Raviv T, Greenfield DS, Liebmann JM, et al. Pericardial patch grafts in glaucoma implant surgery. *J Glaucoma.* 1998;7(1):27–32.
 19. Singh M, Chew PT, Tan D. Corneal patch graft repair of exposed glaucoma drainage implants. *Cornea.* 2008;27(10):1171–1173.
 20. Brandt JD. Patch grafts of dehydrated cadaveric dura mater for tube-shunt glaucoma surgery. *Arch Ophthalmol.* 1993;111(10):1436–1439.
 21. Rosentreter A, Schild AM, Dinslage S, Dietlein TS. Biodegradable implant for tissue repair after glaucoma drainage device surgery. *J Glaucoma.* 2012;21(2):76–78.
 22. Stenzel KH, Miyata T, Rubin AL. Collagen as a biomaterial. *Annu Rev Biophys Bioeng.* 1974;3(1):231–253.
 23. Stephens JD, Sarkisian Jr SR. The use of collagen matrix (Ologen) as a patch graft in glaucoma tube shunt surgery, a retrospective chart review. *F1000 Res.* 2016;5.