


Placenta accreta spectrum: Risk factors, diagnosis and management with special reference to the Triple P procedure

Women's Health
Volume 15: 1–8
© The Author(s) 2019
Article reuse guidelines:
sagepub.com/journals-permissions
DOI: 10.1177/1745506519878081
journals.sagepub.com/home/whe


Ana Piñas Carrillo¹ and Edwin Chandraharan² 

Abstract

Abnormal invasion of placenta or placenta accreta spectrum disorders refer to the penetration of the trophoblastic tissue through the decidua basalis into the underlying uterine myometrium, the uterine serosa or even beyond, extending to pelvic organs. It is classified depending on the degree of invasion into placenta accreta (invasion <50% of the myometrium), increta (invasion >50% of the myometrium) and percreta (invading the serosa and adjacent pelvic organs). Clinical diagnosis is made intra-operatively; however, the confirmative diagnosis can only be made after a histopathological examination. The incidence of abnormal invasion of placenta has increased worldwide, mostly as a consequence of the rise in caesarean section rates, from 1 in 2500 pregnancies to 1 in 500 pregnancies. The importance of the disease is due to the increased maternal and foetal morbidity and mortality. Foetal implications are mainly due to iatrogenic prematurity, while maternal implications are mostly the increased risk of obstetric haemorrhage and surgical complications. The average blood loss is 3000–5000 mL, and up to 90% of the patients require a blood transfusion. An accurate and timely antenatal diagnosis is essential to improve outcomes. The traditional management of abnormal invasion of placenta has been a peripartum hysterectomy; however, the increased incidence and the short- and long-term consequences of a radical approach have led to the development of more conservative techniques, such as the intentional retention of the placenta, partial myometrial excision and the 'Triple P procedure'. Irrespective of the surgical technique of choice, women with a high suspicion or confirmed abnormally invasive placenta should be managed in a specialist centre with surgical expertise with a multi-disciplinary team who is experienced in managing these complex cases with an immediate availability of blood products, interventional radiology service, an intensive care unit and a neonatal intensive care unit to optimize the outcomes.

Keywords

intentional retention of placenta, peripartum hysterectomy, placenta accreta spectrum disorders, placenta percreta, prophylactic endovascular occlusive balloons, the 'smudged egg' sign, Triple P procedure

Date received: 6 January 2019; revised: 11 July 2019; accepted: 2 September 2019

Introduction

Abnormal invasion of placenta (AIP) or placenta accreta spectrum (PAS) disorders refer to the penetration of the trophoblastic tissue through the decidua basalis into the underlying uterine myometrium, the uterine serosa or even beyond, extending to pelvic organs. It is classified depending on the degree of invasion into placenta accreta (invasion <50% of the myometrium), increta (invasion >50% of the myometrium) and percreta (invading the serosa and adjacent pelvic organs). Clinical diagnosis is made

intra-operatively; however, the confirmative diagnosis can only be made after a histopathological examination. In

¹St George's University Hospitals NHS Foundation Trust, London, UK

²St George's University Hospitals NHS Foundation Trust and St George's, University of London, London, UK

Corresponding author:

Edwin Chandraharan, St George's University Hospitals NHS Foundation Trust and St George's, University of London, Blackshaw Road, London SW17 0QT, UK.
Email: edwin.c@sky.com



fact, the term placenta accreta was first described in 1937 by Irving and Hertig as a histopathological term as the 'abnormal adherence of the afterbirth in whole or in parts to the underlying uterine wall in the partial or complete absence of decidua'.¹ The terms placenta accreta and morbidly adherent placenta have been recently substituted by the terms abnormal invasion of placenta or placenta accreta spectrum disorders to include not only the cases of myometrial invasion but also the ones where there is invasion beyond the uterus.

The incidence of AIP has increased worldwide, mostly as a consequence of the rise in caesarean section rates, from 1 in 2500 pregnancies to 1 in 500 pregnancies.² The importance of the disease is due to the increased maternal and foetal morbidity and mortality. Foetal implications are mainly due to iatrogenic prematurity, while maternal implications are mostly the increased risk of obstetric haemorrhage and surgical complications. The average blood loss is 3000–5000 mL,³ and up to 90% of the patients require a blood transfusion. Surgical complications include hysterectomy and ureteric, bladder and bowel injury. This results in a higher incidence of admission to intensive care unit and longer hospital admission. In addition, there is also a higher incidence of post-traumatic stress disorder (PTSD) and psychological sequelae. Maternal mortality was reported in the 1990s to be as high as 7%–10% worldwide.⁴ The improvement on prenatal diagnosis and the management of these cases in specialist centres has reduced the mortality rate as reported in more recent series^{5–7} and is likely to reduce further as clinicians become more experienced in screening of high-risk patients and develop new surgical techniques. The traditional management of AIP has been a peripartum hysterectomy; however, the increased incidence of PAS and the short- and long-term consequences of a radical approach have led to the development of more conservative techniques, such as intentional retention of placenta (IRP), partial myometrial excision and the 'Triple P procedure'. We have discussed the Triple P procedure, which is a conservative surgical alternative to a peripartum hysterectomy in detail.

Risk factors

Although the exact physiopathology of the disease is not fully known, it is believed that damage caused to the decidua basalis results in the abnormal invasion of the trophoblastic tissue through this defective area. Another potential contributor is the hypoxic environment created by the scar tissue that could act as a stimulus for trophoblastic invasion. This damage can be secondary to surgical procedures such as caesarean section and myomectomy or to damage to the endometrium and superficial myometrium caused during manual removal of placenta, uterine curettage or endometrial ablation but also as a result of infectious processes such as endometritis. A case-control

study in the UK found an overall adjusted odds ratio (aOR) for abnormal invasive placenta after previous uterine surgery of 3.40 (95% confidence interval (CI) 1.30–8.91).⁸

There is also an increased risk of AIP with advanced maternal age,^{8,9} shorter intervals between previous caesarean section and current pregnancy, multiparity, placenta praevia, assisted reproduction techniques,⁸ submucosal leiomyomas, smoking, and hypertension disease. There is no robust evidence suggesting that the suture material used during caesarean section or the specific technique used is associated with increased incidence of PAS in subsequent pregnancies.

Placenta praevia and previous caesarean section are the two most recognized risk factors for AIP. A recent systematic review reported an increase in the incidence of abnormally invasive placenta from 3.3%–4% in women with placenta praevia and no previous caesarean section to 50%–67% in women with three or more previous caesarean deliveries.¹⁰

According to a case-control study using the UK Obstetric Surveillance System (UKOSS), the odds of having AIP was increased in women who had a previous caesarean delivery (aOR 14.41, 95% CI 5.63–36.85), other previous uterine surgery (aOR 3.40, 95% CI 1.30–8.91), an in vitro fertilization (IVF) pregnancy (aOR 32.13, 95% CI 2.03–509.23) and placenta praevia diagnosed antepartum (aOR 65.02, 95% CI 16.58–254.96). The study also found raised odds of AIP associated with advanced maternal age in women without a previous caesarean delivery (aOR 1.30, 95% CI 1.13–1.50 for every 1-year increase in age from 35 years).²

Diagnosis

Prenatal diagnosis of invasive placenta is paramount to reduce maternal morbidity and mortality as it allows planning and timing of the surgery, arrangements for interventional radiology, availability of blood products and cell salvage, plan for the most appropriate surgical technique by an experience surgeon and support from other specialities if there is involvement of the ureters, bladder or bowel.

A thorough past obstetric and gynaecological clinical history should raise the strong suspicion of an AIP. The presence of one or more previous caesarean sections, manual removal of placenta, recurrent miscarriages managed surgically or a history of endometritis among others should trigger an even more detailed examination of the placental bed during ultrasound examination.

Ultrasound imaging is the first diagnostic tool with a high specificity and sensitivity. Placental localization and morphology should be routinely assessed in all pregnancies at the time of the anomaly scan. It is reported that up to 50% of the cases are suspected antenatally in the UK.¹¹ Prenatal diagnosis is paramount as it provides an opportunity to make a management plan for delivery, reducing maternal and foetal mortality and morbidity.

Particularly important is the assessment of an anterior low-lying placenta or placenta praevia in the presence of previous caesarean section.

Classical ultrasound features of placenta accreta include the presence of multiple irregular lacunae, loss of the retroplacental sonolucent zone and thinning of the serosa. Placental lacunae are considered the single most reliable feature with a high-sensitivity and good positive predictive value. Typically, they present as numerous irregular lacunae of varying size and turbulent flow as opposed to placental lakes that have a distinct outline and laminar flow.¹² A second grey-scale sign is the interruption of the hyperechogenic line of serosa between the bladder and the uterus, especially if this is associated with crossing blood vessels. It is unusual to be able to see placental mass in the bladder, although this would be diagnostic of a true placenta percreta. There can also be a loss of the sonolucent retroplacental area, and although this feature can be present in normal placentation, the presence of this sign should trigger the search for other features of placenta accreta.

The most common location of placenta accreta is in the low anterior uterine wall at the level of the caesarean section scar with the involvement of the cervix in cases of co-existing placenta praevia. There is a correlation between the length of the cervix and the risk of bleeding, with a cervix <25 mm having a higher risk of bleeding. The risk of placenta accreta is lower if the caesarean section was performed in established labour as the incision is done inadvertently through the effaced cervix in about a third of the cases.¹³

A study comparing the different ultrasound signs concluded that the presence of abnormal vasculature on colour Doppler ultrasound had the best combination of sensitivity and specificity. The best specificity was the presence of an abnormal uterus–bladder interface.

Ultrasound has been proved to be highly sensitive and specific in detecting abnormal invasion of placenta in the third trimester in patients with a low anterior placenta and previous caesarean section, and the prevalence of AIP in these women has been reported as high as 1 in 5.¹⁴

The systematic use of magnetic resonance imaging (MRI) to diagnose AIP is not recommended. A study comparing the accuracy of ultrasound and MRI concluded that although MRI is highly accurate in diagnosing AIP, there is no statistically significant difference in sensitivity or specificity between ultrasound and MRI.¹⁵ MRI can be more accurate than ultrasound to assess the degree of invasion in cases of posterior placenta or extension beyond the uterine serosa.

Management

Once the diagnosis has been made, the patient should be referred to an experienced tertiary centre with 24-h access to interventional radiology and a tertiary neonatal unit as iatrogenic preterm birth is likely.

If the patient is stable and there is no active bleeding, she can be managed as an outpatient with a clear plan for delivery should it become necessary as an emergency. However, depending on the social circumstances (e.g. availability of emergency transport 24/7, patient education and distance from the specialist centre), some clinicians may opt for hospitalization until birth.

Options of management, risks and benefits should be discussed with the patient in an individualized manner according to the location and degree of invasion of placenta.

Management options include the following.

Peripartum hysterectomy

This has been the traditional approach whether it is performed as an elective procedure or as an emergency in cases of massive obstetric haemorrhage. The uterine incision to perform the caesarean section is done away from the placental bed and the foetus delivered followed by the hysterectomy. This is the most radical approach and, when performed as an elective procedure, avoids the attempt to separate the placenta from the uterine wall, which can cause a massive obstetric haemorrhage. The advantage of this approach electively is that it generally reduces the bleeding as the placenta is left ‘untouched’ before proceeding to the hysterectomy. The disadvantage of this procedure is that bleeding can continue after hysterectomy as the abnormally invasive placenta can receive the blood supply from vessels arising from the upper segment of the vagina. Moreover, the newly formed feeding blood vessels as a result of ‘neovascularization’ lack the tunica media (i.e. the muscle layer) and, therefore, may not be amenable for traditional haemostatic measures such as sutures or diathermy, which are dependent on the tunica media. This can result in torrential bleeding during a hysterectomy, needing pelvic packing and the need for a repeat laparotomy. There is also a higher risk of damage to adjacent organs such as the bladder or ureters and inevitably a permanent loss of fertility which can have psychological implications for women and a higher risk of vaginal prolapse in the long term. In cases of placenta percreta invading the urinary bladder, a cystotomy (intentional or otherwise) becomes inevitable during a hysterectomy, which may result in prolonged catheterization.

Conservative techniques

Intentional retention of placenta. The myometrial incision is made above the upper margin of the placenta (similar to the uterine incision during an elective peripartum hysterectomy), and the foetus is delivered.¹⁶ The umbilical cord is then ligated as close as possible to the placenta without attempting to separate the placenta from the uterine wall. The uterine incision is sutured, and the placenta is left

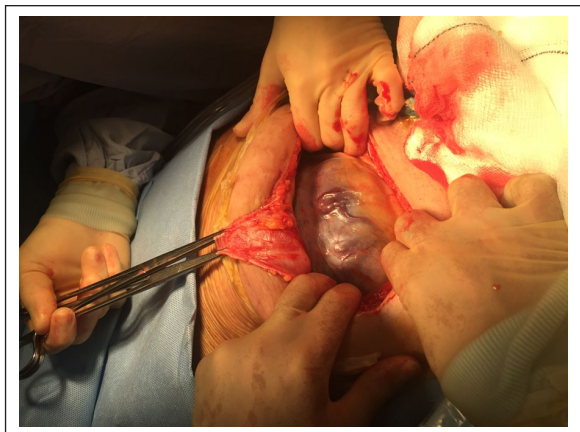


Figure 1. The 'St George's Boat Incision' on the rectus sheath. Note the flap allows access to the myometrium above the upper border to the placenta.

inside the uterus. Oxytocin should not be used as it may cause a partial separation of the 'unattached' parts of the placenta, leading to bleeding. The advantage of this technique is that it minimizes the intra-operative bleeding significantly as the placenta is not disturbed at any point. The disadvantage is that it can take up to 20 weeks for the placental tissue to completely reabsorb by progressive necrosis, and during this period, there is a high risk of secondary haemorrhage, sepsis and the potential need to perform an interval or an emergency peripartum hysterectomy. It also requires a long follow-up to ensure complete reabsorption of the placental tissue, which requires excellent patient compliance. Prophylactic antibiotics must be administered to avoid infection for 7–10 days. However, the use of methotrexate is not recommended because it has a very limited effect as the placenta during late pregnancy has only a few rapidly dividing cells, and methotrexate can cause considerable side effects, including bone marrow suppression, which may increase the risks of sepsis.¹⁷ Even rare complications such as a utero-cutaneous fistula have been reported with IRP.¹⁸ Arterial embolization should not be performed routinely as rapid necrosis of trophoblastic tissue may predispose to sepsis and secondary haemorrhage. In cases of secondary postpartum haemorrhage during the follow-up of an IRP, an emergency embolization can be performed prior to hysterectomy, if deemed appropriate.

As part of the follow-up, it is recommended to perform serial ultrasounds and determine the levels of β -human chorionic gonadotropin (hCG). Although this does not predict the development of infection or haemorrhage, it can assist in evaluating the overall clinical picture. However, caution should be exercised during outpatient management because of potentially very serious complications such as sepsis, secondary haemorrhage and disseminated intravascular coagulation. The recurrent rate may be low if the

placenta during the subsequent pregnancy is implanted away from the previous site of abnormal adherence.

Triple P procedure

This procedure is a novel conservative surgical technique developed to avoid the complications of peripartum hysterectomy as well as IRP.¹⁹ It consists of three steps: *perioperative placental localization* by a transabdominal ultrasound scan immediately prior to surgery to delineate the upper border of the placenta; *pelvic devascularization* by inflation of pre-positioned pelvic arterial occlusive balloon catheters to reduce the blood supply to the placental bed and *placental non-separation and myometrium excision* (i.e. excising the placenta along with the underlying adherent myometrium without separating), followed by reconstruction of the myometrial defect.¹⁹ It combines the principle of not attempting to separate the placenta from the underlying myometrium with the removal of as much placental tissue as possible to minimize the risk of bleeding and infection. This technique requires the involvement of interventional radiology to place prophylactic occlusive balloons in the anterior division of the internal iliac to reduce vascularity from all the 'feeding' vessels to the placental bed prior to the myometrial excision.

The first step is the perioperative localization of the 'upper margin' of the placenta, and an abdominal ultrasound scan is performed to determine the placental edge in order to carry out the uterine incision just above it. This can be achieved through a supra-pubic transverse incision on the skin and a 'St George's Boat Incision' on the rectus sheath after reflecting the subcutaneous fat overlying the rectus sheath up to the umbilicus (Figure 1). When the 'boat-shaped' flap is lifted upwards, access to the myometrium above the upper border of the placenta can be easily obtained (Figure 1). Once the foetus is delivered, the uterus is exteriorized and examined to determine the area of placental invasion. At this point, the second step takes place which involves the temporary pelvic devascularization by inflation of the pre-positioned catheter balloons inserted within the anterior division of the internal iliac arteries. This step is crucial as it significantly reduces the myometrial vascularity not only from the uterine arteries but also from vesical, vaginal arteries, before proceeding to the next step. The third step involves the removal of the adherent placental tissue together with the underlying myometrium. It is necessary to leave about 2 cm of myometrium in contact with the urinary bladder to be able to repair the myometrial defect (Figure 2). In cases of placenta percreta invading the urinary bladder, approximately 2–4 cm of the placental tissue invading the bladder is left in situ. In order to avoid bleeding from this area, a local haemostatic agent (PerClot) is applied (Figure 3) followed by the uterine closure. Despite the apparent 'large' defect left after removal of the invaded myometrium, the contraction and retraction

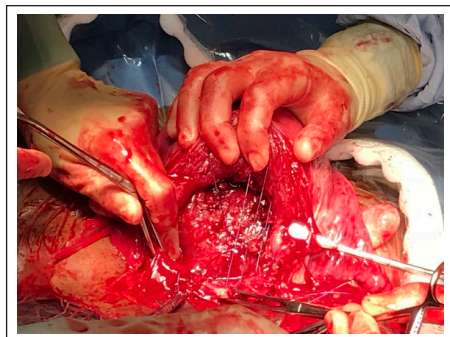


Figure 2. Anterior wall uterine defect after myometrial excision. Note approximately 2 cm lower myometrial margin to facilitate closure.

of the uterus allows an easy repair of the myometrial defect, by initially placing three 'box sutures' to approximate the myometrial edges, followed a 'routine' second-layer closure (Figure 4).

After the surgery, the balloons are left inflated for approximately 2 h, and then, the occlusive balloons are deflated. The intra-vascular catheters are removed after 24 h if there are no complications. If bleeding occurs during this time, embolization could be performed through these catheters.

Therefore, the Triple P procedure is different from the traditional segmental resection or the 'one-step' conservative approach because the Triple P procedure combines the access to the myometrium above the upper border of the placenta and pelvic devascularization, which facilitates the reduction of intra-operative blood loss.

The recommendations in preparation for the surgery include ensuring at least four units of cross-matched blood being available in the operating theatre immediately prior to commencing surgery; ensuring the availability of the cell saver; and the involvement of a multidisciplinary team including anaesthetists, interventional radiologists, specialist midwife, availability of an intensive treatment unit (ITU) bed in case if required and a neonatologist as the caesarean section is usually performed before 37 weeks, and a course of steroids should be administered to minimize respiratory distress syndrome on the new born. As the Triple P procedure does not require a cystotomy, the presence of a urologist is not routinely required, except if there is an unintended cystotomy.

The main advantage of this surgical approach is that it significantly reduces the morbidity. The results from the first 50 cases of Triple P procedure from the Regional Referral Service for Abnormal Invasion of the Placenta at St George's Maternity Unit in London, UK, suggest an average blood loss of 2.3 L, with 40% of patients not requiring a blood transfusion and only three patients requiring embolization due to secondary postpartum haemorrhage, and there was only one cystotomy. None of the 50 patients required a peripartum hysterectomy

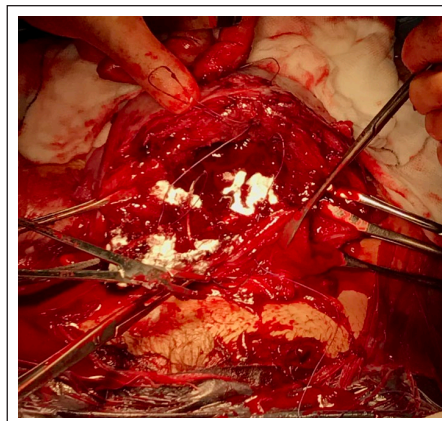


Figure 3. Application of the white powder, the PerClot (local haemostat) to the areas of bladder invasion.

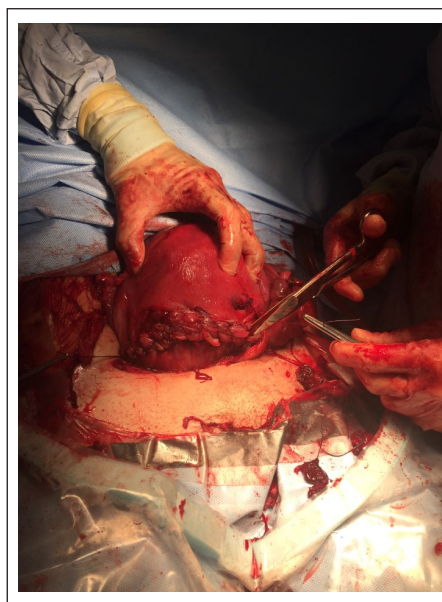


Figure 4. Second-layer closure of the myometrial defect. Note the use of three 'box sutures' with a 110-mm needle to close the first layer without tension, prior to continuous second-layer closure.

(unpublished data from the authors). In contrast, peripartum hysterectomy has been associated with significant maternal morbidity and mortality, which include massive blood loss, which may exceed 10,000 mL in up to 13% of patients.²⁰ Injury to adjacent organs such as the urinary bladder may occur in up to 6%–29%^{21,22} and injury to the ureters in up to 7% of cases.^{23,24} The maternal mortality rate has been reported to be of 1%–6%.^{23–26} It is important to note that bladder injury remains a risk even in interval hysterectomy, and it has been reported that intentional cystotomy and a partial cystotomy may be required in up to 33% of cases of delayed or interval hysterectomy.²⁷

Postnatal follow-up for these patients involves quantification of β -hCG after the surgery and 6 weeks postnatally, together with an ultrasound scan. By 6 weeks, most of the patients (>92%) have complete resorption of the placental tissue left in situ if any was left at all and normal involution of the uterus. None of the 50 patients who had undergone the Triple P procedure had any evidence of placental tissue on transvaginal ultrasound examination after 10 weeks. Anterior and posterior placental invasion (i.e. from a central major degree placenta praevia, traversing the cervix) and the need for additional measures such as tamponade have been shown to increase post-operative hospitalization in women who underwent the Triple P procedure.²⁸

The Triple P procedure was not originally conceived to preserve fertility as the risk of a new episode of abnormally invasive placenta in a subsequent pregnancy will be considerably high. Therefore, approximately 70% of the patients underwent bilateral tubal ligation at the time of the operation; however, the first successful case of pregnancy after Triple P procedure has been recently reported.²⁹ There were no signs of AIP in the new pregnancy and the patient had an uncomplicated caesarean section.²⁸ Although this excellent outcome should be taken with caution, it gives a choice for women who potentially want to have more children after a case of abnormally invasive placenta. A recent comparative cohort study has reported that the Triple P procedure was associated with significantly lower incidence of massive postpartum haemorrhage and reduced inpatient hospital stay, with no cases of peripartum hysterectomy.³⁰

Recent developments

The 'smudged egg sign' and the 'modified Triple P procedure'. Mehdi et al.³¹ recently described a 'smudged egg' sign on peri-operative abdominal ultrasound scan, in cases of placental invasion into the urinary bladder, leading to the loss of echo-free space between Foley's catheter balloon in the bladder and the detrusor wall. This sign may help clinicians to anticipate massive obstetric haemorrhage prior to commencing surgery for AIP.

Forty-five cases of 'modified' Triple P procedures have been performed by applying a tourniquet to the lower uterine segment, instead of prophylactic placement of occlusive balloon catheters,³² and 35 cases of 'modified' Triple P procedure have been performed by a temporary occlusion of internal iliac arteries with a vascular clamp immediately prior to the myometrial excision.³³ Therefore, in 'low-resource' settings, where interventional radiology services are not available 24/7, either temporary clamping of the internal iliac arteries or application of a tourniquet may be attempted, instead of inflation of pre-positioned occlusive balloons. Similarly, if there is abnormal invasion of the placenta in the upper uterine segment, such as invasion at the site of previous cornual ectopic pregnancy

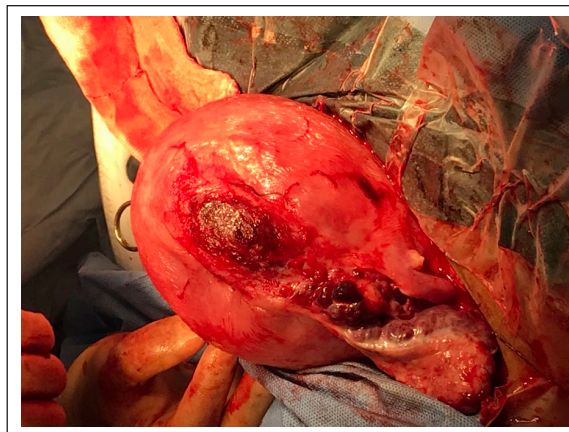


Figure 5. A cornual placenta percreta at the site of excision of previous cornual ectopic pregnancy.

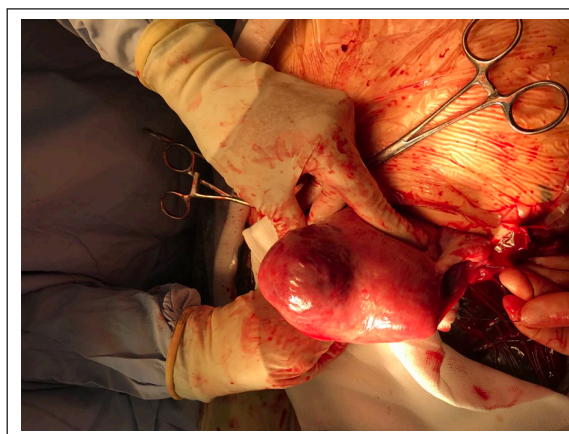


Figure 6. Placenta percreta invading one of the horns of a bicornuate uterus.

(Figure 5) or invasion of one of the horns of a bicornuate uterus (Figure 6), bilateral ligation of the uterine arteries is appropriate, instead of prophylactic occlusive balloon placement. This is because there will not be feeding vessels from the vesical and vaginal arteries in the upper segment during myometrial excision (Figure 7).

The international consensus guidelines on PAS disorders by the International Federation of Gynaecology and Obstetrics (FIGO)³⁴ and the 'Green-top Guidelines' on abnormal invasion of the placenta produced by the Royal College of Obstetricians and Gynaecologists (RCOG)³⁵ in 2018 have recommended both radical and conservative surgical options, including the Triple P procedure as viable surgical alternatives in AIP.

General considerations

Management of abnormal invasion of the placenta depends on the diagnosis (i.e. acreta, increta or percreta with or

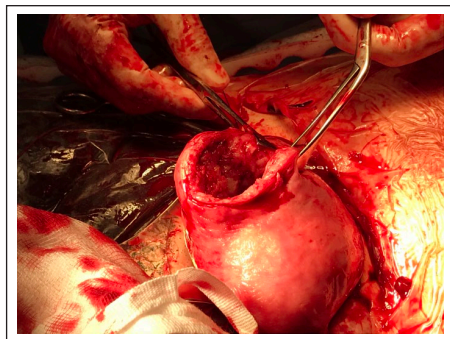


Figure 7. Myometrial excision of area of placental invasion in the upper segment after bilateral ligation of uterine arteries.

without adjacent organ involvement), surgical and anaesthetic expertise available, resources (i.e. facilities for blood transfusion, interventional radiology) as well as the woman's choice for future fertility. Irrespective of the surgical technique of choice, women with a high suspicion or confirmed abnormally invasive placenta should be managed in a specialist centre with surgical expertise with a multidisciplinary team who is experienced in managing these complex cases with an immediate availability of blood products, interventional radiology service, an intensive care unit and a neonatal intensive care unit to optimize the outcomes.

Elective delivery is recommended between 35 and 37 weeks to achieve the best balance between the risks of prematurity and the risk of emergency delivery. The RCOG does not recommend the routine use of ureteric stents as there are currently insufficient data; however, this may have a role when the urinary bladder is invaded by placental tissue or if it is anticipated that there is a parametrial invasion with a high risk of ureteric injury during the surgery.³⁵

Conclusion

There has been an exponential increase in the number of cases of PAS disorders in recent years, and this is likely to further increase in the coming years as a result of increasing numbers of caesarean section delivery and assisted reproduction techniques.

The key to improve maternal and foetal outcomes is prenatal diagnosis. As the incidence increases, the expertise of clinicians improves, and currently, ultrasound is as good as MRI in diagnosing AIP when performed by an experienced operator, especially for an anterior placental invasion.

This increase has also driven the need to develop new surgical techniques in an attempt to be more conservative and reduce the short- and long-term physical and psychological consequences of the classical peripartum hysterectomy. Among them, the Triple P procedure (and its modifications) has shown to have excellent surgical outcomes, with minimum maternal and neonatal morbidity,

and the potential to preserve fertility, in women who desire further pregnancies, after appropriate counselling.

Declaration of conflicting interests

The author(s) declared no potential conflicts of interest with respect to the research, authorship and/or publication of this article.

Funding

The author(s) received no financial support for the research, authorship and/or publication of this article.

ORCID iD

Edwin Chandraharan  <https://orcid.org/0000-0002-5711-8515>

References

1. Irving C and Hertig AT. A study of placenta accreta. *Surg Gynecol Obstet* 1937; 64: 178–200.
2. Fitzpatrick KE, Sellers S, Spark P, et al. Incidence and risk factors for placenta accreta/increta/percreta in the UK: a national case-control study. *PLoS ONE* 2012; 7(12): e52893.
3. Hudon L, Belfort MA and Broome DR. Diagnosis and management of placenta percreta: a review. *Obstet Gynecol Surv* 1998; 53(8): 509–517.
4. O'Brien JM, Barton JR and Donaldson ES. The management of placenta percreta: conservative and operative strategies. *Am J Obstet Gynecol* 1996; 175(6): 1632–1638.
5. Bowman ZS, Manuck TA, Eller AG, et al. Risk factors for unscheduled delivery in patients with placenta accreta. *Am J Obstet Gynecol* 2014; 210(3): 241.e1–241.e6.
6. Shamshirsaz AA, Fox KA, Salmanian B, et al. Maternal morbidity in patients with morbidly adherent placenta treated with and without a standardized multidisciplinary approach. *Am J Obstet Gynecol* 2015; 212(2): 218.e1–218.e9.
7. Shamshirsaz AA, Fox KA, Erfani H, et al. Multidisciplinary team learning in the management of the morbidly adherent placenta: outcome improvements over time. *Am J Obstet Gynecol* 2017; 216(6): 612.e1–612.e5.
8. Fitzpatrick KE, Sellers S, Spark P, et al. Incidence and risk factors for placenta accreta/increta/percreta in the UK: a national case-control study. *PLoS ONE* 2012; 7(12): e52893.
9. Thurn L, Lindqvist PG, Jakobsson M, et al. Abnormally invasive placenta-prevalence, risk factors and antenatal suspicion: results from a large population-based pregnancy cohort study in the Nordic countries. *BJOG* 2016; 123: 1348–1355.
10. Marshall NE, Fu R and Guise JM. Impact of multiple cesarean deliveries on maternal morbidity: a systematic review. *Am J Obstet Gynecol* 2011; 205(3): 262.e1–262.e8.
11. Fitzpatrick K, Sellers S, Spark P, et al. The management and outcomes of placenta accreta, increta and percreta in the UK: a population based descriptive study. *BJOG* 2014; 121(1): 62–70.
12. Baughman WC, Corteville JE and Shah RR. Placenta accrete: spectrum of US and MR findings. *Radiographics* 2008; 28: 1905–1916.
13. Coady AM and Bower S. *Twining's textbook of fetal abnormalities*. London: Churchill Livingstone.

14. D'Antonio F, Iacovella C and Bhide A. Prenatal identification of invasive placentation using ultrasound: systematic review and meta-analysis. *Ultrasound Obstet Gynecol* 2013; 42: 509–517.
15. D'Antonio F, Iacovella C, Palacios-Jaraquemada J, et al. Prenatal identification of invasive placentation using Magnetic resonance imaging: systematic review and meta-analysis. *Ultrasound Obstet Gynecol* 2014; 44(1): 8–16.
16. Timmermans S, van Hof AC and Duvekot JJ. Conservative management of abnormally invasive placentation. *Obstet Gynecol Surv* 2007; 62(8): 529–539.
17. Meyer NP, Ward GH and Chandrharan E. Conservative approach to the management of morbidly adherent placentae. *Ceylon Med J* 2012; 57(1): 36–39.
18. Athanasias P, Krishna A, Karoshi M, et al. Uterocutaneous fistula following classical caesarean delivery for placenta percreta with intentional retention of the placenta. *J Obstet Gynaecol* 2013; 33(8): 906–907.
19. Chandrharan E, Rao S, Belli A-M, et al. The Triple-P procedure as a conservative surgical alternative to peripartum hysterectomy for placenta percreta. *Int J Gynaecol Obstet* 2012; 117(2): 191–194.
20. Wright JD, Pri-Paz S, Herzog TJ, et al. Predictors of massive blood loss in women with placenta accreta. *Am J Obstet Gynecol* 2011; 205(1): 38.e1–38.e6.
21. Hoffman MS, Karlinski RA, Mangar D, et al. Morbidity associated with nonemergent hysterectomy for placenta accreta. *Am J Obstet Gynecol* 2010; 202(6): 628.e1–628.e5.
22. Eller AG, Bennett MA, Sharshiner M, et al. Maternal morbidity in cases of placenta accreta managed by a multidisciplinary care team compared with standard obstetric care. *Obstet Gynecol* 2011; 117: 331–337.
23. Awan N, Bennett MJ and Walters WA. Emergency peripartum hysterectomy: a 10-year review at the Royal Hospital for Women, Sydney. *Aust N Z J Obstet Gynaecol* 2011; 51(3): 210–215.
24. Wright JD, Devine P, Shah M, et al. Morbidity and mortality of peripartum hysterectomy. *Obstet Gynecol* 2010; 115: 1187–1193.
25. Knight M. Peripartum hysterectomy in the UK: management and outcomes of the associated haemorrhage. *BJOG* 2007; 114: 1380–1387.
26. Yucel O, Ozdemir I, Yucel N, et al. Emergency peripartum hysterectomy: a 9-year review. *Arch Gynecol Obstet* 2006; 274(2): 84–87.
27. TamTam KB, Dozier J and Martin JN Jr. Approaches to reduce urinary tract injury during management of placenta accreta, increta, and percreta: a systematic review. *J Matern Fetal Neonatal Med* 2012; 25(4): 329–334.
28. ElTahan M, Carrillo AP, Moore J, et al. Predictors of post-operative hospitalisation in women who underwent the Triple-P Procedure for abnormal invasion of the placenta. *J Obstet Gynaecol* 2018; 38(1): 71–73.
29. Cauldwell M, Chandrharan E, PinasCarillo A, et al. Successful pregnancy outcome in woman with history of Triple P procedure for placenta percreta. *Ultrasound Obstet Gynecol* 2018; 51(5): 696–697.
30. Teixidor Vinas M, Belli AM, Arulkumaran S, et al. Prevention of postpartum hemorrhage and hysterectomy in patients with morbidly adherent placenta: a cohort study comparing outcomes before and after the introduction of the Triple P procedure. *Ultrasound Obstet Gynecol* 2015; 46: 350–355.
31. Mehdi M, Bhide A, Moore J, et al. Is the 'smudged-egg' sign during the peri-operative ultrasound scan in abnormal invasion of the placenta (AIP) associated with excessive intra-operative blood loss during the Triple P Procedure? Book of Abstracts. In: *Proceedings of the 27th world congress on controversies in obstetrics, gynecology & infertility (COGI)*, London, 27 November 2018.
32. Wei Y, Cao Y, Yu Y, et al. Evaluation of a modified 'Triple-P' procedure in women with morbidly adherent placenta after previous caesarean section. *Arch Gynecol Obstet* 2017; 296(4): 737–743.
33. Tskhay VB, Yametov PK and Yametova NM. (2017) The use of modified Triple-P method with adherent placenta long-term results. *MOJ Womens Health* 2017; 4(2): 30–32.
34. Sentilhes L, Kayem G, Chandrharan E, et al. FIGO consensus guidelines on placenta accreta spectrum disorders: conservative management. *Int J Gynaecol Obstet* 2018; 140(3): 291–298.
35. Royal College of Obstetricians and Gynaecologists Green Top Guideline no. 27a. *Placenta praevia and placenta accrete: diagnosis and management*. London: RCOG Press, 2018.