




# A Long-Term Follow-up Study for the Treatment of Snoring after Using Patterned Non-Ablative Erbium: YAG 2,940 nm Laser

Ahmed N. Kassab<sup>1</sup>  Ahmed El Kharbotly<sup>1</sup> Ahmed Abd Elsamie<sup>2</sup> Mohamed Rifaat Ahmed<sup>3</sup>

<sup>1</sup>Department of Otorhinolaryngology, National Institute of Laser Enhanced Sciences, Cairo University, Cairo, Egypt

<sup>2</sup>Department of Radiology, Theodor Bilharz Research Institute – Tbr, Giza, Egypt

<sup>3</sup>Department of Otorhinolaryngology, Faculty of Medicine Suez Canal University, Ismailia, Egypt

Address for correspondence Ahmed N. Kassab, MD, Department of Otorhinolaryngology, National Institute of Laser Enhanced sciences, Cairo University, Cairo, Egypt (e-mail: kassabahmed28@yahoo.com).

Int Arch Otorhinolaryngol 2023;27(1):e104–e110.

## Abstract

**Introduction** Laser uvulopalatoplasty is an established operation for the treatment of snoring with good results on a short-term basis, while long-term follow-up studies, in addition to their scarcity, had conflicting results regarding recurrence, the change of snoring quality, and complications.

**Objective** To assess the long-term follow-up results of using nonablative 2,940 nm Erbium: YAG for the treatment of snoring regarding outcomes and recurrence.

**Methods** This 2-year follow-up study was conducted on 76 patients operated upon by non-ablative 2940 nm Erbium: yttrium-aluminum-garnet (YAG) using a PS01 patterned headpiece. Subjective evaluation of the treatment was performed relying on a smartphone application to record snoring in addition to a questionnaire specially designed to report recurrence and change in the quality of snoring reported by a patient's spouse. The objective evaluation was done by computed tomography (CT) imaging of the soft palate. The patients were evaluated preoperatively, 6 weeks postoperatively and after a 2-year follow-up period.

**Results** Six week after the procedure, there was a significant improvement in 52 patients (68.4%). Out of the 52 patients, only 43 completed the 2-year follow-up; however, 15 of them complained of recurrence. Nevertheless, the patients who suffered from recurrence showed subjective improvement in snoring quality.

**Conclusions** The nonablative mode of Erbium: YAG 2,940 nm laser proved to be efficient in soft palate tightening for the management of snoring. However, there was recurrence in 34.8% of the patients who presented objective and subjective improvement of the complaints, 6 weeks postoperatively and after a 2-year follow-up period.

## Keywords

- ▶ laser
- ▶ snoring
- ▶ long term follow-up period

received  
September 1, 2020  
accepted after revision  
January 23, 2022

DOI <https://doi.org/10.1055/s-0042-1744171>.  
ISSN 1809-9777.

© 2023. Fundação Otorrinolaringologia. All rights reserved.  
This is an open access article published by Thieme under the terms of the Creative Commons Attribution-NonDerivative-NonCommercial-License, permitting copying and reproduction so long as the original work is given appropriate credit. Contents may not be used for commercial purposes, or adapted, remixed, transformed or built upon. (<https://creativecommons.org/licenses/by-nc-nd/4.0/>)  
Thieme Revinter Publicações Ltda., Rua do Matoso 170, Rio de Janeiro, RJ, CEP 20270-135, Brazil

## Introduction

Snoring is a common form of sleep-disordered breathing, which affects more than 30% of the adults in the worldwide population. It is commonly due to obesity, nasal obstruction, or other factors related with the soft palate, tonsils, uvula, base of the tongue, and lateral pharyngeal walls. Often, the problem is caused by vibration of the pharyngeal soft tissue, most commonly redundant soft palate and an elongated uvula. Therefore, in such cases, the treatment focuses on reducing these vibrations.<sup>1–5</sup> Snoring is often associated with obstructive sleep apnea (OSA).<sup>6,7</sup> There have been many options for the treatment of snoring, for instance, in some cases, a possible treatment is by lifestyle changes, such as diet, exercise, cessation of smoking or alcohol intake, and changing the sleeping position.<sup>8–12</sup> On the other hand, many surgical techniques have been advocated in the search for the optimal treatment of snoring. Procedures including traditional uvulopalatopharyngoplasty, electrocautery, lasers, and radiofrequency have been applied. However, surgical procedures may be associated with some significant complications, such as pain, hemorrhage, infection, scarring, and malfunction.<sup>13–15</sup> The Er: YAG laser is a solid-state laser, which emits a wavelength of 2,940 nm in the mid-infrared region with minimal depth of penetration. It can be used in either an ablative or nonablative mode. In the case of nonablative modes, it is reported to be an effective and noninvasive method for soft palate tightening without postoperative complications that other types of ablative lasers may cause.<sup>16–18</sup>

The present study aimed to evaluate the short and long-term outcomes of the nonablative mode of Erbium: YAG laser in the treatment of snoring without OSA, regarding improvement and recurrence.

## Materials and Methods

The study was conducted according to the criteria set by the declaration of Helsinki. The scientific ethical committee and the medical ethics board approved the study. Eighty-eight patients complaining of snoring without OSA presented to the ear, nose, and throat (ENT) outpatient clinic, in the period from January 2017 until March 2018. Out of 88 patients, 76 met all inclusion criteria. The patients signed the informed consent forms after being sufficiently informed about laser therapy, its benefits, and possible risks. Besides, personnel information, age, height, weight, address, phone numbers, and occupation were all registered.

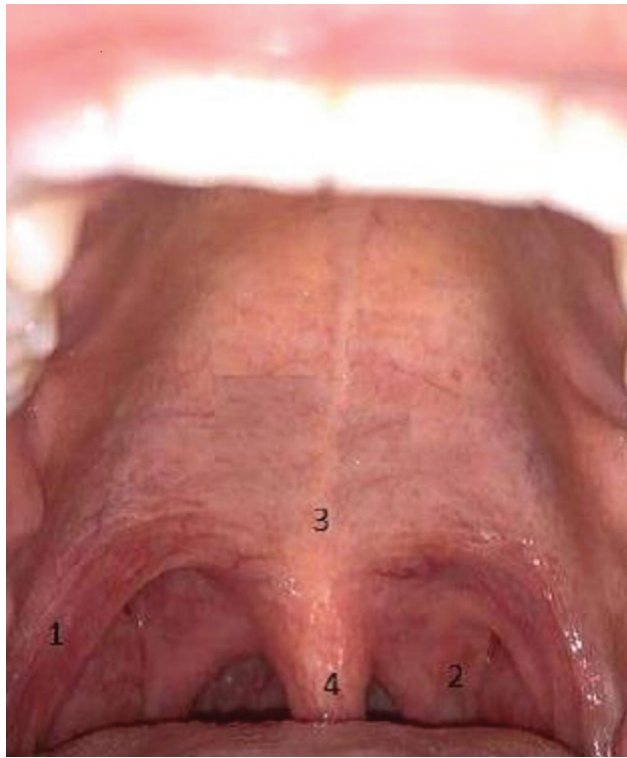
The patients' age ranged from 50 to 70 years (mean  $60 \pm 5$  years), 54 males and 22 females, and their body mass index were below 30. All patients were subjected to full clinical examination including oropharyngeal examination, nasal endoscopy, and Muller maneuver, besides medical history reporting. The patients were referred to the sleep laboratory unit for level-one sleep study polysomnography examination, in which patients with apnea/hypopnea index (AHI)  $> 5$  and respiratory distress index (RDI)  $> 5$  events/hour were excluded. The exclusion criteria also included patients suf-

fering from systemic illness such as hypertension or diabetes, pregnant women, and patients using photosensitive medications. Also, patients who were complaining of nasal obstruction, hypertrophied tonsils (more than grade 2 according to the Brodsky grading scale), marked tongue enlargement, characterized by a highly arched tongue, and increase in its transverse axis as revealed by computed tomography (CT) examination were excluded. In this study, all the included patients with redundant soft palate and uvula were considered class 3 according to the Mallampati score modified by Friedman (visualization of only the base of the uvula). Other scores were excluded, as the higher the scores, the more likely those patients would develop OSA, while patients with lower scores might not suffer from the redundant soft palate.

The patients were operated upon by 2,940 nm Erbium: YAG for soft palate tightening. Each patient completed a nonablative laser procedure protocol that consisted of 3 sessions, 2 weeks apart over 6 weeks. The sessions were completed even though the patient felt some improvement, to achieve complete satisfaction of the patients. The three sessions protocol was adopted based on a previous pilot study performed by the authors. The procedure was performed under local anesthesia; the patient adopted a sitting position wearing protective glasses. Local anesthesia was initiated with a 10% lidocaine spray directed at the soft palate, then maintained by placing a cotton swab moistened with lidocaine over the soft palate utilizing an artery forceps and held in place for 2 minutes. This did not only achieve the primary effect of anesthesia but also prevented the gag reflex that may follow. The Er: YAG laser (Fotona Xs Dynamics, Slovenia) equipped with a PS01 patterned handpiece and spot size 7 mm diameter was used. The parameters applied were nonablative and minimally invasive. Energy fluency of 2.4 J/cm<sup>2</sup> was used with a very long pulse (VLP) duration mode and frequency of 8 Hz. The palatoglossal arch, palatopharyngeal arch, soft palate, and uvula were the target tissues to be laser four times in a precise manner either vertically or horizontally (depending on the region) (→ Fig. 1). The tip of the laser handpiece was placed in a non-contact mode ~ 3 cm away from the targeted tissue, and the session lasted 15 minutes. As the treatment was nonablative, there were no special postoperative medications prescribed or pain killers. The patients were asked to inform us by phone about any discomfort or complaints after each laser session, throughout the short-term and during the long-term follow-up periods.

In addition to the patient's spouse reporting the changes in the quality of snoring, a subjective evaluation was conducted by calculating the snoring scores of the participating patients before and after laser treatment utilizing a smartphone downloaded application called Snorelab (Reviva Ltd., London, United Kingdom)<sup>19–21</sup> (→ Fig. 2).

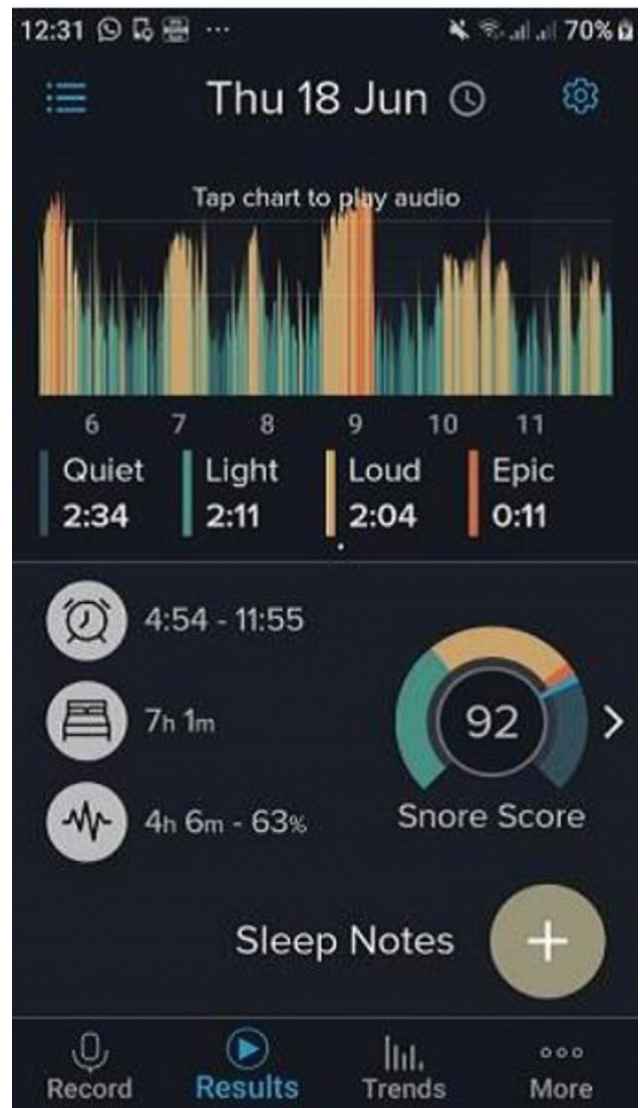A higher snore score indicated louder or more frequent snoring, while a lower snore score indicated quiet and/or less frequent snoring. To ensure the accuracy and credibility of the results, the reported scores represented a mean of three successive readings over one week while sleeping in a



**Fig. 1** Areas that were lasered. 1 - Palatoglossal arch. 2 - Palatopharyngeal arch. 3 - Soft palate. 4 - Uvula.

separate room to avoid any intruding noise. These values were achieved by using effective algorithms, as the application records and calculates a snoring score. The estimated snoring scores were calculated using the total duration of suspected snoring episodes during the night and the average volume of the snoring events relative to a baseline volume level of ~ 40 dB. Light snoring volume was considered if the value was < 50 dB, while loud snoring was considered if the volume was ≥ 50 dB, and, finally, “epic” snoring if the volume was ≥ 60 dB (► **Table 1**).

The objective evaluation of our results was performed by CT imaging of the soft palate, before the treatment and 6 weeks postoperatively, while in the long-term follow-up period, it was excluded to avoid financial burden on the patients. The length of the soft palate was determined by measuring the distance between the posterior nasal spine (posterior end of the hard palate) to the tip of the uvula in mid-sagittal sections.



**Fig. 2** Smart phone application (snore laboratory).

All patients underwent unenhanced multi-slice computed tomography (MSCT) studies using a 32-detector multislice CT scanner. The CT acquisition was designed to cover the entirety of the nasopharynx down to the upper larynx in a craniocaudal extent. The CT parameters were 120 kV, 200 mA, 2.5 mm nominal section thickness, a slice pitch of 2, and 2.5-mm reconstruction thickness. The patients were requested to hold their breath during the

**Table 1** Classification of snoring score grades with corresponding volume, duration and frequency

Grade	Snore score (represents volume and duration)	Snoring volume in dB	Snoring quality according to spouse questionnaire
Grade 1	Score below 30	Base line ~ 40 dB	Snoring rarely annoys partner
Grade 2	Score between 30–59	Light snoring: volume < 50 dB	Occasional snoring that sometimes disturbs partner
Grade 3	Score between 60–89	loud snoring: volume ≥ 50 dB	Disturbs partner most of the night
Grade 4	Score above 90	Epic snoring: volume ≥ 60 dB	Partner sleeps in a separate room every night

**Table 2** Improvement of snoring score grades in 24 patients who were not completely relieved 6 weeks postoperatively

Number of patients classified according to their snoring score grade preoperatively (Number = 24)	Number of patients classified according to their snoring score grade postoperatively			
	Grade 1	Grade 2	Grade 3	Grade 4
0 (grade 1)	0	0	0	0
5 (grade 2) →	4	1	0	0
9 (grade 3) →	0	7	2	0
10 (grade 4) →	0	2	4	4

study with acquisition time of ~ 12 seconds. All images were transferred to the workstation for postprocessing. Multiplanar reconstruction (MPR) was performed for all patients.

### Statistical Analysis

The data collected were processed using the IBM SPSS Statistics for Windows, Version 22.0 software package (IBM Corp., Armonk, NY, USA). The quantitative data were expressed as means ± standard deviation (SD), while the qualitative data were expressed as numbers and percentages. The Student *t*-test was used to compare the significance of the difference for the quantitative variables that followed a normal distribution.

### Results

Seventy-six patients completed 3 sessions of laser treatments, and the outcomes were evaluated 6 weeks postoperatively, and once again after 24 months. The majority of the patients expressed their satisfaction through phone calls, even after two laser sessions, while a small number of patients complained of mild pain after the treatment. No intraoperative or postoperative bleeding or scarring was reported or detected. The subjective evaluation of the results was based on the data delivered by the patients six weeks postoperatively after using the snore laboratory app and feedback from the patient spouse about the quality of snoring. Fifty-two patients (68.4%) declared their complete relief of snoring as evidenced by snore score 25, while 24 patients (31.6%) were not satisfied, as they felt slight improvement.

Hereby, aiming to assess the improvement of the unsatisfied patients, we compared their snoring scores grades preoperatively with their postoperative scores. The results showed that 17 of those patients were promoted to lower snoring score grades, while 7 patients felt some improvement, but it was not enough to change their snoring score grades. The results are listed in ▶Table 2 and summed up in ▶Table 3.

The results in ▶Tables 2 and 3 showed that even though the 24 patients who were not satisfied got better, and the treatment improved their snoring scores significantly, moreover, this was supported by the slight shrinkage in the soft palate revealed by CT imaging, which was our method for objective evaluation of our patients (▶Table 4) (▶Figs. 3 a and 3 b). Those patients needed additional laser sessions to achieve complete relief of snoring. But since we were committed to our three sessions treatment protocol, we decided to exclude them from the further long-term follow-up study, taking into account only the 52 patients who declared their complete satisfaction evidenced by better snore scores and CT imaging.

During the 2-year follow-up period, 9 of our patients dropped out for personal reasons (irrelevant to treatment), and only 43 patients completed the long-term follow-up. Fifteen patients out of the 43 (34.8%) reported recurrence of snoring. On comparing their pre and postoperative snore scores as shown in ▶Table 5 and summed up in ▶Table 6, the change in their snore score grades was not significant.

Assessment of the body mass index of the participating patients after 6 weeks revealed no change, while in the long-term follow-up period, there was a change in the reported values, yet it was not significant.

**Table 3** Preoperative compared with 6 weeks postoperatively snoring score grades for 24 patients who were not completely relieved

Preoperative			Postoperative			Chi squared test	P-value
Snore score grade	N = 24	Percentage	Score	N = 24	Percentage		
1	0	0%	1	4	16.6%	X <sup>2</sup> = 7.51	0.001**
2	5	20.8%	2	10	41.6%		
3	9	37.5%	3	6	25%		
4	10	41.6%	4	4	16.6%		

Chi-squared test is significant at the 95% confidence level.

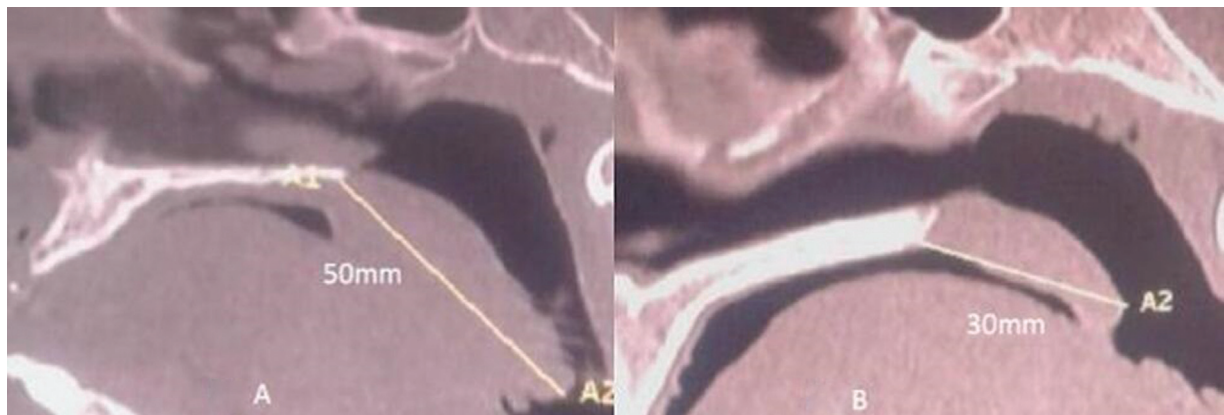
\*\*Significant  $p < 0.01$ .

**Table 4** Changes in the mean length of the soft palate (in mm) of 52 patients who were totally relieved compared with that of 24 patients who were slightly improved

Number of patients	Mean length of soft palate in mm ± SD		P-value
	Preoperative	Postoperative (6 weeks)	
Total improvement 52 patients	41.5 ± 5	37.4 ± 6	0.000259
Slight improvement 24 patients	42.6 ± 2	41.2 ± 3	0.06341

Abbreviation: SD, standard deviation.

High significant difference in the mean length of soft palate for patients who showed total improvement.



**Fig. 3** (A): Preoperative computed tomography image for a patient with a redundant elongated soft palate. (B) Six weeks postoperative computed tomography image of the same patient showing the shrinkage of the soft palate.

**Table 5** Improvement of snoring score grades in 15 patients who suffered snoring recurrence 24 months postoperatively

Number of patients classified according to their snoring score grade preoperatively (number = 15)	Number of patients classified according to their snoring score grade 24 months postoperatively			
	Grade 1	Grade 2	Grade 3	Grade 4
0 (grade 1)	0	0	0	0
1 (grade 2) →	0	1	0	0
4 (grade 3) →	0	3	1	0
10 (grade 4) →	0	0	1	0

**Table 6** Comparison of preoperative and 24-month postoperative snoring score grades of 15 patients who suffered snoring recurrence

Preoperative			Postoperative			Chi squared test	P-value
snore score grade	N = 15	percent	score	N = 15	percent		
1	0	0%	1	0	0%	X <sup>2</sup> = 0.64	0.445
2	1	6.6%	2	4	26.6%		
3	4	26.6%	3	11	73.3%		
4	10	66.6%	4	0	0%		

Chi-squared test is not significant at the 95% confidence level (2-tailed). P-value not significant.

## Discussion

Many types of surgical procedures for the management of snoring have been reported in the literature.<sup>5,22-24</sup> Besides these surgical treatments, some nonsurgical procedures are available.<sup>16,17</sup> Their main goal is to find a simple, safe, bloodless, and effective procedure that leads to a speedy recovery with no fibrosis or scarring, thus allowing patients to return to their normal daily life.

The use of different types of lasers for uvulopalatoplasty (LAUP) has been well recognized to reduce snoring. Ablative types of the laser, such as carbon dioxide or diode laser, have proven to be efficient for the treatment of snoring with variable clinical success rates. However, there were reports on complications such as bleeding, pain, scarring, and fibrosis.<sup>25,26</sup> Although non-ablative Er: YAG laser for soft palate tightening has been introduced as a noninvasive therapy for snoring, very few long-term follow-up studies are available in the literature regarding success rates and recurrence. This prompted us to investigate the outcomes of this relatively recent technique on the short and long-term follow-up regarding efficacy and recurrence.

The use of Er: YAG laser in a nonablative mode would result in hyperthermia. This may cause an increase in the production of collagen fibers type I, which are found in the tissues of the soft palate and uvula, resulting in the reduction of pharyngeal soft-tissue collapsibility, thus opening the airway and decreasing snoring.<sup>27-35</sup>

In a study by Liu et al.,<sup>27</sup> *in vivo* histological investigations on mouse models revealed that the laser photothermic effect increased fibroblast proliferation and the synthesis of both collagens type I and type III. They concluded that collagen remodeling and synthesis was due to laser temperature effects inside the lower dermis responsible for skin tightening.

Unver et al.<sup>36</sup> assessed the effects of nonablative Er: YAG laser irradiation on the histological structure of the soft palate in rats. They reported that the laser thermal effect led to contraction of the pharyngeal soft tissue, which eliminated its vibrations and resulted in airway expansion. Meanwhile, the mucosa remained intact, with no bleeding, severe inflammation, necrosis, or any other complications.

In a study by Miracki and Vizintin,<sup>37</sup> they reported that 74% of patients responded positively to the treatment. The average snoring severity scores before and at the first 2 follow-ups (at 14 and 45 days) improved by 50.5%, while the average total sleep disordered breathing (SDB) score improved by 46%. Svahnström K.<sup>16</sup> reported an 80% success rate in addition to great improvement in the lifestyle of patients as they could breathe much easier, suffer fewer headaches, and be more alert and focused. Cameron Y.S. Lee<sup>38</sup> achieved much better results – a 85.7% success rate – with a short follow-up period (12 weeks) and a small number of patients as he reported 6 out of 7 patients experienced an increase in total oropharyngeal airway volume, especially the most constricted area.

In our study, we used different parameters, a longer follow-up period, together with a different handpiece (PS01), which allows the delivery of energy in patterned columns, thus promoting collagen production, resulting in tightening of the soft palate tissue.<sup>39,40</sup> The present study showed that 24 patients were not satisfied with the treatment after 6 weeks; yet, their subjective and objective evaluations showed that they had improved significantly (► **Tables 2–4**). On the other hand, complete relief of snoring was accomplished in 52 patients, with a success rate 68.4% 6 weeks postoperatively, and, after exclusion of those patients who dropped out through the long follow-up period, we reported 34.8% of recurrence in the long-term follow-up (24 months). However, the recurrent cases did not return to the baseline concerning their subjective characteristics, as there was a positive shift of the snoring scores from high to lower values (► **Table 5** and **6**), denoting that those cases improved in snoring quality compared with their preoperative status, although this positive change was not statistically significant.

We hypothesize that our findings are attributed to the tightening effect of the Er: YAG laser on the soft palate, which was evident in the short-term follow-up period as revealed by CT imaging. This strong effect gradually decreased over the long-term follow-up period (24 months), which is probably due to the reduction of collagen fiber bundles with consequent softening of the soft-palate tissues that led to snoring recurrence in some patients.

The limitations of this study include the lack of a precise and accurate method to determine the improvement of the snoring volume other than the snore laboratory application as well as the loss of some patients to follow-up.

## Conclusions

This long-term follow-up study showed that using the nonablative mode of Er: YAG laser for soft-palate tightening yielded good results. There was no blood loss, no scarring, and it proved to be an efficient modality for the treatment of snoring in cases with redundant soft palate, with minimal pain and no postoperative complications. Of the 52 patients (68.4%) who were completely relived in the short term, only 43 patients completed 2 years of follow-up (9 patients dropped out for different reasons), achieving a 65.2% long-term success rate, while 34.8% reported snoring recurrence.

### Ethical Considerations

The local ethics committee approved the study. Written consent was obtained from all study participants. All participants included in the study have been informed about the procedures to be done and the expected results. All participants agreed to participate in the study by providing a written informed consent.

### Conflict of Interests

The authors have no conflict of interests to declare.

## References

- 1 Hsia JC, Camacho M, Capasso R. Snoring exclusively during nasal breathing: a newly described respiratory pattern during sleep. *Sleep Breath* 2014;18(01):159–164
- 2 Lugaresi E, Cirignotta F, Coccagna G, Baruzzi A. Snoring and the obstructive apnea syndrome. *Electroencephalogr Clin Neurophysiol Suppl* 1982;35(35):421–430
- 3 Wang Z, Rebeiz EE, Shapshay SM. Laser soft palate “stiffening”: an alternative to uvulopalatopharyngoplasty. *Lasers Surg Med* 2002;30(01):40–43
- 4 Rotenberg BW, Luu K. Four-year outcomes of palatal implants for primary snoring treatment: a prospective longitudinal study. *Laryngoscope* 2012;122(03):696–699
- 5 Chiesa Estomba CM, Rivera Schmitz T, Ossa Echeverri CC, Betances Reinoso FA, Fariña Conde J, Alonso Parraga D. The treatment of snoring by radiofrequency-assisted uvulopalatoplasty and results after one-session protocol: a prospective, longitudinal, non-randomized study. *Eur Arch Otorhinolaryngol* 2015;272(10):3059–3063
- 6 Mannarino MR, Di Filippo F, Pirro M. Obstructive sleep apnea syndrome. *Eur J Intern Med* 2012;23(07):586–593
- 7 Johns MW. Daytime sleepiness, snoring, and obstructive sleep apnea. The Epworth Sleepiness Scale. *Chest* 1993;103(01):30–36
- 8 Peppard PE, Young T. Exercise and sleep-disordered breathing: an association independent of body habitus. *Sleep* 2004;27(03):480–484
- 9 Tuomilehto HP, Seppä JM, Partinen MM, et al; Kuopio Sleep Apnea Group. Lifestyle intervention with weight reduction: first-line treatment in mild obstructive sleep apnea. *Am J Respir Crit Care Med* 2009;179(04):320–327
- 10 Huang R, Ho SY, Lo WS, Lai HK, Lam TH. Alcohol consumption and sleep problems in Hong Kong adolescents. *Sleep Med* 2013;14(09):877–882
- 11 Mehari A, Weir NA, Gillum RF. Gender and the association of smoking with sleep quantity and quality in American adults. *Women Health* 2014;54(01):1–14
- 12 Schmidt-Nowara W, Lowe A, Wiegand L, Cartwright R, Perez-Guerra F, Menn S. Oral appliances for the treatment of snoring and obstructive sleep apnea: a review. *Sleep* 1995;18(06):501–510
- 13 Baisch A, Maurer JT, Hörmann K, Stuck BA. Combined radiofrequency assisted uvulopalatoplasty in the treatment of snoring. *Eur Arch Otorhinolaryngol* 2009;266(01):125–130
- 14 Hultcrantz E, Harder L, Loord H, et al. Long-term effects of radiofrequency ablation of the soft palate on snoring. *Eur Arch Otorhinolaryngol* 2010;267(01):137–142
- 15 Kezirian EJ, Weaver EM, Yueh B, Khuri SF, Daley J, Henderson WG. Risk factors for serious complication after uvulopalatopharyngoplasty. *Arch Otolaryngol Head Neck Surg* 2006;132(10):1091–1098
- 16 Svahnström K. Er:YAG Laser Treatment of Sleep-Disordered Breathing. *J Laser Heal Acad*. 2013;2:13–16
- 17 Fiz JA, Morera Prat J, Jané R [Treatment of patients with simple snoring]. [English Ed] *Arch Bronconeumol* 2009;45(10):508–515
- 18 Dovsak D, Gabrijelcic J, Vizintin Z. Night Laser TM – a New Laser Treatment Method for the Reduction of Snoring and Sleep Apnea – a Pilot Study. *J Laser Health Academy* 2011;1:9–10
- 19 Camacho M, Robertson M, Abdullatif J, et al. Smartphone apps for snoring. *J Laryngol Otol* 2015;129(10):974–979
- 20 Ko PR, Kientz JA, Choe EK, Kay M, Landis CA, Watson NF. Consumer sleep technologies: a review of the landscape. *J Clin Sleep Med* 2015;11(12):1455–1461
- 21 Sands SA, Owens RL. Does my bed partner have OSA? There's an app for that!. *J Clin Sleep Med* 2014;10(01):79–80
- 22 Fujita S, Conway W, Zorick F, Roth T. Surgical correction of anatomic abnormalities in obstructive sleep apnea syndrome: uvulopalatopharyngoplasty. *Otolaryngol Head Neck Surg* 1981;89(06):923–934
- 23 Haytoglu S, Kayabasoglu G, Sezen OS. Comparison of Two Techniques in Simple Snoring and Obstructive Sleep Apnea Syndrome Patients: Palatal Implant or Uvulopalatal Flap. *Eur J Gen Med* 2014;11(03):179–186
- 24 Poyrazoglu E, Dogru S, Saat B, Güngör A, Cekin E, Cincik H. Histologic effects of injection snoreplasty and radiofrequency in the rat soft palate. *Otolaryngol Head Neck Surg* 2006;135(04):561–564
- 25 Franklin KA, Anttila H, Axelsson S, et al. Effects and side-effects of surgery for snoring and obstructive sleep apnea—a systematic review. *Sleep* 2009;32(01):27–36
- 26 Barion, Umberto Diode Laser Assisted Uvulopalatoplasty in the Treatment of Snoring. 4th european congress of Oto Rhino Laryngology head and neck surgery Berlin Germany. 2000. May 13 - 18
- 27 Liu H, Dang Y, Wang Z, Chai X, Ren Q. Laser induced collagen remodeling: a comparative study in vivo on mouse model. *Lasers Surg Med* 2008;40(01):13–19
- 28 Goldberg DJ, Whitworth J. Laser skin resurfacing with the Q-switched Nd:YAG laser. *Dermatol Surg* 1997;23(10):903–906, discussion 906–907
- 29 Goldberg DJ, Silapunt S. Q-switched Nd:YAG laser: rhytid improvement by non-ablative dermal remodeling. *J Cutan Laser Ther* 2000;2(03):157–160
- 30 Trelles MA, Allones I, Luna R. Facial rejuvenation with a non-ablative 1320 nm Nd:YAG laser: a preliminary clinical and histologic evaluation. *Dermatol Surg* 2001;27(02):111–116
- 31 Rogachefsky AS, Becker K, Weiss G, Goldberg DJ. Evaluation of a long-pulsed Nd:YAG laser at different parameters: an analysis of both fluence and pulse duration. *Dermatol Surg* 2002;28(10):932–935, discussion 936
- 32 Dayan S, Damrose JF, Bhattacharyya TK, et al. Histological evaluations following 1,064-nm Nd:YAG laser resurfacing. *Lasers Surg Med* 2003;33(02):126–131
- 33 Dayan SH, Vartanian AJ, Menaker G, Mobley SR, Dayan AN. Non-ablative laser resurfacing using the long-pulse (1064-nm) Nd:YAG laser. *Arch Facial Plast Surg* 2003;5(04):310–315
- 34 Trelles MA, Alvarez X, Martín-Vázquez MJ, et al. Assessment of the efficacy of nonablative long-pulsed 1064-nm Nd:YAG laser treatment of wrinkles compared at 2, 4, and 6 months. *Facial Plast Surg* 2005;21(02):145–153
- 35 Fomin D, Nicola E, Oliver C, et al. Collagen type analysis in the soft palate after surgical intervention with CO(2) laser and radiofrequency ablation. *Photomed Laser Surg* 2007;25(05):449–454
- 36 Unver T, Aytugan E, Ozturan O, Kiran T, Ademci E, Usumez A. Histological Effects of Er:YAG Laser Irradiation with Snoring Handpiece in the Rat Soft Palate. *Photomed Laser Surg* 2016;34(08):40–44
- 37 Miracki K, Vizintin Z. Nonsurgical Minimally Invasive Er: YAG Laser Snoring Treatment Journal of the Laser and Health Academy. 2013;1:36–41
- 38 Cameron YS. LEE. Evaluation of a non-ablative Er: YAG laser procedure to increase the oropharyngeal airway volume: A pilot study Dental, Oral and Craniofacial Research. 2015; (1) (3): 56–59
- 39 Manstein D, Herron GS, Sink RK, Tanner H, Anderson RR. Fractional photothermolysis: a new concept for cutaneous remodeling using microscopic patterns of thermal injury. *Lasers Surg Med* 2004;34(05):426–438
- 40 Laubach HJ, Tannous Z, Anderson RR, Manstein D. Skin responses to fractional photothermolysis. *Lasers Surg Med* 2006;38(02):142–149