

Received: 2015.01.01
Accepted: 2015.02.12
Published: 2015.05.26

Coronary Slow Flow Accompanying Exertional Blurred Vision and Effects of Corticosteroids

Authors' Contribution:
Study Design A
Data Collection B
Statistical Analysis C
Data Interpretation D
Manuscript Preparation E
Literature Search F
Funds Collection G

ABCDEF 1 Şahbender Koç
ABCDE 2 Aslı Vural
ABCDE 1 Hakan Aksoy
ABCD 1 Barış Dindar
CDEF 2 Ahmet Karagöz
DEF 3 Zeki Yüksel Günaydın
EF 3 Osman Bektaş

1 Department of Cardiology, Kırıkkale Yüksek İhtisas State Hospital, Kırıkkale, Turkey
2 Department of Cardiology, Giresun University, Giresun, Turkey
3 Department of Cardiology, Ordu University, Ordu, Turkey

Corresponding Author: Ahmet Karagöz, e-mail: drahmetkgz@hotmail.com





Conflict of interest: None declared

Patient: Male, 44
Final Diagnosis: Coronary slow flow
Symptoms: Blurring of vision • chest pain
Medication: —
Clinical Procedure: Medical treatment
Specialty: Cardiology

Objective: Unusual clinical course
Background: Various pathophysiological mechanisms such as microvascular and endothelial dysfunction, small vessel disease, diffuse atherosclerosis, and inflammation have been held responsible in the etiology of coronary slow flow. It is also thought to be a reflection of a systemic slow-flow phenomenon in the coronary arterial tree.
Case Reports: A 44-year-old man presented with chest pain causing fatigue, together with blurred vision for the last 2 years, which disappeared after resting. He had used corticosteroid therapy for facial paralysis 1 month ago. Coronary slow flow was detected in all 3 major coronary arteries on coronary angiography. TIMI measurements for the left anterior descending artery, circumflex, and right coronary artery were 64, 72, and 55, respectively. In fundus fluorescein angiography, retinal vascularity was normal, the arm-to-retina circulation time was 21.8 s, and the arteriovenous transit time was 4.3 s. In the early arteriovenous phase, choroidal filling was long, with physiological patchy type. Diltiazem 90 mg/day and acetylsalicylic acid 100 mg/day were given. His chest pain and visual symptoms disappeared after medical treatment.
Conclusions: Physicians should be aware that glucocorticoids might cause an increase in the symptoms of coronary slow flow and some circulation problems, which might lead to systematic symptoms.

MeSH Keywords: Desoxycorticosterone • Microvascular Angina • No-Reflow Phenomenon

Full-text PDF: <http://www.amjcaserep.com/abstract/index/idArt/893461>

 1189   2  11



Background

Normal coronary arteries might be seen in fifteen percent of patients with anginal symptoms who underwent coronary angiography. In some cases contrast agent passage through the coronary artery may be slow which is defined as coronary slow flow (CSF). In other words coronary slow flow (CSF) is characterized by the delayed opacification of coronary arteries in the absence of obstructive coronary artery disease (CAD) on coronary angiography [1]. Although various pathophysiological mechanisms such as microvascular and endothelial dysfunction, small vessel disease, diffuse atherosclerosis, and inflammation have been held responsible in the etiology of CSF, a clear causal association has not been revealed yet and its etiopathogenesis remains unclear [2]. On the other hand, coronary slow flow (CSF) is also thought to be a reflection of a systemic slow-flow phenomenon in the coronary arterial tree. Glucocorticoids cause an increase in coronary artery constriction and hence decrease coronary artery blood flow and this entity might be valid for the entire systemic arterial network. Herein we report concomitance of coronary slow flow and ophthalmic angina due to decreased choroidal blood flow that aggravated after use of glucocorticoids in a 44-year-old man.

Case Report

A 44-year-old man presented with chest pain causing fatigue together with blurred vision for the last 2 years, which disappeared after resting. His symptoms worsened in the last month.

He was a passive smoker for 15 years. He had erectile dysfunction, hypertension, and hyperlipidemia. He had been using angiotensin-converting enzyme inhibitor and statin. He also stated that his symptoms appeared and worsened after the use of corticosteroid (prednisone 60 mg/day for 6 days, followed by a taper, for a total of 10 days) for facial paralysis. He had a family history of coronary artery disease.

On physical examination, his heart rate was 78 beats per min, and arterial blood pressure was 130 mmHg systolic and 85 mmHg diastolic. His vision, ocular pressure, biomicroscopic examination, and retinas were also normal. There was no abnormality in electrocardiogram and echocardiography. His total blood cholesterol and triglyceride levels were 221 mg/dl and 212 mg/dl, respectively. Blurred vision secondary to optic neuritis may be the first clinical presentation of multiple sclerosis. Neurological examination and cranial computerized tomography imaging analyzed for the differential diagnosis of multiple sclerosis was normal.

On the basis that he had typical symptoms and a strong family history, he underwent coronary angiography. Coronary slow flow (CSF) was detected in all 3 major coronary arteries, without any obstructive disease. Thrombolysis in myocardial infarction (TIMI) measurements for left anterior descending artery (LAD) (Figure 1), circumflex (Cx), and right coronary artery (RCA) were 64 (corrected: 37.6), 72, and 55, respectively. Later, the patient underwent detailed ophthalmologic evaluation to clarify visual symptoms. In fundus fluorescein angiography (FFA), the retinas were normal, the arm-to-retina circulation time was 21.8 s, and the arteriovenous transit time was 4.3 s. In the early arteriovenous phase, choroidal filling was long, with physiological patchy type (Figure 2A). Indocyanine green angiography showed watershed-style vascular filling (Figure 2B). The choroid was not still fully filled after 30 s (Figure 2C) and this made us think that blurred vision might be due to impaired circulation. Diltiazem 90 mg/day and acetylsalicylic acid 100 mg/day was given for CSF. His chest pain and visual symptoms disappeared after medication. After treatment in FFA, the arm-to-retina circulation time was 15.8 s.

Discussion

CSF was first described by Tambe et al. in 1972 in 6 patients [3]. CSF was not found to be related with heart rate, aortic pressure, or myocardial contractility during angiography, and microvascular resistance was thought to be the real cause of

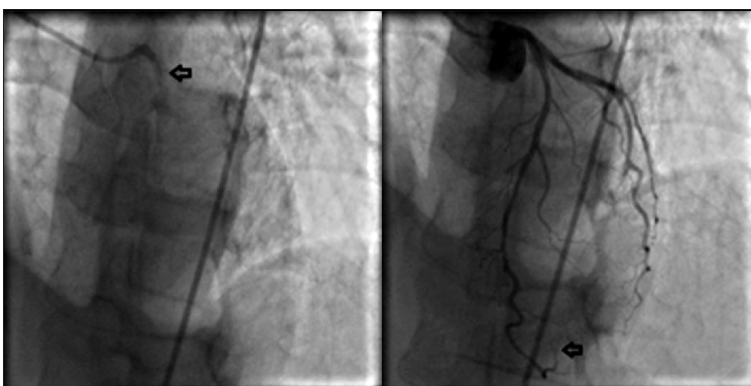


Figure 1. Left anterior descending artery TIMI measurement 64 (corrected TIMI: 37.6).

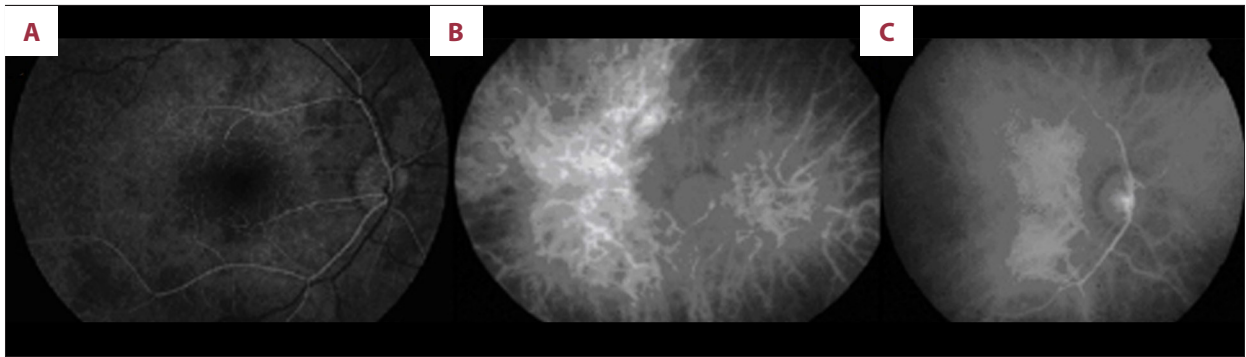


Figure 2. (A) In fundus fluorescein angiography; choroidal filling was long, with physiological patchy type and the arm to retina circulation time was 21.8 s. (B) Indocyanine green angiography showed watershed-style vascular filling. (C) Choroid was still not fully filled after 30 s.

this pathology [3]. Dysfunction of small vessels, imbalance of vasoconstrictor and vasodilator functions, inflammation, platelet dysfunction, obstructive disease of the small coronary arteries, and increased sympathomimetic activity were revealed to be the other causes [4].

In our patient, the arm to retina circulation time was 21.8 s. The values more than 15 s show prolonged circulation. If retina is normal, patchy type choroidal circulation in the early arteriovenous phase is a sign for physiological prolonging in choroid circulation, and visual symptoms occurring during effort may be evidence of impaired choroidal circulation. The choroidal circulation is regulated by the autonomic system, especially the sympathetic system, as in the systemic circulation. The fastest blood flow in human body is in the choroidal circulation. Also, a prolonging in choroidal circulation without the presence of any ophthalmic pathology might be a sign of slow circulation in other tissues. Stimulation of cervical sympathetic nerves decreases the choroidal circulation, whereas sympathectomy increases it. No finding was detected regarding a possibility of autoregulation in choroid [5,6].

Glucocorticoids increase the contractility of vascular smooth muscle cells by noradrenalin and inhibit proliferation and migration [7]. These drugs effect norepinephrine, 11β -hydroxy dehydrogenase enzyme, angiotensin II, endothelin, and mineralocorticoid receptors and also increase the tonus of vascular smooth muscles and cause a resistance in the blood flow. They decrease the nitric oxide (NO) synthesis of the endothelium and flow mediated vasodilation of peripheral arteries and cause endothelial dysfunction [7,8]. Krestel et al. showed that cortisol downregulates endothelin NO synthetase proteins, inhibits intracellular Ca mobilization and decreases NO release by glucocorticoid receptor activation in bovine coronary artery endothelial cells, which leads to an increase in coronary artery constriction and decrease in coronary artery blood flow [9]. These effects are possibly related to 11β -hydroxy dehydrogenase enzyme upregulation. Additionally, as glucocorticoids show their

vascular effects by increasing 11β -hydroxy dehydrogenase activity in vessel smooth muscle independently of blood levels, the patient did not experience an increase in plasma glucose concentration. In addition to passive smoking, dyslipidemia, and hypertension, another possible mechanism for the visual and coronary symptoms in our patient may be the use of corticosteroid and its effects on increasing sympathomimetic activity, which might reduce effort-stimulated vasodilation. This results in vasoconstriction, decreased choroidal, and coronary and penile blood flow during effort, causing visual symptoms, angina, and erectile dysfunction. After the administration of diltiazem, the symptoms disappeared completely, explained by sympathetic blockage of this agent [10]. Additionally antihypertensive effect of diltiazem and antiaggregant effect of acetylsalicylic acid might lead to improvement of the symptoms. At follow-up after medical treatment, in FFA the arm to retina circulation time had decreased to 15.8 s from 21.8 s. The only report of an association of coronary slow flow with ophthalmic circulation disorder was presented by Koç et al. [11]. Retinal arteriovenous circulation time measured using fundus fluorescein angiography was found to be prolonged in patients with CSF. To the best of our knowledge, this is the second report presenting the concomitance of CSF and decreased ophthalmic blood flow. The other points that make his case worth reporting were presence of accompanying erectile dysfunction and aggravation of symptoms after glucocorticoid use.

Conclusions

Physicians should be aware that glucocorticoids might increase the symptoms of CSF and other circulation problems, which might lead to other systematic symptoms. Diltiazem might be an appropriate choice for treatment. However, this is simply a report of a patient's clinical course. Further reports with larger populations are required to discover if the reason behind improvement in the patients' condition was due to discontinuation of steroids and application of diltiazem.

References:

1. Dogan M, Akyel A, Cimen T et al: relationship between neutrophil to lymphocyte ratio and slow coronary flow. *Clin Appl Thromb Hemost*, 2013 [Epub ahead of print]
2. Sezgin AT, Sigirci A, Barutcu I et al: Vascular endothelial function in patients with slow coronary flow. *Coron Artery Dis*, 2003; 14: 155–61
3. Tambe AA, Demany MA, Zimmerman HA, Mascarenhas E: Angina pectoris and slow flow velocity of dye in coronary arteries-a new angiographic finding. *Am Heart J*, 1972; 84: 66–71
4. Li JJ, Xu B, Li ZC et al: Is slow coronary flow associated with inflammation? *Med Hypotheses*, 2006; 66: 504–8
5. Pourmaras CJ, Rungger-Brändle E, Riva CE et al: Regulation of retinal blood flow in health and disease. *Prog Retin Eye Res*, 2008; 27: 284–330
6. Harris A, Kagemann L, Cioffi GA: Assessment of human ocular hemodynamics. *Surv Ophthalmol*, 1998; 42: 509–33
7. Walker BR: Glucocorticoids and cardiovascular disease. *Eur J Endocrinol*, 2007; 157: 545–59
8. Patrick WFH, Walker BR: Therapeutic manipulation of glucocorticoid metabolism in cardiovascular disease. *Review Br J Pharmacol*, 2009; 156: 689–712
9. Rogers KM, Bonar CA, Estrella JL, Yang S: Inhibitory effect of glucocorticoid on coronary artery endothelial function. *Am J Physiol Heart Circ Physiol*, 2002; 283: 1922–28
10. Yamasaki F, Sato T, Sugimoto K et al: Effect of diltiazem on sympathetic hyperactivity in patients with vasospastic angina. *Am J Cardiol*, 1998; 81: 137–40
11. Koç S, Ozin B, Altın C et al: Evaluation of circulation disorder in coronary slow flow by fundus fluorescein angiography. *Am J Cardiol*, 2013; 111: 1552–56