

Received: 2022.08.18

Accepted: 2022.10.04




Available online: 2022.12.02

Published: 2022.12.28

A 54-Year-Old Woman with Papillary Thyroid Carcinoma Associated with Secondary Amyloid Goiter and Thyroid Lipomatosis

Authors' Contribution:

Study Design A
Data Collection B
Statistical Analysis C
Data Interpretation D
Manuscript Preparation E
Literature Search F
Funds Collection G

EF 1 **Eugénia Maria Morado da Silva**
E 1 **Rute Alexandra da Costa Ferreira** 
DE 2 **Aluixa Rosmar Colmenares Lozada** 
EF 1 **João Manuel Sequeira Duarte** 

1 Department of Endocrinology, Hospital de Egas Moniz, Rua da Junqueira, Lisbon, Portugal

2 Department of Pathology, Hospital Distrital de Santarém, Santarém, Portugal

Corresponding Author: Eugénia Maria Morado da Silva, e-mail: emsilva@chlo.min-saude.pt

Financial support: None declared

Conflict of interest: None declared

Patient: Female, 54-year-old
Final Diagnosis: Secondary amyloid goiter • papillary thyroid carcinoma • thyroid lipomatosis
Symptoms: Thyroid gland enlargement • hoarseness • dysphagia
Medication: —
Clinical Procedure: —
Specialty: Endocrinology and Metabolic

Objective: Rare disease


Background: Amyloid deposition in the thyroid gland can be primary or secondary and can result in goiter. There have been previous reports of amyloid goiter and thyroid lipomatosis or fatty infiltration. Papillary thyroid carcinoma is the most common thyroid malignancy. We report a rare case of a 54-year-old woman with papillary thyroid carcinoma associated with secondary amyloid goiter and thyroid lipomatosis.

Case Report: A 54-year-old woman with chronic pyelonephritis and bronchiectasis presented with compressive symptoms due to an enlarged thyroid gland. Thyroid function test results were in the normal range and serum thyroid autoantibodies and serum calcitonin levels were undetectable. Cervical ultrasound showed a diffusely swollen thyroid and a well-defined nodule in the right lobe, of which fine-needle aspiration cytology was suspicious for follicular neoplasm. Computed tomography showed an enlarged thyroid with low attenuation, suggestive of diffuse lipomatosis of the gland. Total thyroidectomy was performed, and a histopathology study indicated the presence of papillary carcinoma and diffuse lipomatosis of the thyroid gland with amyloid deposition. The patient was later diagnosed with secondary amyloidosis.

Conclusions: The presentation of secondary amyloidosis as a diffuse goiter with extensive fatty infiltration must be considered in the differential diagnosis of thyroid enlargement, especially those with rapid onset, and particularly in patients with a history of chronic inflammatory disorders or chronic infections predisposing to amyloid deposition. Rarely, differentiated thyroid carcinoma is found within an amyloid goiter and it must be excluded in the differential diagnosis.

Keywords: Amyloid • Goiter • Lipomatosis

Full-text PDF: <https://www.amjcaserep.com/abstract/index/idArt/938156>




1072



—



4



16



Background

Amyloid goiter, a rare entity first recognized by Beckmann in 1858, is defined as a clinically detectable enlarged thyroid gland due to the extracellular deposition of insoluble protein fibrils accompanied by varying degrees of fat deposition [1]. It may be caused by primary amyloidosis, associated with plasma cell dyscrasias, or, more frequently, by secondary amyloidosis, usually triggered by an inflammatory disease such as tuberculosis, bronchiectasis, familial Mediterranean fever, cystic fibrosis, ulcerative colitis, Crohn's disease, or rheumatoid arthritis, among others [2]. Amyloid goiter has been reported to be associated with diffuse thyroid lipomatosis [3,4], a rare condition characterized by infiltration of mature adipose tissue in the thyroid stroma without evidence of encapsulation [5]. Papillary thyroid carcinoma is the most common thyroid malignancy [6] and rare case reports have mentioned its occurrence associated with amyloid goiter [7-10]. Even more unusual is the synchronous occurrence of papillary thyroid carcinoma, amyloid goiter, and diffuse thyroid lipomatosis [7]. We report a rare case of a 54-year-old woman with papillary thyroid carcinoma associated with secondary amyloid goiter and diffuse thyroid lipomatosis.

Case Report

A 54-year-old female patient with a history of neurogenic bladder, chronic renal failure due to chronic pyelonephritis, and bronchiectasis associated with multiple respiratory infections presented at our Department of Endocrinology with thyroid gland enlargement, hoarseness, and dysphagia, with nearly 4 months of evolution. Physical examination revealed a large bilateral goiter mainly affecting the right side of the neck, where a mass of approximately 3 cm was palpable. Thyroid function test results were in the normal range, with free T4 14.1 pmol/L (reference range, 12-24), free T3 3.9 pmol/L (reference range, 3.1-6.8), and thyroid-stimulating hormone (TSH) 0.8 μ UI/mL (reference range, 0.27-4.20). Serum anti-thyroperoxidase and anti-thyroglobulin antibodies, as well as calcitonin levels, were undetectable. Cervical ultrasound (US) showed a diffusely swollen thyroid and a well-defined nodule in the right lobe, which was solid, isoechoic, taller than wide, with no calcifications, measuring 28×19×29 mm (anteroposterior×width×length); without laterocervical adenopathies. Fine-needle aspiration cytology of the nodule was suspicious for follicular neoplasm (Bethesda IV category). In addition to what was previously described in the US, computed tomography (CT) showed an enlarged thyroid, leading to a slight reduction of tracheal sagittal diameter and areas of low attenuation suggestive of diffuse lipomatosis of the gland (Figure 1). The total thyroidectomy specimen weighed 81 grams, the left lobe measured 32×67×28 mm, isthmus 26×45×20 mm, and the right lobe 45×75×34 mm. Histological study revealed the presence of papillary carcinoma of follicular variant,

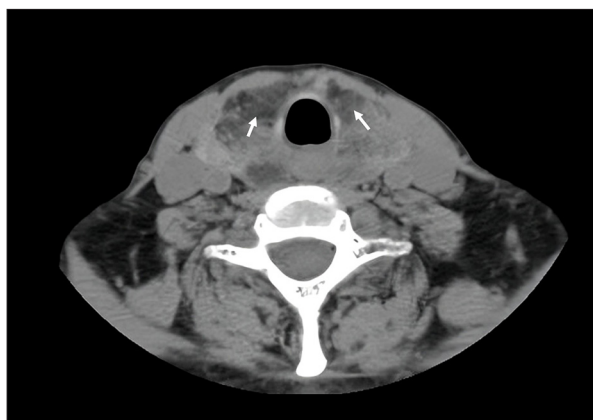


Figure 1. Computed tomography of the neck without contrast. CT scan showing diffuse goiter with hypodense areas (white arrows).

measuring 34×32×25 mm, without lymphovascular invasion or microscopic extrathyroidal extension (pT2, according to AJCC/TNM 8th edition) [11] (Figure 2). Thyroid follicles were admixed with mature adipose tissue, and the stroma was replaced mainly by amorphous eosinophilic material (Figure 3), which was confirmed to be amyloid deposition by orangeophilic staining with Congo red and positive apple-green birefringence under polarized light (Figure 4). A final diagnosis of papillary carcinoma and diffuse lipomatosis of the thyroid gland with amyloid deposition was established. TSH suppression therapy was provided, aiming for a TSH level of 0.5-2.0 μ UI/mL. The patient was referred to an Internal Medicine appointment to proceed with the investigation of amyloidosis, and an abdominal fat aspirate showed amyloid deposits typed as serum amyloid A protein by immunohistochemical staining, confirming the diagnosis of secondary amyloidosis. Unfortunately, the patient died 5 months after the amyloid goiter diagnosis due to a urinary tract infection that developed into sepsis.

Discussion

This case represents an unusual occurrence of papillary thyroid carcinoma in an amyloid goiter subsequently found to be a manifestation of secondary amyloidosis in a patient with chronic pyelonephritis and bronchiectasis. We highlight the need for inclusion of amyloid goiter and diffuse lipomatosis in the differential diagnosis of thyroid enlargement, and the need for exclusion of a differentiated thyroid carcinoma within an amyloid goiter. As shown in this report, amyloid goiter can be associated with diffuse fatty proliferation, probably due to tissue hypoxia secondary to progressive capillary and thyroid follicle destruction leading to metaplasia of stromal fibroblasts [12]. The amyloid deposition has also been reported in association with thyroid malignancies. Medullary thyroid carcinoma often has an amyloid stromal deposition, and it has been suggested

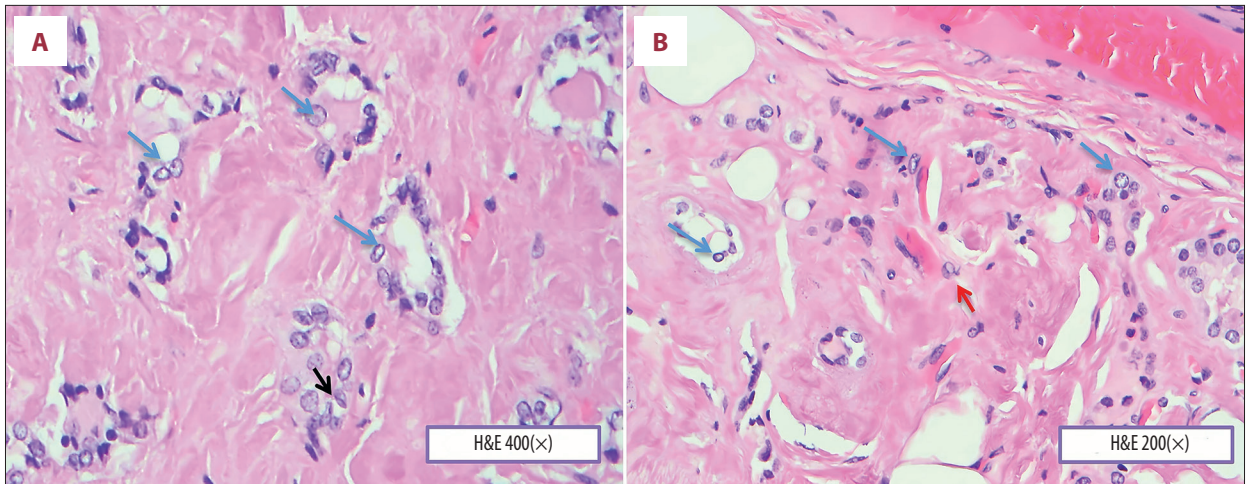


Figure 2. (A, B) A photomicrograph of the thyroid gland showing papillary carcinoma and amyloid deposition. The thyroid gland is infiltrated by pleomorphic malignant cells with nuclear enlargement and “ground-glass” nuclei (blue arrows), nuclear grooves (black arrow), and nuclear pseudo-inclusions (red arrow). The normal background thyroid tissue is replaced by amorphous pink material with the typical appearance of amyloid. Hematoxylin and eosin stain (H&E). Objective magnification **A** ×400 and **B** ×200.

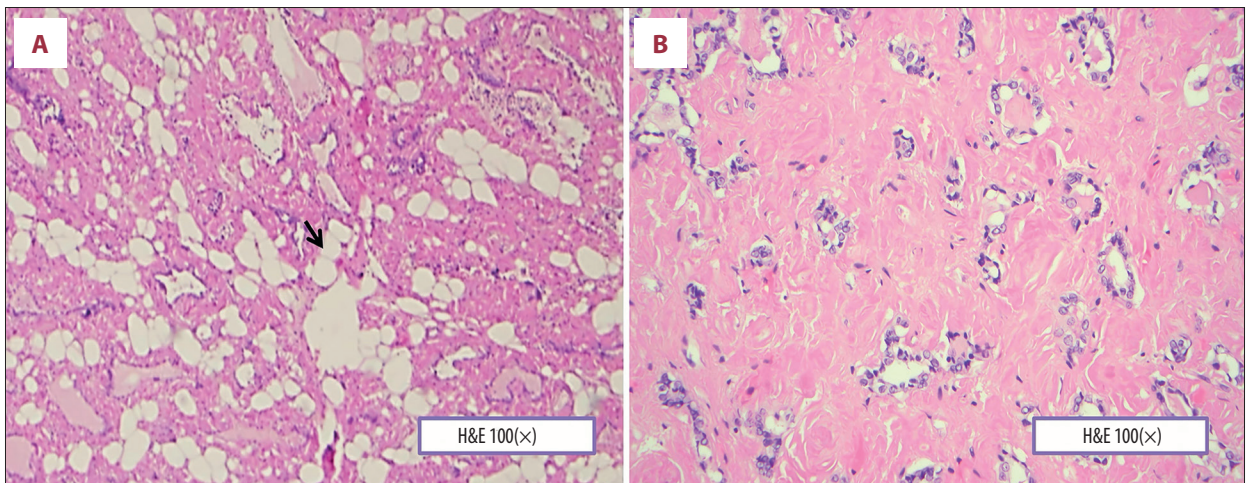


Figure 3. (A, B) A photomicrograph of the histopathology of the thyroid gland showing lipomatosis. The thyroid gland contains mature adipose tissue without inflammation or nuclear atypia (black arrow). The normal background thyroid tissue is replaced by amorphous pink material with the typical appearance of amyloid. Hematoxylin and eosin (H&E). Objective magnification ×100.

that it can be synthesized locally by tumor cells as excess calcitonin aggregates into insoluble fibrils [13]. Papillary thyroid carcinoma has rarely been associated with amyloid goiter, with just a few cases reported, and the mechanism remains unknown [7-10]. Liftin [8] reported a case of mixed papillary and follicular thyroid carcinoma associated with amyloid goiter in a patient with rheumatoid arthritis. Coli et al [7] reported an amyloid goiter with diffuse lipomatosis and papillary thyroid carcinoma in a patient with probable secondary amyloidosis. Coca-Pelaz et al [9] and Nessim et al [10] reported a papillary thyroid carcinoma within an amyloid goiter due to primary amyloidosis. As in our case, most patients with amyloid goiter

present with an enlarged thyroid gland, usually bilateral and diffuse, which can rapidly progress over weeks to months [3,4,9] and it can be associated with compressive symptoms such as dysphagia, dysphonia, and dyspnea [4,9,10]. Thyroid function is usually normal [3,4,7,9,10], but a minority of patients have hyper- or hypo-thyroidism [14]. As previously stated, our patient had normal levels of T4, T3, and TSH. Imaging findings can vary according to the amount of amyloid. Hyperechogenicity in the US and low density on CT, as in our case, may be found in the presence of infiltration of fat tissue [3,4]. Diagnosis of amyloid goiter requires histologic analysis of the excised gland. At histological observation, amyloid deposition appears as an

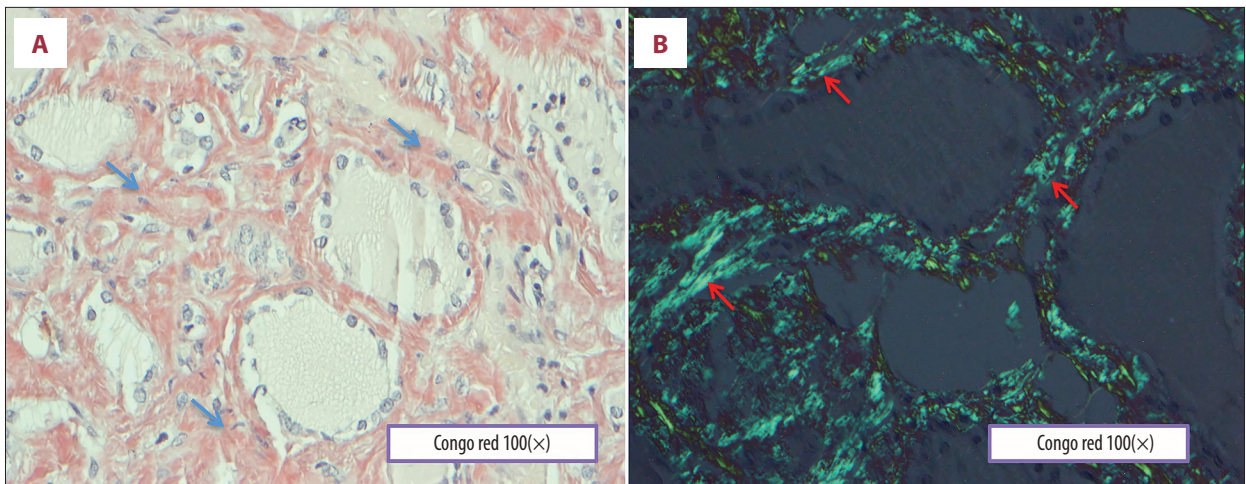


Figure 4. A photomicrograph of the light microscopy and polarized light microscopy of the thyroid gland showing amyloid (A) Light microscopy of the Congo red histochemical staining shows areas of amyloid (blue arrows). Congo red. Objective magnification $\times 100$. (B) Polarized light microscopy of the Congo red staining shows apple-green birefringence in polarized light (red arrows), which is typical for amyloid. Objective magnification $\times 100$.

amorphous, extracellular, proteinaceous substance. It shows positivity to Congo red staining, imparting an apple-green birefringence when viewed under polarized light, which is considered a pathognomonic feature [15]. Immunohistochemical studies can help to define the origin of the amyloid protein deposits, with the presence of light chains in primary amyloidosis and serum amyloid A protein in secondary amyloidosis [16].

Conclusions

The presentation of secondary amyloidosis as a diffuse goiter with extensive fatty infiltration must be considered in the

differential diagnosis of thyroid enlargement, especially in cases with rapid onset, particularly in patients with a history of chronic inflammatory disorders or chronic infections predisposing to amyloid deposition. Rarely, differentiated thyroid carcinoma is found within an amyloid goiter and it must be excluded.

Declaration of Figures' Authenticity

All figures submitted have been created by the authors who confirm that the images are original with no duplication and have not been previously published in whole or in part.

References:

1. Beckmann, O. Ein Fall von amyloider Degeneration. *Archiv f Pathol Anat.* 1858;13:94-98 [in German]
2. Aydin B, Koca YS, Koca T, et al. Amyloid goiter secondary to ulcerative colitis. *Case Rep Endocrinol.* 2016;2016:3240585
3. Aksu AO, Ozmen MN, Oguz KK, et al. Diffuse fatty infiltration of the thyroid gland in amyloidosis: Sonographic, computed tomographic, and magnetic resonance imaging findings. *J Ultrasound Med.* 2010;29(8):1251-55
4. Cavaco DR, Alves Rafael A, Cabrera R, Vilar H, Leite V. Case report: A rare association of diffuse thyroid lipomatosis with amyloid deposition. *Eur Thyroid J.* 2021;10(6):528-32
5. Ge Y, Luna MA, Cowan DF, Truong LD, Ayala AG. Thyrolipoma and thyrolipomatosis: 5 case reports and historical review of the literature. *Ann Diagn Pathol.* 2009;13(6):3
6. Bergdorf K, Ferguson DC, Mehrad M, et al. Papillary thyroid carcinoma behavior: Clues in the tumor microenvironment. *Endocr Relat Cancer.* 2019;26(6):601-14
7. Coli A, Bigotti G, Zucchetti F, Negro F, Massi G. Papillary carcinoma in amyloid goitre. *J Exp Clin Cancer Res.* 2000;19(3):391-94
8. Liftin AJ. Nonmedullary carcinoma of the thyroid gland in association with amyloid goiter: Case report. *Mt Sinai J Med.* 1985;52:225-27
9. Coca-Pelaz A, Allende B, Marcos C, Nieto C. Multifocal papillary thyroid carcinoma associated with primary amyloid goiter. *Auris Nasus Larynx.* 2012;39:549-51
10. Nessim S, Tamilia M. Papillary thyroid carcinoma associated with amyloid goiter. *Thyroid.* 2005;15:382-85
11. Perrier ND, Brierley JD, Tuttle RM. Differentiated and anaplastic thyroid carcinoma: Major changes in the American Joint Committee on Cancer eighth edition cancer staging manual. *Cancer J Clin.* 2018;68(1):55-63
12. Bocker W, Schröder S. Lipomatous lesions of the thyroid gland: A review. *Appl Pathol Int.* 2007;57:449-53
13. Reches M, Porat Y, Gazit E. Amyloid fibril formation by pentapeptide and tetrapeptide fragments of human calcitonin. *J Biol Chem.* 2002;277:35475-80
14. Law JH, Dean DS, Scheithauer B, et al. Symptomatic amyloid goiters: Report of five cases. *Thyroid.* 2013;23(11):1490-95
15. Benson MD, Buxbaum JN, Eisenberg DS, et al. Amyloid nomenclature 2018: Recommendations by the International Society of Amyloidosis (ISA) nomenclature committee. *Amyloid.* 2018;25(4):215-19
16. Picken MM. The pathology of amyloidosis in classification: A review. *Acta Haematol.* 2020;143(4):322-34