

Use of the mini-forceps traction-assisted cannulation technique when standard ERCP methods fail: Single-center retrospective study

OPEN
ACCESS



Authors

Ankit Mishra¹ , Charles Meade², Allison R. Schulman², George Philips², Jorge D. Machicado²

Institutions

- 1 Department of Internal Medicine, University of Michigan, Ann Arbor, United States
- 2 Division of Gastroenterology and Hepatology, University of Michigan, Ann Arbor, United States

48109 Ann Arbor, United States

machicad@med.umich.edu

Key words

Pancreatobiliary (ERCP/PTCD), Diagnostic ERC, ERC topics, Cholangioscopy

received 26.9.2024

accepted after revision 5.12.2024

accepted manuscript online 2.1.2025

Bibliography

Endosc Int Open 2025; 13: a25097369

DOI 10.1055/a-2509-7369

ISSN 2364-3722

© 2025. The Author(s).

This is an open access article published by Thieme under the terms of the Creative Commons Attribution-NonDerivative-NonCommercial License, permitting copying and reproduction so long as the original work is given appropriate credit. Contents may not be used for commercial purposes, or adapted, remixed, transformed or built upon. (<https://creativecommons.org/licenses/by-nc-nd/4.0/>)

Georg Thieme Verlag KG, Oswald-Hesse-Straße 50, 70469 Stuttgart, Germany

Corresponding author

Dr. Jorge D. Machicado, University of Michigan, Division of Gastroenterology and Hepatology, 1500 E Medical Center Dr.,

ABSTRACT

Background and study aims There are few salvage techniques for achieving biliary cannulation when no duct can be accessed.

Patients and methods We retrospectively reviewed 10 consecutive cases in which the mini-forceps traction-assisted cannulation technique (MFTAC) was used after failure of any duct access during endoscopic retrograde cholangiopancreatography (ERCP). Outcomes included technical success, use of adjunct techniques; time to biliary access; and adverse events (AEs).

Results Most patients had a native papilla (n = 9) of peri-diverticular location (n = 5) and a benign indication (n = 6). Standard cannulation was unsuccessful over 8:23 mm:ss (interquartile range [IQR] 6:04–19:43). MFTAC had 100% technical success, achieved biliary access after 17:38 mm:ss (IQR 8:52–20:31), and had a 10% incidence of AEs (post-ERCP pancreatitis). MFTAC was sufficient to allow biliary cannulation in three cases and allowed pancreatic duct access in seven cases, which then allowed biliary cannulation with double-wire technique (5/10) and transpancreatic septotomy (2/10).

Conclusions MFTAC is a feasible salvage approach for biliary access when standard cannulation methods fail.

Introduction

Deep ductal cannulation during endoscopic retrograde cholangiopancreatography (ERCP) fails in approximately 10% to 20% of cases [1]. Despite endoscopist experience, variations in patient papillary morphology may preclude successful deep ductal access with standard cannulation techniques [2]. When no duct can be accessed with a wire during ERCP, free-hand needle knife precut sphincterotomy (NKS) or endoscopic ultrasound-guided biliary drainage (EUS-BD) are well-established salvage techniques that share similar efficacy and safety [3]. For such

scenarios, NKS has been preferably recommended because EUS-BD requires dedicated training on therapeutic EUS, entails incremental equipment costs, and needs a dedicated pre-procedure consent [1]. However, NKS fails to achieve any ductal access in 10% of cases, often related to a distorted major papilla that precludes safe precut dissection [3, 4].

In these settings, traction-assisted methods using endoclips, elastic bands, and two-devices-in-one-channel have been described in small case series and case reports as alternatives to NKS or EUS-BD [5, 6, 7]. Few small studies have reported use of traction via a mini-forceps with a two-devices-in-one-channel

technique to aid successful duct access in difficult ERCPs due to large periampullary diverticulum [5, 8, 9]. We hypothesize that the mini-forceps technique is a feasible alternative to NKS or EUS-BD in situations when no duct can be accessed with standard cannulation methods due to an unfavorable papillary configuration. Thus, we conducted a feasibility study to report technical success and safety of this technique on assisting with difficult biliary cannulation.

Patients and Methods

Study design and patient population

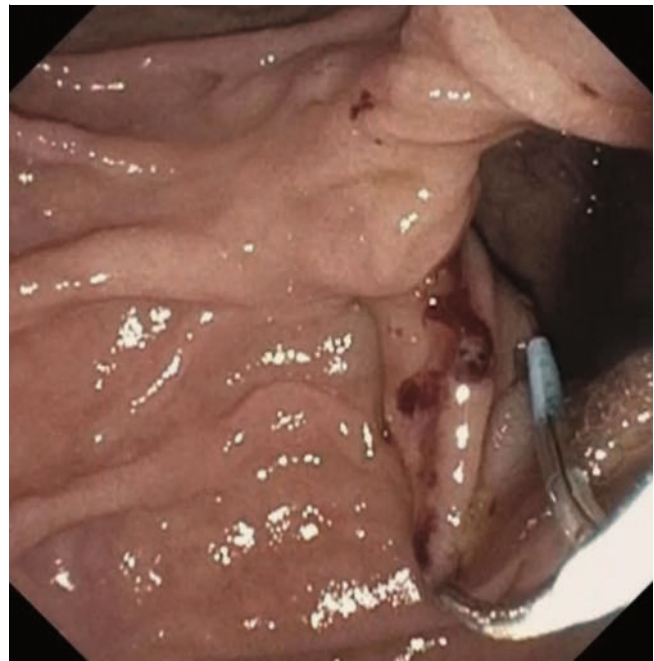
This was a single-center, retrospective case series of consecutive subjects who underwent ERCP at the University of Michigan between August and November 2023. Inclusion criteria were: 1) ERCP for biliary indication; 2) reachable major papilla; 3) failed deep biliary access with standard techniques; 4) failed wire access to the pancreatic duct (PD); and 5) attempted traction-assisted biliary cannulation using a mini-forceps. Exclusion criteria included: attempt of NKS or EUS-BD before use of traction; ampullary mass; ERCP for pancreatic indication; and altered anatomy ERCP. The study protocol was approved by the Institutional Review Board of the University of Michigan (HUM00240663).

Endoscopic technique

Three high-volume advanced endoscopists (> 300 ERCPs per year) started using the mini-forceps traction technique in our center in August 2023. This was used at endoscopist discretion as a salvage cannulation technique when standard methods failed to provide ductal access and before attempting NKS or EUS-BD. The technique consisted of advancing the mini-forceps (catheter diameter 3F; jaw outer diameter 1 mm; SpyBite Max, Boston Scientific, Natick, Massachusetts, United States) through the 4.2-mm working channel of a therapeutic duodenoscope in parallel to a cannulation catheter. Within the duodenal lumen, the jaws of the mini-forceps were used to grasp the inferior duodenal fold while applying traction to the shaft of the device. This maneuver served to mobilize the duodenal mucosa laterally or downwards, reorient the intraduodenal portion of the bile duct, and simultaneously attempt ductal access with a cannulation device (► **Fig. 1**). If the wire accessed the PD, then biliary cannulation was attempted using double-wire technique or transpancreatic septotomy, with or without the assistance of mini-forceps traction. Once biliary cannulation was achieved, biliary sphincterotomy was performed as needed with or without mini-forceps traction (► **Video 1**).

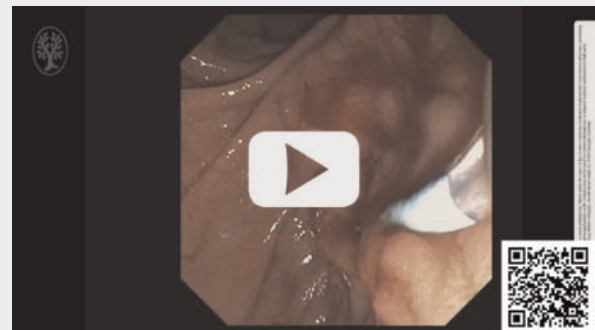
Data collection

Data were obtained from procedure documentation, case videos, and chart review. All cases were video recorded and later assessed by one reviewer (CM). Times from the first attempt at cannulation until starting traction with the mini-forceps and from starting traction until successful biliary cannulation were estimated (mm:ss). Papillary morphology was determined by agreement of two reviewers (CM, JDM) using a validated classi-



► **Fig. 1** Example of mini-forceps traction-assisted biliary cannulation technique in a patient with intradiverticular papilla.

► VIDEO



► **Video 1** A video-guided demonstration of biliary cannulation and biliary sphincterotomy, with or without the use of mini-forceps traction.

fication system [10]. Disagreements were resolved by consensus-based discussion.

Outcomes

The primary outcome was technical success, defined as successful deep cannulation of the bile duct. Secondary outcomes included: 1) use of concomitant adjunct cannulation techniques; 2) elapsed time for successful biliary access with the traction technique; and 3) adverse events (AEs).

Patient characteristics

A total of 10 patients underwent the mini-forceps traction technique (50% female; median age 68.2 years, interquartile range [IQR] 65–75.3). Most patients had native papillary anatomy (n = 9) and a benign indication (n = 6). Half of the patients had a peri-diverticular papilla, including three with intradiverticular location, while the rest had pendulous (n = 3), bulging (n = 1), or creased papillae (n = 1). Standard cannulation attempts were made for a median of 8:23 mm:ss (IQR 6:04–19:43) without successfully accessing any duct.

Procedure outcomes

Technical success with the mini-forceps traction technique was 100%. In three of 10 cases, the mini-forceps technique alone was sufficient to achieve biliary access. In seven of 10 cases, mini-forceps-assisted PD access was first achieved, followed by concomitant double-wire technique (n = 5) and trans-pancreatic septotomy (n = 2) while still applying traction with the mini-forceps. Successful biliary access was obtained at a median of 17:38 mm:ss (IQR 8:52–20:31) from time of initiating traction. One patient with choledocholithiasis and intradiverticular papilla experienced moderately severe post-ERCP pancreatitis despite insertion of a prophylactic pancreatic stent, administration of rectal indomethacin, and peri-procedural fluids. Biliary access on this patient was only successful after trans-pancreatic septotomy, which was performed after PD access was gained with mini-forceps traction (► **Table 1**).

Discussion

In this single-center retrospective study, we found that the mini-forceps traction-assisted cannulation technique was a feasible method to gain biliary access in cases in which guidewire access could not be attained with standard approaches. This method was overall safe, easy to implement, and used in lieu of NKS and EUS-BD in patients with periampullary diverticulum, redundant papillary folds, and inadequately exposed papillary orifice.

Our study expands our knowledge about the utility of the mini-forceps traction-assisted biliary cannulation technique. The technique was first described a decade ago in a case report of a patient with a peri-ampullary diverticulum, in whom endoscopic hemoclip traction failed and then the mini-forceps technique successfully aided on cannulating the bile duct [8]. Subsequently, two case series confirmed high technical success (90%-100%) in patients with periampullary diverticulum in whom standard cannulation techniques failed due to inability to visualize the papilla [5,9.] Similar to those reports, we found 100% technical success on facilitating biliary access with this technique when other standard cannulation techniques failed. Mechanistically, this technique works by exposing the major papilla when duodenal folds or a periampullary diverticulum obscures its visualization, and by straightening and orienting the duct into a more accessible configuration.

There are several relevant points to highlight from our study. A novel aspect is that this technique is not only helpful for pa-

► **Table 1** Study results with mini-forceps traction-assisted technique for biliary cannulation.

Results (N = 10)	n (%) or median (IQR)
Baseline characteristics	
Male sex	5 (50%)
Age, median (IQR)	68.2 (65–75.3)
White race, n (%)	9 (90%)
Papillary anatomy	
▪ Peri-diverticular	5 (50%)
▪ Pendulous	3 (30%)
▪ Bulging	1 (10%)
▪ Creased	1 (10%)
Indication	
▪ Malignant biliary stricture	4 (40%)
▪ Choledocholithiasis	2 (20%)
▪ Papillary stenosis	2 (20%)
▪ Cholangitis	1 (10%)
▪ IgG4 cholangiopathy	1 (10%)
Native papilla	9 (90%)
Duration of cannulation attempts prior to traction-assisted technique (mm:ss), median (IQR)	8:23 (6:04–19:43)
Outcomes	
Technical success	10 (100%)
Adjunct cannulation technique	
▪ Double-wire	5 (50%)
▪ Transpancreatic septotomy	2 (20%)
Duration to successful biliary cannulation with traction-assisted technique (mm:ss), median (IQR)	17:38 (8:52–20:31)
Adverse events	
▪ Post-ERCP pancreatitis	1 (10%)
▪ Perforation	0
▪ Bleeding	0
ERCP, endoscopic retrograde cholangiopancreatography; IQR, interquartile range; mm:ss, minutes:seconds.	

tients with a periampullary diverticulum, but also in other types of challenging ampullary configurations such as pendulous, bulging, or creased papillae. In these cases, NKS was not attempted because configuration of the papilla was not favorable for safe dissection. The traction technique was not only effective in allowing successful bile duct access in these challenging cases, but also in providing adequate orientation for transpancreatic septotomy and biliary sphincterotomy. The technique was easy to implement and required no additional training

other than competence with ERCP. This may be an advantage of this technique over NKS or EUS-BD, which require significant expertise to perform safely and efficiently. Finally, this technique may reduce failed biliary cannulations in patients with difficult ampullary anatomy.

There are some disadvantages with the mini-forceps traction technique. First, traction alone was rarely sufficient to achieve bile duct cannulation. More often, traction technique first led to successful wire access to the PD and subsequently use of pancreatic guidewire-assisted cannulation techniques. This facilitates prophylactic PD stent insertion, which most of these patients would benefit from due to prolonged cannulation attempts. Second, successful biliary cannulation took on average 17 minutes, which reflects the difficulty of the cases that required traction. Although long, this duration is likely shorter than with clip traction or EUS-guided rendezvous [5]. Third, one patient (10%) had moderately severe acute pancreatitis despite rectal indomethacin and a prophylactic pancreatic stent. This cannot be directly attributed to the mini-forceps technique, because this patient also underwent trans-pancreatic septotomy, a recognized risk factor for post-ERCP pancreatitis. Fourth, the mini-forceps used in the study is not available in all endoscopy units, especially in those not performing cholangioscopy. Therefore, availability to disseminate the technique may be limited. Finally, costs to implement this technique may be prohibitive in some low-resource settings, especially compared with clip traction. The cost of each mini-forceps is \$500 in our unit, which is similar to the costs of NKS and cheaper to EUS-BD.

Our study has some limitations. The sample size was small. The technique was performed by high-volume endoscopists. Patients were recruited from a tertiary care center. The design was retrospective. There was no comparative arm. The decision to pursue this technique was at endoscopist discretion without clear criteria, other than failure to cannulate any duct with conventional methods and lack of a favorable configuration for NKS. These limitations result in selection bias and limited external validity. Given the small number of patients with peridiverticular papilla, a more detailed classification of these types of papillary configurations was not conducted.

The study has some strengths that potentially mitigate bias. We included only consecutive cases performed since the technique was first started at our institution. We prospectively video recorded all cases to ensure proper capture of procedure details, which reduces misclassification bias. We reviewed all the videos to calculate procedure time and classified all the papilla configurations using a validated system.

Conclusions

In conclusion, the mini-forceps traction-assisted technique was a feasible salvage approach for bile duct access when standard cannulation methods failed during ERCP. Future prospective studies are needed to compare the mini-forceps technique with NKS, EUS-BD, and other traction-assisted techniques in

cases of difficult biliary cannulation due to difficult ampullary anatomy and when pancreatic guidewire-assisted cannulation is not feasible.

Acknowledgement

Specific author contributions: Study concept and design: JDM Statistical analysis: JDM Drafting of the manuscript: AM, JDM Generation of data: CM Critical revision of the manuscript: JDM Data interpretation, final approval of the manuscript: all authors

Conflict of Interest

Jorge D. Machicado COI: Served in an advisory board of Amgen LCM Allison R Schulman's COI: Apollo Endosurgery Consultant Boston Scientific Consultant Olympus Consultant MicroTech Consultant GI Dynamics Research/grant support Fractyl Research/grant support The remaining authors have no conflicts of interest to declare.

References

- [1] Testoni PA, Mariani A, Aabakken L et al. Papillary cannulation and sphincterotomy techniques at ERCP: European Society of Gastrointestinal Endoscopy (ESGE) Clinical Guideline. *Endoscopy* 2016; 48: 657–683 doi:10.1055/s-0042-108641
- [2] Haraldsson E, Kylanpää L, Gronroos J et al. Macroscopic appearance of the major duodenal papilla influences bile duct cannulation: a prospective multicenter study by the Scandinavian Association for Digestive Endoscopy Study Group for ERCP. *Gastrointest Endosc* 2019; 90: 957–963 doi:10.1016/j.gie.2019.07.014
- [3] Choudhury A, Samanta J, Muktesh G et al. Endoscopic ultrasound-guided rendezvous technique versus precut sphincterotomy as salvage technique in patients with benign biliary disease and difficult biliary cannulation: A randomized controlled trial. *Ann Intern Med* 2024; 177: 1361–1369
- [4] Zhang QS, Xu JH, Dong ZQ et al. Success and safety of needle knife papillotomy and fistulotomy based on papillary anatomy: A prospective controlled trial. *Dig Dis Sci* 2022; 67: 1901–1909 doi:10.1007/s10620-021-06983-7
- [5] Huang L, Yu QS, Sun K. Two biliary cannulation techniques for ERCP in patients with intradiverticular papilla: A retrospective review. *Surg Laparosc Endosc Percutan Tech* 2018; 28: 226–231
- [6] Bonnicksen MH, Djajakusuma A, Wu CCH et al. Clip-and-line traction method for difficult ERCP cannulation due to choledochocoele. *VideoGIE* 2023; 8: 418–419 doi:10.1016/j.vgie.2023.06.014
- [7] Saito K, Fujisawa M, Kogure H. Usefulness of clip-band traction device for biliary cannulation in a case of intradiverticular papilla. *Dig Endosc* 2023; 35: e95–e96 doi:10.1111/den.14574
- [8] Levenick JM, Gardner TB, Hussain ZH et al. SpyBite-assisted biliary cannulation for intradiverticular papilla during ERCP. *Endoscopy* 2014; 46: E514
- [9] Balkrishnan M, Jain M, Snk C et al. Cannulation in patients with large periampullary diverticulum using SpyBite miniforceps. *Clin Exp Hepatol* 2018; 4: 41–42
- [10] Mohamed R, Lethebe BC, Gonzalez-Moreno E et al. Morphology of the major papilla predicts ERCP procedural outcomes and adverse events. *Surg Endosc* 2021; 35: 6455–6465 doi:10.1007/s00464-020-08136-9