

Review paper

Chest computed tomography scan findings of coronavirus disease 2019 (COVID-19) patients: a comprehensive systematic review and meta-analysis

Mohammad Karimian^{1,A,B,C,D,E,F,G}, Milad Azami^{2,A,B,C,D,E,F,G}

¹Department of General Surgery, Faculty of Medicine, Ilam University of Medical Sciences, Ilam, Iran

²Faculty of Medicine, Ilam University of Medical Sciences, Ilam, Iran

Abstract

Introduction: Numerous cases of pneumonia caused by coronavirus disease 2019 (COVID-19) were reported in Wuhan, China. Chest computed tomography (CT) scan is highly important in the diagnosis and follow-up of lung disease treatment. The present meta-analysis was performed to evaluate chest CT scan findings in COVID-19 patients.

Material and methods: All research steps were taken according to the Meta-Analysis of Observational Studies In Epidemiology (MOOSE) protocol and the final report was based on Preferred Reporting Items for Systematic Reviews and Meta-Analyses (PRISMA) guidelines. We registered this review at the International Prospective Register of Systematic Reviews (PROSPERO, CRD42019127858).

Results: Forty eligible studies including 4598 patients with COVID-19 were used for meta-analysis. The rate of positive chest CT scan in patients with COVID-19 was 94.5% (95% CI: 91.7-96.3). Bilateral lung involvement, pure ground-glass opacity (GGO), mixed (GGO pulse consolidation or reticular), consolidation, reticular, and presence of nodule findings in chest CT scan of COVID-19 pneumonia patients were respectively estimated to be 79.1% (95% CI: 70.8-85.5), 64.9% (95% CI: 54.1-74.4), 49.2% (95% CI: 35.7-62.8), 30.3% (95% CI: 19.6-43.6), 17.0% (95% CI: 3.9-50.9) and 16.6% (95% CI: 13.6-20.2). The distribution of lung lesions in patients with COVID-19 pneumonia was peripheral (70.0% [95% CI: 57.8-79.9]), central (3.9% [95% CI: 1.4-10.6]), and peripheral and central (31.1% [95% CI: 19.5-45.8]). The pulmonary lobes most commonly involved were the right lower lobe (86.5% [95% CI: 57.7-96.8]) and left lower lobe (81.0% [95% CI: 50.5-94.7]).

Conclusions: The most important outcomes in chest CT scan of patients with COVID-19 pneumonia were bilateral lung involvement, GGO or mixed (GGO pulse consolidation or reticular) patterns, thickened interlobular septa, vascular enlargement, air bronchogram sign, peripheral distribution, and left and right lower lobes involvement. Our study showed that chest CT scan has high sensitivity in the diagnosis of COVID-19, and may therefore serve as a standard method for diagnosis of COVID-19.

Key words: computed tomography, COVID-19, meta-analysis.

Introduction

In December 2019, numerous cases of pneumonia of unknown cause were reported in Wuhan, Hubei Province, China. On January 7, 2020, a novel coronavirus, severe acute respiratory syndrome coronavirus-2 (SARS-CoV-2), was identified as the causative organism by Chinese experts by performing real-time polymerase chain reaction (real-time PCR) on patients' respiratory tract specimens.

It was subsequently named 2019-nCoV by the World Health Organization (WHO) [1]. There is also evidence that it can be transmitted through respiratory droplets and contact with infected patients as well as fecal-oral transmission [2,3]. Etiologically speaking, virulence of a pathogen may increase sharply during host shifts [4,5], and in contrast, the virulence may decrease through prolonged host-parasite interactions [6].

Correspondence address:

Dr. Milad Azami, Faculty of Medicine, Ilam University of Medical Sciences, Ilam, Iran, e-mail: milad98azami@gmail.com

Authors' contribution:

A Study design · B Data collection · C Statistical analysis · D Data interpretation · E Manuscript preparation · F Literature search · G Funds collection

Coronavirus disease 2019 (COVID-19) is primarily transmitted through respiratory droplets and close contact, and the incubation period is usually between 1 and 14 days. The common symptoms include fever, dry cough, fatigue, and the gradual onset of shortness of breath. People who carry the virus are the source of infection, even during the incubation period. Early detection of the disease or the virus carrier is the key to prevent further spread. However, confirmation of the infection requires a nucleic acid detection kit. The virus can be identified in swabs, secretions, and sputum from the respiratory tract, blood, or feces [7].

Computed tomography (CT) scan is highly important in the diagnosis and follow-up of lung disease treatment. In a review of different studies, one may find that the imaging features of COVID-19 pneumonia are varied, from their natural appearance to diffuse changes in the lungs. In addition, different radiological patterns are observed at different times over the course of the disease. Since the onset of symptoms and acute respiratory distress syndrome (ARDS) was short-lived in the first cases of COVID-19 pneumonia, early detection of the disease is essential for the management of these patients [8].

Numerous studies have been performed regarding the findings of CT scans in COVID-19 patients and the results are inconsistent [3,8-46]. According to previous studies, lesions in patients with COVID-19 show ground-glass opacity (GGO) or mixed (GGO pulse consolidation or reticular) patterns, and are likely to have peripheral distribution, bilateral involvement, lower lobe dominance, and multi-lobe distribution [8-15]. In a systematic review and meta-analysis, a structured review of all documentation and their composition can provide a more comprehensive picture of all dimensions of the subject. One of the main goals of meta-analysis, which is a combination of different studies, is to reduce the differences between parameters by increasing the number of studies involved in the analysis process. Another noteworthy goal of meta-analysis is to find inconsistencies between the results and their causes [47-49]. The present meta-analysis was conducted to evaluate CT scan findings of COVID-19 at the time of admission.

Material and methods

Study protocol

The International Prospective Register of Systematic Reviews (PROSPERO) database and international databases were first reviewed to find relevant published or ongoing projects. All research steps were taken according to the Meta-Analysis of Observational Studies in Epidemiology (MOOSE) protocol [49] and the final report was based on the Preferred Reporting Items for Systematic Reviews and Meta-Analyses (PRISMA) guideline (Suppl Table 1) [50]. Each stage of the study was conducted by two independent authors. Disagreements were resolved by discussion

or a third author was involved. We registered this review at PROSPERO (registration number: CRD42020178078) (Suppl Figure 1). Available at: https://www.crd.york.ac.uk/prospero/display_record.php?RecordID=178078.

Literature search

We searched the Web of Science: ISI, Medline-Ovid, Science Direct, Scopus, EMBASE, PubMed/Medline, Cochrane Library (Cochrane Database of Systematic Reviews – CDSR), EBSCO, CINAHL and Google Scholar databases using the following keywords: “2019 nCoV”, “Novel coronavirus”, “COVID-19”, “Novel coronavirus 2019”, “Wuhan pneumonia”, “Wuhan coronavirus”, “acute respiratory infection”, “COVID-19”, and “SARS-CoV-2”, “CT scan”, “Computed tomography”, “Radiology”, “Radiography”, “Clinical Characteristics”, “clinical features”, and “COVID-19”. An example of a combined search within PubMed is as follows: (“2019 nCoV”, OR “Novel coronavirus”, OR “COVID-19”, OR “Novel coronavirus 2019”, OR “Wuhan pneumonia”, OR “Wuhan coronavirus”, OR “acute respiratory infection”, OR “COVID-19”, OR “SARS-CoV-2”) AND (“CT scan” OR “Computed tomography” OR “Radiology” OR “Radiography” OR “Clinical characteristics” OR “clinical features” OR “COVID-19”).

The search was conducted on March 20, 2020. Additional studies were identified by reviewing the reference lists of relevant articles. No language restrictions were applied. Since the present study was based on a regular review of previous studies, approval of the organizational review board and patient satisfaction were not necessary. The research received no specific funding. Grey literature was found at medrxiv (<https://www.medrxiv.org/>) and manual search of related articles was also conducted.

Inclusion and exclusion criteria

Inclusion criteria were all cross-sectional epidemiological studies aimed at examining chest CT scan findings in COVID-19 patients from January 1, 2020 until March 20, 2020 without language restrictions. Exclusion criteria were as follows: 1. Non-random sampling; 2. Duplicate studies; 3. Studies on non-adult population (more than 10% of sample size being children); 4. Being irrelevant; 5. Sample size smaller than 10 participants; 6. Diagnostic intervention for COVID-19 other than laboratory confirmation; 7. CT scan findings have not been verified by at least one radiology expert; 8. Poor quality in qualitative evaluation; and 9. Case reports, review articles, and letters to the editor without quantitative data.

Study selection and data extraction

Two authors independently presented the results of the initial search with the title and abstract. At this stage, duplicate and unrelated studies were excluded. Duplicate

studies were identified manually or using EndNote X9. Both authors then reviewed the full text of appropriate articles for the inclusion and exclusion criteria. Finally, the authors extracted the data independently from the articles. Any discrepancy between the data extractors was resolved by consensus or by a third author. It should be noted that when an article reported duplicate information from the same patients, both reports were combined to obtain the most complete data, but it was considered as one case.

The data summary form includes the following items: first author's name and year of publication, country and province, article references, study design, mean age and standard deviation, average duration from onset of symptoms until admission, time of performing CT scan, COVID-19 detection method, patient description, sample (respiratory secretions, blood, etc.), sample location (nasal, pharyngeal, etc.), number of patients (total, male and female), number of patients referred to the intensive care unit (ICU), quality of articles, outcomes information: positive chest CT scan in COVID-19 patients, including the sensitivity of chest CT, bilateral pneumonia, predominant chest CT scan patterns [GGO, mixed (GGO pulse consolidation or reticular), consolidation, reticular, and presence of nodule], other chest CT scan features (thickened interlobular septa, vascular enlargement, air bronchogram sign, bronchial wall thickening, bronchiolectasis, fibrous stripes, crazy-paving pattern, thickening of the adjacent pleura, pleural effusion and lymphadenopathy), distribution of lesions (peripheral, central, and peripheral pulse central), lobes involvement (right upper lobe, right middle lobe, right lower lobe, left upper lobe, and left lower lobe) and number of involved lobes (one lobe, two lobes, three lobes, four lobes, and five lobes).

Qualitative evaluation

Based on the type of studies, the adapted Newcastle-Ottawa Scale (NOS) was used to evaluate the risk of bias [51]. Three categories were defined: studies with scores less than 6 were low-quality studies, studies with scores of 6 or 7 were medium-quality, and studies with scores of 8 or 9 were high-quality studies.

Statistical analysis

The I^2 index (with values ranging from 0 to 100%) was used to evaluate the heterogeneity between studies; values above 75% indicate high heterogeneity, values within 50-74% indicate significant heterogeneity, values within 25-49% indicate moderate heterogeneity, and values below 25% indicate low heterogeneity [52,53]. In addition, $p < 0.1$ was also defined for heterogeneity. Meta-analysis was performed with at least three studies. In the case of low heterogeneity the fixed effects model, and otherwise the random effects model, was used to combine the studies. Results were reported as pooled prevalence and 95% confidence interval. To identify the cause of heterogeneity, we

could not perform subgroup analysis or meta-regression due to limitations. Sensitivity analysis for meta-analyses with at least five studies was performed by omitting one study at a time to evaluate the consistency of the results. Funnel plots and the Begg and Egger tests were used to evaluate publication bias. All analyses were performed using comprehensive meta-analysis. P -values less than 0.05 were considered statistically significant.

Results

Description of included studies

We identified 2266 potential articles from databases. After removing duplicates, there were 766 articles left. After evaluating the titles and abstracts, 76 articles were removed for at least one of the following reasons: non-random sampling ($n = 10$), studies on non-adult population ($n = 3$), being irrelevant ($n = 650$), diagnostic intervention for COVID-19 other than laboratory confirmation ($n = 3$), CT scans findings not verified by at least one radiology expert ($n = 2$), poor quality in qualitative evaluation ($n = 0$), and case reports, review articles, and letters to the editor without quantitative data ($n = 58$). Finally, 40 eligible studies with 4598 patients with COVID-19 were used for meta-analysis. This process is illustrated in Figure 1. All studies were conducted in China and all of them were of good or moderate quality and the details of studies are summarized in Table 1. The mean age of the study participants was 50.52 years (95% CI: 50.87-52.17).

Risk of bias

The risk of bias based on the NOS tool is shown in Table 1. Fourteen and 26 studies had moderate and good quality, respectively.

Sensitivity of chest CT findings for COVID-19

The sensitivity of chest CT scan in patients with COVID-19 was 94.5% (95% CI: 91.7-96.3; $I^2 = 98.6\%$). The lowest and highest estimates were for studies by Haiyan *et al.* (61.5%) and many other studies (100%), respectively (Figure 1A).

Bilateral lung involvement

Bilateral lung involvement in chest CT scan with COVID-19 pneumonia was observed in 79.1% of patients (95% CI: 70.8-85.5) (Figure 2B).

Predominant chest CT scan patterns

Pure GGO, mixed (GGO pulse consolidation or reticular), consolidation, reticular, and presence of nodule findings in chest CT scan of COVID-19 pneumonia patients were observed in 64.9% (95% CI: 54.1-74.4), 49.2% (95% CI:

Table 1. Characteristics of articles entered into meta-analysis

Ref.	First author, published Year	Source	Time assessment	Country/Province	Population	Age (year)		The onset of symptoms to admission (day)		ICU/Isolate admission	Sample	COVID-19 confirmation	Sample size			Quality
						Mean	SD	Median	Range				All	Male /Female	CT(+)	
[9]	Chen G, 2020	medRxiv	On admission	China, Wuhan	Patients with 2019-nCoV pneumonia (severe and moderate)	56.3	14.30				Respiratory specimens	Next-generation sequencing or real-time RT-PCR	21	17/4	21	7
[8]	Huang C, 2020	Lancet	On admission	China, Wuhan	Patients with 2019-nCoV pneumonia	49.0	41-58	7.0	4-8	13/8	Respiratory specimens or plasma	RT-PCR confirmed	41	30/11	41	9
[3]	Chen N, 2020	Lancet	On admission	China, Wuhan	Patients with 2019-nCoV pneumonia	55.5	13.1				Throat swab specimens	RT-PCR confirmed	99	67/32	99	9
[10]	Yang W, 2020	Journal of Infection	On admission	China, Zhejiang	Patients with 2019-nCoV pneumonia	45.11	13.35	6.8	5	0/149	Nasal and pharyngeal swab specimens	RT-PCR confirmed	149	81/68	132	7
[11]	Xu YH, 2020	Journal of Infection	Not mentioned	China, Beijing	Patients with 2019-nCoV pneumonia	43.9	16.8				Not mentioned	Nucleic acid testing	50	29/21	41	6
[12]	Sh H, 2020	The Lancet Infectious Diseases	On admission	China, Wuhan	Patients with confirmed COVID19 pneumonia	49.5	11.0				Throats wab	Next-generation sequencing or RT-PCR	81	42/39	81	8
[13]	Wang D, 2020	JAMA	On admission	China, Wuhan	Patients with confirmed COVID19 pneumonia			7.0	4-8	36/102	Throats wab specimens	RT-PCR confirmed	138	75/63	138	9
[14]	Pan Y, 2020	European Radiology	On admission	China, Wuhan	Patients with confirmed COVID19 pneumonia	44.9	15.2				Nasopharyngeal	RT-PCR confirmed	63	33/30	63	8
[15]	Xu X, 2020	BMJ: British Medical Journal	On admission	China, Zhejiang	Patients with confirmed COVID19 pneumonia	41.0	32-52	2.0	1-4		Sputum and throat swab specimens	RT-PCR confirmed	62	36/27	61	8
[16]	Li Y, 2020	American Journal of Roentgenology	On admission	China, Wuhan	Patients with COVID-19	58.0	17				Oropharyngeal swab	nucleic acid testing	51	28/23	51	9
[17]	Zhou S, 2020	American Journal of Roentgenology	On admission	China, Wuhan	Patients with confirmed COVID19 pneumonia	52.8	12.2				Respiratory specimens	RT-PCR confirmed	62	39/23	62	9
[18]	Zhao W, 2020	American Journal of Roentgenology	Not mentioned	China, Hunan	Patients with confirmed COVID19 pneumonia	44.44	12.3				Not mentioned	RT-PCR confirmed	101	56/45	93	8

Table 1. Cont.

Ref.	First author, published Year	Source	Time assessment	Country/Province	Population	Age (year)		The onset of symptoms to admission (day)		ICU/isolate admission	Sample	COVID-19 confirmation	Sample size			Quality
						Mean	SD	Median	Range				All	Male /Female	CT(+)	
[19]	Guan WJ, 2020	medRxiv	On admission	China, 31 provinces	patients with laboratory-confirmed 2019-nCoV ARD					55/1044	Nasal and pharyngeal swab specimens	RT-PCR confirmed	1099	640/459	840	7
[20]	AI JW, 2020	medRxiv	On admission	China, Eastern cities	Patients with confirmed COVID19 pneumonia						Nasopharyngeal swab specimens	RT-PCR confirmed	20	10/10	20	8
[21]	Feng Z, 2020	medRxiv	On admission	China, outside Wuhan	Patients with confirmed COVID19 pneumonia	44.0					Nasal and pharyngeal swab specimens	RT-PCR confirmed	141	72/69		7
[22]	Yuan M, 2020	medRxiv	On admission	China, Wuhan	Patients with confirmed COVID19 pneumonia		8.0	5-11			Throat-swab specimens	RT-PCR confirmed	27	12/15	27	8
[23]	Qian GQ, 2020	medRxiv	On admission	China, Zhejiang	Patients with COVID-19						Throat-swab specimens	RT-PCR confirmed	88	37/54	83	8
[24]	Cao W, 2020	medRxiv	On admission	China, Hubei	Patients with COVID-19						Nasal and pharyngeal swab specimens	RT-PCR confirmed	128	60/68		8
[25]	Liang Y, 2020	medRxiv	Not mentioned	China, Beijing	Patients with confirmed COVID19 pneumonia						Throat-swab specimens	RT-PCR confirmed	21	11/10	21	8
[26]	Huang Y, 2020	medRxiv	On admission	China, Wuhan	Non-survivors patients with COVID-19	69.22	9.64				Not mentioned	RT-PCR confirmed	36	11/25	32	7
[27]	Wu J, 2020	Invest Radiol	On admission	China, Chongqing	Patients with COVID-19	44.0	11.00	7.0	4		Throat swabs or lower respiratory tract	RT-PCR confirmed	80	42/38	76	7
[28]	Kui L, 2020	Chinese Medical Journal	Not mentioned	China, Hubei	Patients with COVID-19	55.0	16.00				Sputum and nasopharyngeal swabs	Nucleic acid positive and RT-PCR confirmed	137	61/76		7

Table 1. Cont.

Ref.	First author, published Year	Source	Time assessment	Country/Province	Population	Age (year)			The onset of symptoms to admission (day)		ICU/isolate admission	Sample	COVID-19 confirmation	Sample size			Quality
						Mean	SD		Median	Range				All	Male /Female	CT(+)	
[29]	Chung M, 2020	Radiology	On admission	China, three provinces	Patients with COVID-19	51.0	14.00					RT-PCR confirmed	21	13/8	18	7	
[30]	Song F, 2020	Radiology	Not mentioned	China, Wuhan	Patients with COVID-19	49.0	16	4.0	1-14			RT-PCR confirmed	51	25/26	50	8	
[31]	Bernheim A, 2020	Radiology	On admission	China, four provinces	Patients with COVID-19	45.0	15.60		1-15			RT-PCR confirmed	121	61/60	94	8	
[32]	Xu Z, 2020	Lancet	On admission	China, Guangdong	Patients with confirmed COVID19 pneumonia	43.1	17.10					Not mentioned	21	10/11	17	9	
[33]	Li K, 2020	Investigative Radiology	On admission	China, Chongqing	Patients with confirmed COVID19 pneumonia	45.5	12.3					RT-PCR confirmed	83	44/39		8	
[34]	Zhang JJ, 2020	Epidemiology and Genetics	On admission	China, Wuhan	Patients with COVID-19			8.0	6-11			RT-PCR confirmed	135	68/67	134	8	
[35]	Wang Y, 2020	Lancet	Not mentioned	China, Wuhan	Patients with COVID-19							Nucleic acid	511		492	8	
[36]	Hu Z, 2020	Science China Life Sciences	On admission	Nanjing, China	Asymptomatic carriers were laboratory-confirmed positive for the COVID-19 virus					1/23		RT-PCR confirmed	24	8/16	17	9	

Table 1. Cont.

Ref.	First author, published Year	Source	Time assessment	Country/Province	Population	Age (year)		The onset of symptoms to admission (day)		ICU/isolate admission	Sample	COVID-19 confirmation	Sample size			Quality
						Mean	SD	Median	Range				All	Male /Female	CT(+)	
[37]	Haiyan Fu, 2020	medRxiv	On admission	Kunming, China	Patients with COVID-19					2/34	Respiratory specimens	RT-PCR confirmed	36	16/20	22	8
[38]	Li J, 2020	medRxiv	On admission		Patients with confirmed COVID19 pneumonia			5.0	2-7	58/240	Throat swab	RT-PCR confirmed	17	9/8	16	7
[39]	Cai Q, 2020	medRxiv	On admission	China, Hubei Province	Patients with confirmed COVID19 pneumonia	47.0	33-61			32/266	Nasal swab	RT-PCR confirmed	298	149/149	298	8
[40]	Jian-ya G, 2020	medRxiv	On admission	China, Chongqing	Patients with COVID-19			6.0	3-8	7/44	Not mentioned	RT-PCR confirmed	51	32/19	51	7
[41]	Cui P, 2020	medRxiv	On admission	China, Wuhan	Patients with COVID-19	61.5	11.2				Throat swab	RT-PCR confirmed	35	0/35	35	8
[42]	Cao M, 2020	medRxiv	On admission	China, Shanghai	Patients with COVID-19	50.1	16.3	5.0		19/179	Throat-swab specimens	RT-PCR confirmed	198	101/97	195	6
[43]	Xu Y, 2020	medRxiv	On admission	China, Chinese Han	Patients with confirmed COVID19 pneumonia					25/44	Pharyngeal swab specimens	RT-PCR confirmed	69	35/34	69	7
[44]	Chen J, 2020	medRxiv	On admission	China, Wuhan	Death cases with COVID-19	65.46	9.74	11.0	8-13.5	47/54	Not mentioned	RT-PCR confirmed	101	64/37	99	7
[45]	Liu J, 2020	medRxiv	On admission	China, Wuhan	Medical staff infected with COVID-19			8.5	4.3-15.0		Throat-swab specimens	RT-PCR confirmed	64	28/36	58	8
[46]	Lei Y, 2020	medRxiv	On admission	China, Chengdu	Tibetan patients with COVID-19	39.3	18.3			7/60	Nasal and pharyngeal swabs or blood	RT-PCR confirmed	67	39/28	47	8

SD – standard deviation, NR – not reported

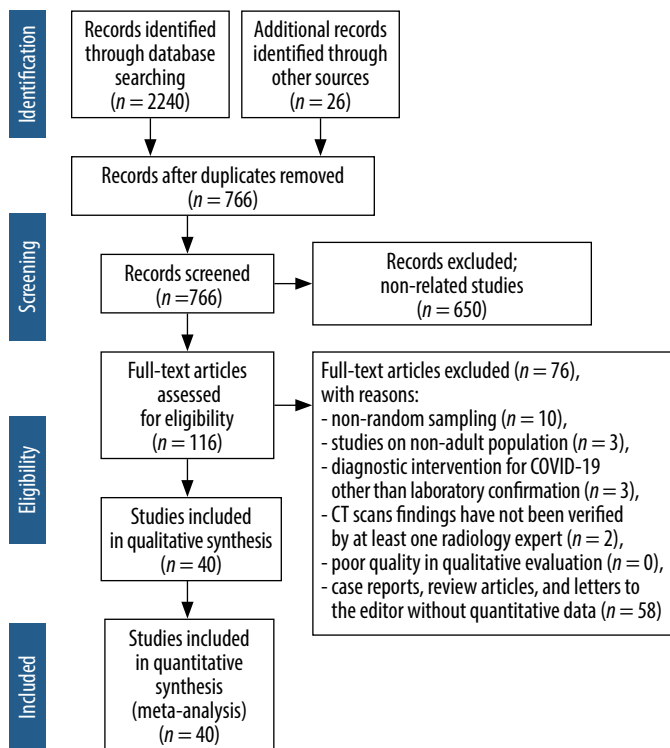


Figure 1. Preferred reporting items for systematic reviews and meta-analyses flowchart

35.7-62.8), 30.3% (95% CI: 19.6-43.6), 17.0% (95% CI: 3.9-50.9) and 16.6% (95% CI: 13.6-20.2) of patients (Figure 3).

Other chest CT scan features

Other chest CT scan features are shown in Figure 4: thickened interlobular septa – 63.6% (95% CI: 52.1-73.8), vascular enlargement – 61.4% (95% CI: 40.4-79.0), air bronchogram sign – 53.5% (95% CI: 40.3-66.2), bronchial wall thickening – 19.8% (95% CI: 12.6-29.6), bronchiolectasis – 19.9% (95% CI: 6.5-47.2), fibrous stripes – 17.2% (95% CI: 5.2-44.2), crazy-paving pattern – 21.7% (95% CI: 13.8-32.5), thickening of the adjacent pleura – 30.0% (95% CI: 16.1-48.8), pleural effusion – 6.9% (95% CI: 4.7-10.1) and lymphadenopathy – 4.7% (95% CI: 3.0-7.5) (Figure 4).

Lesions distribution

The distribution of lung lesions in patients with COVID-19 pneumonia was as follows: peripheral (70.0% [95% CI: 57.8-79.9]), central (3.9% [95% CI: 1.4-10.6]), and peripheral and central (31.1% [95% CI: 19.5-45.8]) (Suppl Figure 1).

Lobes involvement

Pulmonary lobes involvement in patients with COVID-19 pneumonia was as follows (Figure 5): right upper lobe

(58.4% [95% CI: 33.6-79.5]), right middle lobe (49.7% [95% CI: 23.0-76.6]), right lower lobe (86.5% [95% CI: 57.7-96.8]), left upper lobe (64.5% [95% CI: 37.3-84.7]), and left lower lobe (81.0% [95% CI: 50.5-94.7]).

Number of involved lobes

In patients with COVID-19 pneumonia, the number of involved lobes was as follows (Suppl Figure 2): one lobe (58.4% [95% CI: 33.6-79.5]), two lobes (31.1% [95% CI: 19.5-45.8]), three lobes (10.5% [95% CI: 8.0-13.8]), four lobes (20.1% [95% CI: 15.4-25.9]), and five lobes (43.2% [95% CI: 34.2-52.6]).

Sensitivity analysis

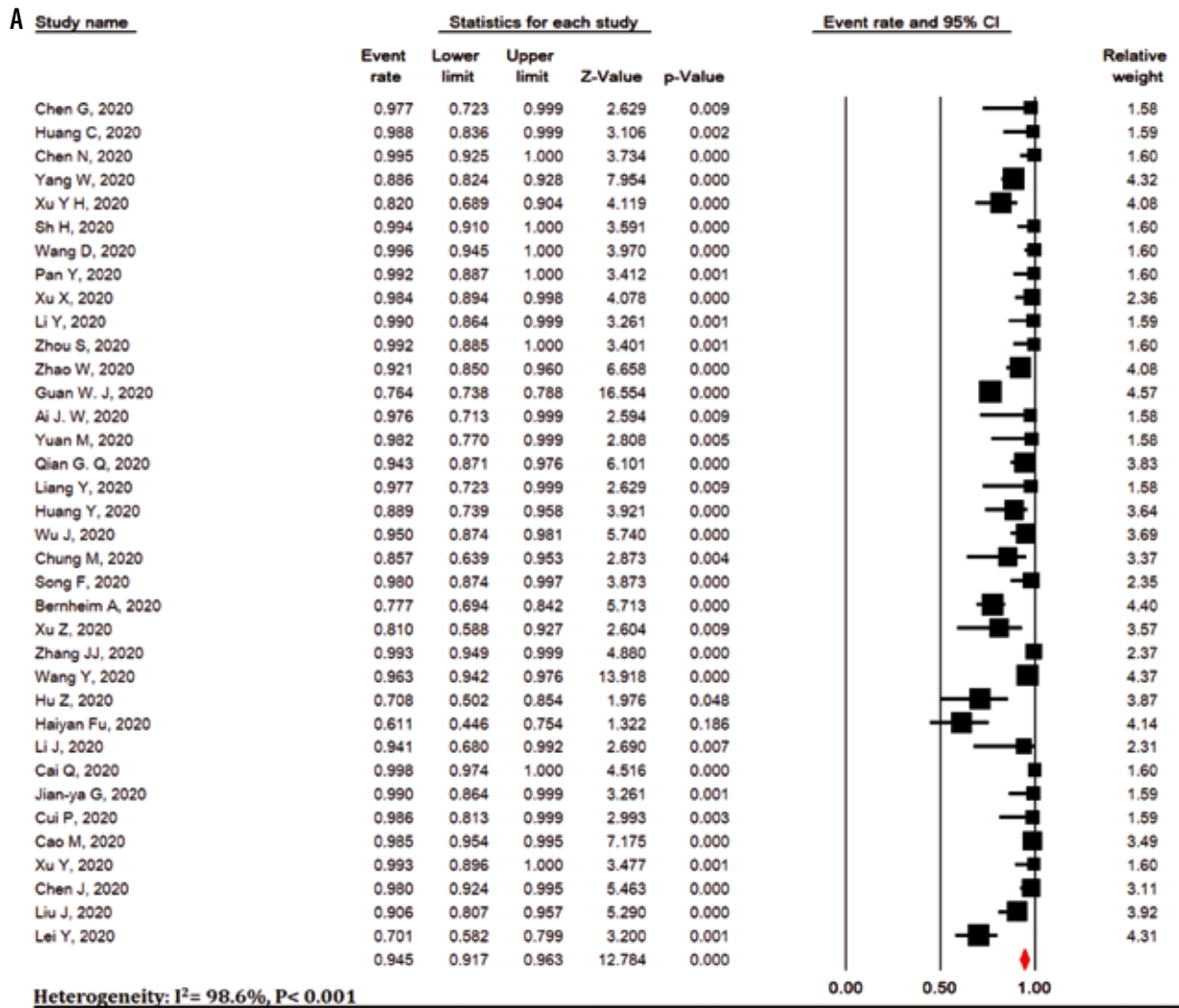
Sensitivity analysis was performed for all meta-analyses and it showed that the overall result remains robust after the omission of one study at a time (Suppl Figures 3-7).

Risk of publication bias

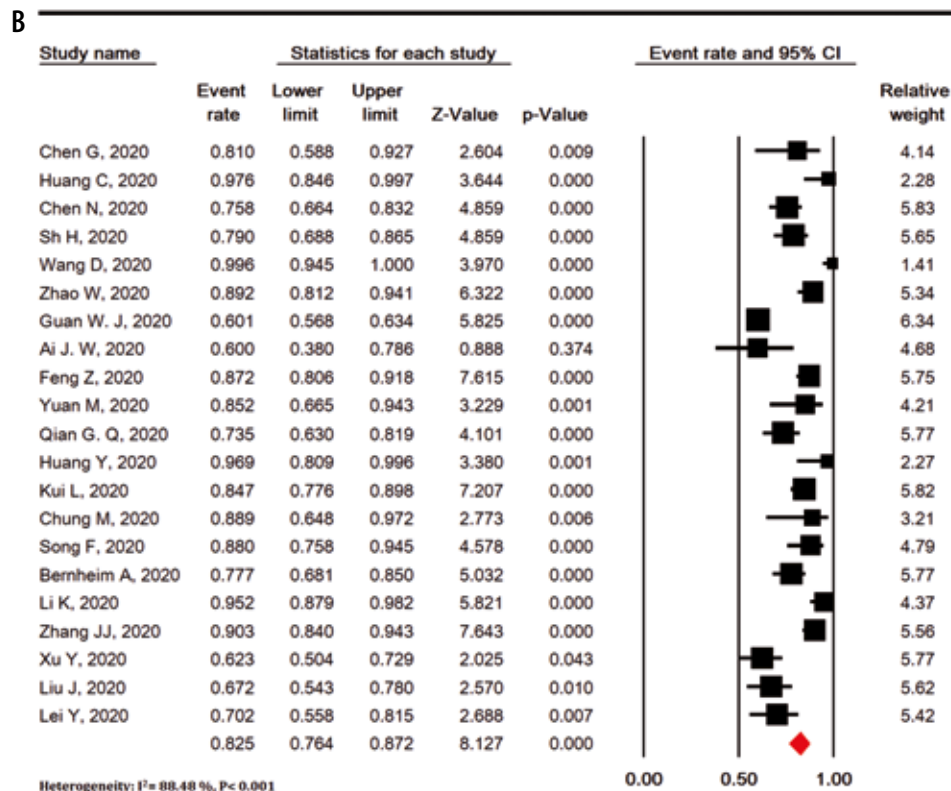
Publication bias was evaluated for studies that showed positive chest CT scan of COVID-19 patients (Begg’s test = 0.774 and Egger’s test < 0.001) and for studies that showed bilateral lung involvement in chest CT scan of COVID-19 patients pneumonia (Begg’s test = 0.194 and Egger’s test < 0.001) (Suppl Figure 8).

Discussion

The present study is the first systematic review and meta-analysis that extensively examines chest CT scan findings in COVID-19 patients. Our study showed that chest CT scan has high sensitivity in the diagnosis of COVID-19. COVID-19 is a new disease with serious consequences for public health. Chest CT scan is an important part of disease detection for patients suspected of having COVID-19 infection and may help early detection of lung malformations for the purpose of screening highly suspected patients, especially those with negative initial reverse-transcription polymerase chain reaction (RT-PCR) screening [54]. In fact, given the limited number of RT-PCR kits in many centers and the likelihood of false negative RT-PCR results, the National Health Commission of China has encouraged clinical findings and chest CT scan [55]. Our review showed some imaging findings that are often seen in patients with COVID-19. The present study showed that 94.5% of COVID-19 patients had positive chest CT scan findings, while the frequency of bilateral lung involvement in chest CT scan of COVID-19 pneumonia patients was 79.1%. It is important to observe the high incidence of bilateral organizing pneumonia in these patients. This suggests that corticosteroids may be an option to suppress this immune response in lung parenchyma of COVID-19 pneumonia.



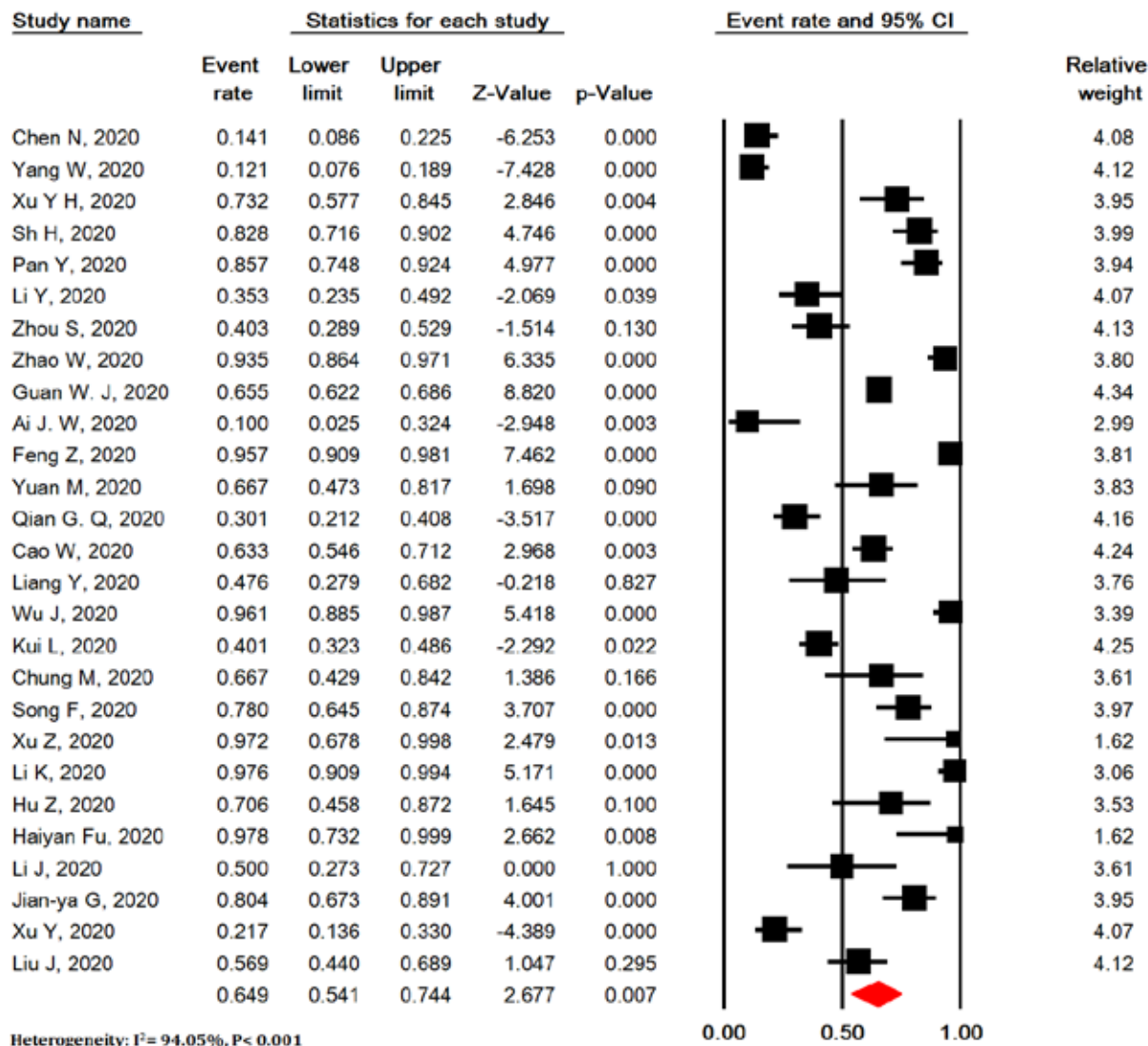
Meta Analysis



Meta Analysis

Figure 2. Meta-analysis of sensitivity of chest computed tomography scan (A) and meta-analysis of bilateral lung involvement in chest computed tomography scan (B) in patients with COVID-19

A



B

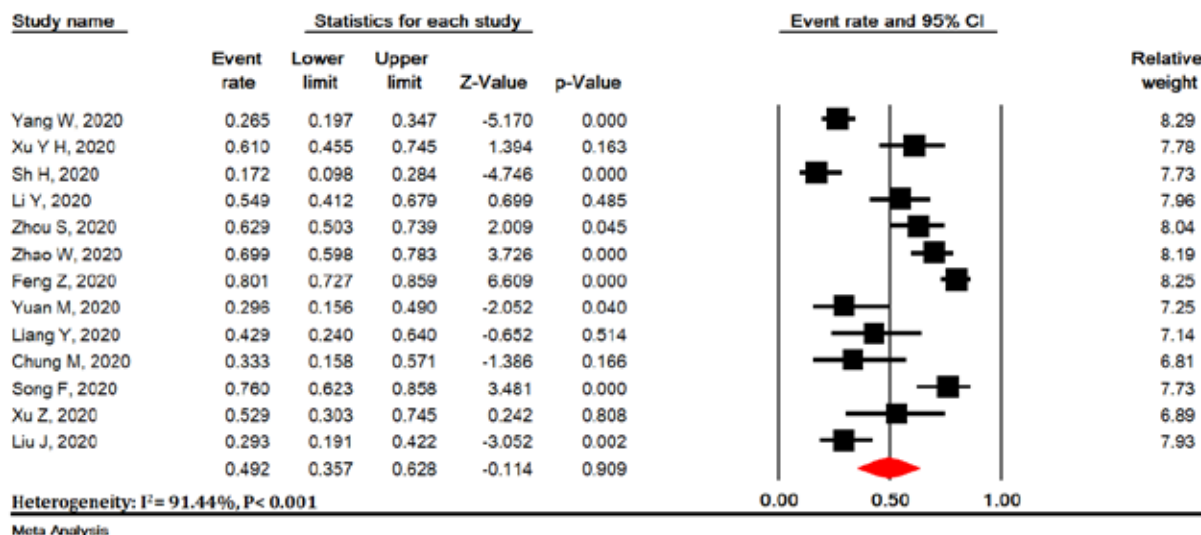
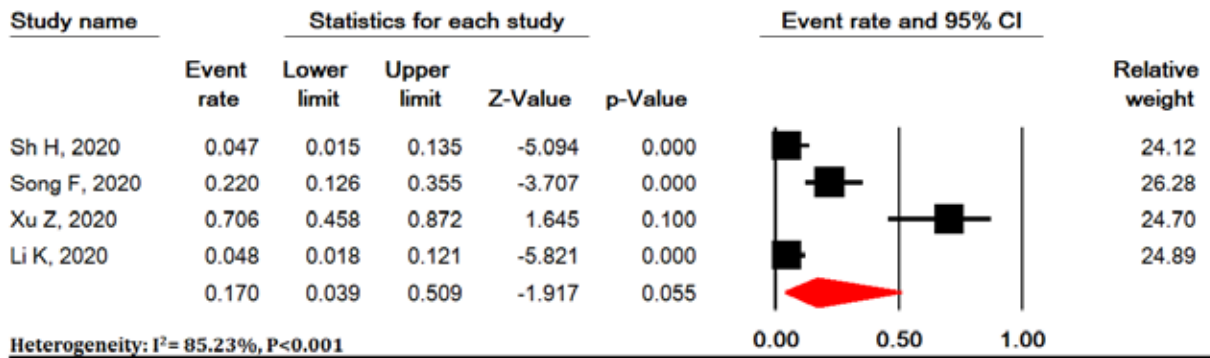


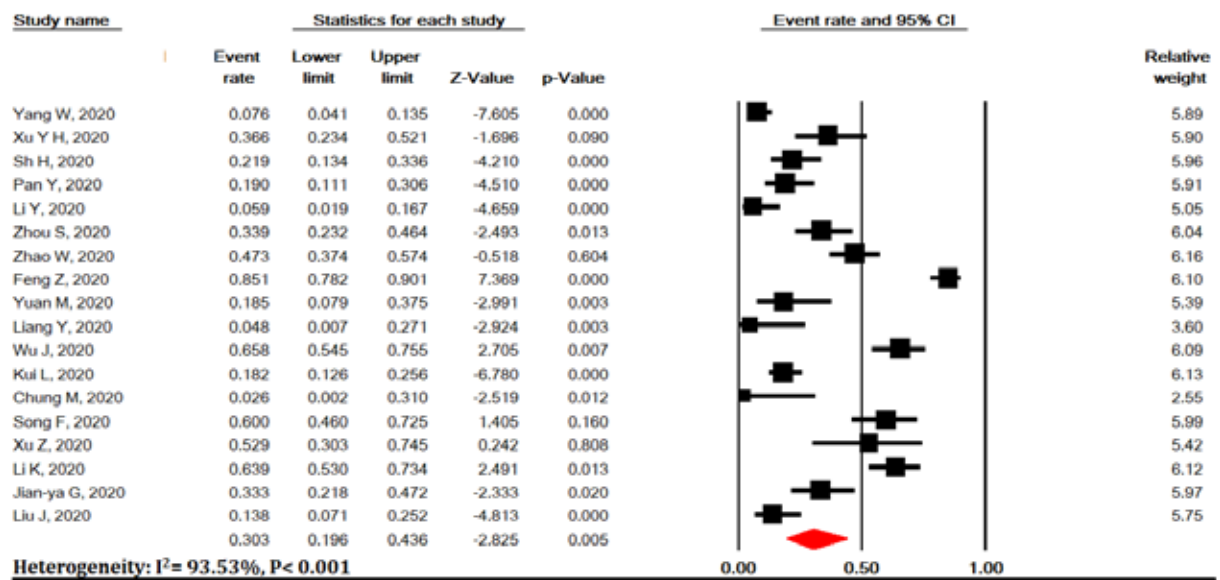
Figure 3. Meta-analysis of pure ground-glass opacity (GGO) (A), mixed (GGO pulse consolidation or reticular) (B), reticular (C), consolidation (D), and presence of nodule (E) findings in chest computed tomography scan of COVID-19 pneumonia

C



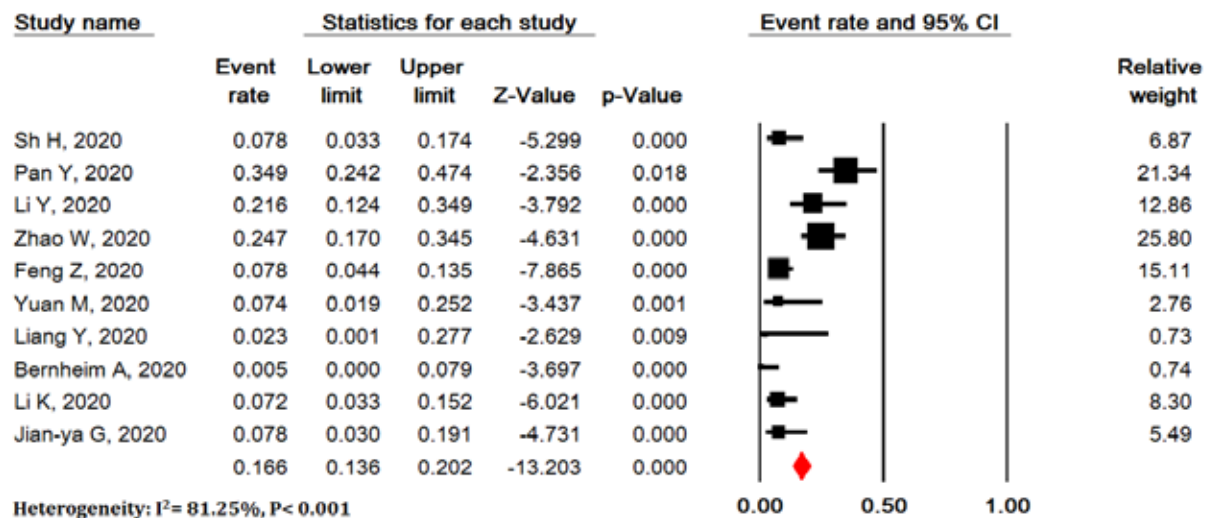
Meta Analysis

D



Meta Analysis

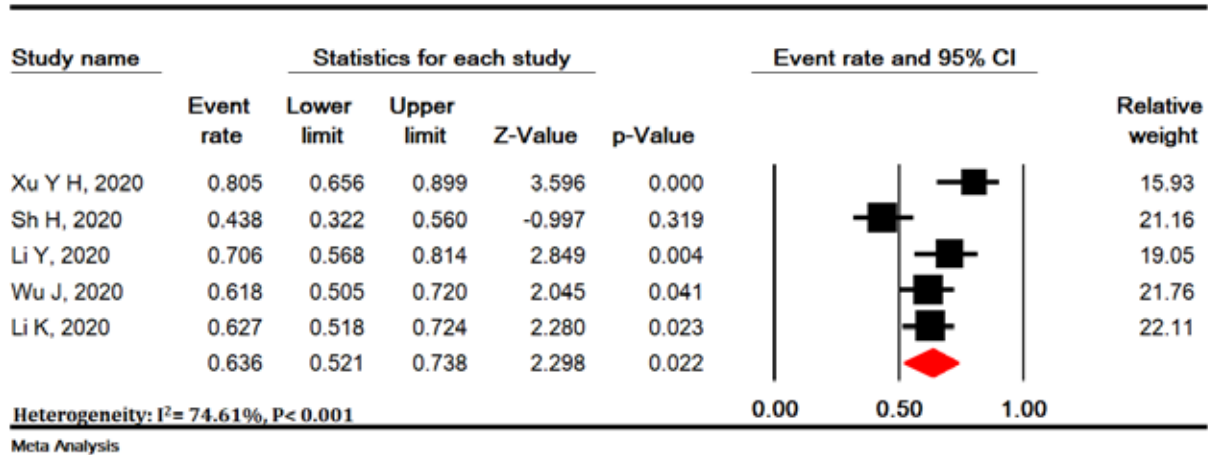
E



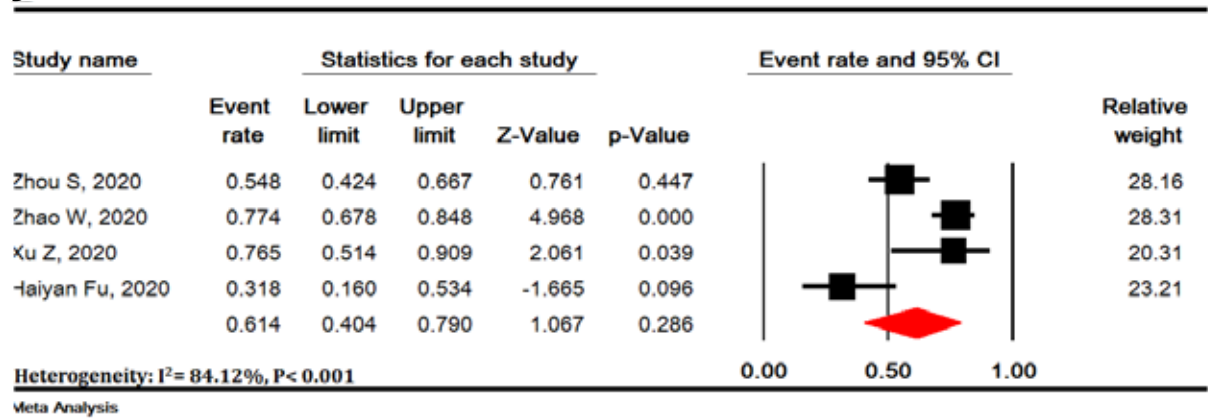
Meta Analysis

Figure 3. Cont.

A



B



C

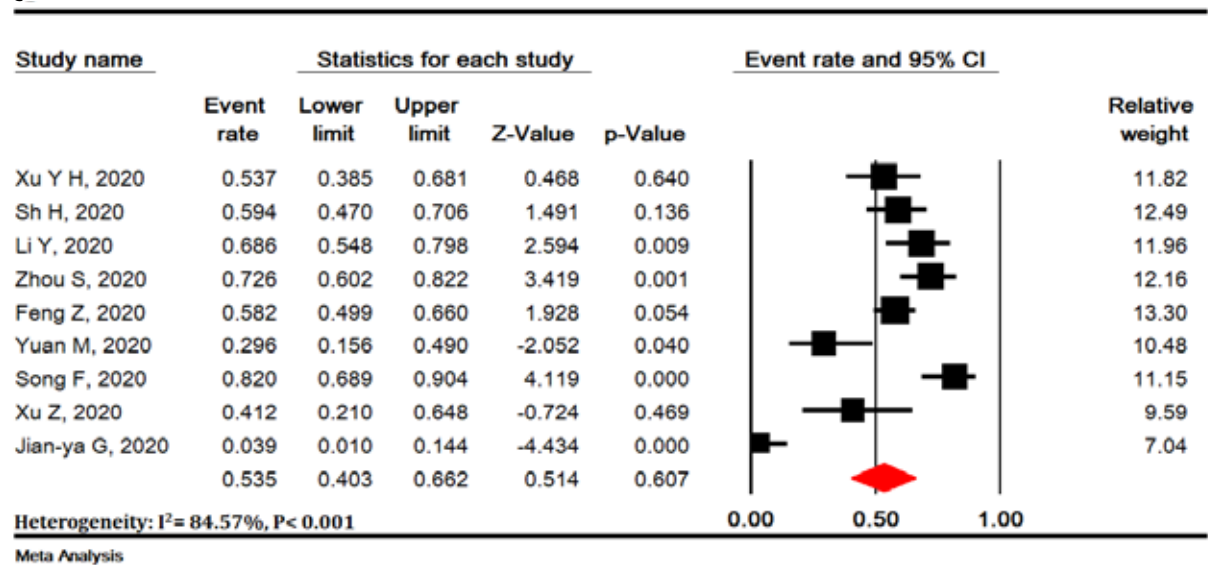
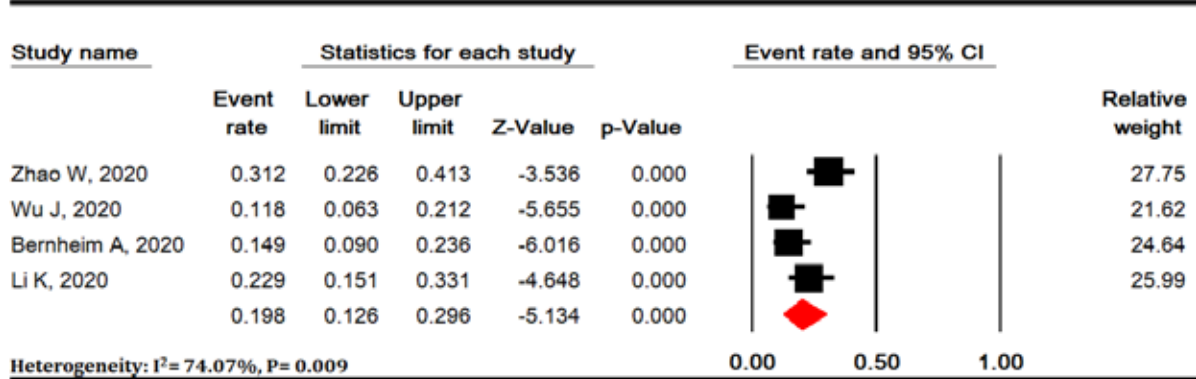
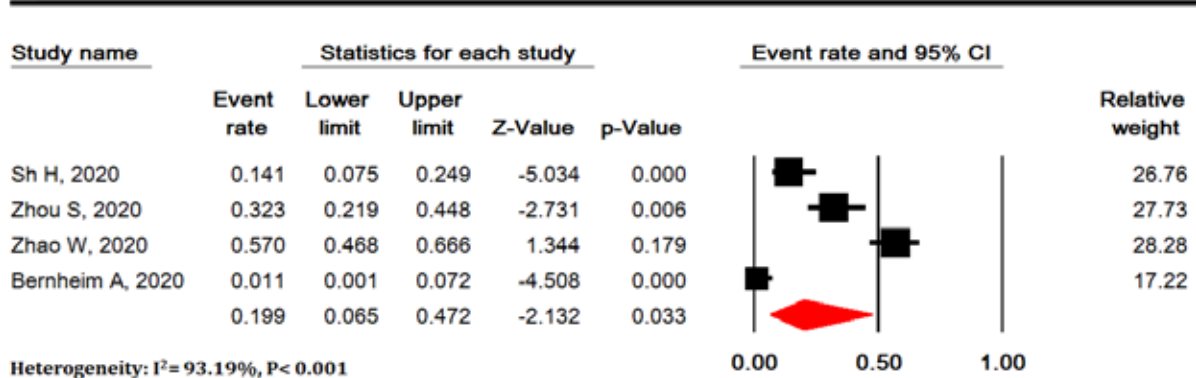


Figure 4. Meta-analysis of thickened interlobular septa (A), vascular enlargement (B), air bronchogram sign (C), bronchial wall thickening (D), bronchiolectasis (E), fibrous stripes (F), crazy-paving pattern (G), thickening of the adjacent pleura (H), pleural effusion (I) and lymphadenopathy (J) findings in chest computed tomography scan of COVID-19 pneumonia

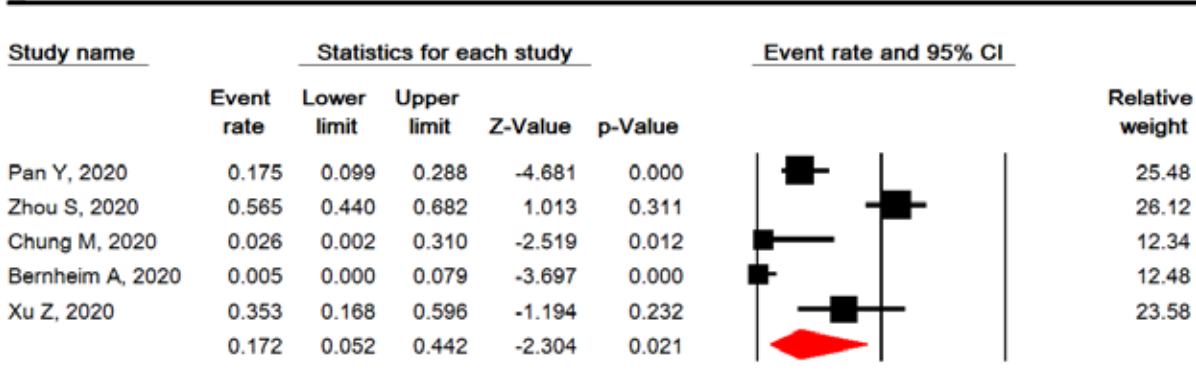
D



E



F



G

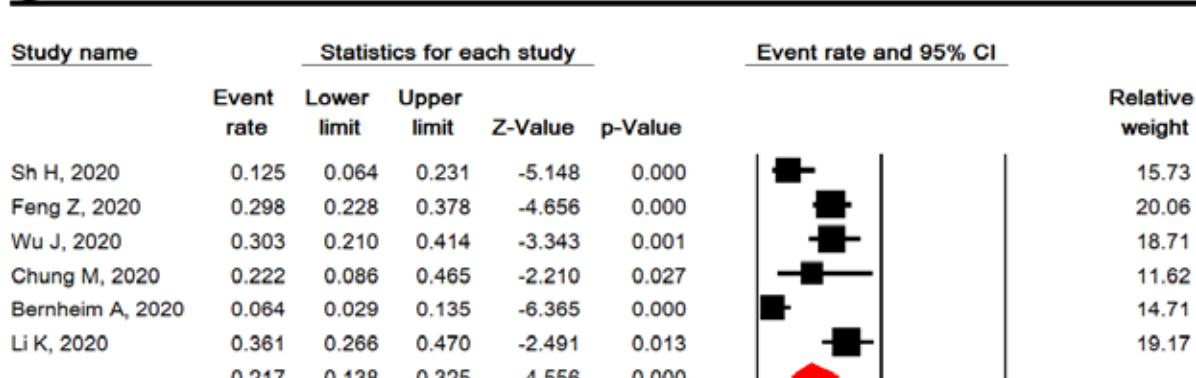
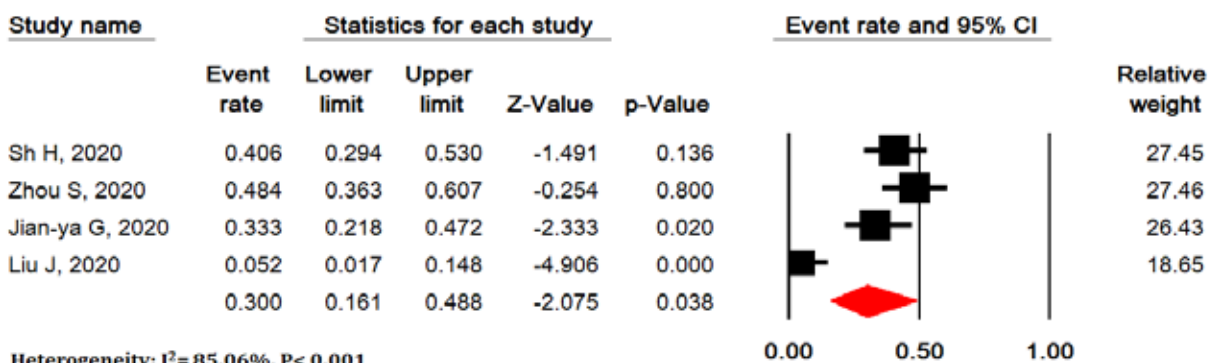


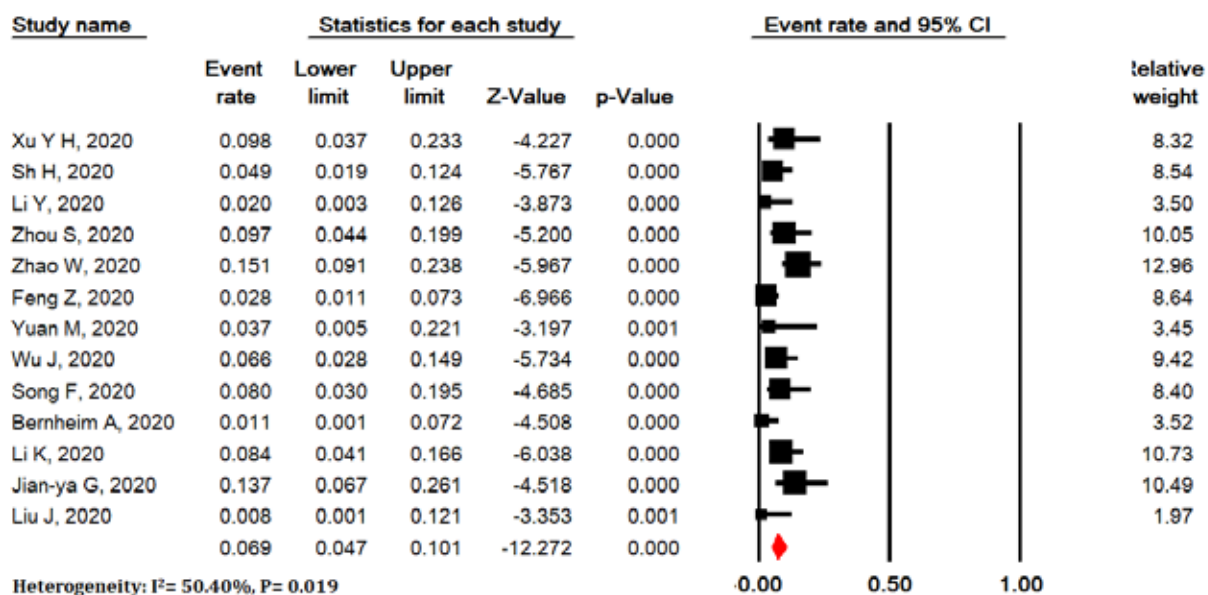
Figure 4. Cont.

H



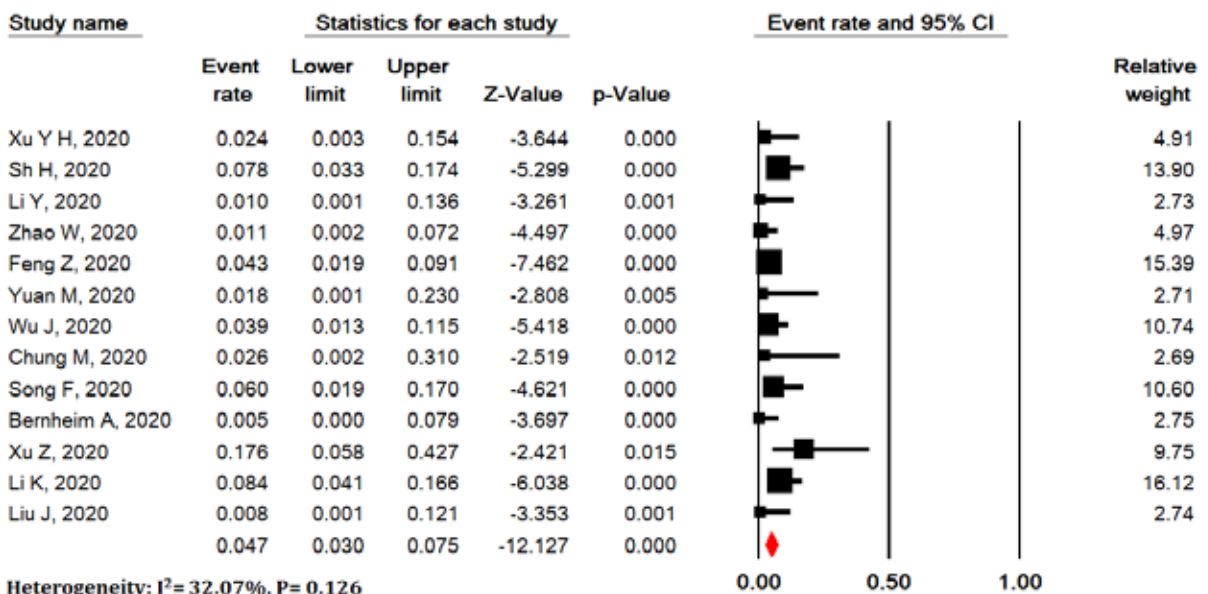
Meta Analysis

I



Meta Analysis

J



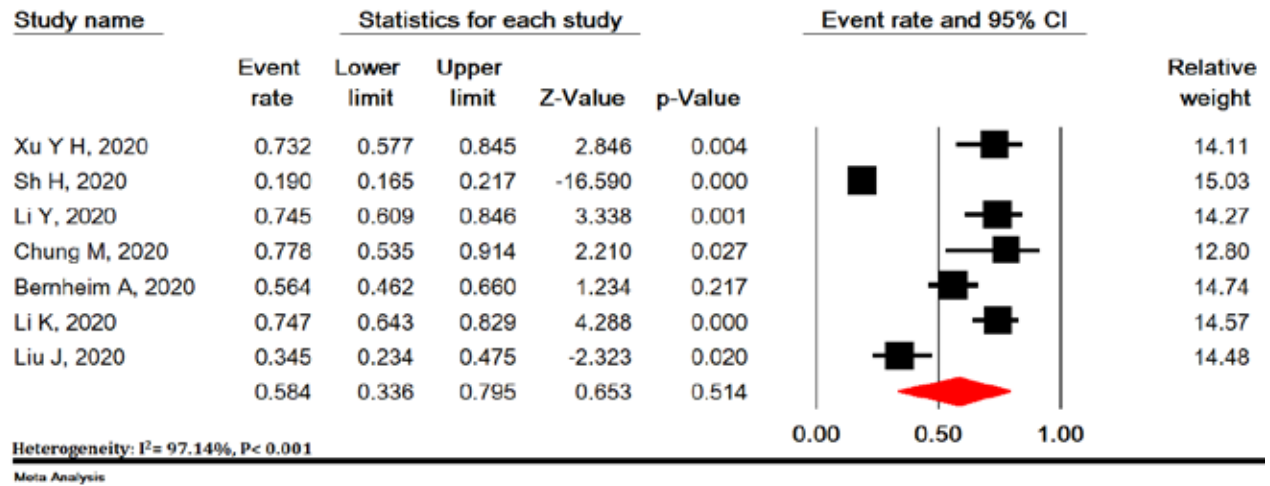
Meta Analysis

Figure 4. Cont.

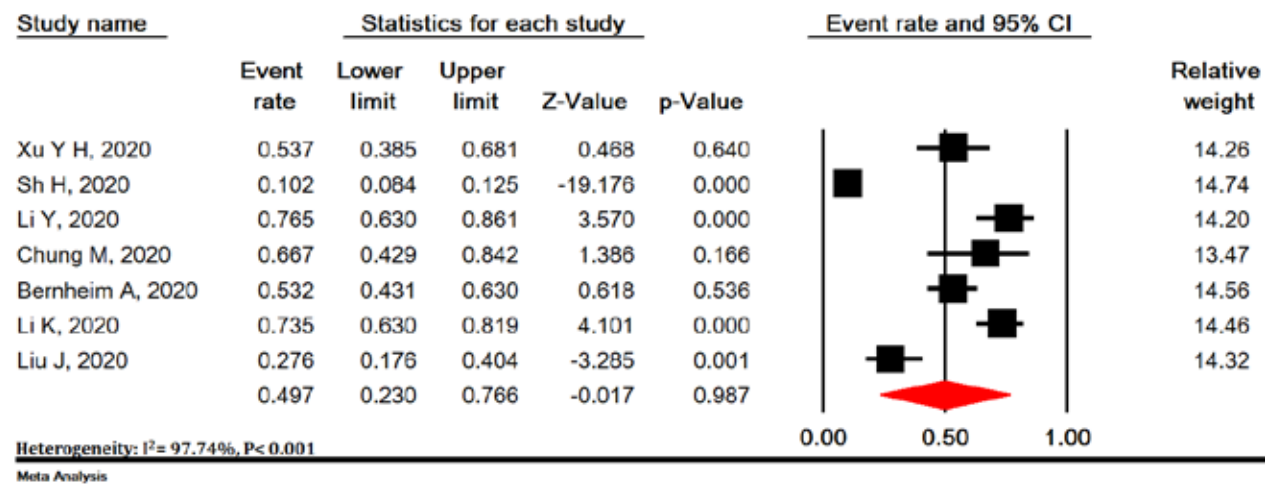
Viruses are a common cause of respiratory tract infection. Imaging findings of viral pneumonia are varied, and may overlap with other infectious and inflammatory lung diseases. Viruses in the same viral family have a similar

pathogenesis, so chest CT scan may help identify distinct patterns and features in immunocompromised patients [56]. Meta-analysis of initial data suggests that chest CT scan findings for 2019-nCoV have many features simi-

A



B



C

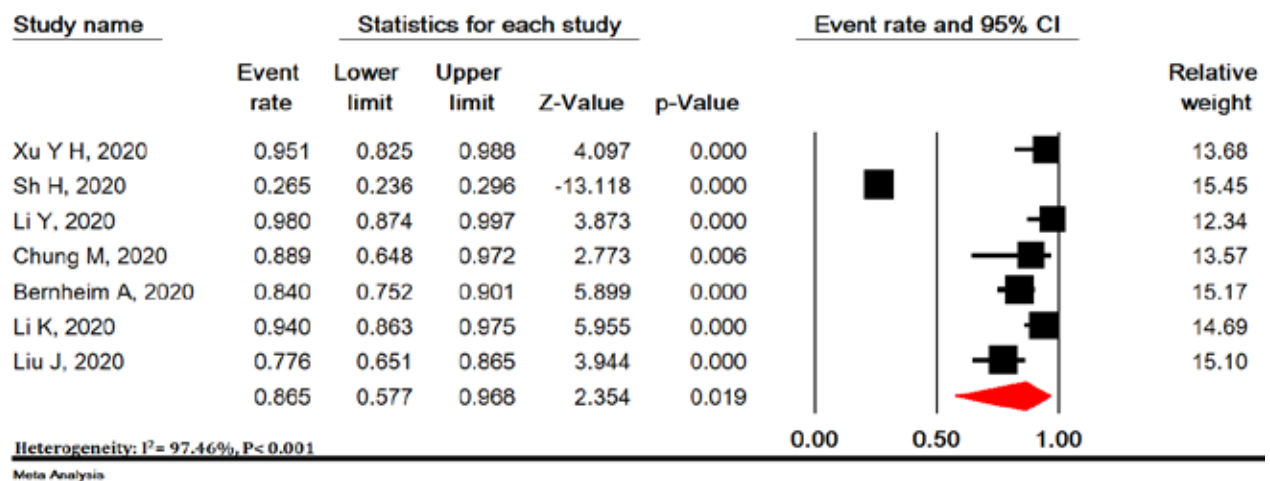
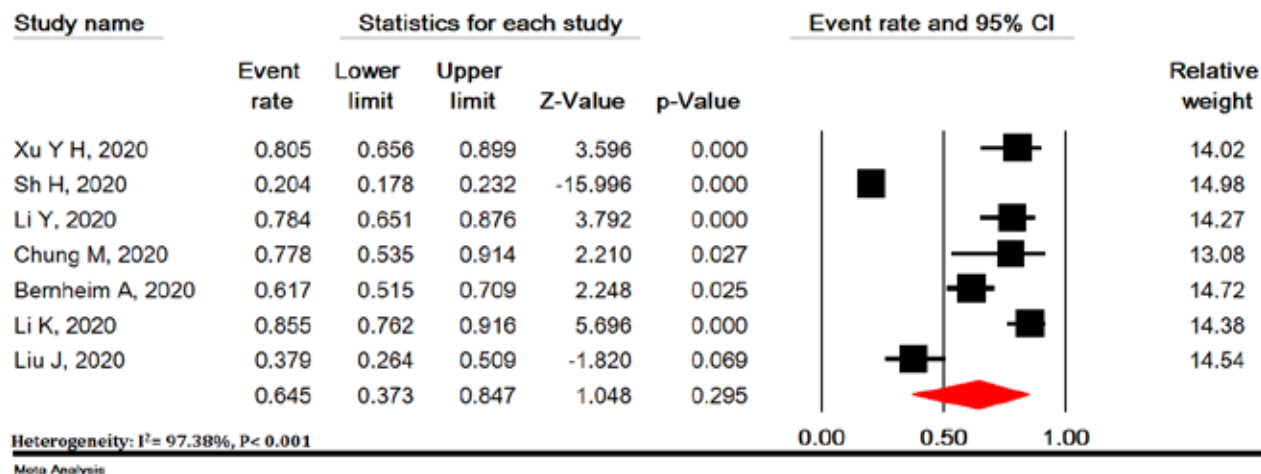


Figure 5. Meta-analysis of right upper lobe (A), right middle lobe (B), right lower lobe (C), left upper lobe (D), and left lower lobe (E) involvement in chest computed tomography scan of COVID-19 pneumonia

D



E

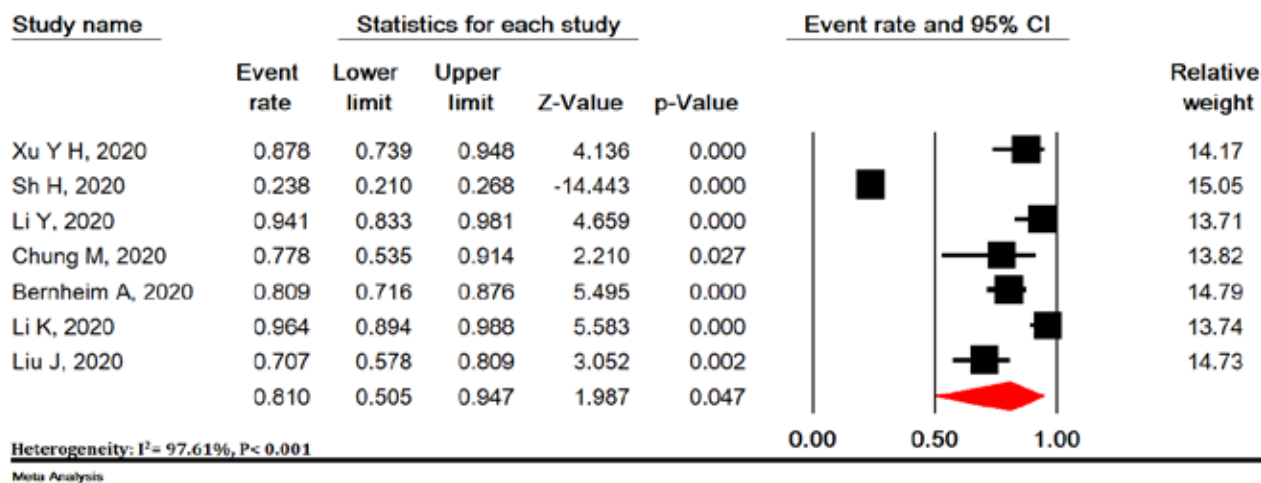


Figure 5. Cont.

lar to other viruses such as the middle east respiratory syndrome (MERS-CoV) and severe acute respiratory syndrome (SARS-CoV) [57].

In the present study, most pulmonary lesions include bilateral lung involvement with multiple lung lobes (predominantly right lower lobe and left lower lobe), with dominant distribution in the peripheral portion of the lungs. Studies have shown that influenza pneumonia tends to affect the lower lobes [56,58]. Wang *et al.* also showed that H7N9 pneumonia has a predominant distribution in the right lower lobe [58]. Both H1N1 and SARS pneumonia are more peripherally distributed [59,60], whereas no lobe infection is found in H5N1 influenza [61]. However, lung involvement with peripheral predominance has also been observed in SARS and MERS. Similarly, previous coronavirus pneumonias have a similar pattern. The dominant peripheral distribution for COVID-19 was shown in our study. Such a distribution is obvious at first glance. This feature of chest CT scan is caused by alveolar injury and pulmonary interstitial edema. We also observed some

chest CT scan features of COVID-19 that differ from chest CT scan features of SARS and MERS. Unifocal involvement is more common than multifocal involvement in patients with SARS and patients with MERS [62,63]. However, contrary to what is seen in the chest CT scan of patients with COVID-19, multi-lobe involvement was more common than single-lobe involvement in the present meta-analysis. Thus, more than two lobes are likely to be involved in this disease. To the best of our knowledge, these findings have not been reported in the literature related to SARS and MERS.

Our results showed that the most common findings of imaging were pure GGO, GGO with mixed consolidation or reticular pattern, interlobular septal thickening, and consolidation. Reticular and nodular pattern were relatively small, which may be explained in the first stage of the disease. In H7N9 pneumonia, most cases showed consolidation [62]. Each of the chest CT scan patterns in our patients is nonspecific and may overlap with other microorganism infections such as H7N9 pneumonia,

H1N1 virus infection, SARS, MERS, and avian influenza A (H5N1) [60-63].

GGO, consolidation, and interlobular septal thickening are the most common chest CT scan findings of H1N1 influenza pneumonia, too [59]. Based on the present meta-analysis, pure GGO is a common finding in about 65% of cases, and GGO with interlobular septal thickening/consolidation in 49% of COVID-19 pneumonia patients. Thus, these features of chest CT scan can be seen in most patients. This finding, along with the dominant distribution in the peripheral part of the lungs, is not common in other viral pneumonias [8,18,27,29,60,61].

In addition, we found that all features of chest CT scan that exist in the initial chest CT scan of patients with COVID-19, such as GGO and consolidation, and other chest CT scan features such as vascular enlargement, interlobular septal thickening, and air bronchogram sign, are also present in the chest CT scan of SARS and MERS. The low incidence of pleural effusion and lymphadenopathy noted in our data was also a feature of chest CT scan in previous studies about SARS [57]. This may be due to the inherent anatomical features of the lower lobe bronchus. The right lower lobe bronchus is tighter than other bronchi of the lung, and the angle between the right lower lobe and the long axis of the trachea is smaller, so it is more viral at early stages. Most likely, it attacks the bronchial branches of the lower lobe and causes infection.

Interestingly enough, we found that most patients have vascular enlargement lesions (61.4%) that may be caused by an acute inflammatory response. However, vascular changes are not similar to changes in malignant lesions such as lung adenocarcinoma that cause vascular dilatation or irregularity and vascular convergence, which may be due to chronic progression and tumor infiltration [17,64].

Angiotensin II converting enzyme is a key molecule involved in the development and progression of acute lung failure. COVID-19 induces direct lung injury by involving angiotensin converting enzyme, which contributes to the progression of alveolar injury [65]. This may explain the pathological mechanism of GGO and consolidation as well as rapid changes in chest CT scan findings. Our results support the observed process, according to which bilateral GGOs or mixed GGOs in chest CT scan should prompt the radiologist to recommend COVID-19 as a possible diagnosis [66,67].

Conclusions

In summary, this work is a meta-analysis on preliminary studies of chest CT scan findings about COVID-19, aimed at introducing the common imaging manifestations of the disease. Radiologists play an important role in rapid iden-

tification and early detection of new cases, which can be useful not only for the patient but also for public health surveillance systems. It is important to recognize the fact that the appearance of CT findings about COVID-19 has some similarities to other viral diseases, especially those in the same viral family (SARS and MERS). Future studies are recommended to determine how CT scans of COVID-19 patients change after treatment.

Limitations of this study include the following: 1. All studies were performed in China, and the severity of chest CT scan manifestations might be affected by ethnic factors; 2. Most patients were hospitalized patients and patients with milder symptoms or those who were not hospitalized, which may cause bias in the results; 3. In most preliminary studies, chest CT scan findings were not separately reviewed according to patients admitted to the ICU or the isolation ward; 4. Follow-up for chest CT scan during treatment until discharge was not included in our study; 5. Our results are based on CT findings during admission, but patients might have experienced symptoms before admission (because chest CT scan findings are influenced by the clinical course of the disease), and during this time the patient might have received antiviral or antibacterial drugs, or steroid therapy, and this might have affected the chest CT scan findings; 6. Since all studies were performed in 2020 in China with the same diagnostic method, we could not discover the cause of heterogeneity.

In conclusion, the most important outcomes in chest CT scan of patients with COVID-19 pneumonia were bilateral lung involvement, GGO or mixed (GGO pulse consolidation or reticular) patterns, thickened interlobular septa, vascular enlargement, air bronchogram sign, peripheral distribution, left and right lower lobes involvement, and one or five lobes involvement.

Our study showed that chest CT scan has high sensitivity in diagnosis of COVID-19, and may therefore serve as a standard method for diagnosis of COVID-19. Rapid detection may lead to early control of the transmission. By diagnosing viral pneumonia on CT scan, infected or suspected patients can be isolated and treated in a timely manner to optimize patient management, especially for hospitals or communities without RT-PCR test kits. However, chest CT scan is still limited in terms of identifying specific viruses. It is important that radiologists recognize whether chest CT scan findings for COVID-19 overlap with chest CT scan findings for diseases caused by different virus families, such as adenovirus.

Conflict of interest

The authors report no conflict of interest.

References

1. WHO. Coronavirus disease (COVID-19) outbreak 2020. Available from: <https://www.who.int/westernpacific/emergencies/covid-19>.
2. Li Q, Guan X, Wu P, et al. Early transmission dynamics in Wuhan, China, of novel coronavirus-infected pneumonia. *N Engl J Med* 2020; 382: 1199-1207.
3. Chen N, Zhou M, Dong X, et al. Epidemiological and clinical characteristics of 99 cases of 2019 novel coronavirus pneumonia in Wuhan, China: a descriptive study. *Lancet* 2020; 395: 507-513.
4. Jones KE, Patel NG, Levy MA, et al. Global trends in emerging infectious diseases. *Nature* 2008; 451: 990-993.
5. Woolhouse ME, Haydon DT, Antia R. Emerging pathogens: the epidemiology and evolution of species jumps. *Trends Ecol Evol* 2005; 20: 238-244.
6. Alizon S, Hurford A, Mideo N, et al. Virulence evolution and the trade-off hypothesis: history, current state of affairs and the future. *J Evol Biol* 2009; 22: 245-259.
7. Pan Y, Guan H. Imaging changes in patients with 2019-nCoV. *Eur Radiol* 2020; 30: 3612-3613.
8. Huang C, Wang Y, Li X, et al. Clinical features of patients infected with 2019 novel coronavirus in Wuhan, China. *Lancet* 2020; 395: 497-506.
9. Chen G, Wu D, Guo W, et al. Clinical and immunologic features in severe and moderate forms of Coronavirus Disease 2019. *J Clin Invest* 2020; 130: 2620-2629.
10. Yang W, Cao Q, Qin L, et al. Clinical characteristics and imaging manifestations of the 2019 novel coronavirus disease (COVID-19): a multi-center study in Wenzhou city, Zhejiang, China. *J Infect* 2020; 80: 388-393.
11. Xu Y-H, Dong J-H, An W-M, et al. Clinical and computed tomographic imaging features of novel coronavirus pneumonia caused by SARS-CoV-2. *J Infect* 2020; 80: 394-400.
12. Shi H, Han X, Jiang N, et al. Radiological findings from 81 patients with COVID-19 pneumonia in Wuhan, China: a descriptive study. *Lancet Infect Dis* 2020; 20: 425-434.
13. Wang D, Hu B, Hu C, et al. Clinical characteristics of 138 hospitalized patients with 2019 novel coronavirus-infected pneumonia in Wuhan, China. *Jama* 2020; 323: 1061-1069.
14. Pan Y, Guan H, Zhou S, et al. Initial CT findings and temporal changes in patients with the novel coronavirus pneumonia (2019-nCoV): a study of 63 patients in Wuhan, China. *Eur Radiol* 2020; 30: 3306-3309.
15. Xu X-W, Wu X-X, Jiang X-G, et al. Clinical findings in a group of patients infected with the 2019 novel coronavirus (SARS-Cov-2) outside of Wuhan, China: retrospective case series. *BMJ* 2020; 368: m792.
16. Li Y, Xia L. Coronavirus Disease 2019 (COVID-19): role of chest CT in diagnosis and management. *AJR Am J Roentgenol* 2020; 214: 1-7.
17. Zhou S, Wang Y, Zhu T, et al. CT features of coronavirus disease 2019 (COVID-19) pneumonia in 62 patients in Wuhan, China. *AJR Am J Roentgenol* 2020; 214: 1287-1294.
18. Zhao W, Zhong Z, Xie X, et al. Relation between chest CT findings and clinical conditions of coronavirus disease (COVID-19) pneumonia: a multicenter study. *AJR Am J Roentgenol* 2020; 214: 1072-1077.
19. Guan W-j, Ni Z-y, Hu Y, et al. Clinical characteristics of 2019 novel coronavirus infection in China. *N Engl J Med* 2020; 382: 1708-1720.
20. Ai J-W, Zhang H-C, Xu T, et al. Optimizing diagnostic strategy for novel coronavirus pneumonia, a multi-center study in Eastern China. Available from: <https://www.medrxiv.org/content/10.1101/2020.02.13.20022673v1>.
21. Feng Z, Yu Q, Yao S, et al. Early prediction of disease progression in 2019 novel coronavirus pneumonia patients outside wuhan with CT and clinical characteristics. Available from: <https://www.medrxiv.org/content/10.1101/2020.02.19.20025296v1>.
22. Yuan M, Yin W, Tao Z, et al. Association of radiologic findings with mortality of patients infected with 2019 novel coronavirus in Wuhan, China. *Plus One* 2020; 15: e0230548.
23. Qian G-Q, Yang N-B, Ding F, et al. Epidemiologic and clinical characteristics of 91 hospitalized patients with COVID-19 in Zhejiang, China: a retrospective, multi-centre case series. *QJM* 2020; 113: 474-481.
24. Cao W. Clinical features and laboratory inspection of novel coronavirus pneumonia (COVID-19) in Xiangyang, Hubei. Available from: <https://www.medrxiv.org/content/10.1101/2020.02.23.20026963v1>.
25. Liang Y, Liang J, Zhou Q, et al. Prevalence and clinical features of 2019 novel coronavirus disease (COVID-19) in the Fever Clinic of a teaching hospital in Beijing: a single-center, retrospective study. Available from: <https://www.medrxiv.org/content/10.1101/2020.02.25.20027763v2>.
26. Huang Y, Zhou H, Yang R, et al. Clinical characteristics of 36 non-survivors with COVID-19 in Wuhan, China. Available from: <https://www.medrxiv.org/content/10.1101/2020.02.27.20029009v2>.
27. Wu J, Wu X, Zeng W, et al. Chest CT findings in patients with coronavirus disease 2019 and its relationship with clinical features. *Invest Radiol* 2020; 55: 257-261.
28. Kui L, Fang Y-Y, Deng Y, et al. Clinical characteristics of novel coronavirus cases in tertiary hospitals in Hubei Province. *Chin Med J* 2020; 133: 1025-1031.
29. Chung M, Bernheim A, Mei X, et al. CT imaging features of 2019 novel coronavirus (2019-nCoV). *Radiology* 2020; 295: 202-207.
30. Song F, Shi N, Shan F, et al. Emerging 2019 novel coronavirus (2019-nCoV) pneumonia. *Radiology* 2020; 295: 210-217.
31. Bernheim A, Mei X, Huang M, et al. Chest CT findings in coronavirus disease-19 (COVID-19): relationship to duration of infection. *Radiology* 2020; 295.
32. Xu Z, Wu W, Jin Y, et al. Key points of clinical and CT imaging features of 2019 novel coronavirus (2019-ncov) imported pneumonia based on 21 cases analysis. Available from: <https://www.medrxiv.org/content/10.1101/2020.03.03.20030775v1>.
33. Li K, Wu J, Wu F, et al. The clinical and chest CT features associated with severe and critical COVID-19 pneumonia. *Invest Radiol* 2020; 55: 327-331.
34. Zhang J-J, Dong X, Cao Y-Y, et al. Clinical characteristics of 140 patients infected with SARS-CoV-2 in Wuhan, China. *Allergy* 2020; 75: 1730-1741.
35. Liu W, Wang F, Li G, et al. Analysis of 2019-nCoV infection and clinical manifestations of outpatients: an epidemiological study from the fever clinic in Wuhan, China. 2020.

36. Hu Z, Song C, Xu C, et al. Clinical characteristics of 24 asymptomatic infections with COVID-19 screened among close contacts in Nanjing, China. *Sci China Life Sci* 2020; 63: 706-711.
37. Fu H, Li H, Tang X, et al. Analysis on the clinical characteristics of 36 cases of novel coronavirus pneumonia in Kunming. Available from: <https://www.medrxiv.org/content/10.1101/2020.02.28.20029173v1>.
38. Li J, Li S, Cai Y, et al. Epidemiological and clinical characteristics of 17 hospitalized patients with 2019 novel coronavirus infections outside Wuhan, China. Available from: <https://www.medrxiv.org/content/10.1101/2020.02.11.20022053v1>.
39. Cai Q, Huang D, Ou P, et al. COVID-19 in a designated infectious diseases hospital outside Hubei Province, China. *Allergy* 2020; 75: 1742-1752.
40. Jian-ya G. Clinical characteristics of 51 patients discharged from hospital with COVID-19 in Chongqing, China. Available from: <https://www.medrxiv.org/content/10.1101/2020.02.20.20025536v1>.
41. Cui P, Chen Z, Wang T, et al. Clinical features and sexual transmission potential of SARS-CoV-2 infected female patients: a descriptive study in Wuhan, China. Available from: <https://www.medrxiv.org/content/10.1101/2020.02.26.20028225v2>.
42. Cao M, Zhang D, Wang Y, et al. Clinical features of patients infected with the 2019 novel coronavirus (COVID-19) in Shanghai, China. Available from: <https://www.medrxiv.org/content/10.1101/2020.03.04.20030395v1>.
43. Xu Y, Li Y-r, Zeng Q, et al. Clinical characteristics of SARS-CoV-2 pneumonia compared to controls in Chinese Han population. Available from: <https://www.medrxiv.org/content/10.1101/2020.03.08.20031658v1>.
44. Chen J, Fan H, Zhang L, et al. Retrospective analysis of clinical features in 101 death cases with COVID-19. Available from: <https://www.medrxiv.org/content/10.1101/2020.03.09.20033068v2>.
45. Liu J, Ouyang L, Guo P, et al. Epidemiological, clinical characteristics and outcome of medical staff infected with COVID-19 in Wuhan, China: a retrospective case series analysis. Available from: <https://www.medrxiv.org/content/10.1101/2020.03.09.20033118v1>.
46. Lei Y, Lan Y, Lu J, et al. Clinical features of imported cases of coronavirus disease 2019 in Tibetan patients in the Plateau area. Available from: <https://www.medrxiv.org/content/10.1101/2020.03.09.20033126v1>.
47. Sayehmiri K, Tavan H, Sayehmire F, et al. Prevalence of epilepsy in Iran using meta-analysis and systematic review. *J Adv Med Biomed Res* 2015; 23: 112-121.
48. Sayehmiri K, Tavan H. Systematic review and meta-analysis methods prevalence of peptic ulcer in IRAN. *Govaresh* 2016; 20: 250-258.
49. Stroup DF, Berlin JA, Morton SC, et al. Meta-analysis of observational studies in epidemiology: a proposal for reporting. *Jama* 2000; 283: 2008-2012.
50. Moher D, Shamseer L, Clarke M, et al. Preferred reporting items for systematic review and meta-analysis protocols (PRISMA-P) 2015 statement. *Syst Rev* 2015; 4: 1.
51. Peterson J, Welch V, Losos M, et al. The Newcastle-Ottawa scale (NOS) for assessing the quality of nonrandomised studies in meta-analyses. Available from: http://www.ohri.ca/programs/clinical_epidemiology/oxford.asp.
52. Higgins JP, Green S. *Cochrane handbook for systematic reviews of interventions*. John Wiley & Sons, New Jersey 2011.
53. Higgins JP, Thompson SG, Deeks JJ, et al. Measuring inconsistency in meta-analyses. *BMJ* 2003; 327: 557-560.
54. Xie X, Zhong Z, Zhao W, et al. Chest CT for typical 2019-nCoV pneumonia: relationship to negative RT-PCR testing. *Radiology* 2020; 296: E41-E45.
55. National Health Commission of the People's Republic of China. China's Hubei reports jump in new cases of COVID-19 after diagnosis criteria revision. Available from: http://en.nhc.gov.cn/2020-02/13/c_76515.htm.
56. Koo HJ, Lim S, Choe J, et al. Radiographic and CT features of viral pneumonia. *Radiographics* 2018; 38: 719-739.
57. Ooi GC, Khong PL, Müller NL, et al. Severe acute respiratory syndrome: temporal lung changes at thin-section CT in 30 patients. *Radiology* 2004; 230: 836-844.
58. Wang Q, Zhang Z, Shi Y, et al. Emerging H7N9 influenza A (novel reassortant avian-origin) pneumonia: radiologic findings. *Radiology* 2013; 268: 882-889.
59. Yuan Y, Tao XF, Shi YX, et al. Initial HRCT findings of novel influenza A (H1N1) infection. *Influenza and other respiratory viruses*. *Influenza Other Respir Viruses* 2012; 6: e114-e119.
60. Wong K-t, Antonio GE, Hui DS, et al. Severe acute respiratory syndrome: thin-section computed tomography features, temporal changes, and clinicoradiologic correlation during the convalescent period. *J Comput Assist Tomogr* 2004; 28: 790-795.
61. Qureshi NR, Hien TT, Farrar J, et al. The radiologic manifestations of H5N1 avian influenza. *Journal of thoracic imaging*. *J Thorac Imaging*; 2006; 21: 259-264.
62. Paul NS, Roberts H, Butany J, et al. Radiologic pattern of disease in patients with severe acute respiratory syndrome: the Toronto experience. *Radiographics* 2004; 24: 553-563.
63. Das KM, Lee EY, Langer RD, et al. Middle east respiratory syndrome coronavirus: what does a radiologist need to know? *AJR Am J Roentgenol* 2016; 206: 1193-1201.
64. Xu X, Chen P, Wang J, et al. Evolution of the novel coronavirus from the ongoing Wuhan outbreak and modeling of its spike protein for risk of human transmission. *Sci China Life Sci* 2020; 63: 457-460.
65. Zhou P, Yang X-L, Wang X-G, et al. A pneumonia outbreak associated with a new coronavirus of probable bat origin. *Nature* 2020; 579: 270-273.
66. Müller NL, Ooi GC, Khong PL, et al. Severe acute respiratory syndrome: radiographic and CT findings. *AJR Am J Roentgenol* 2003; 181: 3-8.
67. Müller NL, Ooi GC, Khong PL, et al. High-resolution CT findings of severe acute respiratory syndrome at presentation and after admission. *AJR Am J Roentgenol* 2004; 182: 39-44.