

Correspondence



Pazopanib as a second line treatment for uterine and ovarian carcinosarcoma: a single institutional study

Tadaaki Nishikawa,¹ Kosei Hasegawa,¹ Akira Yabuno,¹ Hiroyuki Yoshida,¹ Masanori Yasuda,² Eito Kozawa,³ Keiichi Fujiwara¹

¹Department of Gynecologic Oncology, Saitama Medical University International Medical Center, Saitama, Japan

²Department of Pathology, Saitama Medical University International Medical Center, Saitama, Japan

³Department of Diagnostic Radiology, Saitama Medical University International Medical Center, Saitama, Japan

OPEN ACCESS

Received: Sep 9, 2016

Revised: Oct 20, 2016

Accepted: Dec 1, 2016

Correspondence to

Kosei Hasegawa

Department of Gynecologic Oncology,
Saitama Medical University International
Medical Center, 1397-1 Yamane, Hidaka,
Saitama 350-1298, Japan.

E-mail: koseih@saitama-med.ac.jp

Copyright © 2017. Asian Society of
Gynecologic Oncology, Korean Society of
Gynecologic Oncology

This is an Open Access article distributed
under the terms of the Creative Commons
Attribution Non-Commercial License (<http://creativecommons.org/licenses/by-nc/4.0/>)
which permits unrestricted non-commercial
use, distribution, and reproduction in any
medium, provided the original work is properly
cited.

ORCID

Tadaaki Nishikawa

<http://orcid.org/0000-0003-2606-4208>

Kosei Hasegawa

<http://orcid.org/0000-0002-1903-7001>

Akira Yabuno

<http://orcid.org/0000-0002-1221-0609>

Hiroyuki Yoshida

<http://orcid.org/0000-0002-0618-3800>

Masanori Yasuda

<http://orcid.org/0000-0002-0769-360X>

Eito Kozawa

<http://orcid.org/0000-0002-4260-4668>

Uterine carcinosarcoma (UCS) is a relatively rare tumor in gynecologic malignancy that comprises less than 5% of uterine cancers, but it often shows an aggressive phenotype that has contributed to 30% of uterine cancer deaths [1]. Ovarian carcinosarcoma (OCS) is a very rare ovarian tumor that accounts for only 1% of ovarian cancer, and is composed of both malignant epithelial and mesenchymal elements, as well as UCS [1,2]. Prognosis of UCS and OCS is poor because up to 2/3 of patients present with advanced stage [2,3]. Currently, prognostic factors of carcinosarcoma (CS) are not well defined, but published reports have suggested pathological features and age as prognostic factors [4-6]. Previously, gynecological CS had been considered and treated as a sarcoma subtype [7]. However, CS is now recognized as a metaplastic carcinoma with the sarcoma component resulting from dedifferentiation of the carcinoma component [8], and therefore it is recommended that CS is treated similar to high-risk endometrial or ovarian carcinoma [9]. While combination chemotherapy of ifosfamide and paclitaxel is currently considered as a standard chemotherapy for UCS [10], an alternative combination is carboplatin and paclitaxel. The efficacy of combination carboplatin and paclitaxel has been reported in several phase II trials, and this combination appears to be better tolerated [11,12]. Based on these results, the combination of carboplatin plus paclitaxel is often used as a standard first line treatment for UCS or OCS, but second line treatment options are limited.

Pazopanib is a multi-target tyrosine kinase inhibitor of Vascular Endothelial Growth Factor Receptor (VEGFR), Platelet-Derived Growth Factor Receptor (PDGFR), and c-KIT, that is currently widely used for soft-tissue sarcoma treatment. The pazopanib for metastatic soft-tissue sarcoma (PALETTE) study is a phase III clinical trial for metastatic soft-tissue sarcoma including uterine sarcoma [13], which has demonstrated improved survival in pazopanib treated patients. However, the efficacy of pazopanib for CS could not be determined as CS was excluded. Recently, Gynecologic Oncology Group (GOG)-230D, a phase II trial of pazopanib for recurrent or persistent UCS, reported that the response rate of pazopanib for UCS was 0% (0/19) and the median progression free survival (PFS) and overall survival (OS) were only 2.0 and 8.7 months, respectively [14]. For this reason, GOG did not move forward to perform a phase III trial of pazopanib for UCS. However, as there were three (15.8%) patients in that trial who had a PFS that was longer than 6 months, the role of anti-angiogenesis inhibitors in UCS was inconclusive. Now we have had UCS and OCS patients

Keiichi Fujiwara
<http://orcid.org/0000-0002-7388-0243>

Conflict of Interest

No potential conflict of interest relevant to this article was reported.

who were responsive to pazopanib as a second or third line chemotherapy. To our knowledge, this is the first report of a positive clinical response of UCS and OCS patients with pazopanib.

Data from 8 patients in whom pazopanib was administered for advanced or recurrent UCS or OCS in the Saitama Medical University International Medical Center between December 2012 and December 2015 was retrospectively reviewed. Measurable disease from computed tomography (CT) scan images was defined by the Response Evaluation Criteria in Solid Tumors version 1.1 (RECIST v1.1). Toxicity was graded using the National Cancer Institute Common Toxicity Criteria version 4.0 (CTCAE v4).

Patient characteristics and clinical courses are shown in **Table 1**. The median age was 65.5 (range: 51–75). All patients were Asians. Pazopanib was initiated to treat progressive disease in 4 (50%) patients, recurrent disease in 2 (25%) patients, and persistent disease in 2 (25%) patients as a second line or further therapy.

The median of pazopanib administration period was 84.5 days (range: 23–330). Six patients were followed for a median of 6.5 months (range: 1.7–12.4) after initiation of pazopanib therapy. **Fig. 1** shows contrast-enhanced CT images of case 6 and 7 before (**Fig. 1A and 1C**) and after (**Fig. 1B and 1D**) pazopanib treatment, all of which indicating partial response (PR). The clinical benefit rate (PR and stable disease [SD]) was 50% (4/8). Disease control rate, indicated by more than 12 weeks of SD, was 50% (4/8). Seven patients could be evaluated for PFS while one case was excluded for PFS evaluation as pazopanib was discontinued due to toxicity and surgical complete resection (case 1) was performed. The median PFS was 2.8 months, ranging from 0.8 to 11 months. Treatment was discontinued for different reasons, PD in 6 (75%), liver dysfunction in one (13%), and hypothyroidism in 1 (13%). At the time of last follow-up, the median OS since pazopanib initiation was 6.5 months, ranging from 1.7 to 12.4 months, excluding one missing patient (case 2) and the patient (case 1) who underwent operation. Six patients died from disease progression with pazopanib as the last treatment.

Table 1. Patients characteristics, summary of the clinical courses, adverse events

Case	Age (yr)	PS	FIGO stage	Primary site	Sites of metastases	Prior chemotherapy (regimens)	Medicine (day)	Response	PFS (mo)	OS (mo)	Adverse events (medicine days)	Grade	Course	
1	62	0	IIIC2	Uterus	Lung	2	85	SD	(35.7)	(35.7)	NED	Hypothyroidism (23, 76, 85)	G1	Interruption DR discontinuance
2	63	0	IIIA	Uterus	Dissemination	5	23	PD	0.8	Unknown	Unknown	Thrombocytopenia (23) Liver dysfunction (23)	G3	Interruption Discontinuance/PD
3	72	0	IB	Uterus	Lung	2	24	PD	0.8	1.7	DOD	-	-	-
4	67	0	IIIC1	Uterus	Lung/LNs	2	84	PD	2.8	6.6	DOD	Liver dysfunction (78)	G3	Interruption
5	75	0	IVB	Uterus	Lung/LNs dissemination	1	46	PD	1.5	2.1	DOD	-	-	-
6	66	1	IVB	Uterus	Dissemination	1	209	PR	7.0	7.9	DOD	Thrombocytopenia (65)	G3	Interruption/DR
7	51	2	IIIC	Ovary	LN dissemination	2	149	PR	5.0	6.3	DOD	Diarrhea (76)	G3	Interruption
8	65	0	IIIC	Ovary	Lung/LNs dissemination	1	330	SD	11.0	12.4	DOD	-	-	-

Case 1: pazopanib was discontinued due to toxicity and complete resection by video-assisted thoracic surgery was performed after discontinuance on this patient.

DOD, dead of disease; DR, dose reduction; FIGO, International Federation of Gynecology and Obstetrics; LN, lymph node; NED, no evidence of disease; OS, overall survival; PD, progression disease; PFS, progression free survival; PR, partial response; PS, performance status; SD, stable disease.

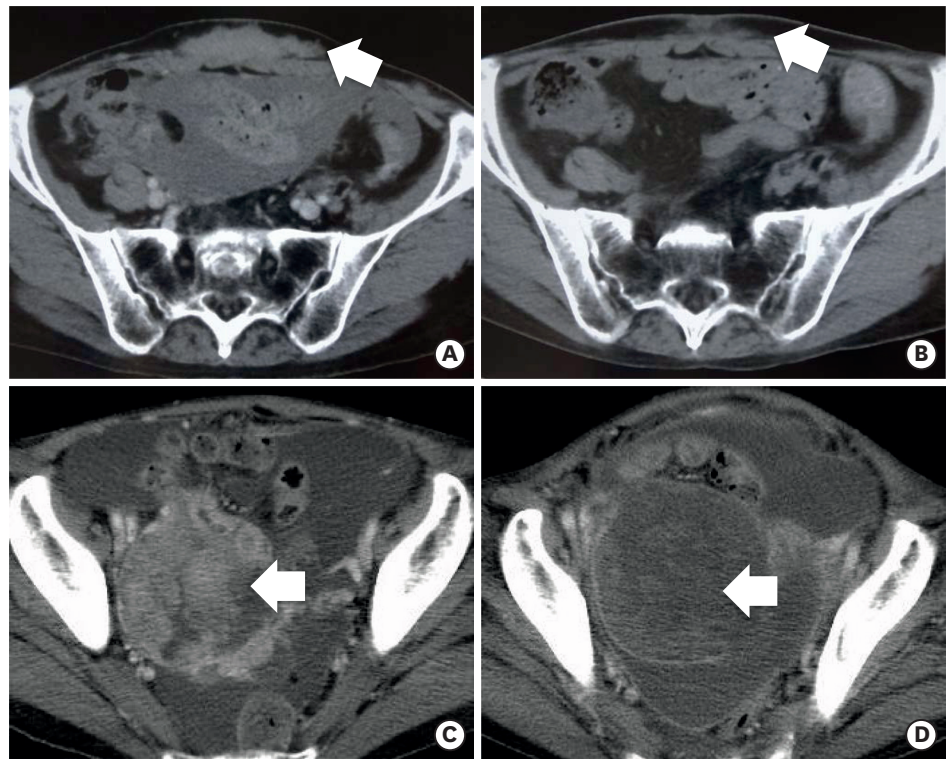


Fig. 1. Contrast-enhanced CT images showing pre (A, C) and post (B, D) pazopanib treatment. White arrows indicate target lesions. (A, B) Case 6: CS of the uterus, reduction of abdominal tumors and malignant ascites were observed after 51 days of pazopanib oral intake. (C, D) Case 7: CS of the ovary, reduction of the solid components of ovarian tumor and malignant ascites were observed after 40 days of pazopanib oral intake. CS, carcinosarcoma; CT, computed tomography.

Pazopanib was started at 800 mg/day in all patients. **Table 1** summarizes the adverse events which necessitated interruption, dose reduction or discontinuance of pazopanib. Two (25%) had pazopanib dose reduced to 600 mg/day due to toxicity. Two (25%) patients discontinued pazopanib administration due to toxicity, and 1 of them (case 2) concurrently had PD. Six (75%) patients discontinued pazopanib administration due to PD. For drug related adverse events, hypothyroidism and elevated thyroid stimulating hormone levels were observed, which was unusual with cytotoxic chemotherapy. Pazopanib treatment was discontinued in case 1 for this reason. Hypertension, urinary protein, and erythema multiforme, which are commonly seen with molecular target therapy, were also observed.

This is the first clinical report showing the clinical response of pazopanib for UCS and OCS. We observed a 25% (2/8) and 50% (4/8) response and clinical benefit rate, respectively. Three (38%) patients with PR and SD continued pazopanib more than 140 days. Unfortunately, the clinical efficacy of pazopanib for CS was undetermined as uterine and ovarian CS patients were excluded in the PALETTE study. Based on c-KIT or PDGFR expression in the sarcoma and carcinoma components of UCS, pazopanib was suggested in UCS treatment [15] although tyrosine kinase inhibitors in general have minimal activity in UCS patients [16,17].

National Comprehensive Cancer Network (NCCN) guideline recommends a combination chemotherapy of ifosfamide and paclitaxel for recurrent and metastatic CS. In addition, alternative combination chemotherapy of paclitaxel and carboplatin is also considered useful to circumvent ifosfamide toxicity [9]. However, existing chemotherapy for CS shows limited

efficacy, with no promising therapy after first-line chemotherapy failure. Therefore, novel approaches are needed to overcome this unmet medical need.

Molecular targeted therapy could be a potential candidate for these situations. Compared to the disappointing results of GOG-230D study, which demonstrated minimal clinical activity with no objective responses and only 15.8% of patients were progression free at 6 months [14], our current study reports 8 cases of recurrent or persistent UCS or OCS, with 25% (2/8) and 50% (4/8) response and clinical benefit rate observed, respectively. Our data suggests that pazopanib might have clinical benefit as a second line treatment in UCS and OCS. The reason for the apparent better clinical activity of pazopanib in our study compared to the cases from the GOG-230D trial is unknown. The extremely disparate clinical background (e.g., race, histology, etc.) of patients in both studies may be a contributing factor and the efficacy of pazopanib needs to be evaluated carefully.

A good example of such trial is the Arbeitsgemeinschaft Gynaekologische Onkologie Studiengruppe Ovarialkarzinom (AGO-OVAR) 16 trial, which is a randomized, double-blind, phase III clinical trial of pazopanib vs. placebo in women who have not progressed after first-line chemotherapy for advanced epithelial ovarian, fallopian tube, and primary peritoneal cancer (AEOC) [18]. This study evaluated the efficacy, safety, and tolerability of pazopanib maintenance therapy for AEOC, and reported a median improvement of 5.6 months (hazard ratio [HR], 0.77) in PFS in AEOC. Of note, this improvement of PFS was absent in a subset of east asian patients [19], which reinforces the importance of race and ethnicity considerations for the evaluation of pazopanib and possibly other drugs.

Our clinical experience in this article suggests that it will be worthwhile to re-test pazopanib prospectively in an asian population and possibly a caucasian population. However, since both UCS and OCS are rare tumors, it may be difficult to conduct prospective studies as a single institution or country. As stated in the consensus review [3], molecular profiling for each patient in addition to ethnical factors is also important. Due to frequent exclusion from clinical trials, it is important to build an international consensus on an efficient development strategy of an effective treatment for CS.

ACKNOWLEDGMENTS

The authors thank all the patients and their families. We also thank Drs. A. Kurosaki, Y. Imai, A. Miyasaka, and S. Sato for their support during our study.

REFERENCES

1. Cantrell LA, Van Le L. Carcinosarcoma of the ovary a review. *Obstet Gynecol Surv* 2009;64:673-80.
[PUBMED](#) | [CROSSREF](#)
2. Pacaut C, Bourmaud A, Rivoirard R, Moriceau G, Guy JB, Collard O, et al. Uterine and ovary carcinosarcomas: outcome, prognosis factors, and adjuvant therapy. *Am J Clin Oncol* 2015;38:272-7.
[PUBMED](#) | [CROSSREF](#)
3. Berton-Rigaud D, Devouassoux-Shisheboran M, Ledermann JA, Leitao MM, Powell MA, Poveda A, et al. Gynecologic Cancer InterGroup (GCIG) consensus review for uterine and ovarian carcinosarcoma. *Int J Gynecol Cancer* 2014;24:S55-60.
[PUBMED](#) | [CROSSREF](#)

4. Harano K, Hirakawa A, Yunokawa M, Nakamura T, Satoh T, Nishikawa T, et al. Prognostic factors in patients with uterine carcinosarcoma: a multi-institutional retrospective study from the Japanese Gynecologic Oncology Group. *Int J Clin Oncol* 2016;21:168-76.
[PUBMED](#) | [CROSSREF](#)
5. Galaal K, Kew FM, Tam KF, Lopes A, Meirovitz M, Naik R, et al. Evaluation of prognostic factors and treatment outcomes in uterine carcinosarcoma. *Eur J Obstet Gynecol Reprod Biol* 2009;143:88-92.
[PUBMED](#) | [CROSSREF](#)
6. Gokce ZK, Turan T, Karalok A, Tasci T, Ureyen I, Ozkaya E, et al. Clinical outcomes of uterine carcinosarcoma: results of 94 patients. *Int J Gynecol Cancer* 2015;25:279-87.
[PUBMED](#) | [CROSSREF](#)
7. Shah SH, Jagannathan JP, Krajewski K, O'Regan KN, George S, Ramaiya NH. Uterine sarcomas: then and now. *AJR Am J Roentgenol* 2012;199:213-23.
[PUBMED](#) | [CROSSREF](#)
8. Wada H, Enomoto T, Fujita M, Yoshino K, Nakashima R, Kurachi H, et al. Molecular evidence that most but not all carcinosarcomas of the uterus are combination tumors. *Cancer Res* 1997;57:5379-85.
[PUBMED](#)
9. National Comprehensive Cancer Network (US). NCCN clinical practice guidelines in oncology (NCCN Guidelines®): uterine neoplasms version 2. 2016 [Internet]. Fort Washington (PA): National Comprehensive Cancer Network; 2016 [cited 2016 Sep 1]. Available from: https://www.nccn.org/professionals/physician_gls/f_guidelines.asp#uterine.
10. Homesley HD, Filiaci V, Markman M, Bitterman P, Eaton L, Kilgore LC, et al. Phase III trial of ifosfamide with or without paclitaxel in advanced uterine carcinosarcoma: a Gynecologic Oncology Group Study. *J Clin Oncol* 2007;25:526-31.
[PUBMED](#) | [CROSSREF](#)
11. Powell MA, Filiaci VL, Rose PG, Mannel RS, Hanjani P, Degeest K, et al. Phase II evaluation of paclitaxel and carboplatin in the treatment of carcinosarcoma of the uterus: a Gynecologic Oncology Group study. *J Clin Oncol* 2010;28:2727-31.
[PUBMED](#) | [CROSSREF](#)
12. Hoskins PJ, Le N, Ellard S, Lee U, Martin LA, Swenerton KD, et al. Carboplatin plus paclitaxel for advanced or recurrent uterine malignant mixed mullerian tumors. The British Columbia Cancer Agency experience. *Gynecol Oncol* 2008;108:58-62.
[PUBMED](#) | [CROSSREF](#)
13. van der Graaf WT, Blay JY, Chawla SP, Kim DW, Bui-Nguyen B, Casali PG, et al. Pazopanib for metastatic soft-tissue sarcoma (PALETTE): a randomised, double-blind, placebo-controlled phase 3 trial. *Lancet* 2012;379:1879-86.
[PUBMED](#) | [CROSSREF](#)
14. Campos SM, Brady WE, Moxley KM, O'Ceirbhail RE, Lee PS, DiSilvestro PA, et al. A phase II evaluation of pazopanib in the treatment of recurrent or persistent carcinosarcoma of the uterus: a gynecologic oncology group study. *Gynecol Oncol* 2014;133:537-41.
[PUBMED](#) | [CROSSREF](#)
15. Huh WK, Sill MW, Darcy KM, Elias KM, Hoffman JS, Boggess JF, et al. Efficacy and safety of imatinib mesylate (Gleevec) and immunohistochemical expression of c-Kit and PDGFR-beta in a Gynecologic Oncology Group Phase II Trial in women with recurrent or persistent carcinosarcomas of the uterus. *Gynecol Oncol* 2010;117:248-54.
[PUBMED](#) | [CROSSREF](#)
16. Menczer J. Review of recommended treatment of uterine carcinosarcoma. *Curr Treat Options Oncol* 2015;16:53.
[PUBMED](#) | [CROSSREF](#)
17. Cantrell LA, Blank SV, Duska LR. Uterine carcinosarcoma: a review of the literature. *Gynecol Oncol* 2015;137:581-8.
[PUBMED](#) | [CROSSREF](#)
18. du Bois A, Floquet A, Kim JW, Rau J, del Campo JM, Friedlander M, et al. Incorporation of pazopanib in maintenance therapy of ovarian cancer. *J Clin Oncol* 2014;32:3374-82.
[PUBMED](#) | [CROSSREF](#)
19. Kim JW, Mahner S, Wu LY, Shoji T, Kim BG, Zhu JQ, et al. Pazopanib maintenance therapy in East Asian women with advanced epithelial ovarian cancer: results from AGO-OVAR16 and an East Asian Study. *Int J Gynecol Cancer*. Forthcoming 2015.
[PUBMED](#) | [CROSSREF](#)