



OPEN ACCESS

## CASE REPORT

# Symmetrical peripheral gangrene of bilateral feet and unilateral hand after administration of vasopressors during septic shock

Naeemah Ruffin,<sup>1</sup> Chirag V Vasa,<sup>2</sup> Sarah Breakstone,<sup>3</sup> Wayne Axman<sup>4</sup>

<sup>1</sup>Orthopedics, Division of Podiatry, Icahn School of Medicine at Mount Sinai, New York, USA

<sup>2</sup>Infectious Diseases, Mount Sinai Queens Hospital, Astoria, New York, USA

<sup>3</sup>Orthopedics, Division of Podiatry, Icahn School of Medicine at Mount Sinai, New York, USA

<sup>4</sup>Orthopedics, Division of Podiatry, Mount Sinai Queens Hospital, Astoria, New York, USA

## Correspondence to

Dr Naeemah Ruffin,  
naeemahruffin@yahoo.com

Accepted 23 January 2018

## SUMMARY

We report a case of a 75-year-old Hispanic man treated for septic shock after undergoing surgery for impacted renal stones. He was given vasopressors and later developed symmetrical peripheral gangrene (SPG) on both his feet and left hand. SPG is a serious and rare condition presenting clinically as an acute onset of ischaemia with no vessel occlusion. Vasopressors are identified as a contributing factor in SPG development. The patient ultimately underwent transmetatarsal amputations of both feet and amputation of three digits on his left hand. Early monitoring and swift management of peripheral ischaemia are essential when using vasopressors for the treatment of septic shock.

## BACKGROUND

Symmetrical peripheral gangrene (SPG), also known as purpura fulminans, is an uncommon condition where symmetric ischaemia of the digital extremities occurs without arterial vessel obstruction, increasing the risk of limb amputation and impacting quality of life.<sup>1 2</sup> The aetiology of the condition is multifactorial but has been linked to the use of vasopressors during treatment of septic shock. There is consensus in the literature that recognising SPG early, along with the underlying conditions, can significantly change how the condition is managed and the final result.<sup>3</sup>

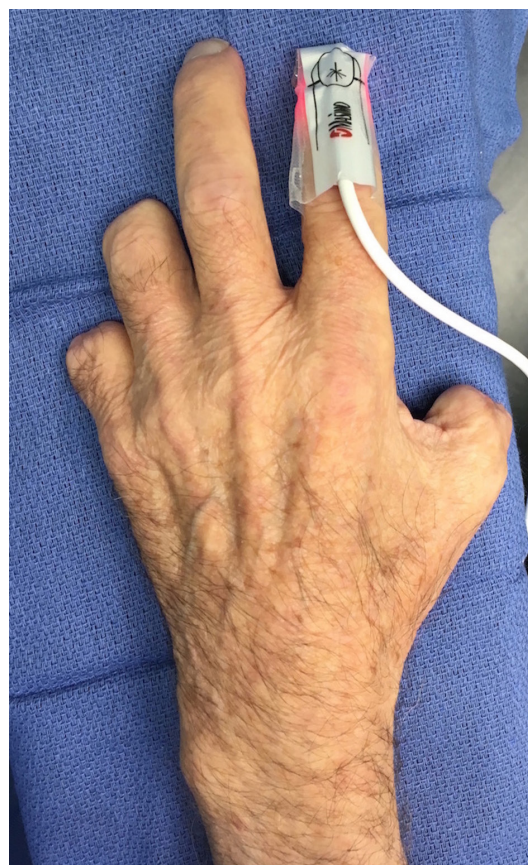Our patient was treated for septic shock after emergency ureteral stent placement surgery. After administering fluid resuscitation, vasopressors and antibiotics, the patient developed gangrene of both feet and his left hand with an unusual sparing of his right hand. He eventually underwent transmetatarsal amputations of both feet and amputation of three digits of his left hand. Our aim is to bring further attention to this rare condition to raise the level of clinical suspicion and improve its management.

## CASE PRESENTATION

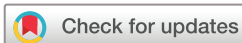We describe a 75-year-old Hispanic man with a medical history of hypertension, hyperlipidaemia and nephrolithiasis presenting to the emergency department (ED) with right flank pain for 2 days and dysuria and frequency for 1 week. In the ED the patient was given antibiotics and fluids. Within 12 hours the patient underwent emergency ureteral stent placement for impacted renal stones. During

surgery the patient developed acute respiratory distress syndrome with severe hypoxaemia and was transferred to the intensive care unit for treatment of urosepsis. The patient was intubated, given antibiotics and intravenous fluids (IVF), and started on vasopressors to support systolic blood pressure and mean arterial pressure goals. Dopamine 2 µg/kg/min (max 20 µg/kg/min) and norepinephrine 1 µg/min (max 30 µg/min) were initiated. Several hours later the patient was started on vasopressin 2.4 units/hour infusion and the patient's lactate was 5.35 the same day.

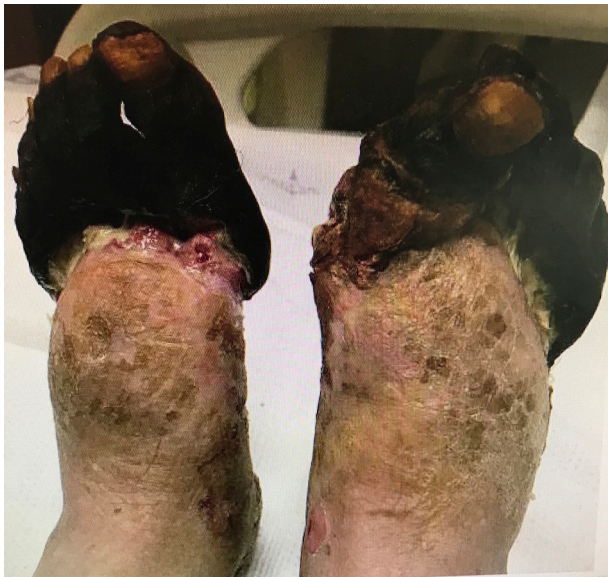The following day the patient's blood pressure began to improve, all vasopressors were tapered, and IVF was continued. The patient was continued on broad-spectrum antibiotics, although all cultures have been negative since admission. Two



**Figure 1** The left hand after amputation of digits 1, 4 and 5.



**To cite:** Ruffin N, Vasa CV, Breakstone S, et al. *BMJ Case Rep* Published Online First: [please include Day Month Year]. doi:10.1136/bcr-2017-223602



**Figure 2** Demarcated gangrene on the dorsal aspect of both feet.

days after vasopressor administration, a bluish discoloration was noted on the patient's upper and lower extremities, capillary refill was more than 3 s, radial and dorsalis pedis pulses were dopplerable, and the skin was intact and cool to touch. Dopamine was discontinued 2 days after administration. Three days later the patient developed gangrenous changes to his left hand and bilateral feet and was given intravenous argatroban 1.5 µg /kg/min. The patient was also dialysed throughout his stay to correct his acidosis. On day 9 since admission, the

patient's feet and hands contained fluid-filled bullae with gangrenous changes.

#### TREATMENT

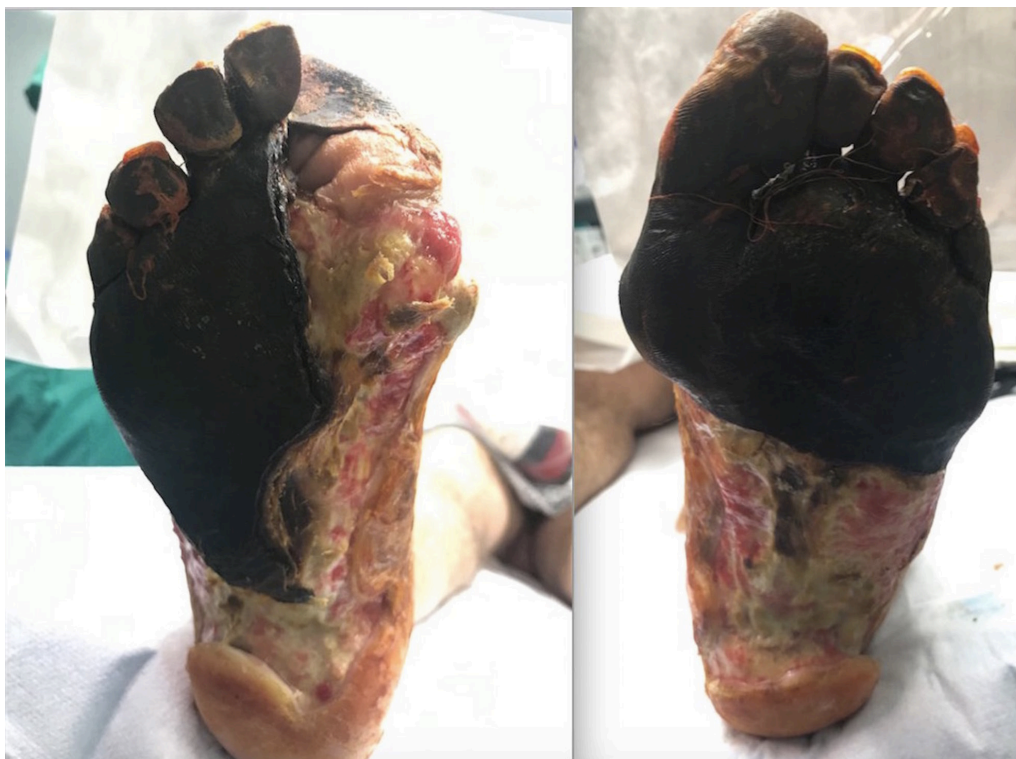Surgery was not initially recommended on noticing gangrenous changes in the patient's hand and feet. The patient was discharged to a nursing home with periodic local wound care and monitoring for gangrene demarcation.

Over the next several months, the patient underwent multiple hospital admissions. He was admitted for necrosis of both feet with left heel cellulitis and was treated with intravenous antibiotics and discharged 6 days later. Five months later the patient's left hand digits 1, 4 and 5 were fully demarcated with dry gangrene, and all three digits were amputated (figure 1). The patient was also treated for soft tissue infections of his feet and was given intravenous antibiotics for 6 weeks to cover positive cultures of Methicillin-resistant *Staphylococcus aureus* and *Pseudomonas*. After 4 months the patient returned to the hospital with dry, demarcated gangrene of both forefeet (figure 2) and plantar mid-feet (figure 3) and underwent bilateral transmetatarsal amputations (figure 4) with application of a Veraflow wound vacuum-assisted closure (VAC) 1 week later.

One full year after the patient was first admitted to the hospital, and 3 months after his bilateral transmetatarsal amputations, a split-thickness skin graft was applied on both his feet (figure 5).

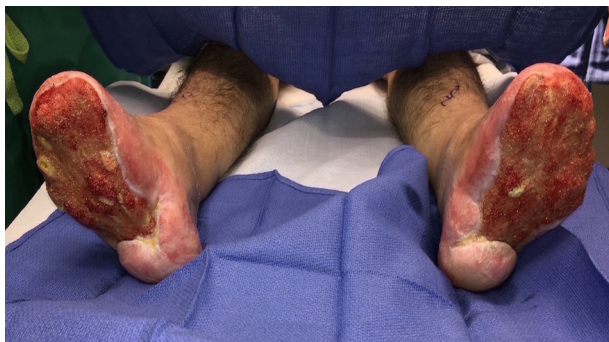#### OUTCOME AND FOLLOW-UP

The patient is currently continuing his recovery as an outpatient with the goal of full ambulation over the next several months.

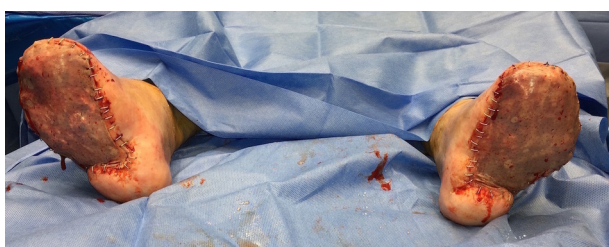


**Figure 3** Demarcated gangrene on the plantar aspect of both feet.





**Figure 4** Both feet 3 months after transmetatarsal amputations and application of Versaflow wound VAC.



**Figure 5** Both feet after application of split-thickness skin grafts.

## DISCUSSION

SPG is an infrequent clinical manifestation of an acute onset of ischaemia in two or more extremities without obstruction of the arteries that supply the extremity.<sup>2</sup> Fingers and toes are most commonly affected, and the least affected are the nose, earlobes and scrotum.<sup>2</sup> Hutchinson first described SPG in 1891 in a 37-year-old man who developed gangrene of the fingers, toes and earlobes after shock.<sup>4</sup> Since then, single case reports and small case series have been reported in the medical literature.<sup>4</sup>

SPG has been linked to infective and non-infective aetiologies and can develop in any age or sex.<sup>3,5</sup> Acute conditions are Gram-negative and Gram-positive septicaemia, low-output states and vasopressor use. Some chronic conditions include essential thrombocythaemia, polycythaemia rubra vera, Raynaud's syndrome, diabetes and small vessel obstruction.<sup>4,6</sup> However, disseminated intravascular coagulation (DIC) has been found widespread and is probably the last cause of microvascular injury resulting in SPG.<sup>3</sup> Strossel and Levy first described the association between DIC and SPG in 1970.<sup>3,4</sup>

Septicaemia is commonly associated with clinical DIC and occurs in approximately 30%–50% of patients with SPG.<sup>4</sup> The majority of SPG cases we reviewed attributed SPG to treatment for cardiogenic shock or septic shock with DIC.<sup>1–3,5,7</sup> The pathomechanics of DIC associated with SPG is primarily driven by a disordered clotting pathway.<sup>8,9</sup> This dysfunction may lead to inappropriate thrombin activation resulting in increased fibrin breakdown products and intravascular microthromboses.<sup>8,10</sup> Furthermore, the additional use of vasoconstrictive drugs exacerbates tissue hypoperfusion and ischaemia, leading to eventual tissue necrosis and gangrene.<sup>11</sup>

Also septic shock can be associated with high lactate. One article reported that very high serum lactate levels may be detected just prior to the onset of SPG.<sup>4</sup> Our patient's lactate was significantly elevated on the same day vasopressors were initiated and remained elevated for the next few days.

The three stages leading up to SPG are sepsis, ischaemia and gangrene. Treatment can be administered at each stage to prevent, slow or reverse the course to SPG. Septic shock, the first stage, results in low perfusion to the peripheral circulatory system and must be aggressively managed.<sup>2,5</sup> Treatment includes resuscitation with fluids, intravenous antibiotics, anticoagulants and vasopressors.<sup>5,7,12</sup>

The vasopressors recommended by the Surviving Sepsis Guidelines are either dopamine or norepinephrine as the initial vasopressor of choice, and vasopressin can supplement norepinephrine.<sup>13</sup> However, it has been noted that dopamine, epinephrine and norepinephrine can cause digital gangrene at recommended or curative dosage levels, especially in patients with DIC and hypovolaemia.<sup>1</sup> For example, renal and mesenteric bed vasodilatation occurs in low-dose dopamine (<5 µg/kg/min), cardiac contractions can occur at moderate doses (5–10 µg/kg/min), and vasoconstriction can occur at higher doses of 10–20 µg/kg/min.<sup>2</sup>

Peripheral gangrene attributed to the vasospastic action of dopamine was first reported in 1973.<sup>12</sup> Since then, one article has cited additional cases reported in the medical literature.<sup>12</sup> The patients in these cases clinically presented with either distal gangrene of multiple extremities or gangrene surrounding the area of intravenous filtration.<sup>12</sup> The infusion rate of dopamine varied in these cases from 1.5 to 66 µg/kg/min, and the average maximum dose given was 10 µg/kg/min.<sup>12</sup> Our patient developed SPG after receiving low to moderate doses of dopamine, ranging from 2 to 20 µg/kg/min for 2 days, norepinephrine doses ranging from 1 to 30 µg/min for 7 days, and vasopressin 2.4 units/hour for 3 days.

**Table 1** Day of initial appearance of ischaemia after vasopressor use

Age	Sex	Condition	Vasopressor	Day ischaemia noted post vasopressor administration	Outcome	Authors
36	M	Cardiogenic shock	Epinephrine (10 mg/50 mL of solution 0.9% at 8 mL/hour intravenous infusion) Dopamine (400 mg/100 mL of solution 0.9% at 10 mL/hour intravenous infusion)	Day 3	All digits autoamputated in the following 3 months and survived	Reyes <i>et al</i> <sup>1</sup>
30	M	Septic shock from intestinal perforation	Dopamine (20 µg/kg/min) and norepinephrine (0.2–0.3 µg/kg/min)	Day 2	Succumbed to multiple organ failure and died	Shenoy <i>et al</i> <sup>5</sup>
58	M	Septic shock/DIC due to pyelonephritis	Norepinephrine, dopamine and dobutamine	Day 3	Amputations of digits in all 4 extremities and survived	Akamatsu <i>et al</i> <sup>7</sup>
60	F	Septic shock/DIC due to renal hydronephrosis	Dopamine (29.5 µg/kg/min) and norepinephrine	Day 2	All limbs developed dry gangrene requiring amputation and survived	Dong <i>et al</i> <sup>2</sup>

DIC, disseminated intravascular coagulation.

The second stage leading to SPG is the onset of digital ischaemia, and there is a small window of time before it appears. The initial sign is erythematous, cold extremities, followed by dusky discolouration of the skin with pain.<sup>4 5</sup> If appropriate care is not given at this time, cyanosis and haemorrhagic bullae or blisters may develop in a symmetrical acral distribution over the fingers and toes.<sup>4 5</sup> Our patient's left fingernail beds and all of his toenail beds were noted to be cyanotic 2 days after administration of vasopressors. Select SPG cases with the day

### Patient's perspective

"My dad was born in Havana, Cuba and has been living here in the US since 1974. There was a moment that my father was very depressed during this situation. He was super active, took care of his household and he took care of his grandchildren all by himself. He worked for 30 years making the legs of pianos. What really affected him was when his left hand was amputated. Never in 30 years did he cut himself when he was making piano legs. Now, he now feels like he is a burden to his family. He was depressed in the nursing home. Now he is not able to move. He went from being super active to not being able to do anything. After his amputations, everything fell on my mom and me. His medical appointments, insurance, bills, it changed everyone's life. His grandchildren are affected too. His granddaughter asks when will her grandfather be able to pick her up from school again. It hurts them seeing him like that. The family is positive about his situation now. We are grateful that his feet were able to be saved and he didn't have to have an above the knee amputation. First time he heard he would be able to walk again and in 2 weeks he can put pressure on his feet. He is so optimistic that his next steps may be that he can go to the supermarket again. What we have learned from all of this is don't be stubborn with illnesses. My father knew he had kidney stones but he didn't want to be a burden. Be grateful because you never know what might happen. Be grateful for what you have. No one's life is perfect. You don't appreciate it as much because you don't think that something bad could happen." (Daughter of the patient)

### Learning points

- ▶ We believe multiple factors during management of sepsis and vasopressor use could potentially lead to the onset of symmetrical peripheral gangrene (SPG). The authors' encounter with this case and literature review provided key learnings in the management and treatment of SPG.
- ▶ SPG can occur when administering dopamine, epinephrine and norepinephrine at therapeutic doses.
- ▶ Consider aspects of the patient's medical history which raise the risk of SPG when administering vasopressors to treat sepsis.
- ▶ Early recognition and prompt treatment with systemic, local or topical sympathetic blockers or vasodilators may be beneficial in treating ischaemia where there is a high clinical suspicion of SPG.
- ▶ Monitoring serum lactate may be helpful in assessing the likelihood of the onset of SPG.
- ▶ Arterial occlusions may prevent the progression of SPG.
- ▶ Given the acute onset of SPG, it is important to have early conversations with the patient and the family regarding potential outcomes such as amputation.

of the initial appearance of ischaemia after vasopressor use are highlighted in [table 1](#).

Given these short time frames, early recognition is essential, as well as identifying patients with underlying diseases that may contribute to gangrene development.<sup>2</sup> The literature states that predicting which patient will develop SPG without occlusive diseases is difficult since the patient may have signs that are not indicative of digital vasoconstriction, such as pedal pulses, warm skin, and normal or high cardiac output.<sup>1</sup> Therefore, it is essential to monitor for ischaemic changes in the extremities when dopamine is infused because once ischaemia develops, the course to gangrene is more likely.<sup>1 14</sup>

The therapies that attempt to slow or reverse ischaemia after its appearance are sympathetic blockers, intravenous vasodilators, local injection of alpha-blockers and phosphodiesterase inhibitors.<sup>5</sup> Benefits have been reported with intravenous infusion of alpha-adrenergic antagonists such as chlorpromazine hydrochloride and infiltration of the ischaemic areas with phentolamine hydrochloride.<sup>14</sup> Phentolamine is a pure alpha-blocker and is recommended over chlorpromazine given its central nervous system effects.<sup>14</sup> The recommended dose of phentolamine is a solution of 5–10 mg diluted in 15 cc of saline solution into the area of ischaemia and monitoring the patients for low blood pressure.<sup>12 14</sup> Also local application of nitroglycerine ointment and early use of epoprostenol have been reported as beneficial.<sup>1 14</sup> Our patient was treated with intravenous argatroban 1.5 µg/kg/min, although it was 3 days after the appearance of digital ischaemia. Once fluid-filled bullae were noted on the digits, our patient received wound care and antibiotics with continuous monitoring for gangrene development.

The development of gangrene is the final stage of SPG. Dry gangrene becomes apparent within the first 12–24 hours after onset of ischaemic changes and progresses proximally with a line of demarcation developing in approximately 2 weeks.<sup>4</sup> Arteries supplying the gangrenous areas of the extremities are difficult to palpate but the large vessels are often spared.<sup>4 5</sup> However, one case reported a 70-year-old woman who, after treatment with vasopressors, developed gangrene in all her fingers and toes of the right foot. Her left foot was spared because the patient's left external iliac artery was occluded.<sup>3</sup> Our patient developed gangrene of his bilateral feet and only his left hand. Sparing of his right hand is currently undetermined.

The only definitive treatment that has been established for gangrene is amputation of the necrotic digits after development of a clear line of demarcation.<sup>5</sup> While awaiting demarcation, autoamputation of the gangrenous digits may occur.<sup>4</sup> In the meantime, local wound care should consist of interdigital padding to protect the gangrenous or ischaemic extremities, antiseptic dressings, debridement and antibiotics.<sup>4</sup> After demarcation, our patient's left hand digits 1, 4 and 5 were amputated, and transmetatarsal amputations were done on both feet with subsequent wound VAC placement and skin grafting.

**Contributors** All authors were involved in the treatment of this patient. WA discussed about writing the paper with SB and NR. NR initiated the concept, design, acquisition of data and literature review, and wrote the initial draft. SB acquired additional data and fact-checked each revision. WA and CVV analysed the article, revising each draft critically for important intellectual content. All authors approved the final version submitted. NR will ensure that all questions regarding the accuracy and integrity of the article are investigated and resolved.

**Funding** This research received no specific grant from any funding agency in the public, commercial or not-for-profit sectors.

**Competing interests** None declared.

**Patient consent** Obtained.

**Provenance and peer review** Not commissioned; externally peer reviewed.

**Open Access** This is an Open Access article distributed in accordance with the Creative Commons Attribution Non Commercial (CC BY-NC 4.0) license, which permits others to distribute, remix, adapt, build upon this work non-commercially, and license their derivative works on different terms, provided the original work is properly cited and the use is non-commercial. See: <http://creativecommons.org/licenses/by-nc/4.0/>

© BMJ Publishing Group Ltd (unless otherwise stated in the text of the article) 2018. All rights reserved. No commercial use is permitted unless otherwise expressly granted.

## REFERENCES

- 1 Reyes AJ, Ramcharan K, Harnarayan P, *et al.* Symmetrical digital gangrene after a high dose intravenous infusion of epinephrine and dopamine following resuscitation from cardiac arrest. *BMJ Case Rep* 2016. doi: 10.1136/bcr-2016-217977. [Epub ahead of print 22 Nov 2016].
- 2 Dong J, Zhang L, Rao G, *et al.* Complicating Symmetric Peripheral Gangrene after Dopamine Therapy to Patients with Septic Shock. *J Forensic Sci* 2015;60:1644–6.
- 3 Markelov A, Defroda S, Baccaro L, *et al.* A unique case of unilateral lower extremity sparing systemic peripheral gangrene. *Case Rep Vasc Med* 2012. doi: 10.1155/2012/750953. [Epub ahead of print 13 Dec 2012].
- 4 Sharma BD, Kabra SR, Gupta B. Symmetrical peripheral gangrene. *Trop Doct* 2004;34:2–4.
- 5 Shenoy R, Agarwal N, Goneppanavar U, *et al.* Symmetrical peripheral gangrene—a case report and brief review. *Indian J Surg* 2013;75:163–5.
- 6 Hayes MA, Yau EH, Hinds CJ, *et al.* Symmetrical peripheral gangrene: association with noradrenaline administration. *Intensive Care Med* 1992;18:433–6.
- 7 Akamatsu S, Kojima A, Tanaka A, *et al.* Symmetric peripheral gangrene. *Anesthesiology* 2013;118:1455.
- 8 Silbart S, Oppenheim W. Purpura fulminans. Medical, surgical, and rehabilitative considerations. *Clin Orthop Relat Res* 1985;193:206–13.
- 9 Davis MD, Dy KM, Nelson S. Presentation and outcome of purpura fulminans associated with peripheral gangrene in 12 patients at Mayo Clinic. *J Am Acad Dermatol* 2007;57:944–56.
- 10 Johansen K, Hansen ST, gangrene S. purpura fulminans) complicating pneumococcal sepsis. *Am J Surg* 2017;165:642–5.
- 11 Molos MA, Hall JC. Symmetrical peripheral gangrene and disseminated intravascular coagulation. *Arch Dermatol* 1985;121:1057–61.
- 12 Winkler MJ, Trunkey DD. Dopamine gangrene. Association with disseminated intravascular coagulation. *Am J Surg* 1981;142:588–91.
- 13 Skrupky LP, Kerby PW, Hotchkiss RS. Advances in the management of sepsis and the understanding of key immunologic defects. *Anesthesiology* 2011;115:1–62.
- 14 Kaul S, Sarela AI, Supe AN, *et al.* Gangrene complicating dopamine therapy. *J R Soc Med* 1997;90:80.

Copyright 2018 BMJ Publishing Group. All rights reserved. For permission to reuse any of this content visit <http://group.bmj.com/group/rights-licensing/permissions>.  
BMJ Case Report Fellows may re-use this article for personal use and teaching without any further permission.

Become a Fellow of BMJ Case Reports today and you can:

- ▶ Submit as many cases as you like
- ▶ Enjoy fast sympathetic peer review and rapid publication of accepted articles
- ▶ Access all the published articles
- ▶ Re-use any of the published material for personal use and teaching without further permission

For information on Institutional Fellowships contact [consortiasales@bmjgroup.com](mailto:consortiasales@bmjgroup.com)

Visit [casereports.bmj.com](http://casereports.bmj.com) for more articles like this and to become a Fellow