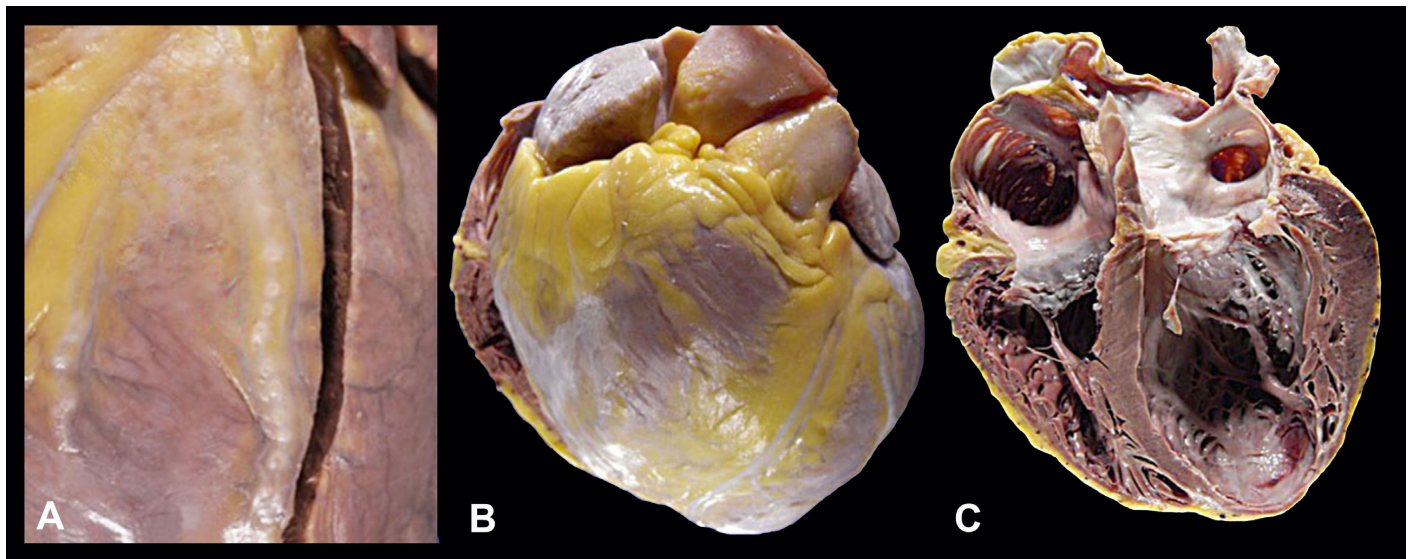


## Chronic Chagas cardiomyopathy

Vera Demarchi Aiello<sup>a</sup>, Fernando Peixoto Ferraz de Campos<sup>b</sup>

Aiello VD, Campos FPF. Chronic Chagasic cardiomyopathy. *Autopsy Case Rep* [Internet]. 2015;5(3):7-9. <http://dx.doi.org/10.4322/acr.2015.012>



Gross findings of Chronic Chagas Cardiomyopathy. **A** – “Chagasic rosary” represented by small round whitish granules deposited sequentially along the coronary vessels. **B** and **C** – Dilation of the atrial and ventricular chambers with typical apical left ventricular aneurysm in C. Image courtesy Dr. Vera Demarchi Aiello.

First described by Carlos Justiniano Ribeiro Chagas (1879-1934) in 1909, Chagas disease (CD) or American trypanosomiasis is caused by the protozoan parasite *Trypanosoma cruzi*. This zoonotic infectious disease follows a sylvatic cycle where blood-sucking triatomine insect (known as kissing bug or in Portuguese as “barbeiro”), acquire the parasite by sucking small mammals’ blood and transmit to humans through their feces, left close to the bite site. The parasite, in turn, reaches the human blood stream when the parasite-laden feces are dispersed at the itching bite wound. More rarely, transmission may also

occur through blood transfusion, congenital, organ transplantation and oral transmission by ingesting contaminated food by infected triatomine or their feces. In addition, the disease may reactivate from the chronic phase when associated with any sort of immunosuppression, including HIV infection.<sup>1</sup>

In 2012 it was estimated that 8 million persons were infected in South and Central America and Mexico and that 12,500 deaths occur annually due to Chagas disease.<sup>2</sup>

The natural history of the disease involves an acute phase that lasts between 8 and 12 weeks after

<sup>a</sup> Pathology Laboratory - Instituto do Coração - Hospital das Clínicas - University of São Paulo, São Paulo/SP – Brazil.

<sup>b</sup> Internal Medicine Division - Hospital Universitário - University of São Paulo, São Paulo/SP – Brazil.

an incubation period of two weeks. However, in case of transmission by transfusion or transplant-associated cases this incubation period may be much longer.<sup>3,4</sup> This phase is characterized by parasitemia, and therefore the diagnosis can be made by detection, on microscopy, of circulating parasites in fresh blood or buffy coat smears. The acute phase may be asymptomatic or may present nonspecific clinical features. Meanwhile, severe acute Chagas disease, hopefully rare (less than 1% of the cases), may present as acute myocarditis, pericardial effusion and/or meningoencephalitis, which is associated with high risk of death.<sup>5</sup>

The chronic phase begins from the moment at which the parasitemia falls and is no longer detectable by microscopy, in the absence of specific therapy. If patients, after the resolved acute infection, do not present signs of heart or gastrointestinal disease they are considered to have the indeterminate form. Although asymptomatic, autopsy studies performed in patients with the indeterminate form who died from accidental causes revealed the presence of scattered myocardial inflammatory sites.<sup>6,7</sup> In the study conducted by Macedo,<sup>8-10</sup> in São Felipe (BA), which comprised 400 patients with the indeterminate form of Chagas disease, 24% developed clinical disease after 10 years. This percentage is higher among younger patients.

The major manifestations of chronic CD comprise cardiomyopathy (much more frequent) and gastrointestinal disease, mainly characterized by the presence of dilations (mega esophagus or mega colon).

Chronic Chagas cardiomyopathy (CCC) may be manifested, isolated or concurrently, by heart failure, arrhythmias, thromboembolism (systemic or pulmonary) and chest pain. Therefore clinical features are characterized by fatigue, dyspnea, peripheral edema, pulmonary rales, ascites, hepatomegaly, increased jugular venous pressure, palpitation, syncope and cardiac arrest, the latter responsible for up to half of the deaths.<sup>11</sup> All types of atrial and ventricular arrhythmias may be virtually present. Atrioventricular and bundle blocks are also often present.<sup>12</sup> Thromboembolism is an important cause of CCC morbidity. Stroke may be due to embolus originated in left ventricular aneurysm or dilated left chamber, and pulmonary thromboembolism arises from right heart thrombi due to chamber dilation or

atrial fibrillation. In a retrospective and large study on autopsies of patients with CCC intracardiac thrombi were observed in 44% of cases.<sup>13</sup>

Gross morphological features of CCC include severe dilation of the atrial and ventricular chambers (Figure, panels B and C), with the typical apical left ventricular aneurysm, a lesion where the ventricular wall is thinned and partially or completely replaced by fibrosis (Figure, panel C). Other areas of wall thinning are also observed, mainly at the diaphragmatic wall near the left atrioventricular junction. Thrombosis is frequent both inside the atrial appendages and filling the apical aneurysm. On the epicardial surface some frequent findings are focal areas of fibrous thickening, the so called "milky spots", usually found on the anterior surface of the right ventricle, and lesions known as the "Chagasic rosary" (Figure, panel A) appearing as round whitish granules along the epicardial course of the coronary vessels in up to one quarter of the cases.<sup>14</sup> At microscopy, there is diffuse chronic myocarditis with variable degrees of fibrosis. The finding of parasites in the myocardium is rare, and usually disproportional to the intensity of the inflammation, a fact that led to the hypothesis of autoimmunity in the pathogenesis of the disease. Higuchi and co-workers believe that the presence of the parasite or its antigens in the myocardium, although in small quantities, is important for the maintenance of the inflammatory process.<sup>15</sup> Inflammation and fibrosis may involve the atrioventricular node and bundle branches, causing cardiac block. Segmental and irregular fibrosis of the ventricular walls may also elicit sustained ventricular tachycardia, since isolated myocardial cells remain as islands or peninsulas within the fibrotic areas, similar to what occurs in healed myocardial infarction.

## REFERENCES

1. Shikanai-Yasuda MA, Carvalho NB. Oral transmission of Chagas disease. *Clin Infect Dis.* 2012;54(6):845-52. <http://dx.doi.org/10.1093/cid/cir956>. PMID:22238161.
2. Moncayo A, Silveira AC. Current epidemiological trend for Chagas disease in Latin America and future challenges in epidemiology, surveillance and health policy. *Mem Inst Ows Cruz Rio de.* 2009;204(Suppl 1):17-30.
3. Centers for Disease Control and Prevention (CDC). Chagas disease after organ transplantation—United States, 2001.

- MMWR Morb Mortal Wkly Rep. 2002;51(10):210-2. PMID:11922190.
4. Kun H, Moore A, Mascola L, et al. Transmission of *Trypanosoma cruzi* by heart transplantation. *Clin Infect Dis*. 2009;48(11):1534-40. <http://dx.doi.org/10.1086/598931>. PMID:19400748.
  5. Maguire JH. *Trypanosoma*. In: Gorbach S, Bartlett J, Blacklow N, editors. *Infectious Diseases*. 2nd ed. Philadelphia: Lippincott, Williams & Wilkins; 2004.
  6. Lopes ER, Chapadeiro E, Almeida HO, Rocha A. Contribuição ao estudo da anatomia patológica dos corações de chagásicos falecidos subitamente. *Rev Soc Bras Med Trop*. 1975;9(6):269-82. <http://dx.doi.org/10.1590/S0037-86821975000600001>.
  7. Lopes ER, Chapadeiro E, Andrade ZA, Almeida HO, Rocha A. Anatomia patológica de corações de chagásicos assintomáticos falecidos de modo violento. *Mem Inst Oswaldo Cruz*. 1981;76(2):189-97. <http://dx.doi.org/10.1590/S0074-02761981000200010>. PMID:6817025.
  8. Macedo VO. Forma indeterminada da doença de Chagas. In: Dias JCP, Coura JR, editors *Clínica e terapêutica da doença de Chagas: uma abordagem prática para o clínico geral*. Rio de Janeiro: FIOCRUZ; 1997.
  9. Macêdo VO. Forma indeterminada da doença Chagas. *J Bras Med*. 1980;38:34-40.
  10. Macêdo V. Indeterminate form of Chagas disease. *Mem Inst Oswaldo Cruz*. 1999;94(Suppl 1):311-6. <http://dx.doi.org/10.1590/S0074-02761999000700059>. PMID:10677745.
  11. Rassi A Jr, Rassi SG, Rassi A. Sudden death in Chagas' disease. *Arq Bras Cardiol*. 2001;76(1):75-96. <http://dx.doi.org/10.1590/S0066-782X2001000100008>. PMID:11175486.
  12. Garzon SAC, Lorga AM, Nicolau JC. Electrocardiography in Chagas' heart disease. *Sao Paulo Med J*. 1995;113(2):802-13. <http://dx.doi.org/10.1590/S1516-31801995000200011>. PMID:8650480.
  13. Oliveira JSM, Araujo RRC, Navarro MA, Muccillo G. Cardiac thrombosis and thromboembolism in chronic Chagas' heart disease. *Am J Cardiol*. 1983;52(1):147-51. [http://dx.doi.org/10.1016/0002-9149\(83\)90085-1](http://dx.doi.org/10.1016/0002-9149(83)90085-1). PMID:6858902.
  14. Benvenuti LA, Gutierrez PS. Epicardial lesions in Chagas' heart disease reflect an inflammatory process. *Arq Bras Cardiol*. 2007;88(4):496-8. <http://dx.doi.org/10.1590/S0066-782X2007000400022>. PMID:17546284.
  15. Higuchi ML, Benvenuti LA, Martins Reis M, Metzger M. Pathophysiology of the heart in Chagas' disease: current status and new developments. *Cardiovasc Res*. 2003;60(1):96-107. [http://dx.doi.org/10.1016/S0008-6363\(03\)00361-4](http://dx.doi.org/10.1016/S0008-6363(03)00361-4). PMID:14522411.

### Correspondence

Vera Demarchi Aiello

Surgical Pathology Section of the Laboratory of Pathology at the Heart Institute

Hospital das Clínicas - University of São Paulo

Av. Dr Enéas C Aguiar, 44 – São Paulo/SP – Brazil

CEP: 05403-000

Phone: +55 (11) 2661-5252

**E-mail:** [anpvera@incor.usp.br](mailto:anpvera@incor.usp.br)