

Oncological safety of immediate rectus abdominis myocutaneous breast reconstruction in patients with locally advanced disease (stage IIb and III)

Mushtaq Mir, Muddassir Shahdhar, Khurshid Ganaie, Quibtiya Syed

Abstract

Background: The management of locally advanced (Stage IIb and III) breast cancer is challenging. It often includes multimodal treatment with systemic therapy and/or radiation therapy and surgery. Immediate breast reconstruction has not traditionally been performed in these patients. We review the results of immediate rectus abdominis musculo-cutaneous (TRAM/VRAM) flap in 60 patients treated for Stage IIb and III breast cancer. **Materials and Methods:** Data were collected prospectively on 60 patients diagnosed with Stage IIb (32 patients) and Stage III (28 patients) breast cancer between May 2008 and May 2012. All patients had mastectomy and immediate rectus abdominis myocutaneous reconstruction (TRAM in 40 patients and VRAM in 20 patients). All patients received primary systemic therapy, and all patients received postoperative radiotherapy to the operative site. **Results:** Mean age was 40.13 (range 28-53) years, mean hospital stay was 8.86 days and mean follow-up for the group was 28 months. Neither of them developed local disease recurrence in the operative site till the last follow-up. Eight (13.3%) patients had some delay in chemo-radiation therapy due to flap-related complications. Flap-related complications were present in eight patients (partial flap failure in four and superficial skin necrosis in four). There was no adverse effect of chemo-radiation therapy on reconstructed breast. **Conclusion:** Immediate TRAM/VRAM breast reconstruction for locally advanced breast cancer is not associated with a significant delay in adjuvant therapy or an increased risk of local relapse. Radiation therapy can be delivered to the reconstructed breast when indicated without difficulty. Breast reconstruction facilitates surgical resection of locally advanced breast cancer with primary closure and should be considered if the patient desires immediate breast reconstruction.

Key words: Immediate breast reconstruction, rectus abdominis myocutaneous reconstruction; mastectomy

Introduction

Breast cancer is a major and important form of malignant disease all over the world. More than a million cases of breast cancer are diagnosed worldwide each year. Each year more than 211,000 cases of invasive breast cancer and more than 58,000 cases of *in situ* breast cancer are diagnosed in the United States, and approximately 40,000 women die of breast cancer^[1] During the Halstedian era, which lasted about 60 years, radical mastectomy was the treatment for carcinoma breast. In fact Halsted warned against closure of the breast wound after the surgery.^[2] Hence attempts to reconstruct breast (process of recreating a breast mound aiming to match the remaining natural breast) after mastectomy had to wait for many years. Despite the condemnation of the reconstruction of breast, Vincent Czerny tried it for the first time in 1895 by transplanting a large lipoma of the flank to the mastectomy site, and it was reported that the patient was

doing well after one year.^[3] Tansini described the use of the latissimus dorsi myocutaneous flap for the first time in 1906 for a breast reconstruction.^[4] In 1942 Sir Harold Gillis of England described a pedicled flap from the abdomen with multiple stages for reconstructing breast.^[5] Manchot in his landmark work on vascular territories developed different types of flaps including the axial flap^[6] The development of muscle, musculo-cutaneous, and fascio-cutaneous flaps and microsurgical transplantation has had a tremendous impact on breast reconstruction. Immediate breast reconstruction, which begins at the time of the mastectomy, has become the standard of care for most patients. The obvious benefit to immediate post-mastectomy reconstruction is the psychological and aesthetic advantage of waking up after the mastectomy with a lesser deformity and a reconstruction well underway. Also, immediate reconstruction can spare the patient additional stages of surgery and additional interruptions in her life. Although a slight drawback of immediate reconstruction is that it requires a longer surgery and recovery than just having mastectomy alone. The aim of our study was to find out the effects of chemo-radiation on breast reconstruction and vice versa. Local recurrence rate was also studied. Our study project was approved by the independent ethics committee/ethical review board of the Government Medical College Srinagar and its associated SMHS Hospital Srinagar Kashmir.

Materials and Methods

The study was conducted by a Plastic Surgeon and General Surgeons from May 2008-May 2012 on 60 patients

Department of Surgery, SMHS Hospital, Srinagar, Jammu and Kashmir, India

Correspondence to: Dr. Muddassir Shahdhar,
E-mail: mshahdhar@yahoo.co.in

Access this article online

Quick Response Code:



Website:
www.sajc.org

DOI:
10.4103/2278-330X.119921

prospectively in the department of General Surgery SMHS Hospital Srinagar, Kashmir, India – a tertiary care centre. All the patients included in this study were explained in detail about the procedure by both the Plastic and General Surgeon of the department. All our patients gave their consent for the procedure and subsequent publication of the work.

Only those patients who could fulfill the following criteria were taken for breast reconstruction:

- Stage IIB and III Breast Cancer
- Age 15-60 years
- Likely anatomical deficiency after mastectomy. This especially applied to patients having good-sized breasts, which if removed would have certainly left behind an unacceptable anatomical deficiency
- Mental fitness for surgery.

Reconstruction was offered to only those who had a very positive frame of mind and only to those who could be brought to that state after adequate counseling. Before offering the option of reconstruction to the patient, her general health and physique was taken into consideration. The health of the tissue at the planned operation site (donor site) was assessed. A day before the surgery, the procedure was planned jointly by general surgeons and a plastic and reconstructive surgeon. The mastectomy site and flap site (e.g., TRAM or VRAM flap) was properly marked with a permanent marker with special emphasis on the mastectomy incision and donor site incision [Figure 1].

Mastectomy and axillary clearance was done by general surgeons [Figure 2]. Specimen was sent for HPE (histopathological examination), Estrogen, Progesterone and Her-2 receptor status. Post mastectomy primary breast reconstruction was done with a pedicled Rectus Abdominis Myocutaneous (Transverse {TRAM} or Vertical {VRAM}) flap [Figure 3].

In our study we used single-pedicled TRAM or VRAM of ipsilateral side as well as of contralateral side. After achieving complete hemostasis, drains (suction) were placed in the area of the mastectomy site, axilla and the donor site [Figure 4]. Postoperative psychological impact was positive in 86.6% because these patients were both oncologically safe and cosmetically good. Patients were followed weekly for 2 weeks, then 2-weekly (every 15 days) for 2 months, then monthly for 2-6 months, and then 2-monthly for the next 6 months. All the patients were subjected to postoperative chemotherapy and radiotherapy.

Results

The minimum age of the patients was 28 years and maximum age was 53 years, with a mean age of 40.13 years [Table 1].

In our study, out of 60 patients, 32 (53.3%) patients had Stage IIB disease and 28 (46.6%) patients had Stage III (IIIa in 20 and IIIb in 8) disease according to American Joint Committee on Cancer (AJCC) staging System [Table 2].

In our study, out of 60 patients, we used TRAM (Transverse Rectus Abdominis Myocutaneous) flap in 40 (66.6%) patients and VRAM (Vertical Rectus Abdominis Myocutaneous) flap in 20 (33.3%) patients. In all patients immediate breast reconstruction was done [Table 3].

None of the patients had local recurrence till the last follow-up.

Chemo-radiation was given to all 60 patients. Eight patients (13.3%) had some delay in chemo- radiation therapy because of flap-related complications [Table 4].

Discussion

The study was conducted in the Department of Surgery in the SMHS hospital—a tertiary care hospital in northern India. A total of 60 cases were included prospectively in the study. Skin-sparing Mastectomy (SSM) has afforded plastic surgeons an unparalleled opportunity to reconstruct a life-like breast ensuring simultaneously a complete removal of the tumor-bearing tissue.^[7-9] In this series, only those patients who could fulfill the inclusion criteria were included. These strict criteria were adopted so as to minimize peri-operative morbidity and achieve optimal results for the different techniques employed. The minimum age of the patients was 28 years and maximum age was 53 years, with a mean age of 40.13 years. Similar results were observed in the study done by Laurie *et al.*^[10] In their study, the patients

Table 1: Age distribution of patients

Age in years	No. of patients	% of patients
≤ 30	8	13.33
31–40	24	40.0
41–50	24	40.0
> 50	4	6.66
Total	60	100

Table 2: Distribution of cases according to AJCC staging

AJCC stage	No. of patients	% of patients
Stage IIB	32	53.3
Stage IIIa	20	33.3
Stage IIIb	8	13.3
Total	60	100

Table 3: Type of flap used

Type of flap used	No. of patients	%
TRAM	40	66.6
VRAM	20	33.3

VRAM=Vertical rectus abdominis myocutaneous, TRAM=Transverse rectus aAbdominis myocutaneous

Table 4: Delay in postoperative chemo-radiation

Delay in chemo-radiation	No. of patients	% of patients
Yes	8	13.3
No	52	86.6

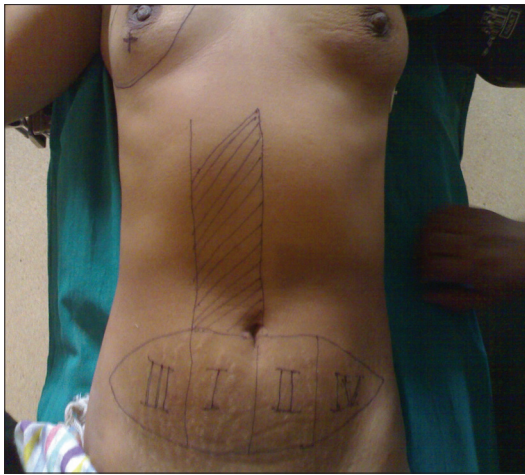


Figure 1: Preoperative flap/site marking for TRAM

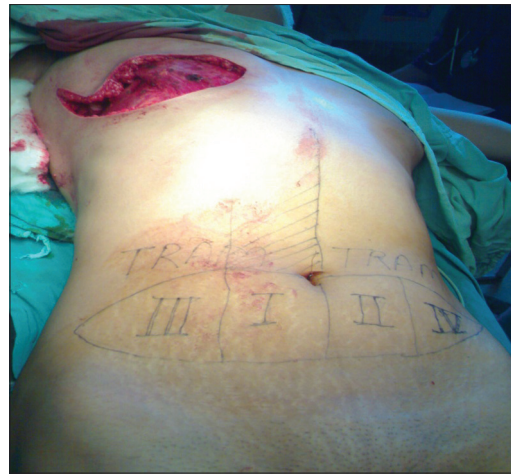

Figure 2: Post-mastectomy defect in a patient with breast cancer

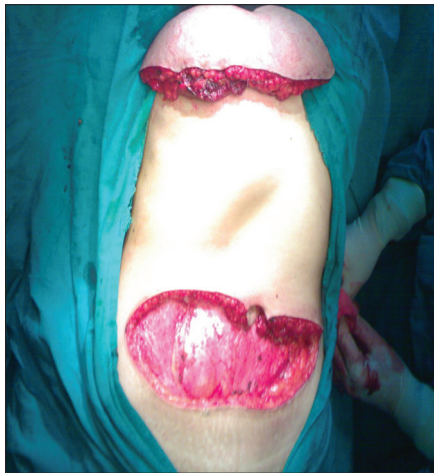

Figure 3: TRAM flap being transposed to the mastectomy defect

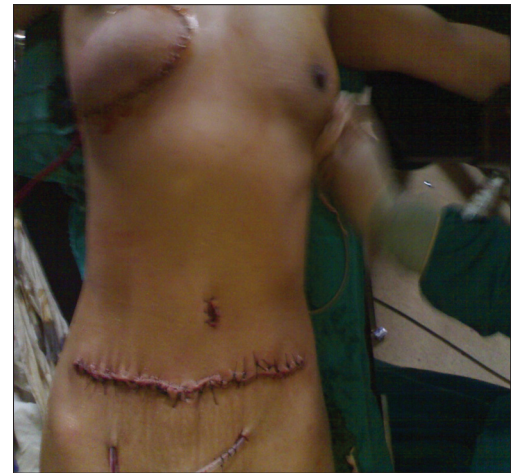

Figure 4: Immediate postoperative result of breast reconstruction

ranged in age between 28-65 years. The mean hospital stay of patients was 8.8 days. Franklyn Elliott *et al.*,^[11] in their study found a hospital stay ranging between 6-9 days. Each patient was subjected to postoperative chemotherapy to reduce the possibility of local and distant recurrence. According to the National Institute of Health Centre Consensus Development Panel,^[12] adjuvant chemotherapy or hormonal therapy is routinely recommended for most patients with tumor more than 1 cm, removing knowledge of nodal status from the decision-making process. All the patients in our series were subjected to postoperative radiotherapy to prolong the disease-free survival. As observed by Styblo *et al.*,^[13] immediate TRAM reconstruction for Stage III breast cancer is not associated with a delay in adjuvant therapy (chemo-radiotherapy). The present study also showed that immediate breast reconstruction had no effect on delaying chemo-radiation therapy. Foster *et al.*,^[14] in their study observed that immediate TRAM breast reconstruction followed by radiation therapy is safe, with minimal morbidity and no significant change in tissue volume. Immediate breast reconstruction can be considered after mastectomy despite the need of postoperative radiation therapy. Mehta *et al.*,^[15] in their study showed that

post-reconstruction chemo-radiation therapy is well tolerated. He observed that, with a mean follow-up of 18 months, no TRAM flaps were lost or required revision. In our present study, we observed similar results. In recent studies, local recurrence rates after mastectomy and immediate breast reconstruction have varied between 0 and 7.9%, whereas total recurrence rates (including systemic recurrence) may reach 20%, depending on patient selection and length of follow-up.^[16,17] The present study had 0% local recurrence rate. This variation may be due to a short follow-up. The mean follow-up time in our study was 28 months. The surgical and particularly the oncological safety of mastectomy followed by immediate breast reconstruction has been discussed in detail in recent literature. Indications for breast reconstruction, especially immediate breast reconstruction have continued to broaden and recent studies report the technique being used even for advanced stages of breast carcinoma.^[18-20]

Conclusion

The use of mastectomy in conjunction with immediate breast reconstruction (IBR) is a team effort that requires close co-operation between the general surgeon and plastic

surgeon. Use of mastectomy with IBR is oncologically safe and provides support for those who believe that skin-sparing mastectomy and IBR are appropriate treatment for patients with locally advanced breast cancer. Immediate breast reconstruction has no effect on chemo-radiation therapy or vice versa. So reconstruction of post-mastectomy breast should be undertaken whenever possible. Our preliminary results with this study and technique have been encouraging and further studies are warranted before it is accepted as standard of care.

References

- Jemal A, Siegel R, Ward E, Murray T, Xu J, Smigal C, *et al.* Cancer statistics, 2006. *CA Cancer J Clin* 2006;56:106-30.
- Burjet WC, editor. *Surgical Papers by William Stewart Halsted*. Baltimore: Johns Hopkins Press; 1924.
- Goldwyn R. Vincenz Czerny and the beginnings of breast reconstruction. *Plast Reconstr Surg* 1978;61:673-81.
- Bostwick J 3rd, Schelfan M. The Latissimus dorsi musculocutaneous flap: A one stage breast reconstruction. *Clin Plast Surg* 1980;7:71-8.
- Mendelson BC. The evolution of breast reconstruction. *Med J Aust* 1982;1:7-8.
- Manchot C. *Die Hautarterien des menschlichen Körpers*. Leipzig: Vogel; 1989.
- Veronesi U, Banfi A, Salvadori B. Breast conservation is the treatment of choice in Small breast cancer: Long term results of a randomized trial. *Eur J Cancer* 1990;26:668-70.
- Schain WS, Wellisch DK, Pasnau RO, Landsverk J. The sooner the better: A study of psychological factors in women undergoing immediate versus delayed breast reconstruction. *Am J Psychiatry* 1985;142:40-6.
- Noone RB, Frazier TG, Hayward CZ, Skiles MS. Patient's acceptance of immediate reconstruction following mastectomy. *Plast Reconstr Surg* 1982;69:632-40.
- Laurie A. Stevens, MH Mc Grath, RG Druss. The psychological impact of the immediate breast reconstruction for women with early breast cancer. *Plast Reconstr Surg* .73, 1984, 619-26.
- Elliott LF, Eskenazi L, Beegle PH Jr, Podres PE, Drazan L. Immediate TRAM Flap Breast Reconstruction: 128 Consecutive Cases. *Plast Reconstr Surg* 1993;92:217-27.
- Eifel P, Axelson JA, Costa J, Crowley J, Curran WJ Jr, Deshler A, *et al.* National Institutes of Health Consensus Development Conference Statement: Adjuvant therapy for breast cancer, November 1-3, 2000. *J Natl Cancer Inst* 2001;93:979-89.
- Styblo TM, Lewis MM, Carlson GW, Murray DR, Wood WC, Lawson D, *et al.* Immediate breast reconstruction for stage III breast cancer using transverse rectus abdominis musculocutaneous (TRAM) flap. *Ann Surg Oncol* 1996;3:375-80.
- Foster RD, Hansen SL, Esserman LJ, Hwang ES, Ewing C, Lane K, *et al.* Safety of immediate transverse rectus abdominis myocutaneous Breast reconstruction for patients with locally advanced disease. *Arch Surg* 2005;140:196-200.
- Mehta VK, Goffinet D. Postmastectomy radiation therapy after TRAM flap breast reconstruction. *Breast J* 2004;10:118-22.
- Carlson GW, Styblo TM, Lyles RH, Bostwick J, Murray DR, Staley CA, *et al.* Local recurrence after skin-sparing Mastectomy: Tumor biology or surgical conservatism? *Ann surgoncol* 2003;10:108-12.
- Medina-Franco H, Vasconez LO, Fix RJ, Heslin MJ, Beenken SW, Bland KI, *et al.* Factors associated with local recurrence after skin-sparing mastectomy and immediate breast reconstruction for invasive breast cancer. *Ann surg* 2002;235:814-9.
- Foster RD, Esserman LJ, Anthony JP, Hwang ES, Do H. Skin-sparing mastectomy and Immediate Breast Reconstruction: A Prospective Cohort Study for the Treatment of Advanced Stages of Breast Carcinoma. *Ann Surg Oncol* 2002;9:462-6.
- Newman LA, Kuerer HM, Hunt KK, Ames FC, Ross MI, Theriault R, *et al.* Feasibility of immediate breast reconstruction for locally advanced breast cancer. *Ann Surgoncol* 1999;6:671-5.
- Downes KJ, Glatt BS, Kanchwala SK, Mick R, Fraker DL, Fox KR, *et al.* Skin-sparing mastectomy and immediate breast reconstruction is an acceptable treatment option for patients with high risk breast carcinoma. *Cancer* 2005;103:906-13.

How to cite this article: ????.

Source of Support: Nil. **Conflict of Interest:** None declared.

Letter to Editor

Is existing cervical cancer screening proven productive in developing nations: Time to move from the laboratory to community?

Sandeep Singh, Sorabh Badaya, Manish Kishore Multani

Correspondence to: Dr. Sandeep Singh,
E-mail: sandeepkcsingh@gmail.com

Access this article online

Quick Response Code:



Website:
www.sajc.org

DOI:
10.4103/2278-330X.119923