

# Podocytes Intracytoplasmic Dense Inclusions: Are They Associated with Subepithelial Dense Deposits? An Ultrastructural Study

Sawsan Mohammad Jalalah

Department of Pathology, Faculty of Medicine, King Abdulaziz University, Jeddah, Saudi Arabia

## Abstract

**Introduction:** Podocytes play a crucial role in health and disease. They participate in clearing the filtration barrier by removing accumulated proteins. It is proposed that podocytes have the ability to remove immune complexes and internalize them in the cytoplasm. **Aims:** The purpose of this study is to review certain immune complex glomerulonephritis (GN) types and illustrate ultrastructural details of podocytes intracytoplasmic dense inclusions (ICDIs) if present. **Materials and Methods:** A retrospective ultrastructural study of podocytes was conducted to detect cytoplasmic inclusions. The study cases ( $n = 148$ ) include GN types with subepithelial dense deposits such as membranous GN, postinfectious GN (PIGN), and lupus nephritis. **Results:** Podocytes ICDIs are detected ultrastructurally in 48 of 148 cases, mostly with PIGN; their morphology resembles the subepithelial dense deposits of the corresponding case. **Conclusions:** Podocytes ICDIs represent internalized immune complexes from the adjacent subepithelial dense deposits, suggesting a clearance method of the glomerular basement membrane by podocytes.

**Keywords:** Intracytoplasmic inclusions, lupus nephritis, membranous glomerulonephritis, podocytes, postinfectious glomerulonephritis

## INTRODUCTION

Podocytes are extremely specialized epithelial cells with interdigitating foot processes connected by slit diaphragm, enveloping the outer surface of the capillary loops, which along with glomerular basement membrane and endothelial cells comprise the filtration barrier.<sup>[1]</sup> Podocytes play an active role in house-keeping where they clear accumulated proteins from the filtration barrier.<sup>[2]</sup> They also express complement factors and complements receptors that may participate in removing glomerular immune complexes.<sup>[3]</sup>

With podocytes crucial role, their dysfunction and loss have been attributed to a vast range of glomerular diseases such as focal segmental glomerulosclerosis, diabetic nephropathy, obesity-related glomerulonephritis (GN), and hereditary nephritis.<sup>[4-6]</sup>

Podocytes may also be injured as a result of subepithelial immune complexes removal through complement-dependant process.<sup>[7-9]</sup> *In vivo* animal studies show that immune

complexes on the surface of podocytes are internalized to be disposed of by these cells.<sup>[10]</sup> However, to my knowledge, no human renal tissue study demonstrated similar findings in the different immune-complex GN types.

I have come across an ultrastructural observation of intracytoplasmic dense inclusions (ICDIs) in podocytes, during my cases examination and sought to investigate this further. The purpose of this study is to review whether certain immune complex GN types have podocytes (ICDI) and to illustrate their ultrastructural appearance if present.

## MATERIALS AND METHODS

This is a retrospective observational study of 148 renal biopsy cases. Cases were retrieved from our institute's renal biopsies archives for the period 2004–2014. Cases were selected based

**Address for correspondence:** Dr. Sawsan Mohammad Jalalah,  
Department of Pathology, Faculty of Medicine, King Abdulaziz  
University, Jeddah, Saudi Arabia.  
E-mail: sjalalah@kau.edu.sa

Received: 17-11-2019 Accepted: 24-11-2019 Published: 08-05-2020

### Access this article online

Quick Response Code:



Website:  
<http://www.jmau.org/>

DOI:  
10.4103/JMAU.JMAU\_66\_19

This is an open access journal, and articles are distributed under the terms of the Creative Commons Attribution-NonCommercial-ShareAlike 4.0 License, which allows others to remix, tweak, and build upon the work non-commercially, as long as appropriate credit is given and the new creations are licensed under the identical terms.

**For reprints contact:** reprints@medknow.com

**How to cite this article:** Jalalah SM. Podocytes intracytoplasmic dense inclusions: Are they associated with subepithelial dense deposits? An ultrastructural study. *J Microsc Ultrastruct* 2020;8:121-5.

on the diagnosis report mentioning the presence of subepithelial dense deposits. The selected cases were membranous GN (MGN) ( $n = 31$ ), postinfectious GN (PIGN) ( $n = 33$ ), and lupus nephritis (LN) Class II–V ( $n = 84$ ) cases.

All renal biopsies submitted to our department were examined by light microscopy (LM), immunofluorescence (IF), and electron microscopy (EM) to ensure a proper diagnosis. The biopsy tissue handling and processing are performed following the routine techniques in the pathology hospital laboratory and the EM unit.

The tissue is divided into three studies. Tissue for LM is fixed in buffered formalin and then processed into paraffin blocks. Sections are stained with hematoxylin and eosin, periodic acid–Schiff, silver methenamine, and Masson trichrome. For IF studies, frozen-tissue sections are labeled with the direct fluorescein isothiocyanate-conjugated antibodies against human IgG, IgA, IgM, C3, C4, C1q, and fibrinogen. Tissue for EM studies is fixed in Trump's fixative (glutaraldehyde and formalin) followed by postfixation in 2% osmium tetroxide, dehydrated in graded ethanol, processed through propylene oxide, and then embedded in resin blocks. Ultrathin sections were stained with uranyl acetate and lead citrate and then examined and photographed with the FEI Morgagni transmission electron microscope. All cases are examined by the same ultrastructural pathologist.

After retrieving the cases by reports, the archived EM images were examined. The previously examined glomeruli were checked to confirm the presence of subepithelial deposits. The podocytes were examined on the EM photographs or reexamination on the electron microscope when the archived photographs did not provide the needed criteria. The case inclusion criteria were cases with at least one nonsclerotic glomerulus examined, providing minimum ten patent capillary loops along with intact properly preserved cells. Cases with fixation artefact were omitted from the evaluation.

### Ethical Statement

The research is approved in the Pathology department board meeting - no. 128482/40 /d; Date 28 / 12 / 1440 Hijra (30/8/2019). Approved by the Dean of the College of Medicine; King Abdulaziz University - Approval no.128482/40 /d / 9; Date 11/ 01/ 1441 Hijra (11/09/2019). Consent forms are signed by patients before the renal biopsy which includes agreement to use tissue biopsies and patient's data for education and research purposes. The procedures follows the guidelines laid down in Declaration of Helsinki (year 2013).

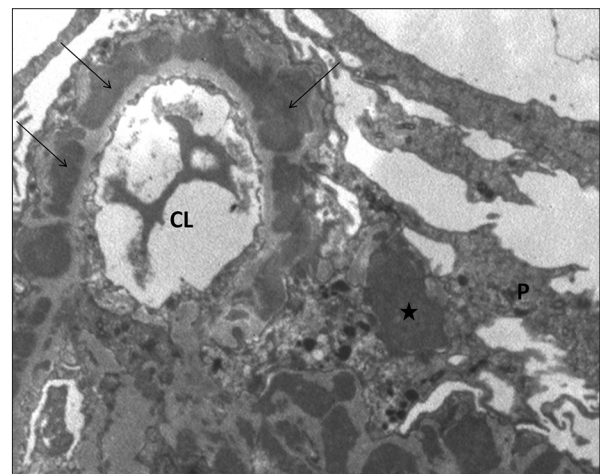
### RESULTS

All the cases selected for the study are confirmed to exhibit subepithelial dense deposits. Ultrastructural examination of podocytes reveals ICDIs in one-third of MGN, PIGN, and LN Class (II, III, IV, and V) cases. The number of cases per GN

**Table 1: Number of cases with or without podocytes dense inclusions**

GN type	Podocytes dense inclusions ( $n=148$ )		
	Present	Nil	Ratio Present: nil
MGN	10	21	1:2.1
PIGN	13	20	1:1.5
LN-II	3	9	1:3
LN-III	3	5	1:1.7
LN-IV	9	25	1:2.8
LN-V	10	20	1:2
Total	48	100	1:2

GN: Glomerulonephritis, MGN: Membranous GN, PIGN: Postinfectious GN, LN: Lupus nephritis

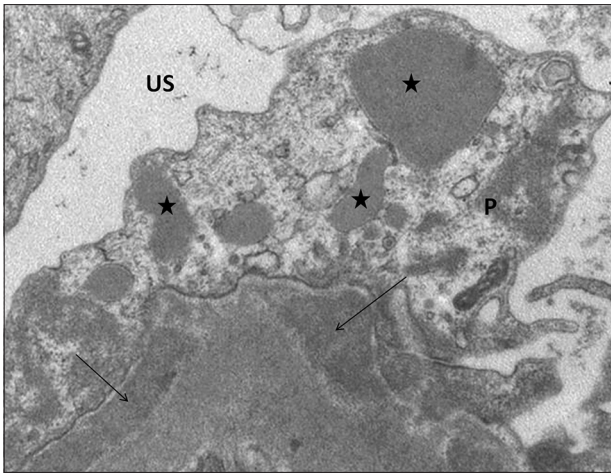


**Figure 1:** Transmission electron micrograph of membranous glomerulonephritis case showing a glomerular capillary loop and part of the mesangial matrix. There are numerous subepithelial dense deposits indicated by the thin arrow. The podocyte contains intracytoplasmic dense inclusions indicated by the star. CL: Capillary lumen, P: Podocyte

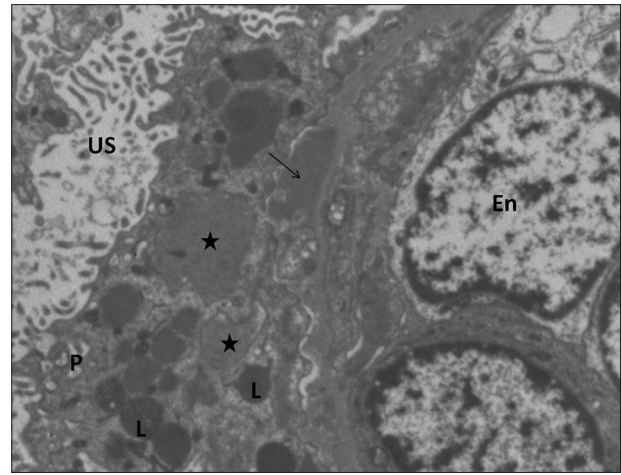
type is listed in Table 1. PIGN shows the highest number of positive case ratio, whereas LN-II shows the least.

Figures 1-6 are transmission electron micrographs (TEMs) of podocytes-containing ICDIs from various cases in the study. The podocytes ICDIs are membrane bound of variable densities, shapes, and sizes; they closely match the ultrastructural criteria of the adjacent subepithelial dense deposits of the same case. In some cases, the podocytes demonstrate foot processes effacement, and occasionally, cytoskeleton condensation in the areas adjacent to the subepithelial dense deposits.

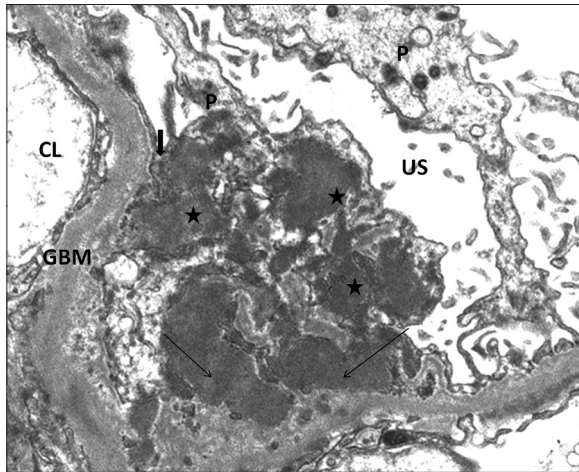
The ultrastructural morphology of subepithelial deposits varies in the different GN types selected in the study. In cases of MGN, numerous dense deposits are observed in subepithelial areas. Cases of PIGN demonstrate large, scattered hump-like dense deposits in subepithelial areas. Few cases demonstrate small subendothelial and mesangial dense deposits. LN morphology corresponds



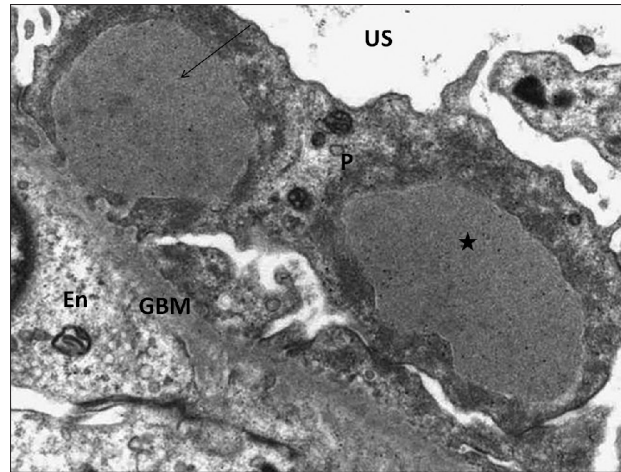
**Figure 2:** Transmission electron micrograph from a case of lupus nephritis III showing part of glomerular basement membrane with large subepithelial dense deposits indicated by thin arrow, and podocyte exhibiting variable size membrane bound intracytoplasmic dense inclusions (star). US: Urinary space, P: Podocyte



**Figure 3:** A case of lupus nephritis IV, the transmission electron micrograph presenting part of a capillary loop with subepithelial dense deposit indicated by the thin arrow. The podocyte exhibits variable size intracytoplasmic dense inclusions (star) and smaller darker lysosome vesicles (L). US: Urinary space, P: Podocyte, En: Endothelial cells



**Figure 4:** Transmission electron micrograph of a lupus nephritis V case, showing GBM with large subepithelial dense deposits marked by the thin arrow and variable size podocyte intracytoplasmic dense inclusions (star). The podocyte cytoplasmic process partially encircling the dense deposit demonstrated by thick arrow. CL: Capillary lumen, US: Urinary space, P: Podocyte, GBM: Glomerular basement membrane



**Figure 5:** A case of postinfectious glomerulonephritis, the transmission electron micrograph illustrates a huge subepithelial hump-like dense deposit marked by the thin arrow. The podocyte displays a similar enormous intracytoplasmic dense inclusion (star). US: Urinary space, P: Podocyte, En: Endothelial cells; GBM: Glomerular basement membrane

to the LN Class (ISN/RPS LN classification):<sup>[11]</sup> LN-II mainly mesangial deposits and few subepithelial deposits; LN-III focal subendothelial and mesangial deposits and few subepithelial deposits; LN-IV subendothelial, mesangial, and few subepithelial dense deposits; LN Class V is mainly subepithelial membranous pattern with few mesangial and subepithelial dense deposits.

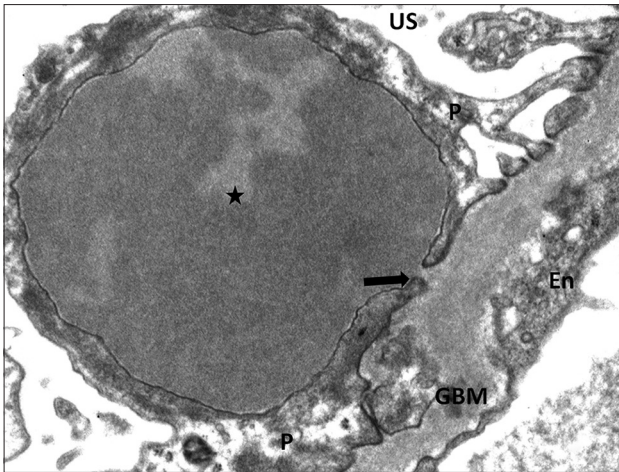
## DISCUSSION

The current study describes podocyte ICDIs in a variety of GN that exhibit subepithelial dense deposits of immune complex nature, in addition to dense deposits in other sites according to the GN type: MGN, PIGN, and LN Classes

II–V LN. One-third of these cases have expressed podocytes ICDI; its presence is not related to GN type but observed more in PIGN.

The morphological resemblance of podocytes' ICDIs to the adjacent subepithelial dense deposits supports the notion that these inclusions are internalized dense deposits. Experimental researches demonstrated that podocytes have the ability to internalize immune complexes.

The podocytes are suggested to participate in the removal of immune complex deposits in the glomerulus through different mechanisms such as complement factors, excess antigen, and monovalent antibodies.<sup>[10,12-14]</sup>

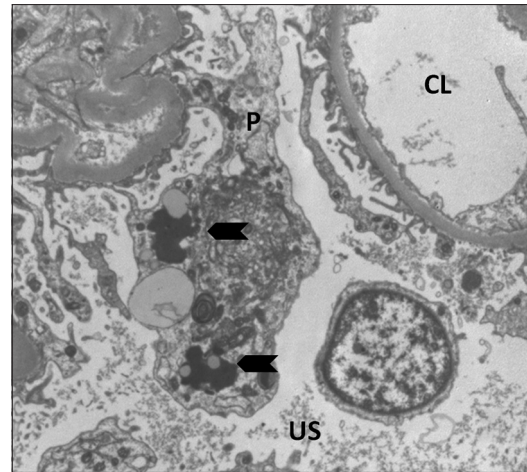


**Figure 6:** From the same case as Figure 5, transmission electron micrograph of a huge hump-like dense deposit inside the podocyte representing the intracytoplasmic dense inclusion (star). The podocyte cytoplasmic process encircles the dense deposit leaving a thin attachment point of the deposit to the GBM (thick arrow). US: Urinary space, P: Podocyte, En: Endothelial cell, GBM: Glomerular basement membrane

Podocytes play a dynamic role in clearing aggregated proteins preventing clogging the filtration barrier. Animal studies have revealed that podocytes internalization of IgG is facilitated by the presence of FcRn, an IgG, and albumin transport receptor in podocytes.<sup>[2]</sup> Furthermore, podocytes cell line studies demonstrated that podocytes express various complement factors and complement receptors.<sup>[15]</sup> In an animal model of immune complex GN, the podocytes expressed the complement factor CFH and facilitated the removal of glomerular subepithelial and subendothelial immune complexes.<sup>[3]</sup>

Earlier studies on cultured podocytes revealed that these cells have the ability to dispose of immune complexes created on their surface provided that the antibodies are monovalent. However, multivalent antibodies immune complexes are handled differently; the cells are much slower in the removal process, resulting in the accumulation of immune complexes. The concept that podocytes internalize and remove proteins has been suggested by multiple studies under various conditions in a process known as endocytosis.<sup>[16-18]</sup> The immune complexes on the surface of podocytes are proposed to be internalized by the same process, and the membrane limited inclusions “endosomes” are taken in to be processed and dispose of by the cells.<sup>[10]</sup>

Unlike autophagosomes, in which podocyte cytoplasm inclusion results from autophagy and delivers damaged cellular proteins to lysosomes to maintain cellular integrity and organelles turnover; the podocyte ICDIs do not contain condensed ribosomes or lipid vacuoles; Figure 7 shows autophagosomes from the study cases.<sup>[19,20]</sup> In addition, the podocytes inclusions in this study have the same electron density as the adjacent subepithelial immune complexes.



**Figure 7:** Transmission electron micrograph of a patent capillary loop and part of a podocyte cytoplasm. The podocyte contains autophagosomes (arrow head). CL: Capillary lumen, US: Urinary space, P: Podocyte

To the best of my knowledge, this is the first ultrastructural study of human immune complex GN that actually captures podocytes ICDIs and links them to the subepithelial dense deposits. Immunolabeling studies of these inclusions at the ultrastructural level would further elucidate their nature. Furthermore, clinical correlation studies are needed to reveal the significance of this ultrastructural finding in the evolution, progression, and outcome of GN.

## CONCLUSION

The presence of podocytes ICDIs may represent internalized immune complexes from the glomerular dense deposits which could be part of the podocytes vital role in clearing the glomerular basement membrane and prevent clogging of the filtration system.

## Financial support and sponsorship

Nil.

## Conflicts of interest

There are no conflicts of interest.

## REFERENCES

1. Pavenstädt H, Kriz W, Kretzler M. Cell biology of the glomerular podocyte. *Physiol Rev* 2003;83:253-307.
2. Akilesh S, Huber TB, Wu H, Wang G, Hartleben B, Kopp JB, *et al.* Podocytes use FcRn to clear IgG from the glomerular basement membrane. *Proc Natl Acad Sci U S A* 2008;105:967-72.
3. Alexander JJ, Wang Y, Chang A, Jacob A, Minto AW, Karmegam M, *et al.* Mouse podocyte complement factor H: The functional analog to human complement receptor 1. *J Am Soc Nephrol* 2007;18:1157-66.
4. Gassler N, Elger M, Kränzlin B, Kriz W, Gretz N, Hähnel B, *et al.* Podocyte injury underlies the progression of focal segmental glomerulosclerosis in the fa/fa Zucker rat. *Kidney Int* 2001;60:106-66.
5. Wiggins RC. The spectrum of podocytopathies: A unifying view of glomerular diseases. *Kidney Int* 2007;71:1205-14.
6. Chen HM, Liu ZH, Zeng CH, Li SJ, Wang QW, Li LS. Podocyte lesions in patients with obesity-related glomerulopathy. *Am J Kidney Dis* 2006;48:772-9.
7. Cybulsky AV, Quigg RJ, Salant DJ. Experimental membranous

- nephropathy redux. *Am J Physiol Renal Physiol* 2005;289:F660-71.1.
8. Berger SP, Daha MR. Complement in glomerular injury. *Semin Immunopathol* 2007;29:375-84.
  9. Takano T, Elimam H, Cybulsky AV. Complement-mediated cellular injury. *Semin Nephrol* 2013;33:586-601.
  10. Singh AK, Kasinath BS. Metabolic fate of monovalent and multivalent antibodies of Heymann nephritis following formation of surface immune complexes on glomerular epithelial cells. *Clin Exp Immunol* 1993;94:403-11.
  11. Markowitz GS, D'Agati VD. The ISN/RPS 2003 classification of lupus nephritis: An assessment at 3 years. *Kidney Int* 2007;71:491-55.
  12. Zoshima T, Hara S, Yamagishi M, Pastan I, Matsusaka T, Kawano M, *et al.* Possible role of complement factor H in podocytes in clearing glomerular subendothelial immune complex deposits. *Sci Rep* 2019;9:7857.
  13. Furness PN. The formation and fate of glomerular immune complex deposits. *J Pathol* 1991;164:195-202.
  14. Fujigaki Y, Nagase M, Kojima K, Yamamoto T, Hishida A. Glomerular handling of immune complex in the acute phase of active *in situ* immune complex glomerulonephritis employing cationized ferritin in rats. Ultrastructural localization of immune complex, complements and inflammatory cells. *Virchows Arch* 1997;431:53-61.
  15. Li X, Ding F, Zhang X, Li B, Ding J. The expression profile of complement components in podocytes. *Int J Mol Sci* 2016;17:471.
  16. Qin XS, Tsukaguchi H, Shono A, Yamamoto A, Kurihara H, Doi T. Phosphorylation of nephrin triggers its internalization by raft-mediated endocytosis. *J Am Soc Nephrol* 2009;20:2534-45.
  17. Swiatecka-Urban A. Endocytic trafficking at the mature podocyte slit diaphragm. *Front Pediatr* 2017;5:32.
  18. Inoue K, Ishibe S. Podocyte endocytosis in the regulation of the glomerular filtration barrier. *Am J Physiol Renal Physiol* 2015;309:F398-405.
  19. Sato S, Kitamura H, Adachi A, Sasaki Y, Ghazizadeh M. Two types of autophagy in the podocytes in renal biopsy specimens: Ultrastructural study. *J Submicrosc Cytol Pathol* 2006;38:167-74.
  20. Hartleben B, Gödel M, Meyer-Schwesinger C, Liu S, Ulrich T, Köbler S, *et al.* Autophagy influences glomerular disease susceptibility and maintains podocyte homeostasis in aging mice. *J Clin Invest* 2010;120:1084-96.