



Tingles down the spinal cord: A spinal functional magnetic resonance imaging investigation of the autonomous sensory meridian response

Stephen D. Smith 

University of Winnipeg, Canada

Tiffany A. Kolesar

University of Manitoba, Canada

Beverley K. Fredborg

Ryerson University, Canada

Jennifer Kornelsen

University of Winnipeg, Canada; University of Manitoba, Canada

Abstract

Autonomous sensory meridian response (ASMR) is a perceptual and emotional phenomenon in which specific sensory stimuli elicit a feeling of calm as well as tingling sensations on the scalp, neck, and shoulders. In the current study, we use fMRI to examine whether the motoric and sensory regions of the spinal cord segments associated with these body parts show increased activity during ASMR experiences. Nine individuals with ASMR completed six spinal functional magnetic resonance imaging runs while passively viewing videos. Three of the videos were shown (through pre-testing) to elicit ASMR tingles and three videos did not (i.e., control videos). The results demonstrated that ASMR-related stimuli elicited activity in dorsal (sensory) regions of spinal cord segments C1, C5, and C6; activity was observed in ventral (motoric) regions of segments C2–C8. Similar activity was not detected in response to control videos.

Keywords

autonomous sensory meridian response, multimodal integration, body perception, spinal fMRI, cervical spinal cord

Date Received: 23 January 2022; accepted: 19 April 2022

Corresponding author:

Stephen D. Smith, Department of Psychology, University of Winnipeg, Winnipeg, Manitoba R3B 0E9, Canada.

Email: s.smith@uwinnipeg.ca

The autonomous sensory meridian response (ASMR) is a multimodal perceptual phenomenon that has some similarities to synesthesia and musical frisson. Individuals who experience ASMR report that specific sensory “ASMR triggers,” such as whispering, consistently elicit tingling sensations on the scalp, neck, and shoulders, sometimes radiating down the back and limbs (Barratt & Davis, 2015). These physical sensations are typically paired with a feeling of calmness and emotional positivity (Poerio et al., 2018). Since it was first discussed on online forums in 2010, ASMR has received an increasing amount of attention from the media—who frequently refer to ASMR as a “brain orgasm”—as well as from researchers. The focus of many of these studies has been on identifying personality (e.g., Janik McErlean & Banissy, 2017) and biological differences (e.g., Smith et al., 2019a) between individuals who are sensitive to ASMR stimuli and those who are not. Notably, there is an increasing interest in delineating the neural activity associated with the ASMR experience itself.

To date, three functional neuroimaging studies have attempted to characterize the neural activity that occurs during the ASMR experience. An electroencephalography (EEG) study reported an increase in frontal midline alpha activity during the experience of ASMR tingles; this response is similar to that observed during some meditative states (Fredborg et al., 2021). An increase in gamma frequency activity was also observed over sensorimotor regions, a result that is consistent with the experience of somatosensory tingles. Two studies using functional magnetic resonance imaging (fMRI) both noted increased activity in the anterior cingulate gyrus and sensorimotor cortical regions during the viewing of ASMR-eliciting videos (Lochte et al., 2018; Smith et al., 2019b).

The fact that it was possible to identify ASMR-dependent changes in brain activity led us to consider whether additional techniques could be used to more precisely link neural activity to the sensory experiences reported by ASMR participants. The regions of the body that are reportedly affected by ASMR “tingles” are innervated by the upper and middle segments of the cervical spinal cord. Advances in fMRI techniques now allow researchers to reliably detect activity in neurons in these spinal cord regions (see Powers et al., 2018 for a review). Such a technique should therefore be ideal for measuring the sensory-emotional tingling experiences that occur on the scalp, shoulders, and upper back during ASMR.

To assess this possibility, nine individuals from our earlier research completed a spinal fMRI study whose procedure was identical to that used in our previous task-based brain fMRI experiment (Smith et al., 2019b). This experiment consisted of six 5-min fMRI runs (60-s fixation cross followed by a 4-min video). In three of the fMRI runs, participants viewed 4-min videos designed to elicit ASMR tingles; in the other three fMRI runs, the videos that were presented were not associated with ASMR (i.e., these were “control” stimuli). Participants indicated the intensity of their ASMR tingles following the scan. The two fMRI runs with the highest intensity ASMR response as well as two control videos were used for analyses. The last half of each video was analyzed to ensure the ASMR tingles were occurring. Spinal fMRI data were acquired using a HASTE scanning sequence identical to that used in our previous investigations of the emotional modulation of spinal cord activity (e.g., Wilson et al., 2018): 44 volumes, nine 2 mm slices; TR = 6750 ms; TE = 76 ms; resolution = 1.04×1.04 mm; FOV = 200 mm \times 100 mm. Data were preprocessed with motion correction, coil alignment, spatial normalization, and smoothing in the rostral-caudal direction. Preprocessed data were analyzed at the individual and group level using the General Linear Model to compare the ASMR-eliciting videos and the control videos to baseline.

The results were consistent with our hypotheses (see Figure 1). ASMR-related stimuli elicited activity in the brainstem as well as in dorsal (sensory) regions of spinal cord segments C1, C5, and C6; activity was observed in ventral (motoric) regions of segments C2–C8. These spinal cord segments innervate the head (scalp), neck, shoulders, and upper limbs, *the same regions associated with self-reported ASMR tingles*. Importantly, these responses did not occur for “control” videos, suggesting that the activity was related to the sensations being experienced by the participants.

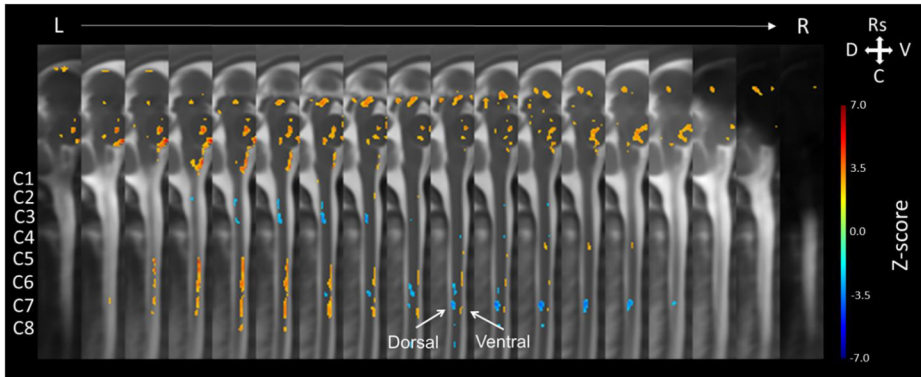


Figure 1. The group-level results are displayed on sagittal slices spanning from the left side of the cord to the right side of the cord as indicated at the top of the figure. Voxels in orange represent significant activity for the ASMR videos > baseline. Abbreviations: Rs = rostral, C = caudal, D = dorsal, V = ventral, R = right, and L = left localization.

The current study, although limited by a small sample size, suggests that it is possible to measure embodied sensory responses during ASMR using spinal fMRI. The increased cervical spinal cord activity detected during ASMR-inducing videos is consistent with the stimulus-dependent sensorimotor responses associated with the ASMR phenomenon. The current data, therefore, allow one to conclude that the tingling down the spine that is often reported during ASMR is actually tingling down the spinal cord.

Acknowledgements

This research was supported by a grant from the Natural Sciences and Engineering Research Council of Canada.

Declaration of Conflicting Interests

The authors declared no potential conflicts of interest with respect to the research, authorship, and/or publication of this article.

Funding

The authors disclosed receipt of the following financial support for the research, authorship, and/or publication of this article: This work was supported by the Natural Sciences and Engineering Research Council of Canada (grant no. RGPIN-2014-03928).

ORCID iD

Stephen D. Smith  <https://orcid.org/0000-0002-9028-8372>

References

- Barratt, E. L., & Davis, N. J. (2015). Autonomous sensory meridian response (ASMR): A flow-like mental state. *PeerJ*, 3, e851. <https://doi.org/10.7717/peerj.851>
- Fredborg, B. K., Champagne-Jorgensen, K., Desroches, A. S., & Smith, S. D. (2021). An electroencephalographic examination of the autonomous sensory meridian response (ASMR). *Consciousness & Cognition*, 87, 103053. <https://doi.org/10.1016/j.concog.2020.103053>

- Janik McErlean, A. B., & Banissy, M. J. (2017). Assessing individual variation in personality and empathy traits in self-reported autonomous sensory meridian response. *Multisensory Research*, 30(6), 601–613. <https://doi.org/10.1163/22134808-00002571>
- Lochte, B. C., Guillory, S. A., Richard, C. A. H., & Kelley, W. M. (2018). An fMRI investigation of the neural correlates underlying the autonomous sensory meridian response (ASMR). *BioImpacts: BI*, 8(4), 295–304. <https://doi.org/10.15171/bi.2018.32>
- Poerio, G. L., Blakey, E., Hostler, T. J., & Veltri, T. (2018). More than a feeling: Autonomous sensory meridian response (ASMR) is characterized by reliable changes in affect and physiology. *PLoS ONE*, 13(6), e0196645. <https://doi.org/10.1371/journal.pone.0196645>
- Powers, J. M., Ioachim, G., & Stroman, P. W. (2018). Ten key insights into the use of spinal cord fMRI. *Brain Sciences*, 8(9), 173. <https://doi.org/10.3390/brainsci8090173>
- Smith, S. D., Fredborg, B. K., & Kornelsen, J. (2019a). Atypical functional connectivity associated with autonomous sensory meridian response (ASMR): An examination of five resting-state networks. *Brain Connectivity*, 9(6), 508–518. <https://doi.org/10.1089/brain.2018.0618>
- Smith, S. D., Fredborg, B. K., & Kornelsen, J. (2019b). A functional MRI investigation of the autonomous sensory meridian response (ASMR). *PeerJ*, 7, e7122. <https://doi.org/10.7717/peerj.7122>
- Wilson, A. D., Kolesar, T. A., Kornelsen, J., & Smith, S. D. (2018). Neural responses to consciously and unconsciously perceived emotional faces: A spinal fMRI study. *Brain Sciences*, 8(8), e156. <https://doi.org/10.3390/brainsci8080156>