

# Intraorbital Solitary Fibrous Tumor Requiring Preoperative Embolization of Feeding Artery

## Abstract

Solitary fibrous tumors (SFTs) are derived from mesenchymal cells and commonly develop in thoracoabdominal organs; however, their occurrence in orbit is rare. The first-choice treatment is to surgically remove as much of the SFT as possible; however, if total removal is not achieved, the recurrence rate is high, resulting in poor prognosis. A 42-year-old man presented with painless right-sided proptosis and diplopia 4 years ago. Orbital computed tomography revealed a right extraconal mass medial to the optic nerve, measuring 25 mm. Magnetic resonance imaging demonstrated iso-signal intensity on T1- and T2-weighted imaging, including flow-void signals. During biopsy of the intraorbital mass, which was performed by ophthalmologists 3 years earlier, difficulty with hemostasis occurred due to massive hemorrhage from the mass. The mass grew to reach a maximal diameter of 33 mm, resulting in referral to the authors' department. Diagnostic cerebral angiography revealed a hypervascular orbital tumor with multiple feeding arteries. To control intraoperative bleeding, the patient underwent preoperative endovascular embolization. Subsequently, the tumor was completely removed using a combination of microsurgical craniotomy and endoscopic endonasal approach, without the occurrence of massive intraoperative hemorrhage from the tumor. Postoperatively, his clinical course was uneventful except for the remaining preoperative diplopia. The tumor was diagnosed histologically as SFT and has not recurred for 8 months since surgery. Preoperative intravascular embolization of branches of the ophthalmic artery can be performed safely, resulting in excellent control of intraoperative bleeding and facilitating complete removal of SFT without additional complications.

**Keywords:** Craniotomy, intraorbital tumor, preoperative embolization, removal, solitary fibrous tumors

## Introduction

Solitary fibrous tumors (SFTs) are rare tumors derived from mesothelial cells or fibroblasts and are prevalent among individuals aged 60–70 years. Although SFTs are often found in the pleura, peritoneum, liver, kidney, and mediastinum, their occurrence in the orbit space is quite uncommon.<sup>[1-3]</sup> According to the 2016 World Health Organization classification, SFTs are grouped under the same category as hemangiopericytomas.<sup>[4]</sup> The malignancy grade ranges from 1 to 3, and the MIB-1 positive rate in pathology correlates well with tumor growth speed.<sup>[5]</sup> The first-choice treatment is to surgically remove as much of the tumor as possible; however, incomplete removal of a tumor through surgery leads to a high risk of recurrence, and the tumor could spread to other parts of the body. In

addition, radiation and chemotherapy are both ineffective; consequently, complete excision is necessary for cure.<sup>[1,3,6,7]</sup> In general, large SFTs are often highly vascular, and preoperative embolization is required to control intraoperative bleeding.<sup>[3,8]</sup> However, due to the risk of complications such as loss of visual acuity, reports describing embolization of orbital tumors are very few.

In the present case, a large progressive orbital SFT (maximum diameter, 33 mm) was so rich in blood flow that embolization of the feeding artery from the ophthalmic artery was considered necessary to achieve total removal.

## Case Report

A 42-year-old man presented with painless proptosis and diplopia, which had progressed gradually over 4 years. He was referred to the Department of

**Munehiro Demura,  
Yasuhiko Hayashi,  
Yasuo Sasagawa,  
Masanao Mohri,  
Masayuki Takahira<sup>1</sup>,  
Mitsutoshi Nakada**

*Departments of Neurosurgery  
and <sup>1</sup>Ophthalmology, Graduate  
School of Medical Science,  
Kanazawa University,  
Kanazawa, Japan*

**Address for correspondence:**  
Dr. Yasuhiko Hayashi,  
13-1 Takara-Machi, Kanazawa,  
Ishikawa, 920-8641, Japan.  
E-mail: yahayashi@med.  
kanazawa-u.ac.jp

### Access this article online

**Website:** www.asianjns.org

**DOI:** 10.4103/ajns.AJNS\_30\_19

### Quick Response Code:



**How to cite this article:** Demura M, Hayashi Y, Sasagawa Y, Mohri M, Takahira M, Nakada M. Intraorbital solitary fibrous tumor requiring preoperative embolization of feeding artery. *Asian J Neurosurg* 2019;14:593-7.

This is an open access journal, and articles are distributed under the terms of the Creative Commons Attribution-NonCommercial-ShareAlike 4.0 License, which allows others to remix, tweak, and build upon the work non-commercially, as long as appropriate credit is given and the new creations are licensed under the identical terms.

**For reprints contact:** reprints@medknow.com

Ophthalmology at our institute. Examination revealed congestion of the bulbar conjunctiva and restricted adduction of the eyeball on the right side. No visual impairment was found on neurological examination. Orbital computed tomography (CT) revealed a right extraconal mass measuring 25 mm × 16 mm × 25 mm, located medially to the optic nerve [Figure 1a]. Magnetic resonance (MR) imaging of the mass demonstrated iso-intensity on both T1- and T2-weighted images, containing flow-void signals within the mass [Figure 1b and c]. The mass was irregularly enhanced with contrast medium, and a dynamic study demonstrated early filling and delayed washout, indicating rich vascularity. A biopsy of the tumor was performed and pathological analysis of the specimen revealed SFT. During biopsy, onset of massive hemorrhage from the mass made it difficult to achieve complete hemostasis. Subsequently, the tumor grew to 30 mm × 19 mm × 33 mm in size and extended to the ethmoid sinus [Figure 1d].

The patient was transferred to our department for removal of the tumor via craniotomy. Surgical removal of the tumor was planned after confirming the absence

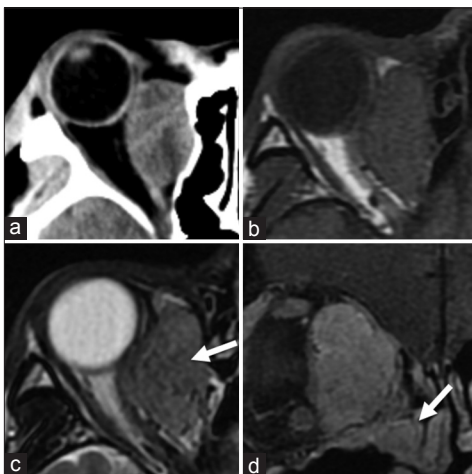
of metastasis throughout the body. Preoperative cerebral angiography revealed that the tumor was hypervascular, with feeder vessels arising from the infra- and supra-orbital arteries and a muscular branch originating from the right ophthalmic artery [Figure 2a and b]. Due to the potential risk of uncontrollable intraoperative hemorrhage, preoperative endovascular embolization using a coil and n-butyl-2-cyanoacrylate (NBCA) was planned. We embolized feeder vessels arising from the ophthalmic artery with coil and the infraorbital artery with NBCA. The procedure was completed successfully with considerable decrease in vascularization without visual complications [Figure 2c].

Surgical removal of the tumor was planned for the following day, along with otolaryngologists. To approach the tumor, a frontal craniotomy was performed by neurosurgeons and an endoscopic transnasal approach to the right orbit was established by otolaryngologists. The right orbital rim and roof were removed in a one-piece fashion. Intraoperatively, the tumor capsule was opened to reveal the fibrous characteristics of the tumor, which was completely removed in a piecemeal manner because the tumor was too large to achieve *en bloc* resection. The volume of intraoperative bleeding was limited to only 180 mL.

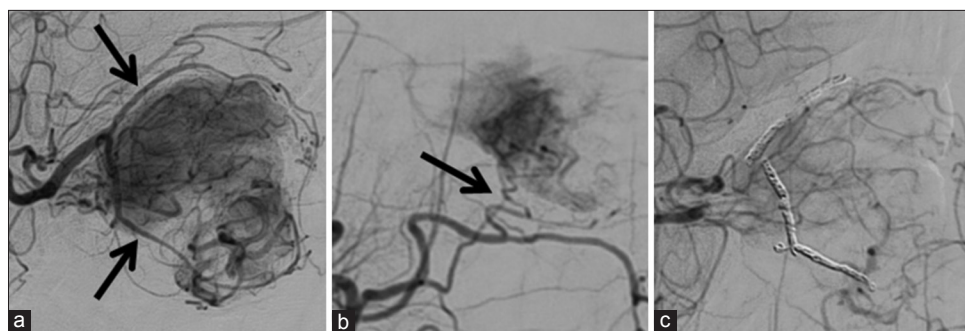
Histological analysis revealed that the mass consisted of spindle cells in a random pattern, with collagen fibers and staghorn-like vascular pattern [Figure 3a and b]. Immunohistochemical staining for CD34 and STAT6 was strongly positive [Figure 3c and d]. The MIB-1 positive rate was 2%–4% [Figure 3e], and the tumor was reconfirmed to be an SFT. Postoperatively, however, proptosis and diplopia did not improve. MR imaging confirmed that the tumor had been totally removed and has not recurred for 8 months since the operation [Figure 4a and b].

## Discussion

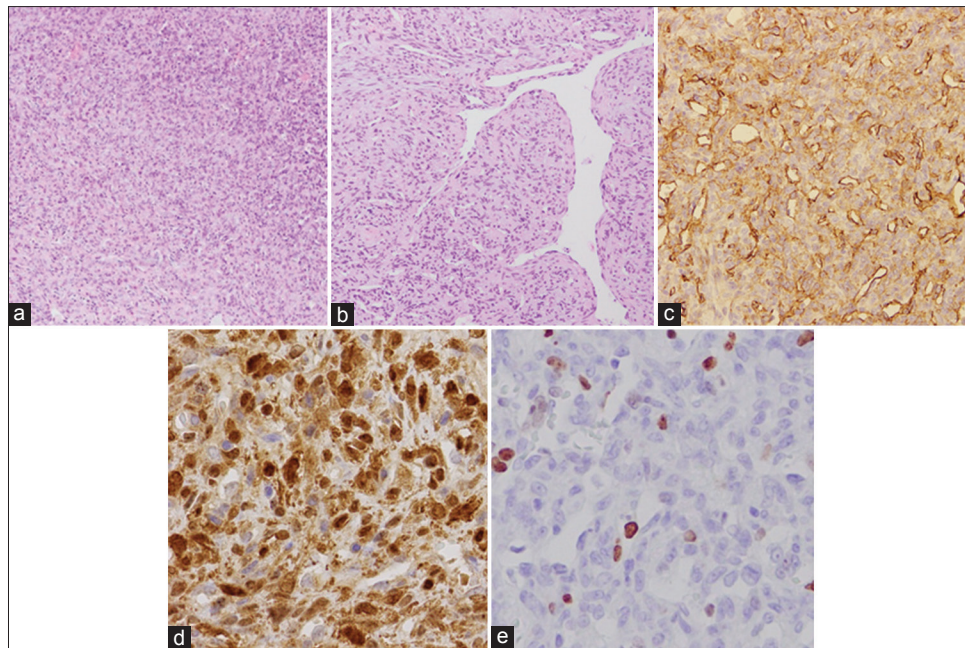
We present a very rare case of a large orbital SFT with significant hypervascularity fed by branches from the ophthalmic artery, which were embolized successfully using an endovascular procedure. This tumor was completely



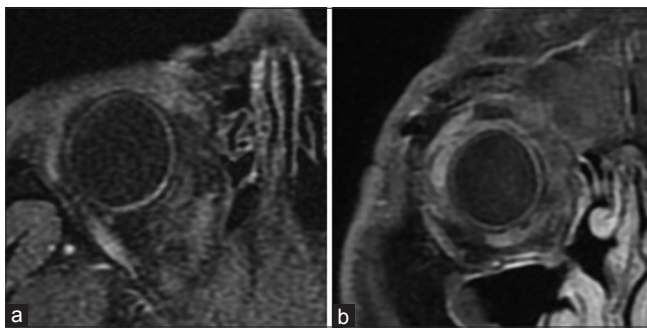
**Figure 1:** (a) Preoperative plain computed tomography scan of the right orbit revealing an extraconal large mass, located medially to the optic nerve. (b) T1-weighted magnetic resonance image revealing iso-intensity in the mass. (c) T2-weighted magnetic resonance image revealing multiple flow-void signals contained within the mass (arrow). (d) The tumor has substantial growth and has extended to the ethmoid sinus



**Figure 2:** (a) Cerebral angiogram demonstrating the supraorbital artery and muscular branch originating from the right ophthalmic artery flowing into the tumor (arrows). (b) Feeding vessel arising from the infraorbital artery (arrow). (c) Preoperative endovascular embolization has been achieved successfully with significant decrease in vascular supply



**Figure 3:** Results of pathological examination of the tumor. (a) The mass consists of spindle cells in a random pattern, with collagen fiber and (b) staghorn-like vascular pattern (H and E staining,  $\times 100$ ). (c) Immunohistochemical staining, with CD34 positive for tumor cells. (d) STAT6 is strongly positive for the nuclei of the tumor cells. (e) The MIB-1 positive rate is 2%–4% (a and b,  $\times 100$ ; c-e,  $\times 300$ )



**Figure 4:** Postoperative axial (a) and coronal (b) magnetic resonance images confirming nonrecurrence of the solitary fibrous tumor 8 months since surgery

removed via a combined transcranial microscopic and transnasal endoscopic approach, without developing massive intraoperative bleeding.

SFT is an uncommon neoplasm that is derived from mesothelial or fibroblast-like mesenchymal cells and can develop in many locations in the body.<sup>[1-3]</sup> However, intraorbital occurrence has been so rare that, to date, approximately 90 cases have been reported.<sup>[9]</sup> The definitive diagnosis of SFT is dependent on characteristic histopathological findings, such as the proliferation of spindle cells, the absence of a specific sequence pattern, and the presence of a staghorn-like vascular pattern, with immunohistological findings positive for CD34, STAT6, Bcl-2, vimentin, and CD99.<sup>[1,2,10]</sup> Among these, positive nucleus staining with STAT6 is available for definitive diagnosis of SFT. The histological findings in our case were compatible with the findings described above,

confirming the diagnosis of SFT in this rare occurrence as an intraorbital tumor.

SFT occasionally presents as clinical recurrence and is thus categorized as an “intermediate malignancy” under the WHO Classification of soft-tissue tumors. The latest version of the WHO Classification in 2016 placed SFT in the same category as hemangiopericytoma.<sup>[4]</sup> Therefore, the most effective treatment for SFT is surgical removal of the tumor to the maximum possible extent.<sup>[1,4,6,7]</sup> In addition, the hemodynamic characteristics must be understood to minimize the risk of intraoperative hemorrhage. In cases involving large tumors, intratumoral blood flow is often abundant, which makes it difficult to remove the tumor; therefore, preoperative embolization is recommended. Although there are some reports of embolization for SFTs, only three cases of embolization for intraorbital SFTs have been described [Table 1]. When we reviewed these reports in detail, the tumors were large and predictably rich in blood flow according to physical examination, angiography, and MR imaging.<sup>[11-13]</sup> After successful preoperative endovascular embolization, the tumors were removed completely without the occurrence of massive intraoperative hemorrhage. In addition, embolization of feeder vessels arising from the ophthalmic artery carries the risk of complications such as visual dysfunction. In our case, embolization was achieved without serious complications such as occlusion of the central retinal artery.

In this case, we selected coil and NBCA as embolic materials. We already knew in advance that the tumor was highly vascular. Therefore, NBCA was selected to control intraoperative bleeding because it has high hemostatic

**Table 1: Characteristics of previously reported intraorbital solitary fibrous tumors and present case performed embolization of feeding arteries before tumor removal**

	<b>Kishimoto (2014)</b>	<b>Nafiseh (2015)</b>	<b>Kaitlyn (2015)</b>	<b>Present case (2017)</b>
Age/sex	75/male	55/female	58/female	42/male
Symptom	Proptosis, swelling	Proptosis, swelling, diplopia	Proptosis	Proptosis
Diameter (mm)	38	27	48	33
Feeding artery	Ophthalmic A, Infraorbital A	Ciliary A	Ophthalmic A	Supraorbital A, Infraorbital A, muscular Br
Embolic material	Coil	Onyx	NBCA	Coil, NBCA
Blood loss	Little	Unknown	20 ml	180 ml
Removal rate	Total	Total	Total	Total

NBCA – n-butyl-2-cyanoacrylate

effect.<sup>[14]</sup> Meanwhile, NBCA has a risk of reflux into the proximal portion of feeder vessels during injection.<sup>[15]</sup> To prevent the occlusion of the right ophthalmic artery by refluxed NBCA, first, we embolized feeder vessels arising from it with a coil. And then, NBCA was successfully injected into the infraorbital artery from the maxillary artery.

To remove a large or giant orbital tumor, it is very difficult to dissect the boundary between the inferior part of the tumor and the surrounding structures.<sup>[11]</sup> Moreover, a transnasal approach using an endoscope does not enable visualization and dissection of the inferior part of the tumor. In our case, a combined microscopic transcranial and endoscopic transnasal approach was successfully used to completely remove the tumor. The nasal approach not only facilitated dissection of the tumor surroundings but also secured views at different angles and helped to establish anatomical orientation in the orbit. To the best of our knowledge, there have been no reports describing a two-way approach to an intraorbital SFT similar to ours. This combined method clearly demonstrates its benefit in compensating for blinded areas in the transcranial approach.

Histological findings included polymorphism of cells and nuclei, necrosis, and a MIB-1 positive rate, which led to the diagnosis of malignancy. As adjunctive therapy, postoperative radiation has been recommended for residual tumor tissue.<sup>[13]</sup> If total removal of the tumor is achieved – as in our case – radiation therapy is reserved for recurrence, and long-term follow-up is essential.

## Conclusion

We were able to completely remove a large SFT from the orbit safely by performing preoperative endovascular embolization to avoid massive intraoperative bleeding. In addition, a combined transcranial and transnasal approach can provide advantages for tumor removal and helps eliminate blinded area(s) to a great extent.

## Declaration of patient consent

The authors certify that they have obtained all appropriate patient consent forms. In the form, the patient has given

his consent for his images and other clinical information to be reported in the journal. The patient understands that his name and initials will not be published and due efforts will be made to conceal identity, but anonymity cannot be guaranteed.

## Financial support and sponsorship

Nil.

## Conflicts of interest

There are no conflicts of interest.

## References

1. Krishnakumar S, Subramanian N, Mohan ER, Mahesh L, Biswas J, Rao NA, *et al.* Solitary fibrous tumor of the orbit: A clinicopathologic study of six cases with review of the literature. *Surv Ophthalmol* 2003;48:544-54.
2. Furusato E, Valenzuela IA, Fanburg-Smith JC, Auerbach A, Furusato B, Cameron JD, *et al.* Orbital solitary fibrous tumor: Encompassing terminology for hemangiopericytoma, giant cell angiofibroma, and fibrous histiocytoma of the orbit: Reappraisal of 41 cases. *Hum Pathol* 2011;42:120-8.
3. Fanning NF, Kahn A, Corbally MT. External carotid artery ligation for life-threatening hemorrhage in exsanguinating orbital facial congenital hemangiopericytoma. *J Pediatr Surg* 1997;32:1252-4.
4. Giannini C, Rushing EJ, Hainfellner JA, Bouvier C, Figarella-Branger D, von Deimling A, *et al.* WHO Classification of Tumours of the Central Nervous System: WHO Classification of Tumours. Revised 4<sup>th</sup> ed., Vol. 1. Lyon: World Health Organization; 2016. p. 249-54.
5. Leoncini G, Maio V, Puccioni M, Franchi A, De Giorgi V, Ucci F, *et al.* Orbital solitary fibrous tumor: A case report and review of the literature. *Pathol Oncol Res* 2008;14:213-7.
6. Brum M, Nzwalo H, Oliveira E, Pelejo MR, Pereira P, Farias JP, *et al.* Solitary fibrous tumors of the orbit and central nervous system: A case series analysis. *Asian J Neurosurg* 2018;13:336-40.
7. Bernardini FP, de Conciliis C, Schneider S, Kersten RC, Kulwin DR. Solitary fibrous tumor of the orbit: Is it rare? Report of a case series and review of the literature. *Ophthalmology* 2003;110:1442-8.
8. Weiss B, Horton DA. Preoperative embolization of a massive solitary fibrous tumor of the pleura. *Ann Thorac Surg* 2002;73:983-5.

9. Shen J, Li H, Feng S, Cui H. Orbital solitary fibrous tumor: A clinicopathologic study from a Chinese tertiary hospital with a literature review. *Cancer Manag Res* 2018;10:1069-78.
10. Chen H, Xiao CW, Wang T, Wu JS, Jiang CC, Qian J, *et al.* Orbital solitary fibrous tumor: A clinicopathologic study of ten cases with long-term follow-up. *Acta Neurochir (Wien)* 2012;154:249-55.
11. Kishimoto I, Shinohara S, Fujiwara K, Kikuchi M, Tona R, Kanazawa Y, *et al.* A case of intraorbital solitary fibrous tumor resected successfully with preoperative arterial embolization. *Nihon Jibiinkoka Gakkai Kaiho* 2014;117:1477-82.
12. Hashemi N, Ling JD, Soparkar C, Sami M, Ellezam B, Klucznik R, *et al.* Transarterial onyx embolization of an orbital solitary fibrous tumor. *Ocul Oncol Pathol* 2015;1:98-102.
13. Wallace KM, Alaraj A, Aakalu VK, Aletich V, Setabutr P. Endovascular preoperative embolization of orbital hemangiopericytoma with n-butyl cyanoacrylate glue. *Ophthalmic Plast Reconstr Surg* 2014;30:e97-100.
14. Kim LJ, Albuquerque FC, Aziz-Sultan A, Spetzler RF, McDougall CG. Low morbidity associated with use of n-butyl cyanoacrylate liquid adhesive for preoperative transarterial embolization of central nervous system tumors. *Neurosurgery* 2006;59:98-104.
15. Razavi MK, Murphy K. Embolization of bronchial arteries with N-butyl cyanoacrylate for management of massive hemoptysis: A technical review. *Tech Vasc Interv Radiol* 2007;10:276-82.