



Since January 2020 Elsevier has created a COVID-19 resource centre with free information in English and Mandarin on the novel coronavirus COVID-19. The COVID-19 resource centre is hosted on Elsevier Connect, the company's public news and information website.

Elsevier hereby grants permission to make all its COVID-19-related research that is available on the COVID-19 resource centre - including this research content - immediately available in PubMed Central and other publicly funded repositories, such as the WHO COVID database with rights for unrestricted research re-use and analyses in any form or by any means with acknowledgement of the original source. These permissions are granted for free by Elsevier for as long as the COVID-19 resource centre remains active.



## Electroencephalographic findings in COVID-19 patients: A systematic review

Katrina T. Roberto<sup>a,\*</sup>, Adrian I. Espiritu<sup>a,b</sup>, Marc Laurence L. Fernandez<sup>a</sup>, Josephine C. Gutierrez<sup>a</sup>

<sup>a</sup> Department of Neurosciences, College of Medicine and Philippine General Hospital, University of the Philippines Manila, Taft Avenue, Manila, 1000, Philippines

<sup>b</sup> Department of Clinical Epidemiology, College of Medicine, University of the Philippines Manila, Taft Avenue, Manila, 1000, Philippines

### ARTICLE INFO

#### Keywords:

Electroencephalography  
Electroencephalogram  
COVID-19  
Coronavirus  
Seizures  
Epilepsy

### ABSTRACT

**Background:** Growing evidence of neurologic involvement seen in COVID-19 infection necessitates the pooling of neurodiagnostic findings like electroencephalography (EEG) that may guide clinical management. The objective of this study was to review the EEG findings in patients diagnosed with COVID-19 infection through a systematic review of published articles.

**Methods:** We systematically searched until July 25, 2020 for published articles that reported on descriptive EEG findings in patients diagnosed with COVID-19 in PUBMED by Medline, EMBASE, and CENTRAL by the Cochrane Library.

**Results:** From a total of 94 identified records, 29 relevant articles were included in this review. A total of 177 patients with COVID-19 with descriptive EEG reports were analyzed. The most common indication for EEG was unexplained altered mental status. Disturbances of background activity such as generalized and focal slowing were seen as well epileptiform abnormalities and rhythmic or periodic discharges. There were no consistent EEG findings specific to COVID-19 infection.

**Conclusion:** The EEG findings in COVID-19 appear to be non-specific. Further research on the relationship of the EEG findings to the clinical state and short- or long-term prognosis of COVID-19 patients may be conducted to help clinicians discern which patients would necessitate an EEG procedure and would eventually require treatment.

## 1. Introduction

The coronavirus disease of 2019 (COVID-19) infection caused by the severe acute respiratory syndrome coronavirus 2 (SARS-CoV-2) primarily presents with respiratory signs and symptoms. Nevertheless, a growing literature suggests that this condition may present with neurologic manifestations and/or complications, which include but are not limited to encephalopathy, seizures, meningoencephalitis, and cerebrovascular diseases [1,2]. Patients with critical medical illnesses are known to be at risk for neurological complications like seizures and status epilepticus; however, the evidence is substantially limited in the context of COVID-19 infection [3]. With growing evidence of neurologic involvement seen in COVID-19, there may be an increasing demand for important neurodiagnostic tools such as electroencephalography (EEG).

The exponential growth of the body of knowledge on COVID-19

infection and its association with neurological complications necessitates a comprehensive evaluation and characterization of electrodiagnostic findings like seen in the EEG. Thus, the objective of this study was to review the EEG findings in patients diagnosed with COVID-19 infection through a systematic review of published relevant articles.

## 2. Methods

This systematic review is reported in accordance with the Preferred Reporting Items for Systematic Reviews and Meta-Analyses (PRISMA) guidelines [4].

### 2.1. Criteria for considering studies for review

We considered case reports/series, cross-sectional and cohort studies

\* Corresponding author.

E-mail addresses: [ktroberto@up.edu.ph](mailto:ktroberto@up.edu.ph) (K.T. Roberto), [aiespiritu@up.edu.ph](mailto:aiespiritu@up.edu.ph) (A.I. Espiritu), [mfernandez@up.edu.ph](mailto:mfernandez@up.edu.ph) (M.L.L. Fernandez), [jcgutierrez4@up.edu.ph](mailto:jcgutierrez4@up.edu.ph) (J.C. Gutierrez).

<https://doi.org/10.1016/j.seizure.2020.09.007>

Received 11 August 2020; Received in revised form 7 September 2020; Accepted 9 September 2020

Available online 15 September 2020

1059-1311/© 2020 British Epilepsy Association.

Published by Elsevier Ltd.

This article is made available under the Elsevier license

(<http://www.elsevier.com/open-access/userlicense/1.0/>).

that reported on descriptive EEG findings in patients diagnosed with COVID-19 infection. We also considered other article types such as letters to the editor and brief communications. We did not apply any restrictions on age, sex, or ethnicity of patients in the studies. We excluded animal studies, unavailable full-text articles, and non-English articles.

## 2.2. Search methods for identification and selection of studies

Two investigators (KTR, AIE) performed an electronic search up to July 25, 2020 using the following major healthcare databases: PUBMED by Medline, EMBASE, and CENTRAL by the Cochrane Library. We utilized the following general and MeSH terms: ("EEG" OR "Encephalograph" OR "Encephalography" OR "Encephalographic" OR "Encephalogram") AND ("COVID" OR "Coronavirus" OR "COVID-19" OR "SARS-CoV-2" OR "nCoV disease"). We screened the references of all identified relevant articles for studies to be included in this review. We assessed the titles and abstracts using predefined screening criteria. Relevant articles were retrieved in full-text articles and were subjected to predefined eligibility criteria. Studies that satisfied these criteria were included in the analysis. Any disagreement in the inclusion of the studies was resolved by consensus with two more investigators (MLF, JCG).

## 2.3. Methodological assessment of included studies

Two investigators (KTR, AIE) evaluated the methodological quality of the included studies using the Murad tool for non-comparative cohorts and case reports/series [5]. Comparative cohorts and

cross-sectional studies were evaluated using the Newcastle-Ottawa Scale in terms of selection, comparability, and outcome domains [6]. We considered "poor", "moderate" or "good" quality when 3 or fewer, 4, or 5 of the criteria were fulfilled in the Murad tool, and 3 points or fewer, 4–5, or 6 and above in the Newcastle-Ottawa Scale. Any disagreement was resolved by consensus with two more investigators (MLF, JCG).

## 2.4. Data collection and analysis

We extracted data from the full text of the articles using a predefined data extraction form. The following information was obtained from each included study: author and year, publication date, study design, study duration, setting, number of included patients, age, sex, descriptive electroencephalographic findings, indication for the EEG study and the recording type, and other clinical information of subjects. Categorical variables were pooled as frequencies and percentages while continuous variables were summarized using means or medians with standard deviation or ranges.

## 3. Results

### 3.1. Included studies

The literature search as shown in Fig. 1 yielded 94 articles. After the removal of 25 duplicates, 32 out of 69 articles fulfilled the screening criteria. Of the remaining 32 studies, a total of 29 articles were included in the review after satisfying the eligibility criteria. There were sixteen

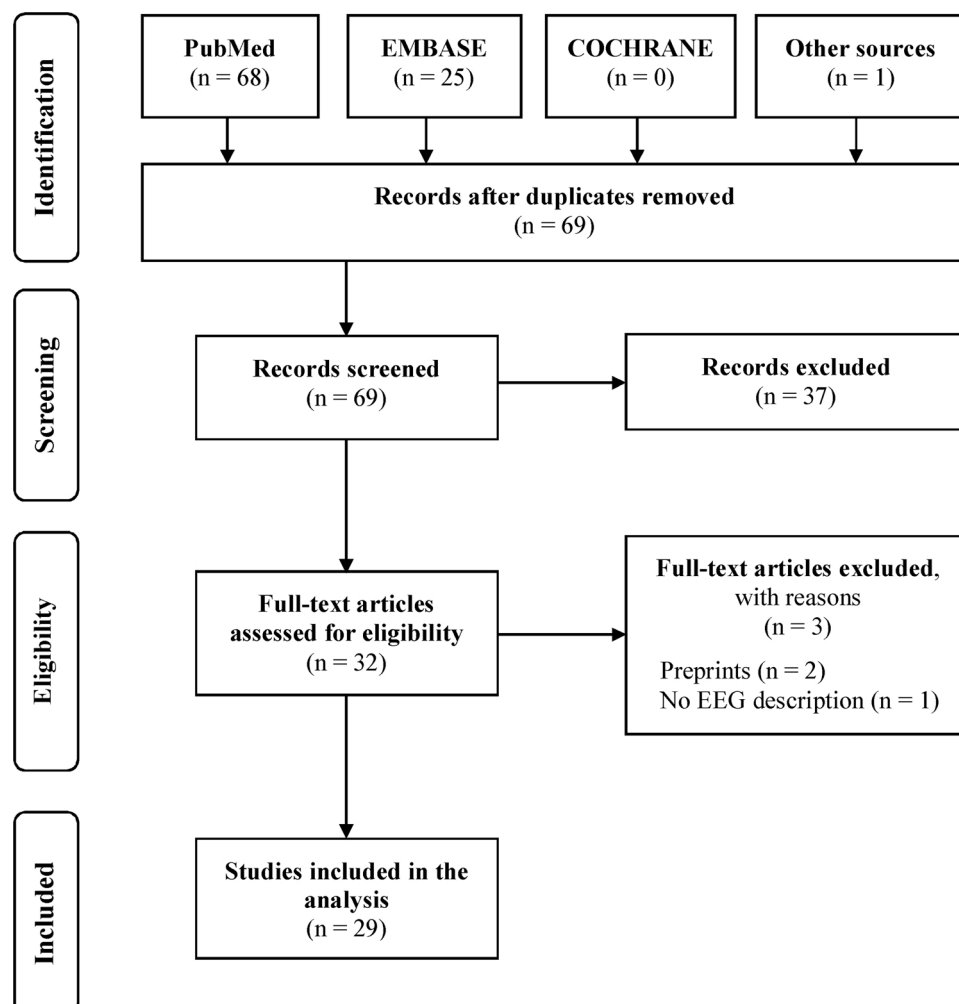


Fig. 1. Preferred reporting items for systematic reviews and meta-analyses (PRISMA) flow diagram of the study.

case reports [7–21], ten case series [22–31], two cohort studies [32,33], and one cross-sectional study [34]. Six studies reported utilization of a retrospective design.

The characteristics of the studies and their quality assessment are shown in Table 1. Included studies came from various countries such as United States of America (USA), Italy, France, Spain, Switzerland, Germany and the United Kingdom (UK). The sample size of the included studies ranged from 1 to 22. All case reports and series except four studies were assessed to have poor methodological quality. The rest of the studies were scored 4–5 stars for the cohorts and 3 stars for the cross-sectional study.

### 3.2. Population characteristics

A total of 177 COVID-19 patients with available descriptive EEG findings were included in the analysis. The demographic information is shown in Table 1 while other relevant clinical information is available as a Supplementary Material. Only one study reported on a single pediatric patient while the rest of the studies analyzed adult subjects [15].

The age of the included subjects was from 6 weeks to 97 years while the female-to-male ratio was 17:39. Of the included subjects, 125 were specified to be critically ill. The use of psychoactive medications at the time of EEG recording was not stated in the studies except for one retrospective study [29]. Eight patients had a history of epilepsy or seizure [12,21–23,25]. Twenty subjects had SARS-CoV-2 RT-PCR testing for CSF, which were all negative [7–10,13–15,17,22,23,26,33].

### 3.3. Electroencephalographic findings in COVID-19

Overall, the indication for performing EEG was due to altered mental status, encephalopathy, or poor responsiveness after the withdrawal of sedation in 160 cases (90.4 %) and seizure-like activity in 48 cases (27.1

%).

Ten studies employed continuous EEG recording [7,11,15,25,27,30,31,34–36]. A few studies employed a limited montage with a minimum of nine electrodes [22,23,25]. The antiepileptic medications and sedatives received by the patients at the time of EEG were not specified in all studies. The electroencephalographic findings in COVID-19 patients are summarized in the Supplementary Material.

Normal EEG was recorded in six cases (3.4 %) [9,18,29]. Disturbances of background rhythm were seen such as generalized slowing in 113 cases (63.8 %) [8,10,16,17,20,22–26,29–34,37]. In those with diffuse slowing, anterior emphasis was reported in 16 patients (9%) [23,24,31]. On the other hand, focal slowing was noted in 14 patients (7.9 %) [14,24,25,37]. The localization of focal slowing was not reported in most of the included studies. One study revealed focal slowing arising in the left temporal lobe in a patient with an infarct on the same location on neuroimaging [37]. Slowing of the posterior dominant rhythm (PDR) was seen in five cases (2.8 %) while an absent PDR was in 18 patients (10.2 %) [19,25]. Burst suppression pattern was noted in one patient (0.6 %) [25]. Triphasic waves were also reported in two patients (1.1 %) [19,23].

Epileptiform discharges were described in 34 patients (19.2 %) [7,8,11,13,19,21,24,25,27,28,30,32]. Only two studies included patients showing epileptiform abnormalities on EEG with a history of seizure or epilepsy [19,21]. Status epilepticus was reported in eight of 177 patients (4.5 %); of these, five cases (2.8 %) were non-convulsive [7,8,12,19,21,27,30,34]. In three cases of status epilepticus, neuroimaging was unremarkable [7,8,19]. In contrast, one patient with post-encephalitic epilepsy had left temporoparietal lobe gliosis and atrophy while another patient had T2-weighted hyperintensities on the right orbital prefrontal cortex, right mesial prefrontal cortex and right caudate nucleus on MRI [12,21]. Among cases of status epilepticus with CSF studies, one patient had a CSF picture consistent with viral meningoencephalitis [8], but

**Table 1**

Characteristics of the included studies and population, and quality assessment.

Author and Year	Setting	Sample (N)	Study Design	Age in years Mean or Median (SD or Range)	Sex (F:M)	Quality Assessment
Balloy 2020	France	1	Case report	59	0:1	Poor
Bernard-Valnet 2020	Switzerland	1	Case report	64	1:0	Poor
Canham 2020	United Kingdom	10	Case series	65 (18–74)	2:8	Poor
Cecchetti 2020	Italy	18	Case series	46–79	7:11	Moderate
De Stefano 2020	Switzerland	1	Case report	56	1:0	Poor
Dugue 2020	USA	1	Case report	0.125	0:1	Poor
Duong 2020	USA	1	Case report	41	1:0	Poor
Farhadian 2020	USA	1	Case report	78	1:0	Poor
Fasano 2020	Italy	1	Case report	54	0:1	Poor
Filatov 2020	USA	1	Case report	74	0:1	Poor
Flamand 2020	France	1	Case report	80	1:0	Poor
Galanapoulou 2020	USA	22	Retrospective case series	30–83	7:11	Poor
Haddad 2020	USA	1	Case report	41	0:1	Poor
Helms 2020	France	8 out of 58	Case series	63	NR	Poor
Hepburn 2020	USA	2	Case series	76, 82	0:2	Poor
Le Guennec 2020	France	1	Case report	69	0:1	Poor
Logmin 2020	Germany	1	Case report	70	1:0	Poor
Morassi 2020	Italy	1	Retrospective case series	76	1:0	Poor
Pastor 2020	Spain	20	Cohort	61.5 (36–97)	3:17	Moderate
Petrescu 2020	France	36	Retrospective case series	67 (43–97)	5:13	Moderate
Pilotto 2020	Italy	1	Case report	60	0:1	Poor
Romero-Sanchez 2020	Spain	2 out of 841	Retrospective cohort	NR	NR	Moderate
Scullen 2020	USA	12 out of 27	Retrospective cross-sectional study	59.8 (35–91)	NR	Poor
Sohal 2020	USA	1	Case report	72	0:1	Poor
Somani 2020	USA	2	Case series	49, 73	0:2	Poor
Vellieux 2020	France	2	Case series	37, 42	0:2	Poor
Vespigani 2020	France	26	Retrospective case series	67 (58–70)*	1:4*	Poor
Vollono 2020	Italy	1	Case report	78	1:0	Poor
Zanin 2020	Italy	1	Case report	54	1:0	Poor

NR – not reported.

\*Representative cases.

none revealed a positive result for those tested for SARS-CoV-2.

Rhythmic or periodic patterns recorded in the studies were as follows: (a) generalized periodic discharges (GPDs) in 13 (7.3 %) [22,29], (b) lateralized periodic discharges (LPDs) in 13 (7.3 %), two of whom had LPDs arising from the right frontal lobe [21,22,32], (c) bilateral independent periodic discharges (BIPDs) in 1 (0.6 %) that later evolved into status epilepticus (SE) [30], (d) generalized rhythmic delta activity (GRDA) in 7 (4%) [22,25], (e) unspecified rhythmic delta activity (RDA) in 8 (4.5 %) [29], (f) lateralized rhythmic delta activity (LRDA) in 1 (0.6 %) arising from the left temporal region [25], and (g) frontal intermittent rhythmic delta activity (FIRDA) in 1 (0.6 %) [23].

Other electroencephalographic findings reported in the available literature include isoelectric EEG consistent with brain death in two cases (1.1 %) in one study and fast activity superimposed on slow waves in three patients (1.7 %) [22,23]. The abovementioned findings were seen in adult subjects. Excessive temporal sharp transients and intermittent vertex delta slowing with normal sleep-wake cycling was noted in one recording (0.6 %) done on an infant with COVID-19 [15]. Frontal sharp waves were suggested to be a possible biomarker of epileptic dysfunction in COVID-19 encephalopathy in one study [25].

EEG patterns and imaging correlation was not specifically performed in the included studies. A few patients in our review were seen to have focal EEG abnormalities that could be explained by the underlying focal structural pathology. These patients were noted to have encephalitis [21], leptomeningeal enhancement [28], gliosis [12,37], and craniotomy [13] in the same region. Of note, the presence of focal EEG dysfunction prompted neuroimaging to be done in one patient which then revealed cerebral microbleeds [14]. In contrast, three cases with focal EEG abnormalities showed normal findings [8] or chronic microvascular ischemic changes with no acute findings on imaging [11,27]. As expected, one case with EEG findings of diffuse slowing with absent reactivity was reported to have MRI with perfusion studies compatible with hypoxic encephalopathy [31].

#### 4. Discussion

To our knowledge, our present review provides the most comprehensive summary of the EEG findings in patients with COVID-19 infection. None of the studies appear to have demonstrated a finding that is specific to COVID-19. It is suggested that SARS-CoV-2 has some propensity for neurotropism and given the presence of hypoxia, metabolic derangements, and primary brain injury itself, seizures may indeed be expected in COVID-19 [46]. Although it is well known that critically ill patients are at high risk for seizures and status epilepticus, our review provides more reliable estimates of the frequencies of EEG findings among COVID-19 patients reported in the literature. The aggregated information in our review may be crucial in guiding important clinical decisions in the management of this condition.

It is important to highlight that unexplained altered mental status was the most common indication for performing an EEG procedure according to our review. Moreover, the majority of the patients had multiple comorbidities and polypharmacy, was intubated for acute respiratory distress syndrome (ARDS), and was admitted to the intensive care unit. Thus, the findings of this study reflect similar findings of encephalopathy in critically ill patients in general [3]. The clinical indication for the procedure in COVID-19 patients is consistent with those applied for critically ill patients.

The majority of the EEG recordings showed non-specific EEG abnormalities of background rhythm like generalized/ focal slowing and epileptiform discharges. Generalized slowing is present in approximately 6 out of 10 patients with reported EEG in the literature. A wide range of etiologies may lead to diffuse background slowing such as sedative and anesthetic effect, various etiologies of encephalopathy, and central nervous system infectious processes. COVID-19-associated encephalopathy was found to be encountered in older and critically ill patients and may be of hypoxic-ischemic, toxic-metabolic, and

inflammatory origin [38]. It remains uncertain whether the neurologic complications of COVID-19 such as encephalopathy is due to direct viral neuroinvasion or is a result of the critical illness. In our review, none of the identified cases with cerebrospinal fluid (CSF) analysis turned out positive for the virus which limits the evidence of the potential contribution of neuroinvasion of the virus to the EEG abnormalities seen. However, it should be noted that the difficulties in finding SARS-CoV-2 in the CSF may be related to the possibly insufficient accuracy of the testing kits in detecting the virus in these samples.

Focal non-epileptic slowing is another EEG abnormality seen in a number of COVID-19 cases. This finding suggests possible focal underlying structural brain pathology of non-specific etiology. Among the cases reported, only one with focal slowing had a pre-existing or chronic structural lesion [37]. Other MRI studies of COVID-19 cases in other reports showed abnormalities in the medial temporal lobe, multifocal white matter regions and right gyrus rectus [39,40]; most findings were consistent with ischemic strokes, leptomeningeal enhancement and encephalitis [41]. Further neuropathological studies revealed the presence of severe hypoxic and hemorrhagic phenotypes, thrombotic complications, acute disseminated encephalomyelitis, encephalitis and meningitis [42–45]. Thus, these neuroimaging and pathological studies demonstrate pieces of evidence suggestive of the neuroinvasive capability of the virus in altering human brain cortices that could be a potential source of focal or generalized abnormalities seen in the EEG tracings.

Epileptiform abnormalities are also seen among the identified cases, which are present nearly 2 out of 10 patients with reported EEG. One retrospective case series suggested that epileptiform discharges are more common in COVID-19 patients than in other group of patients with encephalopathy [25]. In contrast, other retrospective case series revealed no epileptiform abnormalities; only non-specific EEG abnormalities and a normal or mildly altered background were recognized in the majority of the cases. These epileptiform patterns may be expected in critically ill patients at high risk for clinical seizures. The important question remains whether these epileptiform discharges are brought about by the potential neuroinvasiveness of COVID-19 or not. Moreover, the possible epileptogenesis of COVID-19 infection, which would necessitate long-term antiepileptic drug treatment, is yet to be established.

In our review, only 2.8 % of cases were found to have nonconvulsive status epilepticus (NCSE). The EEG remains to be an important diagnostic tool to detect brain dysfunction especially in unexplained disorders of consciousness particularly in the setting of NCSE. Suspicion for NCSE in patients with altered mental status without a known acute brain insult is a strong indication for continuous EEG monitoring as NCSE is related to high mortality and morbidity [47]. Due to the seemingly low occurrence of NCSE in the reported cases in our review, a high index of suspicion by the clinicians is crucial to be able to detect this condition.

Furthermore, there has been a drastic decrease in the number of procedures done during this pandemic [48]. The conduct of continuous EEG during this pandemic is limited to urgent cases only because of the safety concern imposed by the contagiousness of the virus and concerns to reduce the exposure to SARS-CoV-2 of EEG technicians during this pandemic. Three centers included in our review opted to employ an eight-channel acquisition system using nine electrodes rather than a full montage EEG. In the context of COVID-19, a reduced EEG montage may be useful as it allows reduced contact time of EEG technicians to infected patients [49]; however, its sensitivity to detect epileptiform abnormalities has been questioned. One study demonstrated the reasonable diagnostic utility of a reduced channel EEG for detecting generalized or hemispheric seizures and rhythmic periodic patterns [50]. We believe that the use of eight-channel montage in the COVID-19 context to guide patient management may be recommended when adequate evidence to support its use becomes available.

This systematic review has limitations given the retrospective nature of the identified studies. We also observed among the included studies a

heterogeneous sample concerning illness severity, sedatives and anti-epileptic drugs received at the time of EEG. The included patients had an urgent indication for EEG; hence EEG abnormalities were expected to be more frequently reported. Certainly, a number of cases who had undergone EEG procedures were not documented yet in the literature which could limit the estimates provided in our review. The lack of uniform reporting of EEG findings, the interrater variability in interpreting EEG recordings, and the limited montage used in some included studies were other inherent limitations of the studies included.

In summary, COVID-19 patients may frequently manifest with abnormal EEG particularly in severe cases. However, the abnormal EEG findings appear to be non-specific. Further research on the relationship of the EEG findings to the clinical state and short- or long-term prognosis of COVID-19 patients may be conducted to help clinicians discern which patients would necessitate an EEG procedure and would eventually require treatment with the ultimate aim of improving their clinical outcomes.

### Data sharing policy

The authors confirm that the data supporting the findings of this study are available within the article and/or its supplementary materials.

### Funding

This research did not receive any specific grant from funding agencies in the public, commercial, or not-for-profit sectors.

### CRedit authorship contribution statement

**Katrina T. Roberto:** Conceptualization, Data curation, Formal analysis, Writing - original draft, Writing - review & editing. **Adrian I. Espiritu:** Conceptualization, Data curation, Formal analysis, Writing - original draft, Writing - review & editing. **Marc Laurence L. Fernandez:** Conceptualization, Data curation, Formal analysis, Writing - original draft, Writing - review & editing. **Josephine C. Gutierrez:** Conceptualization, Data curation, Formal analysis, Writing - original draft, Writing - review & editing.

### Declaration of Competing Interest

The authors report no declarations of interest.

### Acknowledgement

Nil.

### Appendix A. Supplementary data

Supplementary material related to this article can be found, in the online version, at doi:<https://doi.org/10.1016/j.seizure.2020.09.007>.

### References

- [1] Ellul MA, Benjamin L, Singh B, Lant S, Michael BD, Easton A, et al. Neurological associations of COVID-19. *Lancet Neurol* 2020;(July).
- [2] Collantes MEV, Espiritu AI, Sy MCC, Anlanc VMM, Jamora RDG. Neurological manifestations in COVID-19 infection: a systematic review and meta-analysis. *Can J Neurol Sci / J Can des Sci Neurol* [Internet] 2020;15(July):1–26. Available from: <https://www.cambridge.org/core/product/identifier/S0317167120001468/type/journal-article>.
- [3] Bleck TP, Smith MC, Pierre-Louis SJ, Jares JJ, Murray J, Hansen CA. Neurologic complications of critical medical illnesses. *Crit Care Med* [Internet] 1993;21 (January(1)):98–103. Available from: <http://www.ncbi.nlm.nih.gov/pubmed/8420739>.
- [4] Moher D, Shamseer L, Clarke M, Ghersi D, Liberati A, Petticrew M, et al. Preferred reporting items for systematic review and meta-analysis protocols (PRISMA-P) 2015 statement. *Syst Rev* 2015;4(1):1–9.
- [5] Murad MH, Sultan S, Haffar S, Bazerbachi F. Methodological quality and synthesis of case series and case reports. *BMJ Evidence-Based Med* [Internet] 2018;23(April (2)):60–3. <https://doi.org/10.1136/bmjebm-2017-110853>. Available from: .
- [6] Wells G, Shea B, O'Connell D, Peterson J. The Newcastle-Ottawa Scale (NOS) for assessing the quality of nonrandomised studies in meta-analyses. Ottawa, ON: Ottawa Hospital Research Institute; 2000.
- [7] Balloy G, Mahé P, Leclair-visonneau L. Non-lesional status epilepticus in a patient with coronavirus disease 2019. *Clin Neurophysiol* 2020.
- [8] Bernard-Valnet R, Pizzarotti B, Anichini A, Demars Y, Russo E, Schmidhauser M, et al. Two patients with acute meningoencephalitis concomitant with SARS-CoV-2 infection. *Eur J Neurol* 2020.
- [9] Logmin K, Karam M, Schichel T, Harmel J, Wojtecki L. Non-epileptic seizures in autonomic dysfunction as the initial symptom of COVID-19. *J Neurol* 2020;3–4.
- [10] Pilotto A, Odolini S, Masciocchi S, Comelli A, Volonghi I, Gazzina S, et al. Steroid-Responsive Encephalitis in Coronavirus Disease 2019. *Ann Neurol* 2020;2:1–5.
- [11] Sahal S, Mossammat M. COVID-19 presenting with seizures. *IDCases* 2020.
- [12] Vollono C, Rollo E, Romozzi M, Frisullo G, Servidei S, Borghetti A, et al. Focal status epilepticus as unique clinical feature of COVID-19 A case report. *Seizure Eur J Epilepsy* 2020;78(April):109–12.
- [13] Zanin L, Saraceno G, Panciani PP, Fontanella MM. SARS-CoV-2 can induce brain and spine demyelinating lesions. 2020. p. 1–4.
- [14] De Stefano P, Nencha U, De Stefano L, Mégevad P, Seck M. Clinical Neurophysiology Practice Focal EEG changes indicating critical illness associated cerebral microbleeds in a Covid-19 patient. *Clin Neurophysiol Pract* 2020;5:125–9.
- [15] Dugue R, Cay-martínez KC, Thakur K, Joel A, Chauhan LV, Williams SH, et al. Neurologic manifestations in an infant with COVID-19. *Neurology* 2020.
- [16] Duong L, Xu P, Liu A. Meningoencephalitis without respiratory failure in a young female patient with COVID-19 infection in Downtown Los Angeles, early April 2020. *Brain Behav Immun* 2020;(January).
- [17] Farhadian S, Glick LR, Vogels CBF, Thomas J, Chiarella J, Casanovas-massana A, et al. Acute encephalopathy with elevated CSF inflammatory markers as the initial presentation of COVID-19. *BMC Neurol* 2020;20(248):1–5.
- [18] Fasano A. First motor seizure as presenting symptom of SARS-CoV-2 infection. *Neurol Sci* 2020;2–4.
- [19] Flamand M, Perron A, Buron Y, Szurhaj W. Pay more attention to EEG in COVID-19 pandemic. *Clin Neurophysiol* 2020;(xxxx):19–21.
- [20] Haddad S, Tayyar R, Risch L, Churchill G, Fares E, Choe M. Encephalopathy and seizure activity in a COVID-19 well controlled HIV patient. *IDCases* 2020.
- [21] Le Guennec L, Devianne J, Jalin L, Cao A, Galanaud D, Navarro V, et al. Orbitofrontal involvement in a neuroCOVID-19 patient. *Epilepsia* 2020;00(00): 1–5.
- [22] Vespigiani H, Colas D, Lavin B, Soufflet C, Maillard L, Pourcher V, et al. Report of EEG finding on critically ill patients with COVID-19. *Ann Neurol* 2020.
- [23] Canham L, Staniaszek LE, Mortimer AM, Nouri LF, Kane NM. Electroencephalographic (EEG) features of encephalopathy in the setting of Covid-19: a Case Series. *Clinical Neurophysiol Pract*. 2020.
- [24] Cecchetti G, Vabanesi M, Fanelli G, Minicucci F, Agosta F, Tresoldi M, et al. Cerebral involvement in COVID-19 is associated with metabolic and coagulation derangements: an EEG study. *J Neurol* 2020;(0123456789):1–5.
- [25] Galanopoulou AS, Ferastroaru V, Correa DJ, Cherian K, Duberstein S, Gursky J, et al. EEG findings in acutely ill patients investigated for SARS-CoV2/COVID-19: a small case series preliminary report. *Epilepsia Open* 2020;5(2):314–24.
- [26] Helms J, Kremer S, Merdji H, Clere-Jehl R, Schenck M, Kummerlen C, et al. Neurologic features in severe SARS-CoV-2 infection. *N Engl J Med* 2020;383(23).
- [27] Hepburn M, Mullaguri N, George P, Hantus S, Punia V, Bhimraj A, et al. Acute Symptomatic Seizures in Critically Ill Patients with COVID-19: Is There an Association? *Neurocrit Care* 2020;2019.
- [28] Morassi M, Bagatto D, Cobelli M, D'Agostini S, Gigli GL, Bnà C, et al. Stroke in patients with SARS-CoV-2 infection: case series. *J Neurol* 2020;(0123456789):1–8.
- [29] Petrescu A, Taussig D, Bouillieret V. Electroencephalogram (EEG) in COVID-19: a systematic retrospective study. *Neurophysiol Clin Neurophysiol*. 2020.
- [30] Somani S, Pati S, Id O, Communication B. De novo status epilepticus in patients with COVID-19. *Ann Clin Transl Neurol* 2020;0–2.
- [31] Vellieux G, Rouvel-taltec A, Jaquet P, Grinea A, Sonnevill R, Ortho M. COVID-19 associated encephalopathy: is there a specific EEG pattern? *Clin Neurophysiol* 2020.
- [32] Pastor J, Vega-zelaya L, Abad EM. Specific EEG encephalopathy pattern in SARS-CoV-2 patients. *J Clin Med* 2020;9(1545):1–14.
- [33] Romero-Sánchez CM, Díaz-maroto I, Fernandez-Diaz E, Sanchez-Larsen A, Layos-Romero A, Garcia-Garcia J, et al. Neurologic manifestations in hospitalized patients with COVID-19: the ALBACOV registry. *Neurology* 2020.
- [34] Scullen T, Mathkour M. COVID-19 associated encephalopathies and cerebrovascular disease: the New Orleans experience. *World Neurosurg* 2020;(May).
- [35] Louis S, Dhawan A., Newey C., Nair D., Jehi L., Hantus S. Continuous Electroencephalography (cEEG) Characteristics and Acute Symptomatic Seizures in COVID-19 Patients. *medrxiv*.
- [36] Pati S, Toth E, Chaitanya G. Quantitative EEG markers to prognosticate critically ill patients with COVID-19: a retrospective cohort study. *Clin Neurophysiol* 2020.
- [37] Filatov A, Sharma P, Hindi F, Espinosa PS. Neurological complications of coronavirus disease (COVID-19): encephalopathy. *Cureus* 2020;12(3):1–6.
- [38] Garg RK, Paliwal VK, Gupta A. Encephalopathy in patients with COVID-19: a review. *J Med Virol* 2020;0–3.
- [39] Kremer S, Lersy F, de Sèze J, Ferré J-C, Maamar A, Carsin-Nicol B, et al. Brain MRI findings in severe COVID-19: a retrospective observational study. *Radiology*

- [Internet] 2020;16(June):202222. <https://doi.org/10.1148/radiol.2020202222>. Available from:.
- [40] Politi Ls, Salsano E, Grimaldi M. Magnetic resonance imaging alteration of the brain in a patient with coronavirus disease 2019 (COVID-19) and anosmia. *JAMA Neurol* [Internet] 2020;77(August (8)):1028. Available from: <https://jamanetwork.com/journals/jamaneurology/fullarticle/2766765>.
- [41] Kremer S, Lersy F, Anheim M, Merdji H, Schenck M, Oesterlé H, et al. Neurologic and neuroimaging findings in COVID-19 patients: a retrospective multicenter study. *Neurology* [Internet] 2020;17(July). <https://doi.org/10.1212/WNL.00000000000010112>. Available from:.
- [42] Schaller T, Hirschtbühl K, Burkhardt K, Braun G, Trepel M, Märkl B, et al. Postmortem examination of patients with COVID-19. *JAMA* [Internet] 2020;323(June (24)):2518. Available from: <https://jamanetwork.com/journals/jama/fullarticle/2766557>.
- [43] Reichard RR, Kashani KB, Boire NA, Constantopoulos E, Guo Y, Lucchinetti CF. Neuropathology of COVID-19: a spectrum of vascular and acute disseminated encephalomyelitis (ADEM)-like pathology. *Acta Neuropathol* [Internet] 2020;140(July (1)):1–6. Available from: <http://link.springer.com/10.1007/s00401-020-02166-2>.
- [44] Solomon IH, Normandin E, Bhattacharyya S, Mukerji SS, Keller K, Ali AS, et al. Neuropathological features of Covid-19. *N Engl J Med* [Internet] 2020;383(September (10)):989–92. <https://doi.org/10.1056/NEJMc2019373>. Available from:.
- [45] von Weyhern CH, Kaufmann I, Neff F, Kremer M. Early evidence of pronounced brain involvement in fatal COVID-19 outcomes. *Lancet* [Internet] 2020;395(June (10241)):e109. Available from: <https://linkinghub.elsevier.com/retrieve/pii/S0140673620312824>.
- [46] Asadi-pooya AA. Seizures associated with coronavirus infections. *Seizure Eur J Epilepsy* 2020;(January):49–52.
- [47] Herman ST, Abend NS, Bleck TP, Chapman KE, Drislane FW, Emerson RG, et al. Consensus statement on continuous EEG in critically ill adults and children, part I: indications. *J Clin Neurophysiol* 2015;32(2):87–95.
- [48] Assenza G, Lanzone J, Ricci L, Boscarino M, Tombini M, Galimberti CA, et al. Electroencephalography at the time of Covid-19 pandemic in Italy. *Neurol Sci* 2020.
- [49] Haines S, Caccamo A, Chan F, Galaso G, Catinchi A, Gupta PK. Practical considerations when performing neurodiagnostic studies on patients with COVID-19 and other highly virulent diseases neurodiagnostic studies on patients with COVID-19 and other highly virulent diseases. *Neurodiagn J* 2020;00(02):1–18.
- [50] Gururangan K, Razavi B, Parvizi J. Clinical Neurophysiology Practice Diagnostic utility of eight-channel EEG for detecting generalized or hemispheric seizures and rhythmic periodic patterns. *Clin Neurophysiol Pract* 2018;3:65–73.