



Real-Time Shear Wave Elastography for Determining the Ideal Site of Liver Biopsy in Diffuse Liver Disease

Yashwant Patidar¹ Jitender Singh¹ Navojit Chatterjee¹ Amar Mukund¹ Archana Rastogi²
Guresh Kumar³ Manoj Kumar Sharma⁴

¹Department of Interventional Radiology, Institute of Liver and Biliary Sciences, New Delhi, India

²Department of Pathology, Institute of Liver and Biliary Sciences, New Delhi, India

³Department of Clinical Research, Institute of Liver and Biliary Sciences, New Delhi, India

⁴Department of Hepatology, Institute of Liver and Biliary Sciences, New Delhi, India

Address for correspondence Yashwant Patidar, MD, Department of Interventional Radiology, Institute of Liver and Biliary Sciences, Pocket D-1, Vasant Kunj, New Delhi 110070, India (e-mail: dryashwantpatidar@gmail.com).

Indian J Radiol Imaging 2024;34:44–53.

Abstract

Objectives The objective of the study was to identify accurate site of liver biopsy under ultrasound and elastography guidance and compare the shear wave elastography (SWE) and transient elastography (TE) diagnostic accuracy with histopathological correlation.

Methods This was a prospective single-center study where patients scheduled for nonfocal liver biopsy were divided into two groups (group U: ultrasound; group E elastography) by sequential nonrandom selection of patients. Elastography was performed before the biopsy and biopsies from the maximum stiffness segment were taken.

Results There was no significant difference of intersegmental liver stiffness with mean velocity; however, biopsy segment velocities show significant difference with mean liver stiffness suggestive of heterogenous distribution of fibrosis. The rho (r ; Spearman's correlation) value between biopsy segments and mean velocities shows excellent correlation. The diagnostic performance of TE was good for fibrosis stages F2, F3, and F4, while SWE was fair for the diagnosis of fibrosis stages F1 and F2 and fairly equal for the diagnosis stages F2 and F3. Area under the curve (AUC) values in differentiating mild (F1) or no fibrosis from significant fibrosis (\geq F2) were 95.5 with cutoff value of at least 1.94 m/s.

Conclusions The diagnostic performance of SWE is comparable with TE in liver fibrosis staging and monitoring. Fibrosis is heterogeneously distributed in different segments of the right lobe liver. Therefore, elastography at the time of biopsy may help in defining the accurate site for biopsy and improve histopathological yield in detecting liver fibrosis in patients with chronic liver disease.

Advances in Knowledge Elastography-guided biopsy is helpful to determine the ideal site of biopsy.

Keywords

- ▶ shear wave elastography
- ▶ transient elastography
- ▶ ultrasound
- ▶ nonalcoholic steatohepatitis
- ▶ fibrosis

article published online
August 16, 2023

DOI <https://doi.org/10.1055/s-0043-1771529>.
ISSN 0971-3026.

© 2023. Indian Radiological Association. All rights reserved.

This is an open access article published by Thieme under the terms of the Creative Commons Attribution-NonDerivative-NonCommercial-License, permitting copying and reproduction so long as the original work is given appropriate credit. Contents may not be used for commercial purposes, or adapted, remixed, transformed or built upon. (<https://creativecommons.org/licenses/by-nc-nd/4.0/>)

Thieme Medical and Scientific Publishers Pvt. Ltd., A-12, 2nd Floor, Sector 2, Noida-201301 UP, India

Introduction

Diffuse parenchymal diseases of the liver are one of the major causes of liver fibrosis (LF), which leads to cirrhosis, portal hypertension, and hepatocellular carcinoma.¹ They are a major cause of morbidity and mortality in developing and developed countries. The causative factors of liver diseases (LDs) include infection (hepatitis viruses), autoimmune disorders, toxins, and metabolic damage. Degree of LF correlates with the severity of liver parenchymal damage and LDs are curable and reversible if LF is detected early.² Hence, estimating the degree of LF is essential in the evaluation of the severity of LD as well as in its therapy. Liver biopsy can only assess a very limited part of the whole liver, while fibrosis is a heterogeneously distributed entity. Hence, its diagnosis and grading are limited by sampling variability and there is inaccurate histopathological yield. Liver biopsy is the gold standard for evaluating the extent of LF, but liver biopsies are associated with higher sampling errors, low repeatability, and invasive and interobserver variability. Therefore, liver biopsy is not characterized as the ideal technique for screening, longitudinal monitoring, and assessing the treatment response.

In the current scenario, percutaneous liver biopsy is the gold standard for assessment of hepatic fibrosis (HF).³ Several noninvasive techniques for measurements of liver stiffness, such as real-time shear wave elastography (SWE) and transient elastography (TE; FibroScan, Echosens, Paris, France) are now available.⁴ The ideal test for the staging of LF should be simple, readily available, inexpensive, reproducible, accurate, and noninvasive. Given these conditions, ultrasound (US) elastography has many advantages in becoming the ideal test for quantifying LF with the help of SWE, which is a relatively new technique.^{5,6} SWE technology showed wide acceptance and is successfully used in the assessment of diseases of various tissues and organs.^{7,8}

The diagnostic performance of SWE is comparable or even better than TE in the detection of portal hypertension in chronic liver disease (CLD).⁹ Fibrosis is nonuniform in distribution, so elastographic measurement or biopsy from one site is not an accurate reflection of the disease process. Previous literature had shown that liver stiffness measured by SWE reflects the pathological stage of fibrosis, with good accuracy and diagnostic performance.^{10,11} However, there is no such study that determines the ideal site of liver biopsy based on elastography. In view of heterogeneous nature of fibrosis, we performed ultrasonography (USG) and elastography evaluations before liver biopsy to determine the ideal site of biopsy and along with it compared the SWE and TE results.

Materials and Methods

Study Design and Study Population

The present study was approved by the institutional review board (IEC/2020/73/MA08) and it was a prospective nonrandomized single-center tertiary institution study of adult cohorts. Eligible patients underwent USG-guided nonfocal liver biopsy in the day care unit of the interventional radiology department between September 2019 and August 2020. Patients younger than 18 years and those with known cirrhosis were excluded from the present study. Informed written consent was obtained and patients were divided into two groups: **Group U (USG group)** underwent US-guided biopsy, while in **Group E (elastography group)** both US and elastography guidance was used for targeting the areas of maximum tissue resistance/velocity and biopsy was planned as shown in the flowchart in **►Fig. 1**. Both techniques were compared with the FibroScan score and histopathological score (meta-analysis of histological data in viral hepatitis [METAVIR]) of the biopsy sample in all patients.

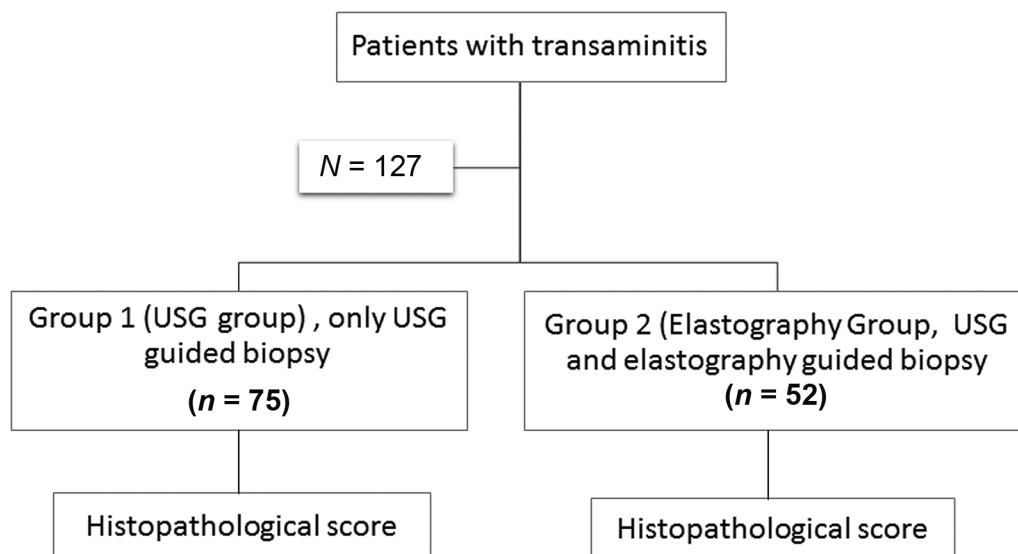


Fig. 1 Flowchart summarizing the study methodology.

Transient Elastography Examination

All TE examinations were performed in the supine position with arms in overhead abduction. The intercostal space providing the best visualization of the liver at the midaxillary line was chosen using B-mode with the FibroScan machine. The TE probe was placed in the selected intercostal space perpendicular to the skin surface. An adequate amount of gel was placed to form better acoustic isolation, and appropriate compression pressure according to pressure indicator was applied. Measurements were recorded in median number in kilopascal (kPa), which was then interpreted into LF staging. To ensure adequate results and readings, the interquartile range (IQR)/median ratio <25% was considered. Liver stiffness and controlled attenuation parameters (CAP) were analyzed.

Shear Wave Elastography Examination

SWE was performed by using the Toshiba Aplio, Japan, system. It measures the speed of propagation of shear wave, which is then converted to tissue stiffness using a computer algorithm. These quantitative values are simultaneously generated with conventional B-mode images and also mapped as a color-coded two-dimensional elastography of tissue stiffness. SWE was performed by two radiologists in the interventional radiology department. The patients were kept nil per os (NPO) for 4 to 6 hours. Before the elastography examination, patients were trained for neutral breath holding position (neither full inspiration nor full expiration). First, we performed the routine grayscale USG of the liver, followed by elastography mode. In the elastography mode, the region of interest (ROI) was placed approximately 2.0 cm beneath the liver capsule 90 degrees to the center of the transducer, avoiding major vascular structures of the liver. The scan box measuring 0.5×1.0 cm and largest possible ROI (range: 15–30 mm²) was used.

Before biopsy, three to five elastography measurements were obtained at the following locations in the right lobe of the liver: (1) right upper lobe segments (segments 7 and 8) and (2) right lower lobe segments (segment 5 and 6). The right intercostal window approach was used for upper lobe measurements, whereas the intercostal or subcostal approach was used for right lower lobe measurements. The mean and median liver elasticity values were calculated for each of the four segments.

The obtained measurements were expressed in meter per second (m/s). The SWE speed was transformed into kilopascal (kPa) using Young's formula ($kPa = 3pv^2$), where p is tissue density and is constant for liver parenchyma ($\sim 1,000$ kg/m³) and v = speed of shear wave. The results were correlated with LF staging (METAVIR scoring).

Liver Biopsy

US-guided nonfocal liver biopsy was performed in the department of interventional radiology. Informed consent was taken before the procedure and local anesthesia (2% xylocaine) up to liver capsule was given. All biopsy specimens were obtained using an 18-gauge core biopsy gun (IB; Medical Device Technologies) from the right lobe of the liver (specimen length: ~ 1.8 –2 cm) because left lobe measure-

ments are highly influenced by the respiratory and cardiovascular movements and the left lobe is the least favored site for liver biopsy.

Histologic Examination

For staging of LD, the METAVIR scoring system were used.¹² The METAVIR score is an ordinal scale that grades fibrosis (F) from 0 to 4, where F4 = cirrhosis, F3 = many septa with architectural distortion but no feature of obvious cirrhosis; F2 = few septa but with maintained parenchymal architecture; F1 = enlarged portal tract with fibrosis; F0 = no fibrosis. Steatosis (S) was graded into the following categories: S0 = absent, S1 < 5%, S2 = 5 to 33%, S3 = 34 to 66%, and S4 > 66%. The necroinflammatory score (A) is the sum of (1) interface hepatitis and/or piecemeal (score, 0–3) and (2) lobular hepatitis (score, 0–2), which gives the total necroinflammatory activity score (A0–A3). Statistical analysis of the fibrosis, steatosis, and necroinflammatory scores was done.

Statistical Analysis

Statistical results were analyzed using Statistical Package for the Social Sciences software (SPSS) software, version 22.0. The mean values of the SWE velocity were estimated from the SWE values obtained from four different liver sites. Mann-Whitney U test and t -test were used to find out the correlation between the variables of the two groups. The liver parenchyma site with the highest positive correlation was identified by Spearman's correlation test. Online confidence interval (CI) generator was used to calculate the CIs for the correlation. The diagnostic performance of SWE in differentiating different stages of fibrosis was evaluated from the area under the curve (AUC) values of the receiver operating characteristic (ROC) curves. The sensitivity and specificity of SWE and TE were calculated using optimal cutoff values.

Results

Our study population comprised 127 patients (86 males and 41 females) with age ranging from 19 to 76 years (mean: 41.2 ± 13.6 years). The patients were divided into two groups according to the biopsy guidance used; 75 patients in whom only US guidance was used were included in **Group U** (US) and 52 patients in whom US and elastographic guidance was used were included in **Group E** (elastography). The mean age (years) of patients in groups E and U was 40.75 ± 13.59 and 41.90 ± 12.34 years, respectively. Baseline patient characteristics of the groups are detailed in ► **Table 1**. The groups were comparable with respect to etiology, CAP, liver stiffness measurement (LSM), fibrosis, steatosis, activity, and liver function test (LFT). The causes of CLD were nonalcoholic steatohepatitis (NASH; $n = 52$, 40.9%), hepatitis B virus (HBV; 31, 24.4%), hepatitis B virus (HCV; 17, 13.4%), chronic biliary pathology (primary biliary cirrhosis, PBC and primary sclerosing cholangitis, PSC; 9, 7.1%), and other diseases including autoimmune hepatitis and nonalcoholic fatty liver (NAFL; 18, 14.2%). FibroScan (TE) mean liver stiffness measurement (LSM) was 9.210 ± 5.52 kPa (range: 3.5–42 kPa) and mean CAP was 266.59 ± 56.52 kPa (range: 172–396 kPa).

Table 1 Clinical and demographic characteristics (mean \pm standard deviations)

Variable	Category	N = 127	Group U (N = 75)	Group E (N = 52)	p-Value
Age (y)	Male: 86; female: 41	41.22 \pm 13.06 (19–76)	40.75 \pm 13.599	41.90 \pm 12.345	0.44
Liver function test	Bilirubin	1.809 \pm 2.7172 (0.2–16)	2.260 \pm 4.6806	1.158 \pm 1.2715	0.236
	AST	89.26 \pm 52.7 (16–455)	106.681 \pm 66.363	64.48 \pm 51.262	0.146
	ALT	96.87 \pm 61 (13–521)	111.69 \pm 159.772	75.48 \pm 65.097	0.267
	AKP	107.33 \pm 86.705 (13–695)	114.97 \pm 93.835	96.31 \pm 74.750	0.309
	GGT	66.66 \pm 83.275 (7–660)	69.56 \pm 73.846	62.48 \pm 95.864	0.156
	Albumin	3.848 \pm 0.6347 (1.9–5.1)	3.896 \pm 0.6420	3.780 \pm 0.6245	0.271
FibroScan	CAP	266.59 \pm 56.525 (172–396)	264.28 \pm 56.301	269.98 \pm 57.243	0.595
	LAM	9.210 \pm 5.5210 (3.5–42)	9.571 \pm 5.8338	8.890 \pm 4.2958	0.930
Fibrosis	0	56 (44.1)	24	32	
	1	20 (15.7)	10	10	
	2	24 (18.9)	9	15	
	3	21 (16.5)	7	14	
	4	6 (4.7)	2	4	
Activity	0	75 (59)	28	47	
	1	8 (6.3)	3	5	
	2	30 (23.7)	15	15	
	3	14 (11)	6	9	
Steatosis	0	73 (57.5)	28	45	
	1	27 (21.2)	11	17	
	2	20 (15.8)	10	10	
	3	7 (5.5)	3	2	
Diagnosis	NASH	52 (40.9)	28	24	
	Chronic hepatitis (HBV)	31 (24.4)	18	13	
	Chronic hepatitis (HCV)	17 (13.4)	11	6	
	Chronic biliary pathology	9 (7.1)	7	2	
	Others	18 (14.2)	11	9	
Velocity (m/s), n = 52	Segment 5	1.9471 \pm 0.5 (1.20–3.08)			
	Segment 6	2.1356 \pm 0.6 (1.40–3.88)			
	Segments 7	2.0373 \pm 0.6 (1.28–3.81)			
	Segments 8	2.1058 \pm 0.6 (1.36–3.95)			

Abbreviations: AST, aspartate aminotransferase; ALT, alanine transaminase; AKP, alkaline phosphatase; CAP, controlled attenuation parameter; GGT, gamma-glutamyl transferase; LSM, liver stiffness measurement; NASH, nonalcoholic fatty liver disease.

The study population undergoing liver biopsy comprised 56 patients without any evidence of fibrosis ($F=0$). Twenty patients had nonsignificant fibrosis ($F=1$), 24 patients had significant LF ($F=2$), 21 patients had severe LF ($F=3$), and 6 patients had cirrhosis ($F=4$). In total, 27.2% patients accounted for stage S0 steatosis. Seventy-three of the 127 patients (57.4%) in our study had a total activity score of A0.

We noted maximum liver stiffness in segment 6 and took maximum biopsies from the inferior segments in about approximately 67% as noted in **Table 2**. There was no significant difference between intersegmental liver stiffness and mean velocity; however, the biopsy segment velocities show a significant difference with the mean liver stiffness

suggestive of heterogeneous distribution of fibrosis. The rho (r ; Spearman's correlation) value between biopsy segments and mean velocities shows excellent correlation as described in **Table 2**. Further dividing the right lobe on the basis of Couinaud's classification shows excellent correlation of all segments (anterior/posterior and superior/inferior) with V_{mean} and V_{biopsy} ; however, there is more correlation with the inferior segment (5/6) as described in **Table 3**.

The mean velocity in patients with stage F4 fibrosis was 2.82 ± 0.24 , F3 was 2.69 ± 0.74 , F2 fibrosis was 2.09 ± 0.20 , and F1 fibrosis was 1.90 ± 0.19 m/s. Different degrees of fibrosis showed a significant difference in the level of LS (mean velocity) as shown in box

Table 2 SWE velocity value at different segments and its correlation with mean velocity (r value Spearman's correlation) and percentage/frequency of biopsy segment (mean velocity: 2.04 m/s)

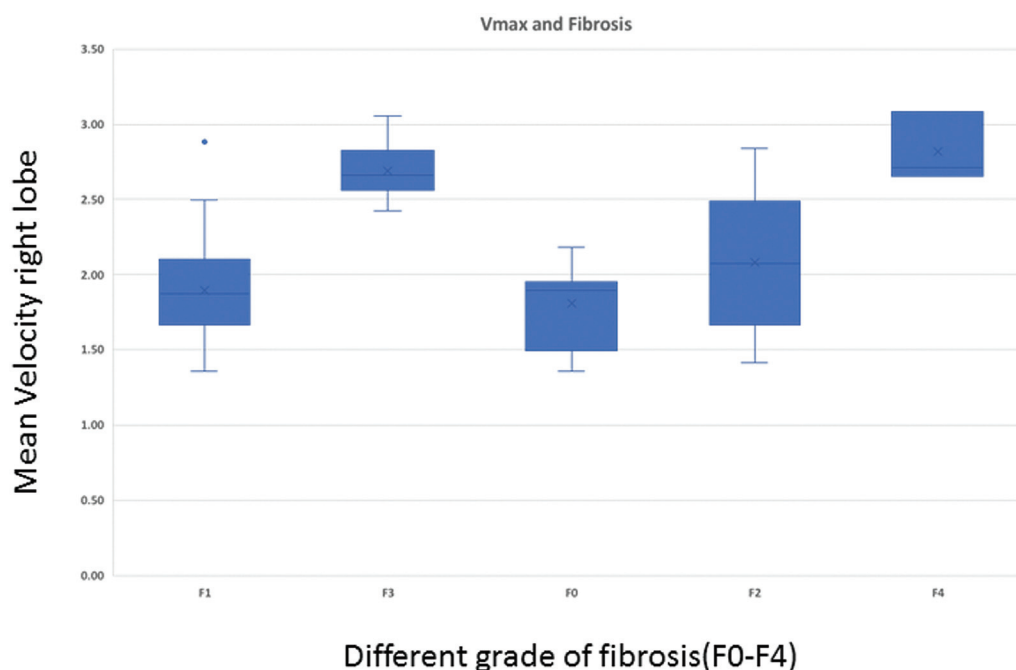
Segments	Mean velocity \pm SD	Confidence coefficient	r value with V_{mean}	Frequency (%)
Biopsy segment	2.31 \pm 0.67	0.18	0.925	–
Segment 5	1.95 \pm 0.58	0.16	0.739	9 (17.3%)
Segment 6	2.12 \pm 0.63	0.17	0.874	26 (50%)
Segment 7	2.04 \pm 0.63	0.17	0.816	11 (21.2%)
Segment 8	2.11 \pm 0.65	0.18	0.841	6 (11.5%)

Abbreviations: SD, standard deviation; SWE, shear wave elastography.

Table 3 Correlation of SWE velocity value at different site with mean velocity (r value Spearman's correlation)

Segments	Mean \pm SD	r with V_{mean}	r with V_{biopsy}
Anterior (5/8)	2.02 \pm 0.063	0.85	1
Posterior (6/7)	2.08 \pm 0.065	0.906	1
Inferior (5/6)	2.05 \pm 0.010	1	1
Superior (7/8)	2.05 \pm 0.024	1	0.875

Abbreviations: SD, standard deviation; SWE, shear wave elastography.

**Fig. 2** Box and whisker plot shows the mean shear wave elastography (SWE) values in the right lobe of the liver for various fibrosis stages. The top and bottom lines of each box represent the first and third quartiles (25th and 75th percentiles). The middle lines of each box are the median and the lines of the upper and lower boxes are the 5th and 95th percentiles.

and whisker plot (**►Figs. 2 and 3**). The ROC curve drawn to differentiate fibrosis stage with cutoff value and AUCs for differentiating fibrosis stage is noted in **►Table 4** and **►Fig. 4**.

Liver stiffness measurement according to fibrosis stages: The mean LSM using TE for fibrosis stages F0, F1, F2, F3, and F4 was 5.57 (4.2–7), 6.25 (4.9–9.1), 8.5 (5.5–13.4), 9.15 (8.0–

15.9), and 15.55 (14.5–22.3) kPa, respectively, as described in **►Fig. 5**. The areas under the receiver operating characteristic (AUROCs) for TE and SWE in fibrosis stages F1, F2, F3, and F4 are shown in **►Table 5**. TE was good for the diagnosis of fibrosis stages F2, F3, and F4; while SWE was fair for the diagnosis of fibrosis stages F1 and F2 and fairly equal for the diagnosis of stages F2 and F3. AUCs in differentiating no or

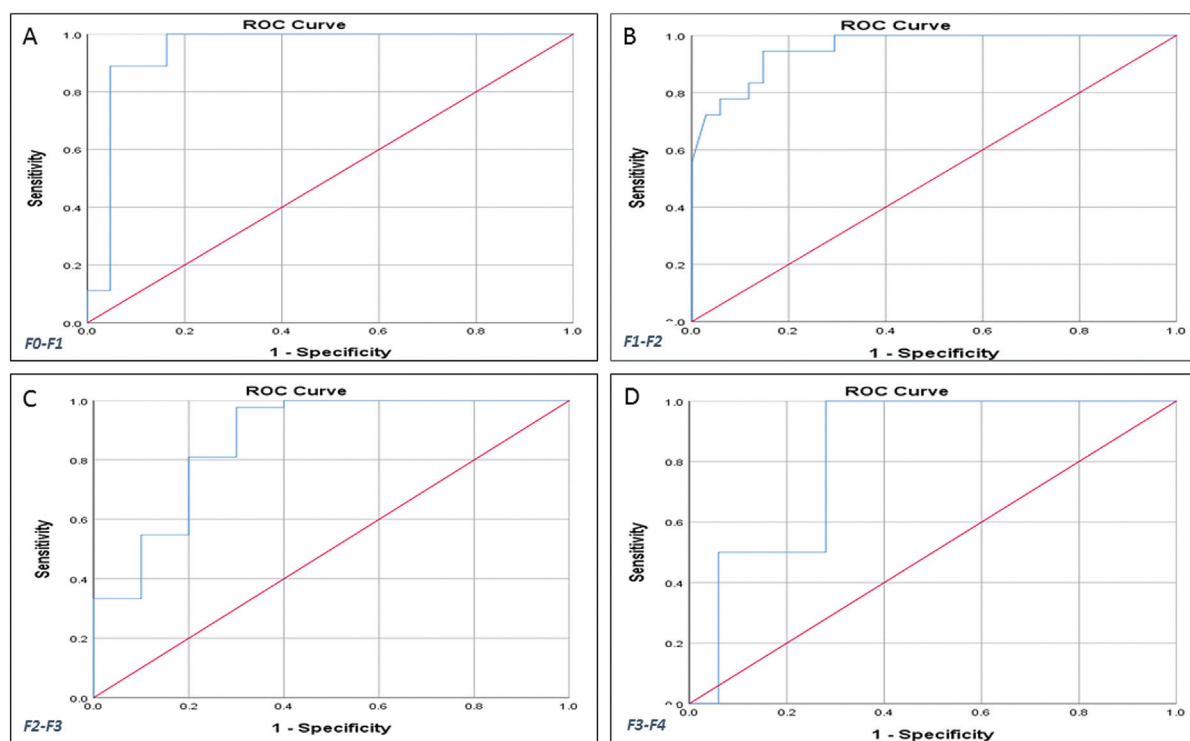


Fig. 3 Receiver operating characteristic (ROC) curve of the diagnostic performance of shear wave elastography (SWE; velocity) for the prediction of different grades of liver fibrosis in group E. Graphs show AUCs (area under the receiver operating characteristic [AUROC]) for mean SWE values at the right lobe. (A) The cutoff (AUC) value for fibrosis stage F0–F1 (normal to mild) is 1.64 (86.7). (B) The cutoff value for fibrosis stage F1–F2 (moderate) is 1.94 (95.5). (C) The cutoff value for fibrosis stage F2–F3 (severe) is 2.44 (94.6), and (D) the cutoff value for fibrosis stage F3–F4 (cirrhosis) is 2.58 (93).

Table 4 Optimal stiffness cutoff value of SWE in group E according to level fibrosis

Parameter	Cutoff (m/s)	AUC	Sensitivity	Specificity	Asymptotic 95% confidence interval	
					Lower	Upper
F0–F1 Normal–mild	1.64	86.7	81	80	72	100
F1–F2 Mild–moderate	1.94	95.5	88.9	85.3	90.6	100
F2–F3 Moderate–severe	2.44	94.6	88.9	83.7	88.3	100
F3–F4 Cirrhosis	2.58	93.0	100	72	63.3	100

Abbreviations: AUC, area under the curve; SWE, shear wave elastography.

mild fibrosis (F1) from significant fibrosis (\geq F2) were 95.5 with cutoff value of at least 1.94 m/s in the present study as seen in **Table 5**.

Discussion

Management and prognosis of CLD are highly dependent on the stage of fibrosis; hence, management of these patients relies on estimating the degree of fibrosis. Liver biopsy was one of the earliest and gold standard approaches to evaluate LF.

We assessed the clinical usefulness of LSM using SWE with various CLD in predicting the accurate site of biopsy and

the degree of LF by analyzing the SWE and histopathological results. The LS values measured by SWE showed significant correlation with severity of LF ($r = 0.88$, $p < 0.001$). Additionally, the present study results indicated that SWE had a high detection rate for significant (\geq F2) and advanced fibrosis (\geq F3; AUROC values of 0.95 and 0.94, respectively) as reported in previous literature.¹³

Biopsy Site

In our study, we only took the stiffness in the right lobe as the left lobe is the least favored site for liver biopsy.^{14,15} Also Friedrich-Rust et al¹⁶ reported that the values of the left and right LSM showed no difference statistically. Elastography

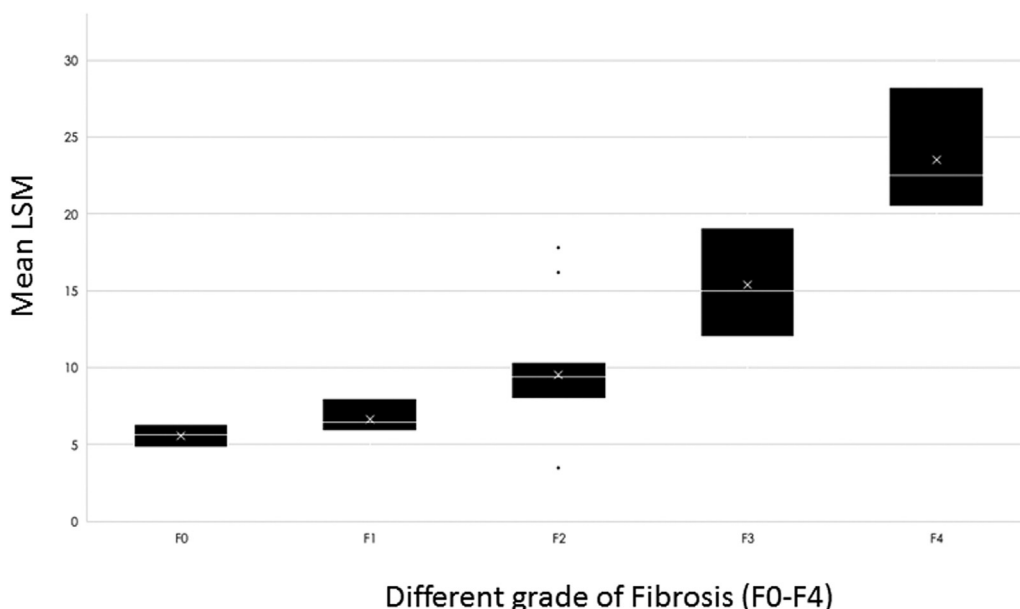


Fig. 4 Box and whisker plot shows the mean transient elastography (TE) values in the right lobe of the liver for various fibrosis stage. The top and bottom lines of each box represent the first and third quartiles (25th and 75th percentiles). The middle lines of each box are the median and the lines of the upper and lower boxes are the 5th and 95th percentiles. The error bars show the minimum and maximum values. LSM, liver stiffness measurement.

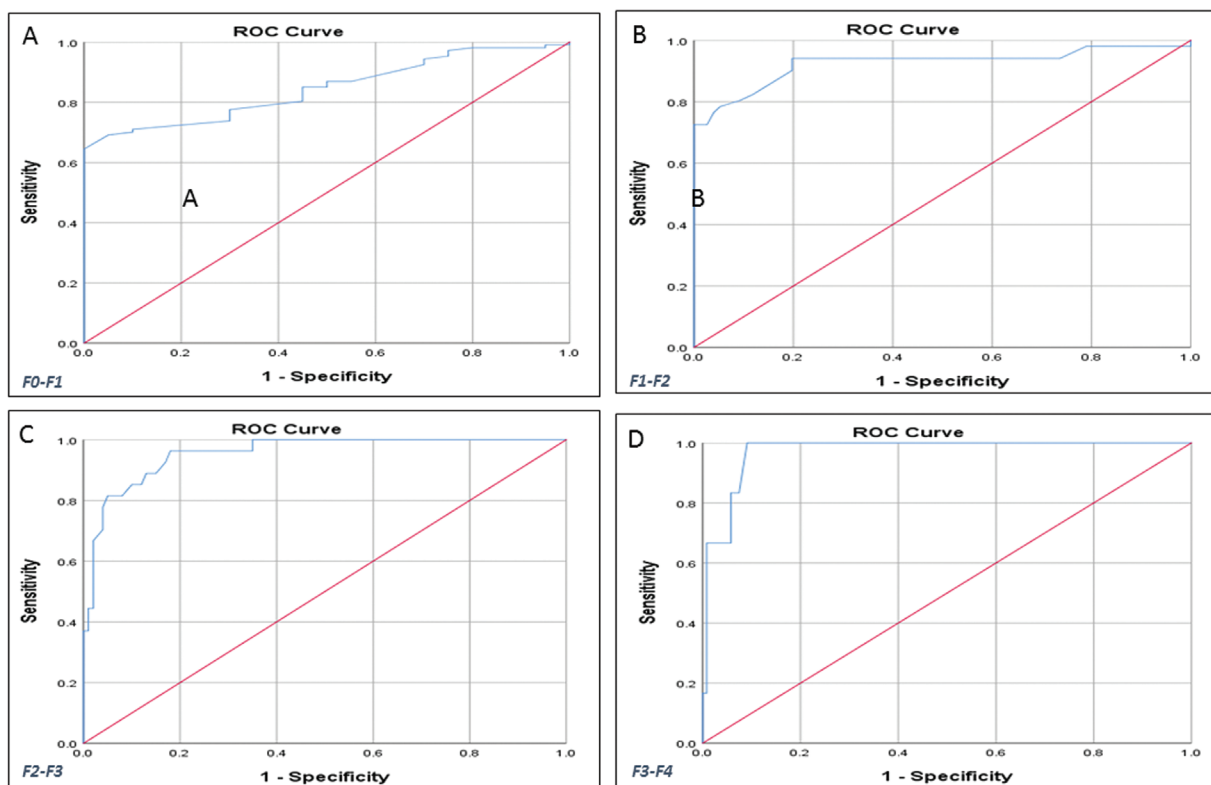


Fig. 5 Receiver operating characteristic (ROC) curve of the diagnostic performance of transient elastography (TE; LAM) for the prediction of different grades of liver fibrosis in all patients. Graphs show AUCs (area under the receiver operating characteristic [AUROC]) for the mean TE values at the right lobe to. (A) The cutoff (AUC) value for fibrosis stage F0–F1 (normal to mild) is 6.25 (84.7). (B) The cutoff value for fibrosis stage F1–F2 (moderate) is 8.5 (92.5). (C) The cutoff value for fibrosis stage F2–F3 (severe) is 9.1 (95.6). (D) The cutoff value for fibrosis stage F3–F4 (cirrhosis) is 15.5 (97.2).

Table 5 Comparison between SWE and TE

Parameter	Group	TE cutoff (kPa) SWE cutoff (m/s)	AUC (%)	Sensitivity	Specificity
F0–F1 Normal–Mild	TE	6.1	82.4	72	60
	SWE	1.64	86.7	81	80
F1–F2 Mild–moderate	TE	7.8	93.5	90.9	84.3
	SWE	1.94	95.5	88.9	85.3
F2–F3 Moderate–severe	TE	9.0	96.4	88.9	87.7
	SWE	2.44	94.6	88.9	83.7
F3–F4 Cirrhosis	TE	17.5	97.9	100	94.4
	SWE	2.58	93.0	100	72

Abbreviations: AUC, area under the curve; SWE, shear wave elastography; TE, transient elastography.

findings suggested that there was variable liver stiffness in the right lobe, which was reflected as a different velocity in the segments of the right lobe. This suggests a heterogeneous distribution of the fibrosis in the liver. This might be attributed to sinusoidal blood oxygen levels, which in turn are directly related to the proportion of blood contributed by capsular arterioles and the ratio of systemic to portal blood perfusing the segment. Liver parenchyma that is closer to the hilum or has a higher proportion of postprandial portal blood might allow fewer reactive oxygen species to form and hence a lesser degree of fibrosis.^{17,18}

Spearman's correlation between biopsy segment velocities shows that the inferior lobe/segments are better for biopsy, which was denoted by the excellent correlation with mean velocities ($r = 1$). SWE stiffness of the biopsy segments better correlates with the histopathological finding compared with the mean velocities of the right lobe. It is in contrast to the study performed by Samir et al,⁵ who noted that the accurate site of measurement of SWE stiffness is the right superior or upper lobe.

We compared the variability of the data of elastography in different segments of the right lobe and we have seen that the coefficient of variance is lowest in segment 5 (29%) compared

with other segments (>31%) for diffuse LDs. This result is in concordance with the study by Ling et al¹⁹ who revealed that the intraindividual measurements of LSM exhibited the lowest variation in segment 5 (coefficient of variation, CV 27%). Furthermore, they also stated a statistically significant difference in LSM between segments 5 and 1, 2, 3, 7, or 8 ($p < 0.05$). In contrast, in our study no significant difference was noticed in between segments 5 and 6, 7, and 8. Overall, we found that the inferior segment of the right lobe shows least variability and better correlation with LF.

Shear Wave Elastography

In the present study, we found that the AUROC was over 90% for fibrosis at stages F1–F2, F2–F3, and F3–F4, indicating that SWE is accurate in assessing LF at different stages. The AUROC increase with increase in the grade of fibrosis. This study shows that SWE has high sensitivity and specificity to analyze LF in patients with \geq F2 fibrosis stage. The AUROC of DOR (diagnostic odds ratio) was 0.90, indicating that it has a higher diagnostic performance value. In our study, SWE showed a statistically significant difference in values of the mean LS in different grades of LF. Patients with advanced LF (METAVIR: F2/F3) had higher LS than those with early stages

Table 6 Comparison of shear wave elastography (SWE) cutoff with different studies in kilopascal (kPa)

Etiology	\geq F2	\geq F3	F4	Studies
Chronic hepatitis B	7.1	7.9	10.1	Leung et al ²³
Chronic hepatitis B	8.5	11.5	18.1	Guibal et al ¹³
Nonalcoholic fatty liver disease	8.7	10.7	14.4	Tada et al ²⁴
Autoimmune liver disease	9.7	13.2	16.3	Zheng et al ²⁶
Various chronic liver diseases	8.6	10.5	14.0	Jeong et al ⁶
Various chronic liver diseases (kPa)	11.2	17.8	19.5	Present study
Shear wave velocity in different grade of fibrosis	\geq F2	\geq F3		F4
2D-SWE (ASQ) Toshiba (vendor specification)	1.76	2.21		2.86
Present study	1.92	2.44		2.58

of fibrosis (METAVIR: F0/F1). This suggests that SWE has good predicting power for different stages of LF. Moustafa et al,²⁰ Cassinotto et al,²¹ and Guibal et al¹³ showed that LS depends on the stage of fibrosis with significant relationship with liver biopsy and there was a significant difference in the LS in patients with advanced fibrosis compared to those in early stage of fibrosis.

The sensitivity for the diagnosis of significant fibrosis (\geq F2), severe fibrosis (\geq F3), and liver cirrhosis (F4) was 89.9, 89.9, and 100%, respectively, and the specificity was 85, 83.5, and 72%, respectively. These results were in concordance with study by Nierhoff J et al.²² Comparison with previous studies is summarized in ►Table 6.

SWE versus TE

The intraclass correlation coefficients (ICC) shows there was an intraobserver agreement for TE and SWE. There was excellent correlation in repeated measurements by the same operator for TE and SWE. In a study conducted by Leung et al,²³ the sensitivity and specificity of SWE in the diagnosis of LF were 85 and 92%, respectively. For diagnosis of liver cirrhosis, the sensitivity and specificity of SWE were 97 and 93%, respectively. These results are quite similar to the results in our study as noted in ►Tables 6. Tada et al²⁴ stated that SWE can be used similar to TE in the assessment of LF. A strong correlation between SWE and TE was established by Deffieux et al.²⁵ In their study for LF staging, the AUROC curves were similar for SWE and TE. Zheng et al²⁶ concluded that SWE had a higher sensitivity and specificity for diagnosis of F4 METAVIR stage as compared with lower stages, which is also seen in our results. Our results are in concordance with result of Tada et al²⁴ and Ferraioli et al,²⁷ who observed that both SWE and TE show a similar diagnostic performance in the evaluation of LS. Previous literature reports no significant association between the liver stiffness values and steatosis or inflammatory activity within the liver. In our study, we found that the degree of steatosis shows no significant correlation with the SWE velocity measurements and this finding is concordant with previous findings in the literature.^{28,29}

One major disadvantage of SWE is that there are no uniform standard values available across different US systems and the value of LS varies with different US systems developed by different manufacturers at the same degree of fibrosis. The velocity at different levels of fibrosis in the present study and vendor specification regarding the USG machine elastography is summarized in ►Table 6.

The limitations of the present study include a small sample size with a heterogeneous study population. Therefore, etiology-specific studies should be performed. Other noninvasive techniques such as magnetic resonance (MR) elastography and serum markers of fibrosis were also not used in our study. The AUROC values of liver stiffness measured using SWE is slightly lower in the present study than previously reported. This could be explained by the fact that a different hardware was used with the inclusion of a heterogeneous cohort with different causes of CLD.

Future Directions

This is a pilot study with a small sample size and future studies with a larger sample size are required to establish the accuracy of USG elastography to find the most accurate site of biopsy. With recent advancements, MR elastography-guided biopsy may produce promising results.

Conclusion

Fibrosis is a heterogeneously distributed entity as concluded by the fact that the SWE segmental mean velocity is different in different segments of the right lobe liver. Therefore, elastography-guided liver biopsy helps in defining the accurate site for biopsy and hence can improve the histopathological yield in detecting LF in patients with CLD. This also helps in recording the baseline liver stiffness, which will be helpful in follow-up. The diagnostic performance accuracy of SWE is comparable to FibroScan.

Author Contributions

Y.P. was responsible for conceptualization of the study design, project administration, resources, supervision, methodology, software, and writing and preparation of the original draft. J.S. contributed to data curation, methodology, investigation, software, validation, and writing and preparation of the original draft. N.C. was responsible for data curation, visualization, and writing, reviewing, and editing of the manuscript. A.M. was responsible for supervision, validation, and visualization. A.R. was responsible for software and resources. G.K. was responsible for formal analysis, validation, and visualization. M.K.S. was responsible for conceptualization of the study design, validation, resources, and supervision.

Funding

None.

Conflict of Interest

None declared.

References

- 1 Zhou WC, Zhang QB, Qiao L. Pathogenesis of liver cirrhosis. *World J Gastroenterol* 2014;20(23):7312–7324
- 2 Pariente D, Franchi-Abella S. Paediatric chronic liver diseases: how to investigate and follow up? Role of imaging in the diagnosis of fibrosis. *Pediatr Radiol* 2010;40(06):906–919
- 3 Bravo AA, Sheth SG, Chopra S. Liver biopsy. *N Engl J Med* 2001;344(07):495–500
- 4 Sigrist RMS, Liao J, Kaffas AE, Chammas MC, Willmann JK. Ultrasound Elastography: review of techniques and clinical applications. *Theranostics* 2017;7(05):1303–1329
- 5 Samir AE, Dhyani M, Vij A, et al. Shear-wave elastography for the estimation of liver fibrosis in chronic liver disease: determining accuracy and ideal site for measurement. *Radiology* 2015;274(03):888–896
- 6 Jeong JY, Kim TY, Sohn JH, et al. Real time shear wave elastography in chronic liver diseases: accuracy for predicting liver fibrosis, in comparison with serum markers. *World J Gastroenterol* 2014;20(38):13920–13929

- 7 Tian J, Liu Q, Wang X, Xing P, Yang Z, Wu C. Application of 3D and 2D quantitative shear wave elastography (SWE) to differentiate between benign and malignant breast masses. *Sci Rep* 2017; 7:41216
- 8 Taljanovic MS, Gimber LH, Becker GW, et al. Shear-wave elastography: basic physics and musculoskeletal applications. *Radiographics* 2017;37(03):855–870
- 9 Elkrief L, Rautou PE, Ronot M, et al. Prospective comparison of spleen and liver stiffness by using shear-wave and transient elastography for detection of portal hypertension in cirrhosis. *Radiology* 2015;275(02):589–598
- 10 Li C, Zhang C, Li J, Huo H, Song D. Diagnostic accuracy of real-time shear wave Elastography for staging of liver fibrosis: a meta-analysis. *Med Sci Monit* 2016;22:1349–1359
- 11 Kim DW, Suh CH, Kim KW, Pyo J, Park C, Jung SC. Technical performance of two-dimensional shear wave Elastography for measuring liver stiffness: a systematic review and meta-analysis. *Korean J Radiol* 2019;20(06):880–893
- 12 Bedossa P, Poynard T The METAVIR Cooperative Study Group. An algorithm for the grading of activity in chronic hepatitis C. *Hepatology* 1996;24(02):289–293
- 13 Guibal A, Renosi G, Rode A, et al. Shear wave elastography: an accurate technique to stage liver fibrosis in chronic liver diseases. *Diagn Interv Imaging* 2016;97(01):91–99
- 14 Toshima T, Shirabe K, Takeishi K, et al. New method for assessing liver fibrosis based on acoustic radiation force impulse: a special reference to the difference between right and left liver. *J Gastroenterol* 2011;46(05):705–711
- 15 Karlas T, Pfrepper C, Wiegand J, et al. Acoustic radiation force impulse imaging (ARFI) for non-invasive detection of liver fibrosis: examination standards and evaluation of interlobe differences in healthy subjects and chronic liver disease. *Scand J Gastroenterol* 2011;46(12):1458–1467
- 16 Friedrich-Rust M, Nierhoff J, Lupsor M, et al. Performance of acoustic radiation force impulse imaging for the staging of liver fibrosis: a pooled meta-analysis. *J Viral Hepat* 2012;19(02):e212–e219
- 17 Bota S, Sporea I, Sirli R, Popescu A, Dănilă M, Sendroiu M. Factors that influence the correlation of acoustic radiation force impulse (ARFI), elastography with liver fibrosis. *Med Ultrason* 2011;13(02):135–140
- 18 Goldstein NS, Hastah F, Galan MV, Gordon SC. Fibrosis heterogeneity in nonalcoholic steatohepatitis and hepatitis C virus needle core biopsy specimens. *Am J Clin Pathol* 2005;123(03):382–387
- 19 Ling W, Lu Q, Quan J, Ma L, Luo Y. Assessment of impact factors on shear wave based liver stiffness measurement. *Eur J Radiol* 2013; 82(02):335–341
- 20 Moustafa EF, Makhlouf N, Hassany SM, et al. Non-invasive assessment of liver fibrosis in patients with hepatitis C: shear wave elastography and colour Doppler velocity profile technique versus liver biopsy. *Arab J Gastroenterol* 2017;18(01):6–12
- 21 Cassinotto C, Boursier J, de Lédighen V, et al. Liver stiffness in nonalcoholic fatty liver disease: a comparison of supersonic shear imaging, FibroScan, and ARFI with liver biopsy. *Hepatology* 2016; 63(06):1817–1827
- 22 Nierhoff J, Chávez Ortiz AA, Herrmann E, Zeuzem S, Friedrich-Rust M. The efficiency of acoustic radiation force impulse imaging for the staging of liver fibrosis: a meta-analysis. *Eur Radiol* 2013;23 (11):3040–3053
- 23 Leung VY, Shen J, Wong VW, et al. Quantitative elastography of liver fibrosis and spleen stiffness in chronic hepatitis B carriers: comparison of shear-wave elastography and transient elastography with liver biopsy correlation. *Radiology* 2013;269(03): 910–918
- 24 Tada T, Kumada T, Toyoda H, et al. Utility of real-time shear wave elastography for assessing liver fibrosis in patients with chronic hepatitis C infection without cirrhosis: comparison of liver fibrosis indices. *Hepatol Res* 2015;45(10):E122–E129
- 25 Deffieux T, Gennisson JL, Bousquet L, et al. Investigating liver stiffness and viscosity for fibrosis, steatosis and activity staging using shear wave elastography. *J Hepatol* 2015;62 (02):317–324
- 26 Zheng J, Guo H, Zeng J, et al. Two-dimensional shear-wave elastography and conventional US: the optimal evaluation of liver fibrosis and cirrhosis. *Radiology* 2015;275(01):290–300
- 27 Ferraioli G, Tinelli C, Dal Bello B, Zicchetti M, Filice G, Filice C Liver Fibrosis Study Group. Accuracy of real-time shear wave elastography for assessing liver fibrosis in chronic hepatitis C: a pilot study. *Hepatology* 2012;56(06):2125–2133
- 28 Wong VW, Vergniol J, Wong GL, et al. Diagnosis of fibrosis and cirrhosis using liver stiffness measurement in nonalcoholic fatty liver disease. *Hepatology* 2010;51(02):454–462
- 29 Fierbinteanu-Braticevici C, Andronescu D, Usvat R, Cretoiu D, Baicus C, Marinoschi G. Acoustic radiation force imaging sonoe-elastography for noninvasive staging of liver fibrosis. *World J Gastroenterol* 2009;15(44):5525–5532