

Reversible ecchymosis and hyperpigmented lesions: A rare presentation of dietary Vitamin B12 deficiency

Hans Raj Pahadiya¹, Manoj Lakhotia¹, Sukhdev Choudhary¹,
Gopal Raj Prajapati¹, Sangeeta Pradhan¹

¹Department of Medicine, Dr. S.N. Medical College, Jodhpur, Rajasthan, India

ABSTRACT

A 40-year-old male presented because of generalized weakness, fatigability, and hyperpigmentation with ecchymosis, he was diagnosed to have dietary Vitamin B12 deficiency anemia. The hyperpigmentation and ecchymosis lesions resolved after Vitamin B12 supplementation. Beside hyperpigmented lesion on the skin, the presence of ecchymosis is a very rare manifestation of the disease. Thrombocytopenia in Vitamin B12 deficiency anemia rarely leads to ecchymosis.

Keywords: Ecchymosis, hyperpigmentation, Vitamin B12 deficiency

Introduction

In developing countries like India, nutritional deficiencies are prevalent, among them, the Vitamin B12 deficiency is now recognized as a common public health problem. The pure vegetarian individuals are more prone for developing dietary Vitamin B12 deficiency. The common presenting features of Vitamin B12 deficiency are because of involvement of hematologic, gastrointestinal, nervous, and rarely cutaneous systems. The cutaneous symptoms of disease are rare, these include vitiligo, angular glossitis, hyperpigmented lesions of the skin, sparse hypopigmented hairs, and hemorrhages.^[1,2] The hyperpigmentation in Vitamin B12 deficiency is explained because of increased melanin synthesis. The presence of thrombocytopenia in Vitamin B12 deficiency is common finding because of dyshemopoietic in the bone marrow. Hyperpigmentation along with ecchymosis as the first presentation of Vitamin B12 deficiency is rare. We report a 40-year-old pure vegetarian male with hyperpigmentation lesions and ecchymosis on skin because of Vitamin B12 deficiency.

Address for correspondence: Dr. Hans Raj Pahadiya,
Department of Medicine, Dr. S.N. Medical College,
Jodhpur - 342 001, Rajasthan, India.
E-mail: drhans05sms@gmail.com

These hyperpigmentation improved with Vitamin B12 supplementation.

Case Report

A 40-year-old vegetarian Hindu male presented with complaints of hyperpigmented macules predominantly over legs. He also had a history of fatigability, lethargy, and exertional breathlessness for 1 month. He denied muscle aches, abdominal pain, joint pain, fever, trauma, or blood loss from any site in the body. There was no history of chronic illness, drug intake, surgery, or bleeding disorder in his family. The vital parameters were stable. The conjunctiva was pale. There was no organomegaly and lymphadenopathy. Skin examination revealed multiple, diffuse, ecchymosed lesion scattered predominantly on the lower extremities [Figure 1a-d]. His hemogram showed hemoglobin of 9.7 g/dL, leukocytes 6120/mm³ (neutrophils 76.2%; lymphocytes 16%; monocytes 7.5%), platelets 169,000/mm³, mean corpuscular volume 87.8 fL, and mean corpuscular hemoglobin was 30.4 pg. The peripheral blood film (PBF) showed few normochromic macrocytoses, hypersegmented neutrophils, and thrombocytopenia. The Vitamin B12 level

This is an open access article distributed under the terms of the Creative Commons Attribution-NonCommercial-ShareAlike 3.0 License, which allows others to remix, tweak, and build upon the work non-commercially, as long as the author is credited and the new creations are licensed under the identical terms.

For reprints contact: reprints@medknow.com

How to cite this article: Pahadiya HR, Lakhotia M, Choudhary S, Prajapati GR, Pradhan S. Reversible ecchymosis and hyperpigmented lesions: A rare presentation of dietary Vitamin B12 deficiency. J Family Med Prim Care 2016;5:485-7.

Access this article online

Quick Response Code:



Website:
www.jfmprc.com

DOI:
10.4103/2249-4863.192343

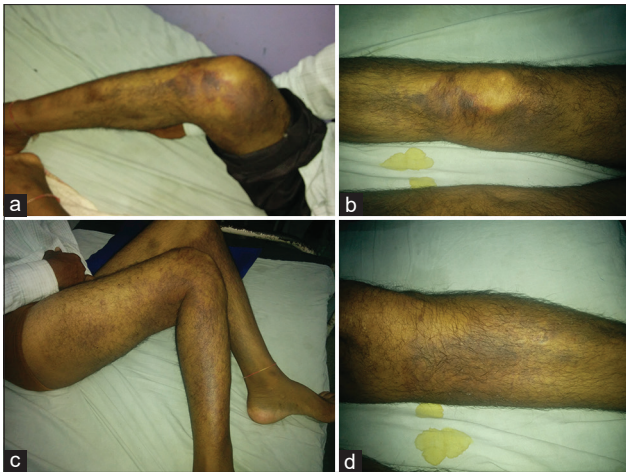


Figure 1: (a-d) Hyperpigmented ecchymosis lesions

was 272 pg/mL (normal range 211–911 pg/mL), serum lactate dehydrogenase 1250 IU/L, and serum bilirubin was 2.43 mg/dL. The bone marrow aspiration revealed megaloblastic erythropoiesis [Figure 2]. The antinuclear antibody and Coombs test were negative. The coagulation profile and iron profile were within normal limit. Renal function tests, urinalysis, and electrolytes were within normal limit. Gastroscopy, electrocardiograph, ultrasonography of abdomen, and chest X-ray did not reveal any significant abnormality. He was treated with intramuscular hydroxocobalamin 1000 µg daily for 5 days, after that alternate day for a week, and thereafter weekly for 1 month. At the follow-up of 1 month, his hematological parameters were within normal limits and ecchymosis disappeared.

Discussion

The Vitamin B12 deficiency has a varied presentation of symptoms and affects all age groups. The common presenting features of Vitamin B12 deficiency are because of involvement of hematologic, gastrointestinal, nervous, and rarely cutaneous systems. The symptoms because of anemia are fatigability, lethargy, and exertional breathlessness. The neurological symptoms include optic atrophy, ataxia, subacute combined degeneration of spinal cord, dementia, and rarely psychosis.^[1] The mucocutaneous manifestations of Vitamin B12 deficiency are less common. The cutaneous manifestations of Vitamin B12 deficiency are skin hyperpigmentation, vitiligo, angular glossitis, and sparse lustreless hypopigmented hairs. These manifestations are reversible after the Vitamin B12 supplementation.^[2,3] A hypothesis explained hyperpigmentation in Vitamin B12 deficiency due to increase synthesis of melanin with increased melanosomes in the basal layer of skin by decreasing the level of reduced glutathione, which activates tyrosinase and thus leads to transfer to melanosomes; a defect is also described in the melanin transfer between melanocytes and keratinocytes, resulting in pigmentary incontinence.^[4,5] The patients with nutritional Vitamin B12 deficiency also had bleeding manifestations and qualitative abnormalities of platelets,

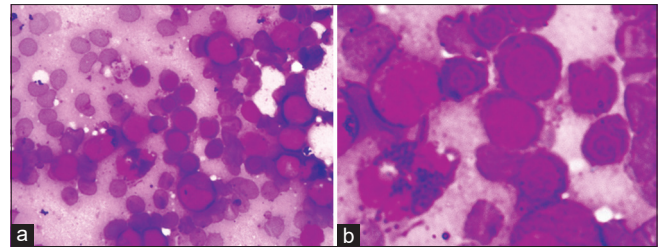


Figure 2: (a and b) Bone marrow aspiration picture showing megaloblastic cells

i.e., abnormal aggregation to adenosine diphosphate, collagen, epinephrine, and ristocetin.^[6]

Smith *et al.*^[7] reported nine cases of hemorrhagic emergencies attributable to thrombocytopenia associated with various forms of megaloblastic anemia. After blood transfusion and supplementation of Vitamin B12 or folic acid therapy all responded well. The presence of thrombocytopenia is widely recognized as part of the dyshemopoietic pattern in megaloblastic anemia. The possible presentation of a megaloblastic anemia as a hemorrhagic diathesis is explained by thrombocytopenia.

We assume that these ecchymosed lesions might be due to chronic microhemorrhages in the superficial layer of skin because of thrombocytopenia in this patient. To conclude, a patient presenting with cutaneous ecchymosis and hyperpigmentation having pallor and PBF showing macrocytic erythrocytes should be evaluated for Vitamin B12 deficiency and early Vitamin B12 supplementation should be installed to prevent further serious complications of the disease. We report this case to highlight the rare presenting feature of the Vitamin B12 deficiency.

Financial support and sponsorship

Nil.

Conflicts of interest

There are no conflicts of interest.

References

1. Oh R, Brown DL. Vitamin B12 deficiency. *Am Fam Physician* 2003;67:979-86.
2. Aaron S, Kumar S, Vijayan J, Jacob J, Alexander M, Gnanamuthu C. Clinical and laboratory features and response to treatment in patients presenting with Vitamin B12 deficiency-related neurological syndromes. *Neurol India* 2005;53:55-8.
3. Santra G, Paul R, Ghosh SK, Chakraborty D, Das S, Pradhan S, *et al.* Generalised hyperpigmentation in Vitamin B12 deficiency. *J Assoc Physicians India* 2014;62:714-6.
4. Mori K, Ando I, Kukita A. Generalized hyperpigmentation of the skin due to Vitamin B12 deficiency. *J Dermatol* 2001;28:282-5.
5. Agrawala RK, Sahoo SK, Choudhury AK, Mohanty BK,

- Baliarsinha AK. Pigmentation in Vitamin B12 deficiency masquerading Addison's pigmentation: A rare presentation. *Indian J Endocrinol Metab* 2013;17 Suppl 1:S254-6.
6. Ghosh K, Krishna V, Mohanty D. Platelet dysfunction in nutritional Vitamin B12 deficiency. *Platelets* 1991;2:153-6.
7. Smith MD, Smith DA, Fletcher M. Haemorrhage associated with thrombocytopenia in megaloblastic anaemia. *Br Med J* 1962;1:982-5.