

Adalimumab for Treatment of Idiopathic Frosted Branch Angiitis: A Case Report

Alireza Hedayatfar^{1,2}, MD; Masoud Soheilian³, MD

¹Noor Ophthalmic Research Center, Noor Eye Hospital, Tehran, Iran

²Eye Research Center, Rassoul Akram Hospital, Iran University of Medical Sciences, Tehran, Iran

³Ophthalmic Research Center, Shahid Beheshti University of Medical Sciences, Tehran, Iran

Purpose: To report a case of recurrent idiopathic frosted branch angiitis (FBA) successfully treated with adalimumab.

Case Report: A 14-year-old otherwise healthy boy was referred to the uveitis clinic for bilateral panuveitis with diffuse retinal vascular sheathing and severe macular edema. Extensive work-up including aqueous sampling for detection of viral causes was inconclusive. Two years ago, a similar episode had been treated with oral prednisolone, however it was complicated by adverse psychiatric effects. The progressive course of the condition mandated considering other therapeutic measures; Adalimumab was chosen based on its purported efficacy for treatment of childhood uveitis and a favorable safety profile. The patient responded dramatically to a single subcutaneous injection of adalimumab without any side effect during and after injection. The therapeutic effect was rapid and relatively long-lasting.

Conclusion: To the best of our knowledge, this is the first case of idiopathic FBA treated successfully with adalimumab without adjunctive steroid therapy.

Keywords: Adalimumab; Anti-Tumor Necrosis Factor; Frosted Branch Angiitis; Uveitis

J Ophthalmic Vis Res 2013; 8 (4): 372-375.

Correspondence to: Alireza Hedayatfar, MD. Noor Eye Hospital, #96 Esfandiar Blvd., Vali'asr Ave., Tehran, 196865311, Iran; Tel: +98 21 82400, Fax: +98 21 8865 0501; e-mail: ahedaiatfar@noorvision.com

Received: June 16, 2012

Accepted: January 07, 2013

INTRODUCTION

Frosted branch angiitis (FBA) is a rare disease characterised by visual disturbance associated with anterior chamber and vitreous inflammation and severe sheathing of retinal vessels resembling the appearance of frosted branches of a tree. It was originally described in a six-year-old child by Ito in 1976.¹ FBA can be associated with ocular and systemic diseases. Cytomegalovirus retinitis, acquired immunodeficiency syndrome, and toxoplasma chorioretinitis are frequent ocular associations, while systemic lupus erythematosus, Crohn's

disease, Behcet's disease, large cell lymphoma, and acute lymphoblastic leukemia have been described as systemic associations.² The idiopathic type typically occurs in young and healthy persons and is associated with good recovery of vision. Systemic steroids are the only suggested treatment for this condition. Herein we report a case of recurrent idiopathic FBA treated successfully with adalimumab.

CASE REPORT

A 14-year-old boy, who was otherwise healthy, was referred to the uveitis clinic for progressive

blurring of vision in both eyes since 1 month before.

On examination, visual acuity was 20/400 in both eyes. Anterior segment examination revealed mild ciliary injection and anterior chamber reaction (2+ cells) but no keratic precipitates or posterior synechiae. Both eyes had inflammatory reaction in the vitreous (2+ cells) but there were no snow balls or snow bank formation. Fundus examination disclosed extensive retinal vascular sheathing and scattered intraretinal hemorrhages with severe macular edema in both eyes (Fig. 1).

Systemic work-up and investigations, including a complete blood count (CBC), erythrocyte sedimentation rate (ESR), C-reactive protein (CRP) titer, angiotensin converting enzyme (ACE) titer, tuberculin skin test (TST), urine analysis and chest X-ray were unremarkable. Rheumatologic tests including antinuclear antibodies (ANA), anti double strand DNA antibody (anti ds-DNA), rheumatic factor (RF), antiphospholipid antibody, anti-neutrophil cytoplasmic antibodies (ANCA), and cryoglobulin assay were all negative. Blood CD₄ and CD₈ counts were within normal range and serology for the human immunodeficiency virus was also negative. Brain magnetic resonance imaging (MRI) did not show any abnormality. Blood serology for possible infectious causes including herpes family viruses, i.e. herpes simplex virus (HSV) type 1 and 2, varicella zoster virus (VZV), cytomegalovirus (CMV), and Epstein-Barr virus (EBV), hepatitis B and C viruses, treponema, borrelia, and toxoplasma were checked. Immunoglobulin G (IgG) levels against HSV type 2 and CMV (but not IgM) were elevated. We tested the aqueous specimen after

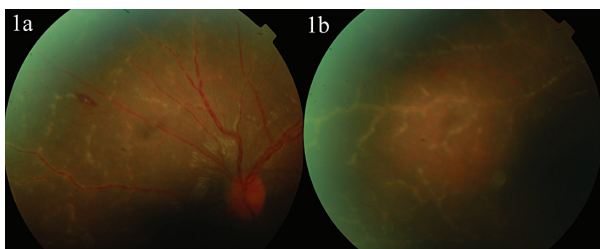


Figure 1. Color fundus photographs show diffuse and extensive retinal vascular sheathing in the left (1a) and right (1b) eyes.

an anterior chamber paracentesis to investigate the presence of deoxyribonucleic acid (DNA) of HSV type 1 and CMV viruses. The result of polymerase chain reaction (PCR) on aqueous samples was negative for both viruses.

Until the results of blood tests and aqueous PCR became ready, vision continued to deteriorate down to 20/1000 and 20/800 in the right and left eyes, respectively.

Based on the inconclusive work-up a diagnosis of idiopathic FBA was entertained and a course of systemic steroids was suggested. At this time, the patient's parents mentioned that two years ago, for treatment of a similar condition, oral prednisolone 1 mg/kg had been commenced but soon after initiation, the patient developed severe mood changes which persisted long after discontinuation of treatment. The parents therefore rejected corticosteroid treatment. The progressive nature of the condition mandated considering other therapeutic measures to prevent macular scarring. Due to the safety profile of anti-tumor necrosis factor (TNF) agents and their rapid onset of effect, adalimumab was considered as an alternative to conventional treatment for which the parents provided written informed consent. A single dose of 40 mg pre-filled adalimumab

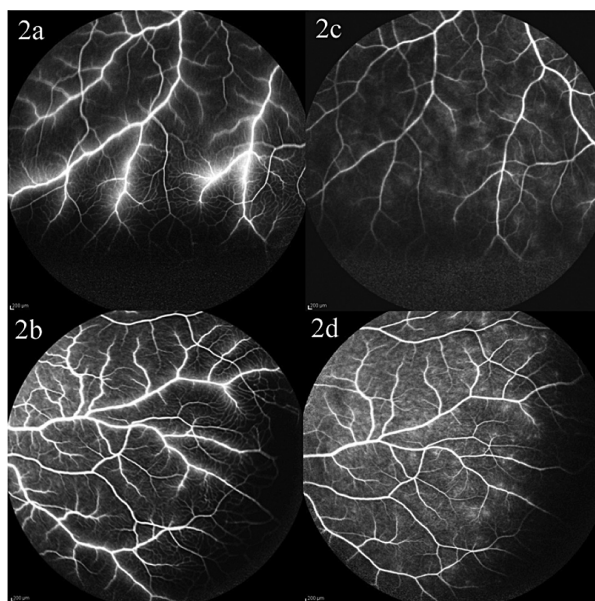


Figure 2. Fluorescein angiography: compare vascular wall staining before (2a, 2b) and three weeks after adalimumab injection. (2c, 2d)

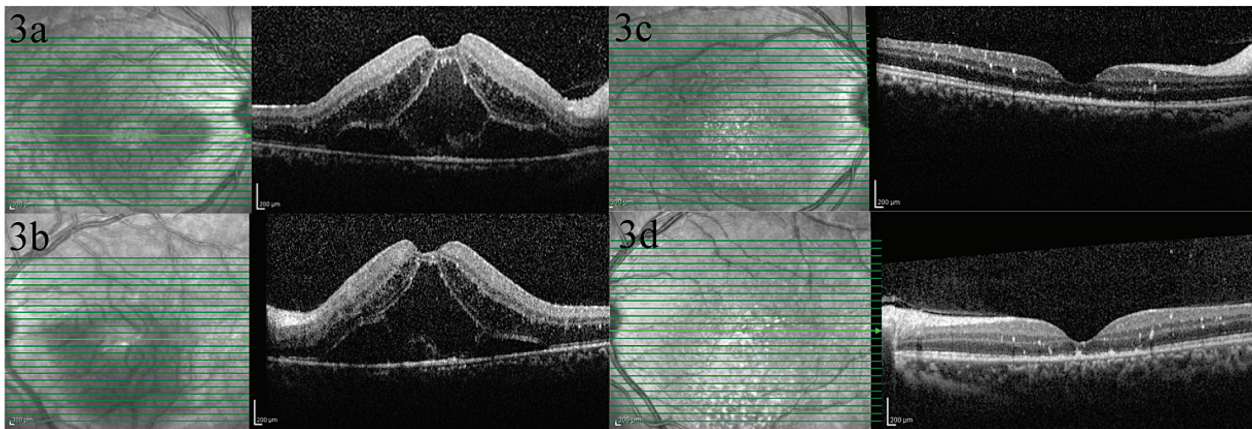


Figure 3. OCT images show large cystoid spaces in the outer retina and subretinal fluid accumulation with central retinal thickness of 916 and 978 micrometers in the right (3a) and left (3b) eyes, respectively. There was a dramatic improvement three weeks after adalimumab injection (3c, 3d).

(HUMIRA®, Abbott Laboratories, North Chicago, IL, USA) was injected subcutaneously in the patient's right thigh. No local or systemic adverse effect was noted at the time of injection or later on.

Three weeks after injection, visual acuity improved to 20/200 and 20/120 in the right and left eyes, respectively. Anterior chamber and vitreous reaction decreased to 1+ cell, and vascular sheathing and macular edema resolved dramatically. Repeat fluorescein angiography and optical coherence tomography (OCT) confirmed the improvement (Figs. 2 and 3).

10 weeks after injection, visual acuity improved to 20/40 and 20/30 in the right and left eyes, respectively. In both eyes, the anterior chambers were quiet and the vitreous had only trace cellular reaction. Clinical improvement continued up to the last visit (6 months after the injection) when visual acuity reached 20/25 in both eyes with no sign of active inflammation.

DISCUSSION

FBA is basically divided into three different subgroups.³ The first comprises patients affected by lymphoma and leukemia presenting with a frosted branch-like appearance in the fundus. The second group includes patients with associated autoimmune or viral disease which can present with FBA in association with the underlying disease. The third group consists of patients with an acute idiopathic disorder.

The characteristic feature of this latter type is its occurrence in otherwise healthy young individuals with good recovery of vision. Clinically, there is severe sheathing of retinal vessels appearing like the frosted branches of a tree, and acute visual disturbance associated with anterior chamber and vitreous inflammation; fluorescein angiography shows leakage from sheathed vessels without signs of occlusion or stasis.^{4,5} Systemic steroids are the main and only suggested treatment for this condition. In our patient however, prior adverse psychiatric effects of steroid treatment encouraged us to employ another therapeutic option: adalimumab, a fully humanized monoclonal anti-TNF antibody, was chosen based on its suggested effect for treatment of refractory childhood uveitis including juvenile idiopathic arthritis.⁶⁻⁸

Our patient responded dramatically to a single subcutaneous injection of adalimumab. The improvement was rapid and long lasting and the patient did not report any side effect during follow up.

Review of the literature revealed no other therapeutic option for treatment of idiopathic FBA except systemic steroids. To our best knowledge, this is the first case of idiopathic FBA treated successfully with an anti-TNF agent without adjunctive steroid therapy.

Conflicts of Interest

None.

REFERENCES

1. Ito Y, Nakano M, Kyu N, Takeuchi M. Frosted branch angiitis in child. *Jpn J Clin Ophthalmol* 1976;30:797-803.
2. Walker S, Iguchi A, Jones NP. Frosted branch angiitis: A review. *Eye (Lond)* 2004;18:527-533.
3. Kleiner RC. Frosted branch angiitis: clinical syndrome or clinical sign? *Retina* 1997;17:370-371.
4. Watanabe Y, Takeda N, Adachi-Usami E. A case of frosted branch angiitis. *Br J Ophthalmol* 1987;71:553-558.
5. Geier SA, Nasemann J, Klauss V, Kronawitter U, Goebel FD. Frosted branch angiitis in patient with acquired immune deficiency syndrome. *Am J Ophthalmol* 1992;113:203-205.
6. Gallagher M, Quinones K, Cervantes-Castañeda RA, Yilmaz T, Foster CS. Biological response modifier therapy for refractory childhood uveitis. *Br J Ophthalmol* 2007;91:1341-1344.
7. Biester S, Deuter C, Michels H, Haefner R, Kuemmerle-Deschner J, Doycheva D, et al. Adalimumab in the therapy of uveitis in childhood. *Br J Ophthalmol* 2007;91:319-324.
8. Kotaniemi K, Säilä H, Kautiainen H. Long-term efficacy of adalimumab in the treatment of uveitis associated with juvenile idiopathic arthritis. *Clin Ophthalmol* 2011;5:1425-1429.