

Bilateral superficial cervical plexus block with or without low-dose intravenous ketamine analgesia: effective, simple, safe, and cheap alternative to conventional general anesthesia for selected neck surgeries

Sandip Mukhopadhyay¹
Mausumi Niyogi²
Manotosh Dutta³
Ritam Ray³
Ganesh Chandra Gayen³
Monoj Mukherjee³
Basabdatta Samanta
Mukhopadhyay⁴

¹Department of Pharmacology, Christian Medical College, Ludhiana, Punjab, ²Department of Anesthesiology, Burdwan Medical College, Burdwan, West Bengal, ³Department of ENT, Burdwan Medical College, Burdwan, West Bengal, ⁴Department of Biochemistry, Christian Medical College, Ludhiana, Punjab, India

Correspondence: Sandip Mukhopadhyay
Department of Pharmacology,
Christian Medical College, Ludhiana,
Punjab, PIN-141008 India
Tel +91 98 8882 1984
Email sandipcmcl@gmail.com

Background: General anesthesia is commonly used for surgery in the neck region. Superficial cervical plexus block is adequate to produce anesthesia in the anterior and anterolateral aspects of the neck. Our aim was to observe the effectiveness of bilateral cervical plexus block for surgery in this region of the neck.

Methods: A total of 136 neck surgery cases were enrolled in this prospective uncontrolled study. All patients were administered ropivacaine 0.5% as a bilateral cervical plexus block. The incision line was infiltrated with lignocaine 1% and adrenaline 1:100,000. For thyroglossal cyst and thyroglossal fistula, an additional 1.5 mL of LA solution was deposited over the hyoid bone on both sides of the midline. Any anesthetic inadequacy was corrected using ketamine 25 mg intravenously and repeated if necessary.

Results: Of 37 patients with thyroglossal cyst, the block was sufficient in 36 patients, and one patient required ketamine. Block was adequate in 23 of 24 patients with thyroglossal fistula, and one patient required ketamine. Among the branchial cyst and branchial fistula cases, six of 16 patients required ketamine supplementation. Of three thyroidectomy patients, one required ketamine supplementation, and one was converted to conventional general anesthesia. For lymph node excision and lymph node biopsy patients, LA block was sufficient in all 31 cases. In the last group, one of 25 patients required ketamine supplementation.

Conclusion: The overall success of bilateral cervical plexus block as a sole method of anesthesia in these selected neck surgeries was 91.9% and with low-dose ketamine supplementation it approached more than 99%. However, cervical plexus block was not a good method of anesthesia for thyroid surgery in this study. For the remainder of cases, bilateral cervical plexus block alone or in conjunction with ketamine appeared to be a cheap, safe, and effective alternative to conventional general anesthesia.

Keywords: superficial cervical plexus block, neck surgery, thyroglossal cyst, thyroglossal fistula, branchial cyst, ketamine

Introduction

The superficial cervical plexus supplies the skin of the anterolateral neck via the anterior primary rami of the second to fourth cervical nerves,¹ and block of this plexus anesthetizes the areas of the anterior triangle of the neck. The anterior triangle and anterolateral part of the neck are prone to different types of neck swelling or

pathology, and different types of neck surgery are done in this area. Superficial cervical plexus block alone or in conjunction with deep cervical plexus block is frequently attempted for carotid endarterectomy and postoperative analgesia for neck surgery. The literature suggests that superficial cervical plexus block has similar results to combined cervical plexus block.² Superficial cervical plexus block is probably sufficient for thyroid surgery, although use of regional anesthesia in thyroid surgery remains controversial.³ In a prospective, uncontrolled study, we undertook different types of neck surgery using bilateral cervical plexus block as the sole anesthetic procedure in a series of 136 cases. The purpose of the study was to evaluate the effectiveness of bilateral cervical plexus block as an alternative to general anesthesia for some selected types of neck surgery. Our aim was to find a safe and cheaper alternative to conventional general anesthesia for common neck surgery.

Materials and methods

After approval from the hospital ethics committee, 136 cases (Table 1) were enrolled over a period of 18 months. The cases were scheduled for different types of neck surgery, namely excision of thyroglossal cyst, thyroglossal fistula, or branchial fistula, lymph node biopsy/excision, thyroidectomy, and other neck swellings, including sebaceous cyst, lipoma, and granuloma. The patients were selected from the age group 16–50 years, ASA (American Society of Anesthesiologists) grade I or II, and weight 50–70 kg. Informed consent was obtained from all patients who were willing to undergo neck surgery whilst awake under local anesthesia and sedation. Patients not fulfilling these inclusion criteria, not providing informed consent, with coagulopathy or a history of coagulopathy, unwilling to undergo surgery under local anesthesia, with a large tumor size (>5 cm in diameter), with a tumor approaching the posterior border of the sternocleidomastoid or beyond or with retrosternal extension, hypertension, diabetes, a history of epilepsy, neuropathy, infection in the injection area, or obesity were excluded.

Table 1 Indications for neck surgery

Group	Type of surgery	Male	Female	Total
1	Thyroglossal cyst	21	16	37
2	Thyroglossal fistula	14	10	24
3	Branchial cyst	4	1	5
4	Branchial fistula	7	4	11
5	Thyroidectomy	1	2	3
6	Lymph node excision/biopsy	16	15	31
7	Others	11	14	25
Total		74	62	136

Patients with communication problems such as dementia, a language barrier, or mental retardation were also excluded. The primary endpoint of the study was successful bilateral cervical plexus block cases adequate for neck surgery as the sole method of anesthesia. The secondary endpoints were surgical cases requiring ketamine supplementation along with bilateral cervical plexus block, overall safety of the procedure, and any adverse drug reactions. Conversion to general anesthesia was taken as failure.

All patients were given ranitidine 300 mg, metoclopramide 10 mg, and lorazepam 1 mg 6 hours before surgery. On the operating table, intravenous midazolam 1.5–2.0 mg and pentazocine 15 mg were administered to the patient slowly. Ropivacaine 0.5% was administered bilaterally to all patients as a superficial cervical plexus block. The total volume used was 12–14 mL (6–7 mL on each side). The block was performed in the following manner. After antiseptic dressing, a line was drawn from the tip of the mastoid process to the transverse process (Chassaignac's tubercle) of the C6 vertebra along the posterior border of the clavicular head of the sternocleidomastoid muscle (Figure 1). The site of needle insertion was marked at the midpoint of the line. The branches of the superficial cervical plexus emerge behind the posterior border of the sternocleidomastoid muscle. Local anesthetic was injected along the posterior border of the sternocleidomastoid muscle 2–3 cm below and above the needle insertion site by a "fan" technique with superior–inferior needle redirection,⁴ using a 1.5-inch 25-gauge needle. The depth of needle insertion was 1.0–1.5 cm to avoid the risk of deeper block or inadvertent injection. For patients in whom hyoid resection was planned as a part of their surgery, an additional 1.5 mL of local anesthetic was injected over the hyoid bone approximately 1 cm lateral to the midline on both sides. Lignocaine 1% with adrenaline 1:100,000 in a volume of 3–4 mL was infiltrated along the incision line in all patients. The local infiltration volume was reduced or omitted in lymph node biopsy/excision cases where nodes were small, single, and very superficial. The onset of action for this block is 10–15 minutes, and the first sign of nerve blockade is decreased sensation in the area of distribution of the respective components of the cervical plexus. All patients were positioned in neck extension for ease of surgery at the request of the surgeon. Oxygen was administered to all patients via a simple face mask. The duration of surgery was 35–110 minutes. Monitoring of blood pressure and heart rate, electrocardiography, and pulse oximetry was done in the intraoperative period. If intraoperative anesthesia was inadequate, ketamine was administered as a slow intravenous

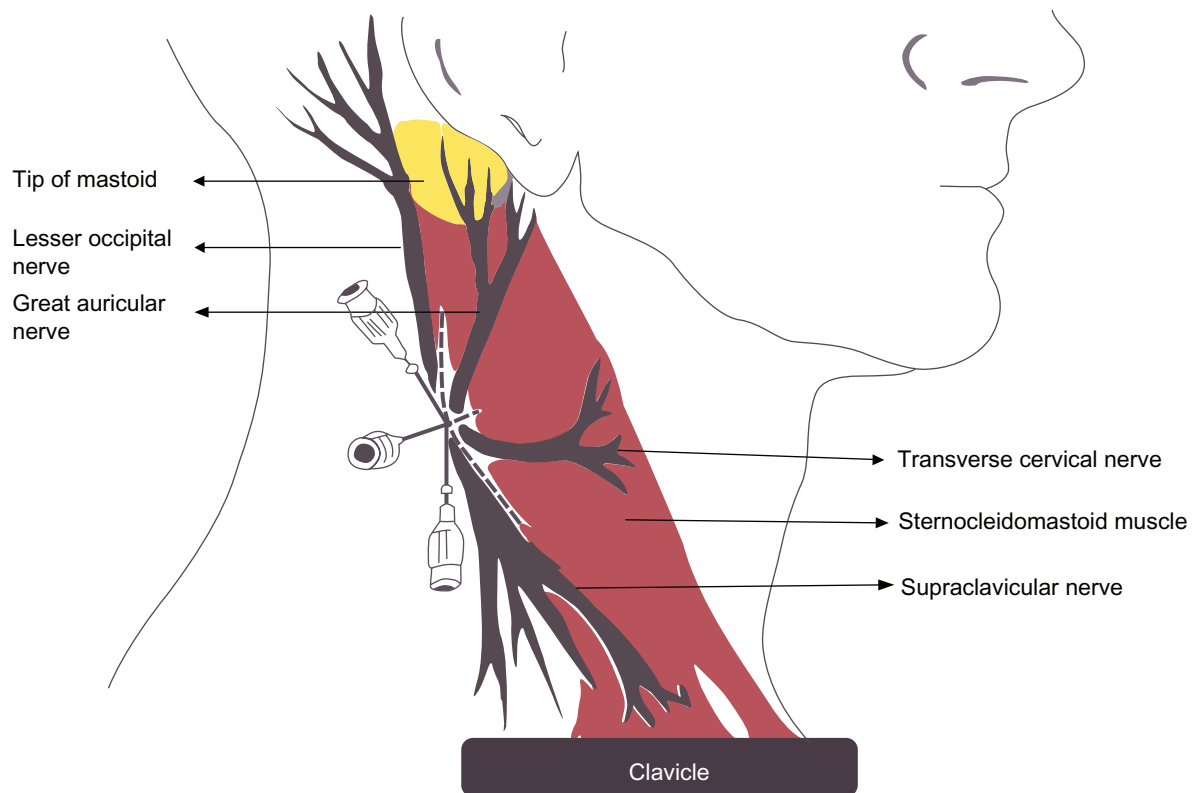


Figure 1 Anatomy of superficial cervical plexus of neck.

Notes: Needle insertion point is along the posterior border of the sternocleidomastoid muscle in the midpoint between the line joining the mastoid tip with the transverse process of the C6 vertebra. The needle shows the method of local anesthetic deposition in a “fan”-shaped manner.

25 mg push initially followed by similar or lower doses as and when required.

Results

The results are summarized in Table 2. Of 37 patients with a thyroglossal cyst, one required supplemental ketamine at a dose of 25 mg as a single intravenous bolus. At this dose, we did not find any significant respiratory depression or signs of significant desaturation on pulse oximetry.

Of 24 patients with thyroglossal fistula, one required a single intravenous dose of ketamine 25 mg. Cervical plexus block was sufficient for anesthesia in the remainder of the patients. Of five patients with a branchial cyst, cervical plexus block alone was effective in three patients and two required ketamine. Cervical plexus block alone was effective in seven of 11 patients with a branchial fistula, and four patients required ketamine when dissection of the fistula went too high and there was pulling of the sinus tract.

Table 2 Outcomes of different types of neck surgery

Group	Name/Type of surgery	Total	Median duration (minutes)	SCB alone	Ketamine	Converted/Failure	Abandoned
1	Thyroglossal cyst	37	43	36	1	0	0
2	Thyroglossal fistula	24	43	23	1	0	0
3	Branchial cyst	5	52	3	2	0	0
4	Branchial fistula	11	52	7	4	0	0
5	Thyroidectomy	3	110	1	1	1	0
6	Lymph node excision/biopsy	31	48	31	0	0	0
7	Others	25	40	24	1	0	0
	Total	136	–	125	10	1	0

Notes: Of 136 cases, 125 were successfully dealt with by SCB alone. Ketamine supplementation was required in 10 cases. Only one case was converted to general anesthesia.

Abbreviation: SCB, superficial cervical plexus block.

The dose of ketamine required was 25 mg intravenously for three patients and 35 mg for one patient. However, there was no significant respiratory depression or oxygen desaturation noted on pulse oximetry. The study also included three patients with thyroidectomy. The average duration of surgery was 110 minutes for these patients. Ketamine was required in one patient, and was given as a slow 25 mg intravenous push followed by a repeat of 10–20 mg on four occasions. One patient was converted to complete general anesthesia because of anxiety due to dragging pain during dissection and was not willing to continue surgery whilst awake. Of 31 patients scheduled for lymph node excision/biopsy, none required an additional dose of any anesthetic agent after the block. Superficial cervical plexus block alone was effective in 24 of 25 patients undergoing other types of surgery, with ketamine administered to one patient as a 25 mg intravenous push.

Discussion

Superficial cervical plexus block causes anesthesia of the anterior triangle of the neck through the anterior primary rami of C2–C4. The individual nerves emerge as four distinct nerves from the posterior border of the sternocleidomastoid muscle. The lesser occipital nerve usually is a direct branch from the main stem of the second cervical nerve. The larger remaining part of this stem then unites with part of the third cervical nerve to form a trunk that arises as the greater auricular and transverse cervical nerves. Another part of the third cervical nerve runs downward to unite with a major part of the fourth to form the supraclavicular trunk, which then divides into the three groups of supraclavicular nerves. The branches of the superficial cervical plexus are through ascending branches and descending branches. The GALA (General Anesthetic versus Local Anesthetic) study tested the hypothesis that local anesthesia is safer than general anesthesia in a large population undergoing carotid endarterectomy.¹ Many local anesthetic techniques, including superficial cervical plexus block, are relatively low risk procedures.⁵

Hematoma formation is a risk associated with this procedure. The risk is greater in anticoagulated patients, so these were not included in our study. Gentle and steady pressure for five minutes was sufficient when any vein or artery was inadvertently punctured. Blockade of the phrenic nerve does not occur after superficial cervical plexus block, but is common with deep cervical plexus block. Bilateral deep cervical block may create severe respiratory insufficiency due to diaphragmatic palsy and therefore is not recommended.

Central nervous system toxicity is the most serious consequence of cervical plexus block. This complication occurs because of the rich vascularity of the neck, including the vertebral and carotid artery vessels, and is usually caused by inadvertent intravascular injection of local anesthetic rather than absorption. Frequent careful aspiration must be done while injecting the local anesthetic.

Spinal anesthesia is a definite risk but rare. This complication may occur with injection of a larger volume of local anesthetic inside the dural sleeve accompanying the nerves of the cervical plexus. Avoidance of high volume and pressure during injection are the best measures to avoid this complication. Careful and frequent aspiration should be performed during the operation.

In our study, we found no major complications and only some minor hematomas. Most surgery performed to the front of the neck is in the area supplied by branches from the superficial cervical plexus, so block can be performed easily, even without the help of a nerve locator.

With regard to thyroid surgery, different combinations of superficial cervical plexus block with general anesthesia or deep cervical plexus block were tried at different times. It was found that bilateral superficial cervical plexus block reduces the number of general anesthetics required during thyroidectomy. It also significantly lowers the severity of postoperative pain during the first 24 hours and shortens the hospital stay.⁶ Superficial cervical block may not be able to cover deeper compartments to alleviate pain on swallowing. We do not use deep cervical block because of the higher rate of complications, such as intravenous injection, hematoma, nerve injury, and unintended blockade of the vagus nerve, brachial plexus,⁷ or phrenic nerve.⁸

The percentage success rate of bilateral cervical plexus block is shown in Figure 4. Regarding excision of thyroglossal cysts and thyroglossal fistulas, the block along with incision line infiltration and 1 mL of local anesthetic deposited over either side of the hyoid bone was successful in 97% and 95.8% of cases, respectively, and with low-dose ketamine supplementation the success rate approached 100% in both groups. All the patients were comfortable and had good pain relief during the postoperative period. No complication was noted in patients given low-dose ketamine, and there was no delay in their recovery other than slight drowsiness.

Ketamine supplementation was necessary in 40% of patients with a branchial cyst. Otherwise the procedures were uneventful (Figures 2 and 3). No patient received more than 50 mg of ketamine. Postoperative recovery was uneventful.

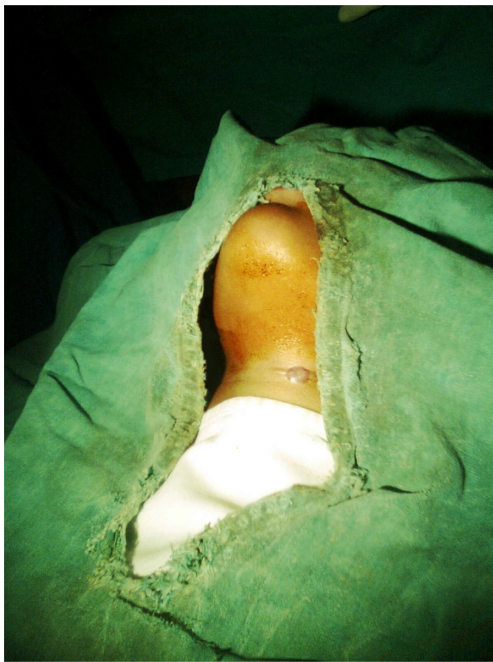

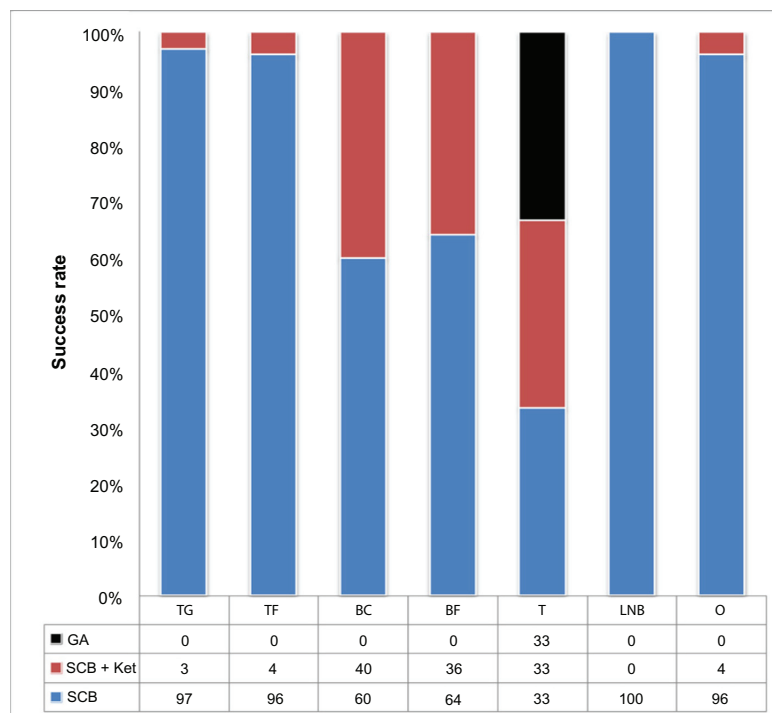
Figure 2 Case of branchial fistula before surgery.

Notes: Bilateral superficial cervical plexus block is administered to the patient after light sedation with midazolam and pentazocine. Neck extension is applied for surgical reasons. With this much neck extension, the patient had no discomfort and maintained a state of arousable sleep without any oxygen desaturation.

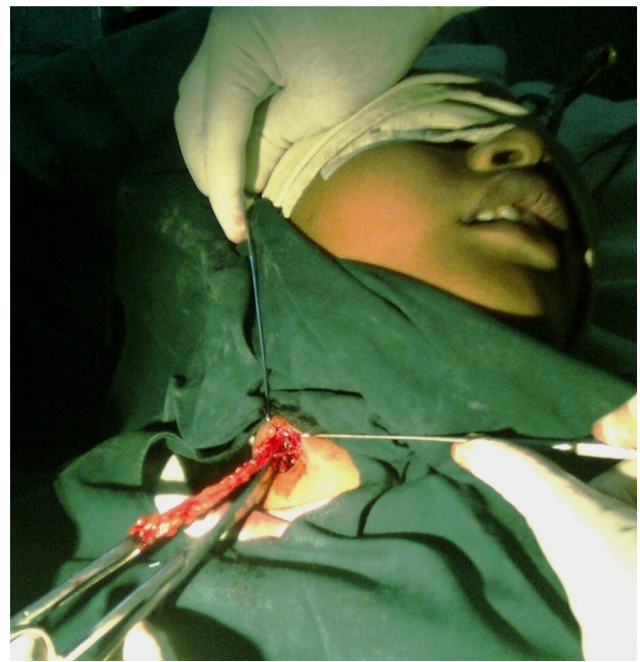

Figure 3 A 17-year-old male patient with branchial fistula during excision with bilateral superficial cervical plexus block.

Notes: The patient was under light arousable sedation and maintained adequate oxygen saturation even without administration of oxygen. (Nasal oxygen prong was removed because the patient was not willing to keep it and still had no problem with oxygen saturation).



Types of surgery and methods of anesthesia (in percent)

Figure 4 Surgical success of superficial cervical plexus block shown as a percentage.

Notes: Percentage of patients in whom bilateral SCB was successful is shown as blue bars, and patients who received ketamine in addition is shown in red. Conversion to GA was considered to be treatment failure (shown in black). The success rate (percentage) is shown along the y axis for the different groups of patients (x-axis).

Abbreviations: GA, general anesthesia; SCB, superficial cervical plexus block; Ket, ketamine; TG, thyroglossal cyst; TF, thyroglossal fistula; BC, branchial cyst; BF, branchial fistula; T, thyroidectomy; LNB, lymph node biopsy; O, others.

In the branchial fistula group, ketamine supplementation was required in 36% of patients. However, it must be noted that the incisions were made at different levels of the neck and there was application of traction over the dissected tract for ease of dissection. This created a type of dragging pain in one patient who was eventually given a dose of ketamine.

For lymph node biopsy, block was successful in 100% of cases. There was no need for ketamine or any other anesthesia in any of these patients. For other short superficial procedures in the anterolateral aspect of the neck, deep cervical block alone was effective in 96% of cases.

Local anesthesia has been used successfully as an effective alternative to general anesthesia for thyroid surgery and was reported to be associated with low morbidity and high levels of patient satisfaction.⁹ Another study reported same-day discharge following sutureless thyroid surgery under local anesthesia with an endothermal bipolar vessel-sealing system.⁵ This study in an unselected group of thyroidectomy patients suggested that local anesthesia has similar outcomes and morbidity rates to those of general anesthesia.¹⁰ It is likely that the costs associated with local anesthesia are lower. In our study, block was successful to some extent, but this was not adequate for continuation of surgery in most cases. There was a need for additional drugs in two cases. This was probably due to dissection being required to a deeper plain of the neck and even over the trachea, which was not well covered by the block. Moreover, there was dragging pain

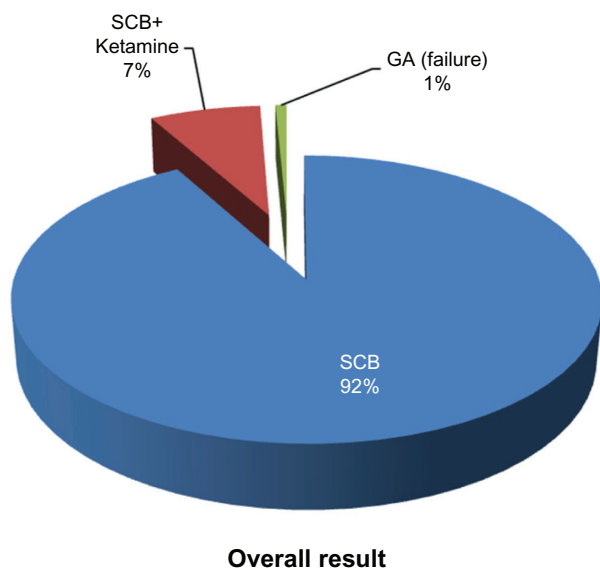


Figure 5 Overall success of bilateral cervical plexus block.

Notes: Bilateral SCB was successful in 92% of cases, ketamine supplementation was required in 7% of cases, and failure (conversion to GA) was required in less than 1% cases.

Abbreviations: SCB, superficial cervical plexus block; GA, general anesthesia.

Table 3 Cost-effectiveness of superficial cervical plexus block

Item	Cost (GA) US\$	Cost (SCB) US\$	Cost (SCB + ketamine) US\$
Drugs	10–14	3–3.5	4–4.5
Gas	12	0	0
Oxygen	2	1	1
Volatile anesthetic agent	6–20	0	0
Recovery (8–24-hour stay)	20	0	0
Total	50–68	4–4.5	5–5.5

Notes: This table compares the average minimum cost (drugs only) involved in conventional GA with the average maximum cost involved in SCB and SCB + ketamine anesthesia in a nonmetropolitan, semiurban area in India. Duration of surgery was the median duration of all surgeries (from Table 2), ie, 48 minutes. The cost of GA is expected to increase when the duration of surgery is longer. However, the cost of SCB is not increased for the surgeries mentioned in this study. The cost of SCB is calculated taking the sum of the cost of a 20 mL ropivacaine 0.5% ampoule, a lignocaine 2% vial, and injectable adrenaline, pentazocine, and midazolam. The SCB + ketamine group had the added cost of an additional 2 mL vial of ketamine 100 mg, one ampoule of glycopyrrrolate, and a 4 mg ampoule of ondansetron. Therefore, even the minimum cost of GA was more than 10 times that of the SCB or SCB + ketamine groups for similar types of surgery. The cost of consumables, eg, tracheal tubing, was not included. Recovery stay costs include oxygen, oxygen delivery consumables, and a minimum one-day stay; the actual cost of stay may be more. The cost of GA would increase further in larger facilities and in big cities in India by 5–10-fold (including theater charges, recovery stay costs, consumables).

Abbreviations: SCB, superficial cervical plexus block; GA, general anesthesia.

while dissecting out the gland from the deeper structures which seemed uncomfortable for one patient, in whom there was a need for additional anesthetic. A pressure and dragging sensation produced enough anxiety and discomfort to make the patient uncooperative with the procedure under local anesthesia, so this case was converted to general anesthesia with intubation. Bilateral superficial cervical block alone was not a good option for thyroid surgery in our study, so was not used in further patients requiring thyroidectomy.

The overall success of bilateral superficial cervical block in the selected neck surgeries in this study was 91.9% when used as a sole method of anesthesia, and approached more than 99% with low-dose ketamine supplementation (Figure 5). From the cost point of view, superficial cervical block was much cheaper compared with general anesthesia (Table 3). The cost of general anesthesia is calculated only in terms of cost of drugs, anesthetic gases/agents, oxygen, and cost of consumables, drugs, and oxygen in recovery room in uncomplicated surgeries.

Conclusion

In our study, bilateral superficial cervical block with low-dose ketamine appeared to be a very effective method of anesthesia for neck surgery to the anterior and partly to the lateral aspect of the neck, except for thyroid surgery. It was characterized by rapid recovery from anesthesia,

good analgesia, and a relatively incident-free postoperative period. Moreover, the expenditure on anesthesia was very small when compared with conventional general anesthesia and intubation, which is commonly used in neck surgery. Therefore, we can conclude that bilateral superficial cervical block with or without low-dose ketamine supplementation is a cheap, safe, and effective alternative to general anesthesia for neck surgery to the anterolateral aspect of the neck.

Acknowledgments

Ashok Dandapath is acknowledged for his moral support during this research, as well as the late Niranjan Maitra for his inspirational work.

Disclosure

The authors report no conflicts of interest in this work.

References

1. Standing S, Borley NR, Collins P, et al, editors. *Gray's Anatomy: The Anatomical Basis of Clinical Practice*. 40th ed. London, UK: Churchill Livingstone Elsevier; 2008.
2. Ivanec Z, Mazul-Sunkol B, Lovricević I, et al. Superficial versus combined (deep and superficial) cervical plexus block for carotid endarterectomy. *Acta Clin Croat*. 2008;47:81–86.
3. Andrieu G, Amrouni H, Robin E, et al. Analgesic efficacy of bilateral superficial cervical plexus block administered before thyroid surgery under general anaesthesia. *Br J Anaesth*. 2007;99:561–566.
4. Claudio R. Superficial cervical plexus block. Available from: http://www.nysora.com/peripheral_nerve_blocks/nerve_stimulator_techniques/3103-superficial-cervical-plexus-block.html. Accessed January 6, 2011.
5. Bodenham AR, Howell SJ. General anaesthesia vs local anaesthesia: an ongoing story. *Br J Anaesth*. 2009;103:785–789.
6. Shih ML, Duh QY, Hsieh CB, et al. Bilateral superficial cervical plexus block combined with general anesthesia administered in thyroid operations. *World J Surg*. 2010;34:2338–2343.
7. Inabnet WB, Shifrin A, Ahmed L, Sinha P. Safety of same day discharge in patients undergoing sutureless thyroidectomy: a comparison of local and general anesthesia. *Thyroid*. 2008;18:57–61.
8. Weiss A, Isselhorst C, Gahlen J, et al. Acute respiratory failure after deep cervical plexus block for carotid endarterectomy as a result of bilateral recurrent laryngeal nerve paralysis. *Acta Anaesthesiol Scand*. 2005;49:715–719.
9. Hisham AN, Aina EN. A reappraisal of thyroid surgery under local anaesthesia: back to the future? *ANZ J Surg*. 2002;72:287–289.
10. Spanknebel K, Chabot JA, DiGiorgi M, et al. Thyroidectomy using monitored local or conventional general anesthesia: an analysis of outpatient surgery, outcome and cost in 1,194 consecutive cases. *World J Surg*. 2006;30:813–824.

Local and Regional Anesthesia

Publish your work in this journal

Local and Regional Anesthesia is an international, peer-reviewed, open access journal publishing on the development, pharmacology, delivery and targeting and clinical use of local and regional anesthetics and analgesics. The journal welcomes submitted papers covering original research, basic science, clinical studies, reviews & evaluations,

Submit your manuscript here: <http://www.dovepress.com/local-and-regional-anesthesia-journal>

Dovepress

guidelines, expert opinion and commentary, case reports and extended reports. The manuscript management system is completely online and includes a very quick and fair peer-review system, which is all easy to use. Visit <http://www.dovepress.com/testimonials.php> to read real quotes from published authors.