

**Case
Report**

An Unusual Foreign Body in the Heart: A Case Report

Supomo, MD, PhD and Handy Darmawan, MD

Penetrating foreign bodies in the heart is rare and may lead to life-threatening complications. Early diagnosis and removal are crucial for these rare cases. We report a case of accidental penetrating sewing needle in the right ventricle. The needle was successfully removed without open heart surgery and cardiopulmonary bypass (CPB), after accurate localization using transthoracic echocardiography (TTE).

Keywords: cardiopulmonary bypass, echocardiography, foreign bodies, heart ventricles, needles

Introduction

Accidental penetration of sewing needle in the heart is rare and may lead to life-threatening complications. The needle can rapidly migrate through the tissues, which can result in cardiac tamponade, hemothorax, and pneumothorax. In the absence of migration, mural thrombi and endocarditis may occur. Therefore, early diagnosis and prompt removal were lifesaving and recommended.¹⁾ There were only three cases of accidental needle penetration in the heart and all of them required an open heart surgery with cardiopulmonary bypass (CPB).²⁾ In this report, we describe a case of an accidental penetrating needle in the heart, which was successfully removed without open heart surgery and CPB after accurate localization using transthoracic echocardiography (TTE).

Thoracic and Cardiovascular Surgery Division, Department of Surgery, Dr. Sardjito General Hospital, Universitas Gadjah Mada, Yogyakarta, Indonesia

Received: July 6, 2017; Accepted: August 3, 2017

Corresponding author: Supomo, MD, PhD. Department of Surgery, Faculty of Medicine, Dr. Sardjito General Hospital, Universitas Gadjah Mada, Kesehatan Street, Sekip, Sinduadi, Mlati, Sleman, Yogyakarta 55281, Indonesia

Email: supomo.tkv@mail.ugm.ac.id

©2018 The Editorial Committee of *Annals of Thoracic and Cardiovascular Surgery*. This work is licensed under a Creative Commons Attribution-NonCommercial-NonDerivatives International License.

Case Report

A 14-year-old male was consulted to our department with a history of accidental sewing needle penetration through his chest. An exploration surgery had been performed 6 days before admission in the previous rural hospital without knowing the exact location of the needle, thus end as a failure. Vital signs were normal. A simple chest X-ray displayed a needle in the chest (**Fig. 1**). The needle was demonstrated in the right ventricle using TTE (**Fig. 2**). One end of the needle was seen embedded into the lateral wall of the right ventricle and the other end was embedded into the interventricular septum, near to the apex. Furthermore, a median sternotomy was performed. The needle ends were not visible on the cardiac surface. Nevertheless, the needle was palpated in the right ventricular wall. We gently pushed the needle without incising the muscle, grasped with an anatomical forceps, and pulled out from the apex (**Fig. 3**). Postoperative TTE showed no abnormality and the patient was discharged from the hospital 4 days after the surgery.

Discussion

Penetrating foreign bodies in the heart is rare. The objects usually comprise of bullets, acupuncture needles, fragments of Kirschner wires, grenade, venous catheter, or even more rarely sewing needles.^{1,3)} There were only 40 cases of sewing needle penetration in the heart reported within the period of 1967–2013. Ninety percent

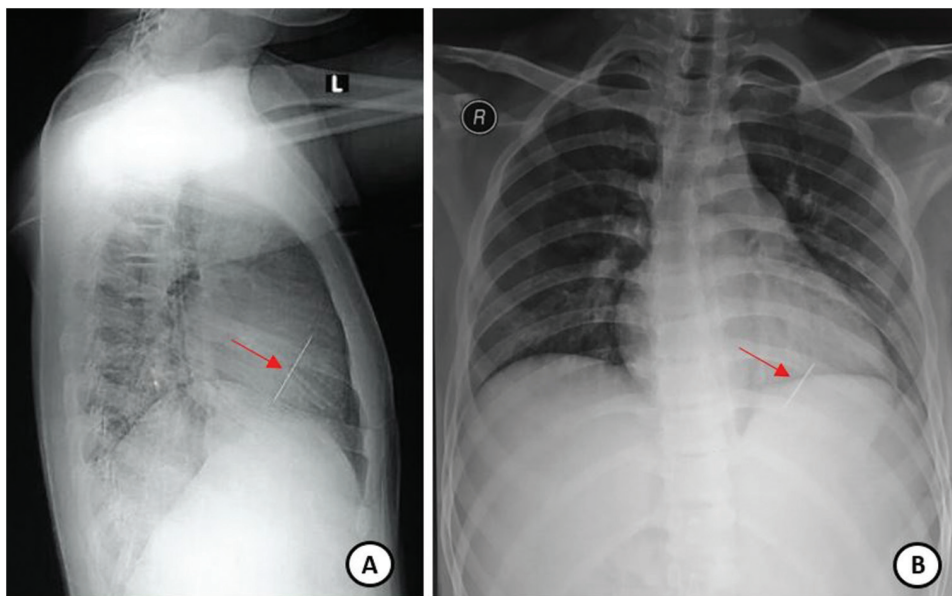


Fig. 1 Chest X-ray showing a needle (arrow) in the chest from posteroanterior (A) and lateral projection (B).

of all cases were found in a patient with major psychiatric disorder. There were only three cases of accidental needle penetration in a non-psychiatric patient.²⁾

The most common symptoms are dyspnea and chest pain, but they can be asymptomatic.⁴⁾ If left untreated, the sharp nature of needles enables them to migrate through the tissues rapidly, leading to hemothorax, cardiac tamponade, and pneumothorax. Even in the absence of migration, mural thrombi may form, leading to repeated embolization. Rarely, there may be valvular regurgitation, especially with needles embedded in the ventricular septum.¹⁾ In addition, infective endocarditis may develop in longstanding cases.⁵⁾ Therefore, its removal is essential.

In the most cases, removal of intracardiac foreign body requires open heart surgery with CPB. Soren et al.²⁾ reported three cases of accidental penetrating sewing needle in the heart, which were managed surgically and required CPB. In our case, the needle ends were not visible on the surface of the heart. However, because the needle was long and embedded in the right ventricle wall, it was possible for us to remove it without CPB after accurate localization using TTE (**Fig. 2**). If the needle was neither embedded in the myocardium nor palpated from the surface of the heart, open heart surgery using CPB is required.¹⁾

Preoperative examination of the intracardiac foreign bodies can be performed by several radiological examinations. In this case, real-time echocardiography is superior

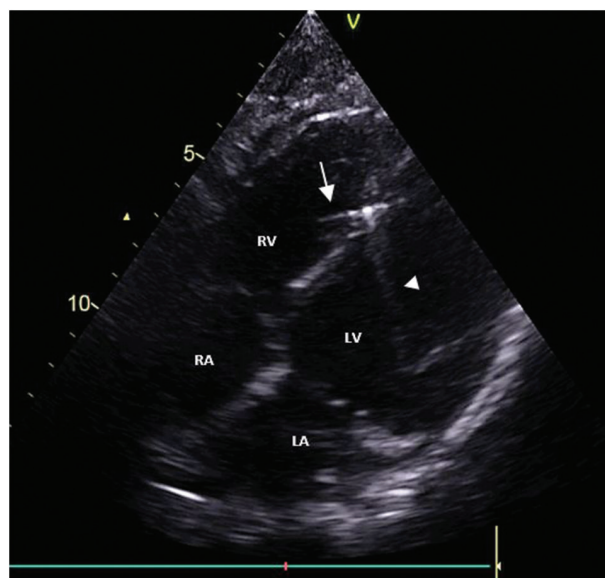


Fig. 2 Transthoracic echocardiography demonstrating the needle (arrow) in the right ventricle (RV) and its acoustic shadow (arrow head).

to other types of radiological examinations due to its direct visualization of intracardiac structure, capability to assess cardiac function, and non-ionizing radiation properties.⁶⁾ In addition, echocardiography was reported to have almost 100% of sensitivity for assessing the size, location, and mobility of intracardiac foreign bodies.³⁾ Both TTE and transesophageal echocardiography (TEE) offer great value for localization of intracardiac foreign

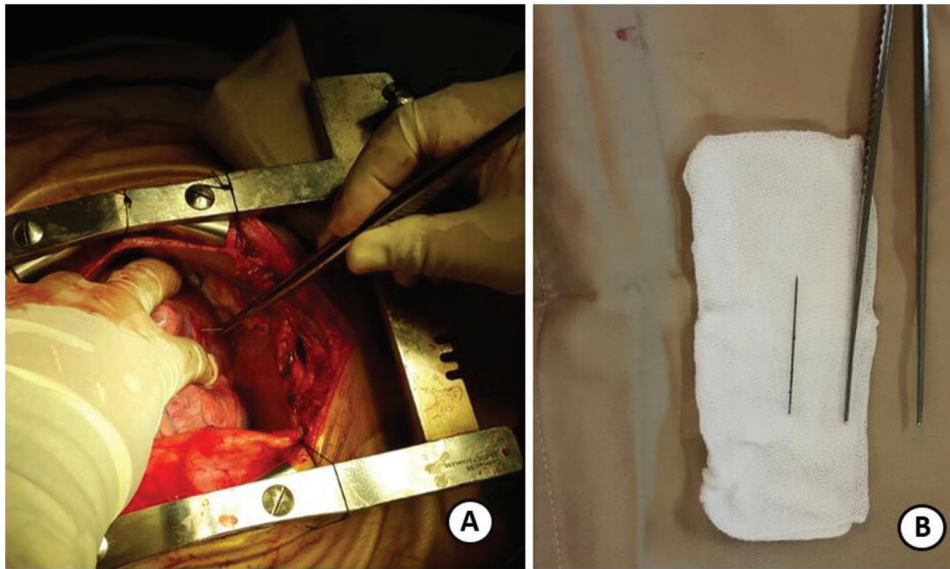


Fig. 3 Photograph taken during surgery showing the needle was pulled out from the apex (A) and the needle after removal (B).

bodies.⁶⁾ Radiological examination using TTE was selected for our patient due to its convenience and non-invasive procedure.

Conclusion

Determination of the exact location of the foreign body in the heart is important to ensure its complete removal. Moreover, it may avoid open heart surgery and the use of CPB.

Disclosure Statement

All authors have no conflicts of interest.

References

- 1) Talwar S, Subramaniam KG, Subramanian A, et al. Sewing needle in the heart. *Asian Cardiovasc Thorac Ann* 2006; **14**: 63-5.
- 2) Soren S, Surjit, Chaudhury S, et al. Multiple self-inserted pins and nails in pericardium in a patient of schizophrenia: case report and review. *Ind Psychiatry J* 2015; **24**: 82-7.
- 3) Actis Dato GM, Arslanian A, Di Marzio P, et al. Posttraumatic and iatrogenic foreign bodies in the heart: report of fourteen cases and review of the literature. *J Thorac Cardiovasc Surg* 2003; **126**: 408-14.
- 4) Gungor H, Duygu H, Yildiz BS, et al. A remnant sewing needle in the right ventricle as cause of chest pain. *Clin Cardiol* 2010; **33**: E23-5.
- 5) Mandegar MH, Ali Yousefnia M, Rayatzadeh H, et al. Intramyocardial sewing needle extracted one year after insertion. *Interact Cardiovasc Thorac Surg* 2006; **5**: 742-3.
- 6) Qian H, Song H, Li Y, et al. Removal of metallic foreign body in the heart by minimally invasive procedure under the guidance of transesophageal echocardiography and transthoracic echocardiography. *J Thorac Dis* 2015; **7**: E560-3.