



## Revision strategy for malunited tibial plateau fracture caused by failure of initial treatment

Jiang Liangjun, Zheng Qiang\*, Pan Zhijun, Hang Li

The Orthopedics Department of 2nd Affiliated Hospital of Medical College of Zhejiang University, Hangzhou, Zhejiang, China

### ARTICLE INFO

#### Article history:

Received 27 November 2018

Received in revised form

19 July 2019

Accepted 24 August 2019

Available online 19 September 2019

#### Keywords:

Malunited tibial plateau fracture

Revision strategy

Intra-articular osteotomy

Articular surface reduction

Lower limb alignment

### ABSTRACT

**Objective:** The aim of this study was to evaluate our treatment algorithm and results in revision surgery of malunited tibial plateau fracture after failure of initial treatment.

**Methods:** Our revision strategy was as follows: First, we determined the presence of any infection. Second, we determined whether the patient required total knee arthroplasty (TKA). Third, based on the characteristics of the tibial plateau fracture malunion, patients underwent one of the following surgical methods to achieve reduction: original fracture line osteotomy, tibial tubercle + original fracture line osteotomy, fibula head + original fracture line osteotomy, and metaphyseal open window reduction rod technique. The results was assessed with healing time, Rasmussen score, knee range of motion and complication rates.

**Results:** A total of 25 patients 16 men and 9 women; Mean age: 47.4 years (range: 35–63 years) underwent tibial plateau fracture revision operation. The time interval between the two surgeries was 2–24 months. The follow-up time was 12–30 months, and the operation time was 120–300 min. All patients received bone union at the last follow-up. The healing time was 3–6 months. The postoperative Rasmussen score was 19–29 (mean 23.8) compared with 14.4 points before the operation ( $p < 0.05$ ). The postoperative knee joint activity was 60–110° (mean 95.0°), compared with 57.8° before the operation ( $p < 0.05$ ). Six patients still had a 2-mm collapse on the articular surface, and 4 patients still had slight valgus ( $< 5^\circ$ ). Except for 2 TKA cases, fracture reduction was excellent in 15 cases and good in 8 cases, with a good rate of 100%. Superficial wound infections occurred in 3 patients.

**Conclusion:** Because revision of tibial plateau fracture malunion caused by failure of initial treatment is difficult, it is necessary to create a detailed surgical plan before the operation. Satisfactory clinical effects can be obtained if the correct revision strategy is used. The key to success is adopting a proper revision strategy according to the unique characteristics of the patient's tibial plateau fracture malunion.

**Level of Evidence:** Level IV, Therapeutic Study.

© 2019 Turkish Association of Orthopaedics and Traumatology. Publishing services by Elsevier B.V. This is an open access article under the CC BY-NC-ND license (<http://creativecommons.org/licenses/by-nc-nd/4.0/>).

### Introduction

Failure of initial treatment caused by malunion of the tibial plateau fracture often results in dysfunction.<sup>1,2</sup> In patients with severe malunion, it is necessary to perform revision surgery. At present, the indications for revision of tibial plateau fracture malunion are generally considered to be as follows. Mahadeva D et al<sup>3</sup>

\* Corresponding author. Tel.: +86 13858050807; fax: +86 0571 87783530.

E-mail addresses: [lylj@zju.edu.cn](mailto:lylj@zju.edu.cn) (J. Liangjun), [2100057@zju.edu.cn](mailto:2100057@zju.edu.cn) (Z. Qiang), [zhq1967@hotmail.com](mailto:zhq1967@hotmail.com) (P. Zhijun), [abacus0610@163.com](mailto:abacus0610@163.com) (H. Li).

Peer review under responsibility of Turkish Association of Orthopaedics and Traumatology.

described surgical indications to include a change of  $\geq 5^\circ$  in lower limb alignment (varus or valgus), articular surface compression  $\geq 5$  mm, and an increase of  $\geq 5$  mm in the width of the tibial plateau. Bennett WF et al<sup>4</sup> believed that in addition to an articular collapse  $\geq 5$  mm, a plateau shift and axial instability  $\geq 5^\circ$  were indications for surgery. A change in posterior slope angle of  $\geq 10^\circ$  is also considered to be an indication for operation.<sup>5</sup> In addition, it is generally believed that lower limb alignment is critical<sup>3,6</sup> and even important than the smooth of articular surface. Therefore, we postulate that the indications for a revision operation include articular surface collapse  $\geq 5$  mm, malalignment (varus or valgus  $\geq 5^\circ$ ), and change in posterior slope angle of  $\geq 10^\circ$ .

Currently, the methods used for revision operations mainly include open reduction and internal fixation, proximal tibial osteotomy, external fixation, and total knee arthroplasty.<sup>7</sup> Each method has its own indications, and it is necessary to adopt a specific treatment method for a specific type of malunion. However, there is no systematic study in the existing literature on the revision strategy of tibial plateau fracture malunion. It is not clear which revision method should be adapted to which type of tibial plateau fracture malunion.

We retrospectively analysed patients who underwent revision surgery for tibial plateau fracture malunion in our hospital from January 2012 to December 2016. The patients were classified based on malunion characteristics, and they underwent different methods of revision surgery according to our revision strategy. The treatment experience of these patients was summarised. We hoped to determine the following: 1) whether our revision strategy of tibial plateau fracture malunion was accurate and helpful, 2) the key points of different types of revision surgery, and 3) whether the clinical effect of revision was achieved.

**Methods**

Patient inclusion criteria were as follows: 1) receipt of primary tibial plateau fracture operation; 2) imaging examination showing one of the following indications: tibial plateau articular surface collapse  $\geq 5$  mm, change in alignment (varus or valgus) by  $\geq 5^\circ$ , or change in tibial plateau posterior slope angle by  $\geq 10^\circ$ ; and 3)  $\geq 1$  year of follow-up. Exclusion criteria were 1) old tibial plateau fracture not previously treated with surgery, 2) the presence of psychiatric disorders that severely affect postoperative functional assessment, or 3) pathological fractures.

A total of 25 patients were summarized, including 9 men and 16 women. The patients' ages ranged from 35 to 63 years (average 47.4 years). The Schatzker classification was used to categorise the tibial plateau fracture: 5 cases had type II, 5 cases had type IV, 9 cases had type V, and 6 cases had type VI. The time interval between the two operations was 2–24 months (average 10.6 months). The

preoperative Rasmussen score ranged from 9 to 19 points (average 14.4 points), and the knee motion activity was 20–90° (average 57.8°).

The reasons for revisions were as follows: 1) articular surface collapse of  $\geq 5$  mm in 8 patients, 2) articular surface collapse of  $\geq 5$  mm and alignment changed by  $\geq 5^\circ$  in 15 patients (including 3 cases of varus and 12 cases of valgus), 3) articular surface collapse of  $\geq 5$  mm with a tibial plateau posterior slope angle  $< 0^\circ$  and subluxation of the knee joint in 1 patient, and 4) articular surface collapse of  $\geq 5$  mm with subluxation of the knee joint in 1 patient. The average collapse of the articular surface was 6.2 mm, and the average change in the angulation alignment was  $8.0^\circ$  (Table 1).

*Preoperative planning*

After the patients were admitted to hospital, the routine knee X-ray, total lower extremity X-ray, and computed tomography (CT) of the knee were adapted to confirm the characteristics of the fracture malunion. If allowed, magnetic resonance imaging was performed to check the ligaments. According to the preoperative examinations, revision surgery was established according to the characteristics of the malunited tibial plateau fractures. The revision strategy we developed was as follows: 1) Identify whether local infection existed. If the patient was infected, we changed the original internal fixation to external fixation. 2) Determine whether the patient required total knee arthroplasty. Total knee arthroplasty was performed in the following situations: elder age ( $> 60$  years), significant osteoarthritis, or severe bone defect. 3) In other patients, the following surgical methods were performed: a) if one tibial plateau is unreduced and the tibia plateau articular surface is collapsed, the original fracture line osteotomy would be performed; 2) if bilateral plateaus are unreduced and the plateau articular surface is collapsed, tibial tubercle + original fracture line osteotomy would be performed; 3) if the articular surface is depressed with complete articular cartilage, the metaphyseal open window reduction rod technique would be performed; and 4) if the posterolateral plateau is collapsed, the fibula head + original fracture line osteotomy would be performed.

**Table 1**  
Preoperative characteristics of patients.

no.	Sex	Age	Fracture type	Preoperative articular surface	Preoperative lines of force	Whether infected	Preoperative function score	Revision time (months)	Knee activity (°)	Reasons for revision
1	Male	35	IV	The lateral collapse	Varus	No	13	7	35	Lateral collapse 5 mm, varus $5^\circ$
2	Female	53	II	The lateral collapse	Valgus	No	16	12	50	Lateral collapse 12 mm, valgus $11^\circ$
3	Female	42	V	The lateral collapse	Valgus	No	18	12	55	Lateral collapse 5 mm, valgus $7^\circ$
4	Female	47	V	The lateral collapse	Valgus	No	15	6	35	Lateral collapse 6 mm, valgus $9^\circ$
5	Male	48	VI	The lateral collapse	Normal	Yes	13	6	45	Lateral collapse 5 mm
6	Female	53	II	The lateral collapse	Valgus	No	12	12	55	Lateral collapse 5 mm, valgus $5^\circ$
7	Female	54	VI	The lateral collapse	Valgus	Yes	11	2	40	Lateral collapse 5 mm, valgus $6^\circ$
8	Female	60	IV	The lateral collapse	Valgus	No	17	6	80	Lateral collapse 10 mm, valgus $12^\circ$
9	Male	52	V	The lateral collapse	Valgus	No	17	12	90	Lateral collapse 6 mm, valgus $8^\circ$
10	Female	62	V	The lateral collapse	Valgus	No	13	10	60	Lateral collapse 10 mm, valgus $10^\circ$
11	Male	54	V	The lateral collapse	Valgus	No	19	3	90	Lateral collapse 5 mm
12	Female	51	V	The lateral collapse	Valgus	Yes	16	4	80	Lateral collapse 6 mm, valgus $5^\circ$
13	Female	51	IV	The lateral collapse	Normal	No	17	12	55	Lateral collapse 5 mm
14	Female	45	II	The lateral collapse	Normal	No	18	12	80	Lateral collapse 5 mm
15	Female	52	V	The lateral collapse	Valgus	Yes	14	6	30	Lateral collapse 10 mm, valgus $9^\circ$
16	Female	53	IV	The lateral collapse	Valgus	No	12	6	45	Lateral collapse 10 mm
17	Female	53	VI	The medial collapse	Normal	No	13	12	20	Medial collapse 5 mm, knee subluxation, PTSA $< 0^\circ$
18	Male	40	VI	The lateral collapse	Normal	No	14	10	70	Lateral collapse 6 mm
19	Male	63	VI	The lateral collapse	Varus	No	13	22	90	Lateral collapse 5 mm, varus $14^\circ$
20	Female	45	V	The lateral collapse	Normal	No	9	11	20	Lateral collapse 5 mm, knee subluxation
21	Female	43	II	The lateral collapse	Valgus	No	12	24	50	Lateral collapse 10 mm, valgus $8^\circ$
22	Male	45	V	The lateral collapse	Normal	No	15	9	90	Lateral collapse 5 mm
23	Female	55	IV	The lateral collapse	Valgus	No	14	4	60	Lateral collapse 8 mm, valgus $6^\circ$
24	Male	39	VI	The lateral collapse	Valgus	No	12	4	50	Lateral collapse 5 mm, varus $5^\circ$
25	Male	42	II	The lateral collapse	Normal	No	17	6	70	Lateral collapse 5 mm

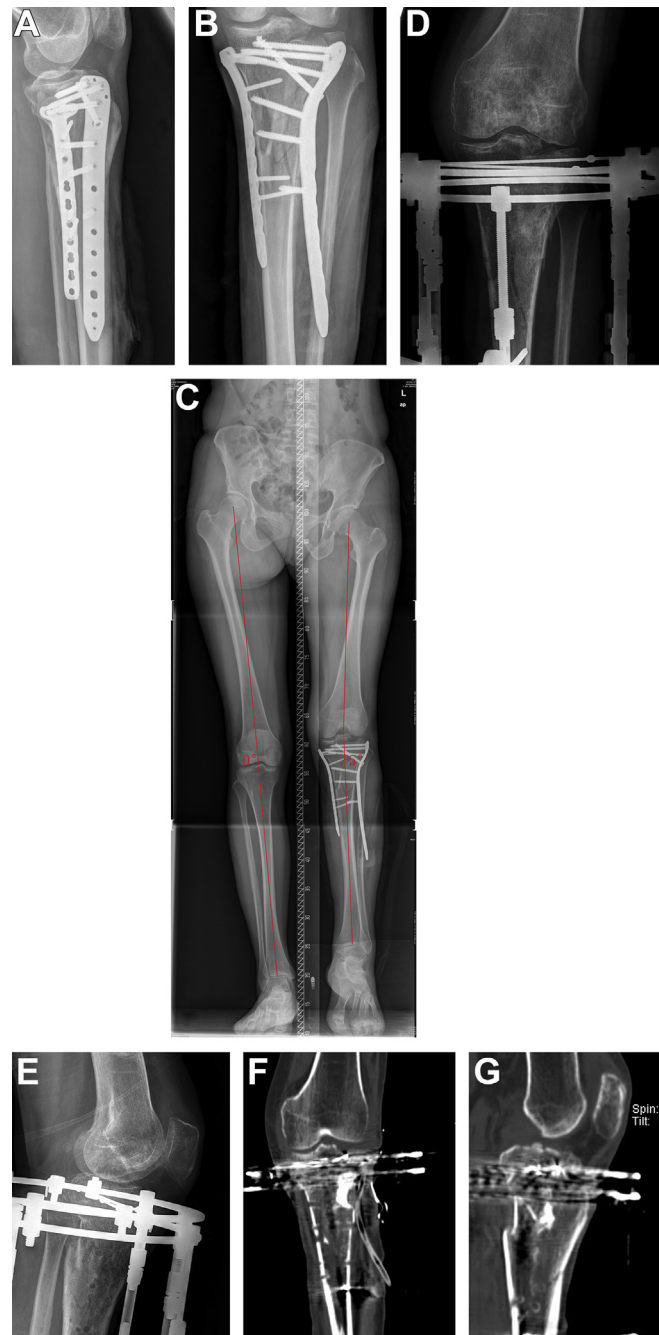
### Surgical treatment

In general, patients were administered general anaesthesia in the supine position with a tourniquet on the affected limb, and the injured limb and the anterior superior iliac spine area were disinfected. The detailed treatment method was based on the pre-established revision surgical strategy.

#### Open window reduction rod treatment group

First, we removed the original internal fixation, opened the articular capsule, and switched the meniscus upward to expose the articular surface. Then we opened a metaphyseal bone cortex

window under the tibia plateau. The size of the window was generally about  $2 \times 2$  cm. We reduced the articular depression by a rod, which was placed through the open window to push up the depressed articular surface until anatomical reduction of the articular surface was ensured under direct vision. It was necessary to repeatedly push up the subchondral bone, and we took care to prevent the articular surface cartilage from being broken by the excessive force due to striking. Afterward, the autogenous iliac bone was implanted at the bone defect. We used the anatomic locking plate and row-screws technique to fix the articular surface. If the alignment was abnormal, an extra-articular osteotomy was performed later.

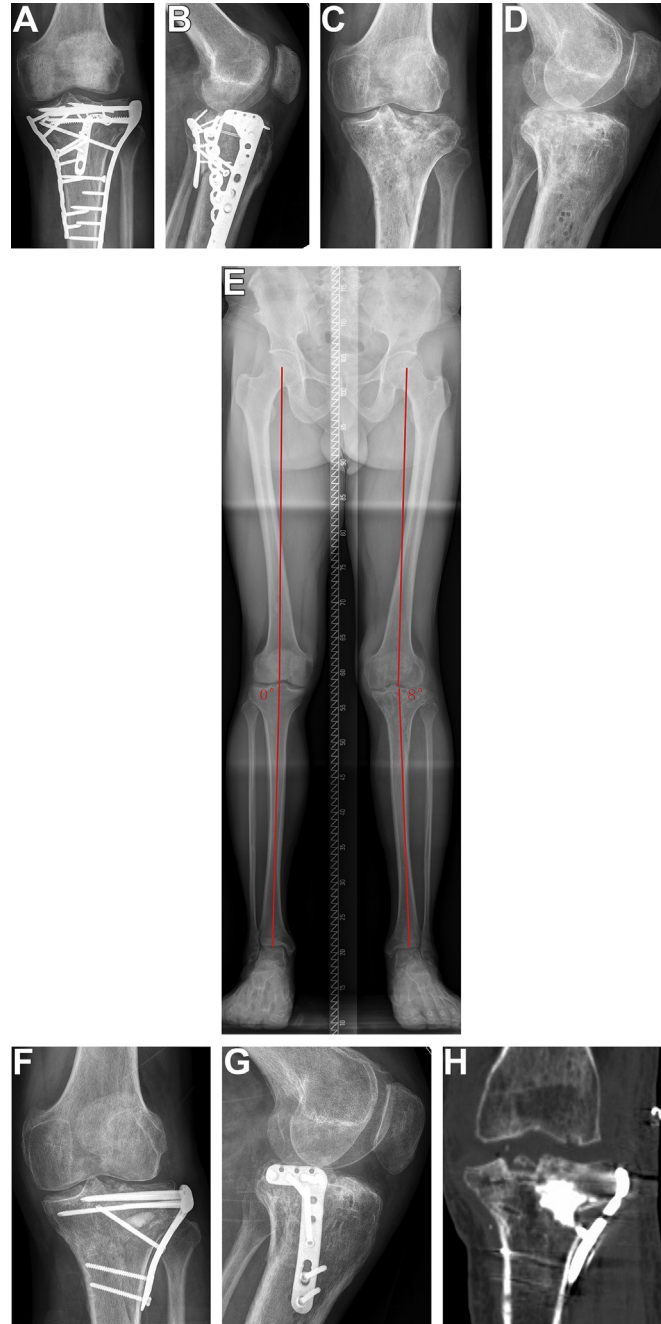


**Fig. 1.** A 54-year-old woman with infection. (A–C) Preoperative X-ray showed that collapse of the lateral tibial plateau articular surface and obvious valgus alignment ( $5^\circ$  valgus). (D, E) Revision surgery was performed to remove the original internal fixation, reduce the articular surface, and perform external fixation treatment. (F, G) CT scan after revision operation showed 2 mm of articular surface collapse left.

*Intraosteotomy treatment group*

In tibial tubercle osteotomy, an osteotomy from the distal end of the tibial tubercle is usually chosen. After osteotomy, the tibial tubercle was lifted toward the proximal end, and the entire tibia plateau was exposed. In fibular head osteotomy, the common peroneus nerve was first exposed and protected. We carefully identified the attachment point of the tendon of the biceps femoris at the fibular head and performed a “V”-shaped osteotomy. Then we turned the fibular head to the proximal end to expose completely the lateral and posterolateral tibial plateau. After that, we found the original fracture line in order to perform original fracture line

osteotomy. We placed multiple K-wires to mark the location and confirmed the position and direction of the osteotomy by C-arm fluoroscopy. We then made multi-hole drills at the location of the osteotomy using a 2.5-mm drill or K-wire. Intra-articular osteotomy was performed with a sharp bone osteotome. We were careful to avoid popliteus blood vessels and nerve damage during osteotomy. After scar tissue was cleaned up, we tried to reduce the osteotomy plateau and temporarily fix it. The medial plateau was temporarily fixed using a reconstructed plate or T-shaped plate, and the lateral plateau was temporarily fixed using the K-wire. An autogenous iliac bone fragment of the same size was placed into the defect with the



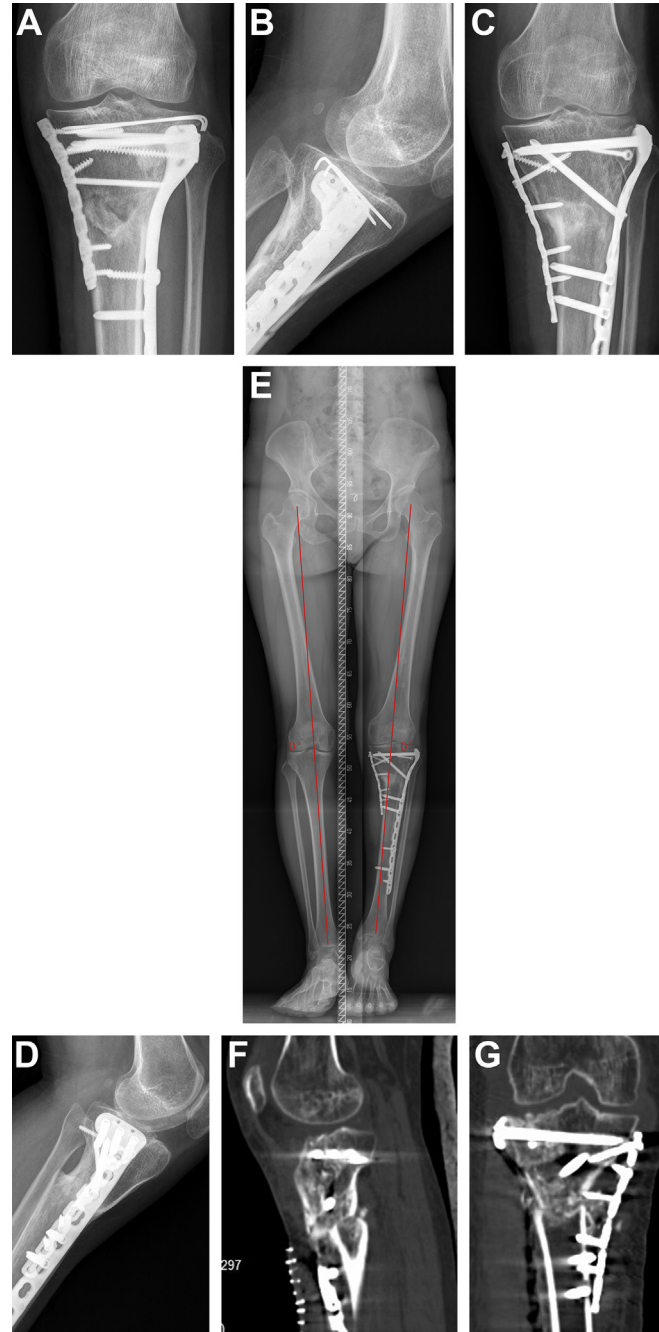
**Fig. 2.** A 52-year-old man. (A, B) Preoperative X-ray showed collapse of the lateral tibial plateau, basically normal alignment, and posterior slope angle. (C–E) X-rays showed that after the internal fixation was removed, the lateral tibial plateau articular surface collapsed about 6 mm, and the alignment valgus was about 8°. (F–H) X-rays and CT scan after the revision operation showed that the fracture healed and the articular surface collapse was reduced.

smooth face upward to replace the articular surface. K-wires were used to fix the iliac bone fragment temporarily, and the width of the tibial plateau was restored by clamping the medial and lateral tibial plateau. After C-arm fluoroscopy checked reduction, a lateral anatomic locking plate with row-screws was used to fix the lateral tibial plateau and the articular surface.

#### Postoperative treatment and follow-up

Postoperative drainage routinely continued for 24 h, and antibiotics were routinely administered for 48 h to prevent infection.

Passive joint function activity was performed immediately after the operation, and partial weight training was started 2 weeks after the operation under the physician's guidance. Patients were followed up every 3 months. At each follow-up, patients underwent plain radiography, and knee joint activity was tested. CT and full-length lower limb X-rays were performed every 6 months. The patients' treatment plans were summarised, and the operative time, fracture healing time, fracture reduction, lower limb alignment, knee joint function scores, knee joint range of motion, and postoperative complications were summarised. The standard clinical and radiological criteria were used to judge the fracture healing time, the Rasmussen score



**Fig. 3.** A 42-year-old woman. (A, B) Preoperative X-rays showed the collapse of the lateral tibial plateau was 5 mm and valgus alignment. (C–E) X-rays after revision operation showed the smooth articular surface and normal alignment. (F, G) CT scan showed the articular surface was well reduced.

system<sup>5</sup> was used to evaluate knee joint function, and the method proposed by Biggi et al<sup>8</sup> was used to evaluate fracture reduction.

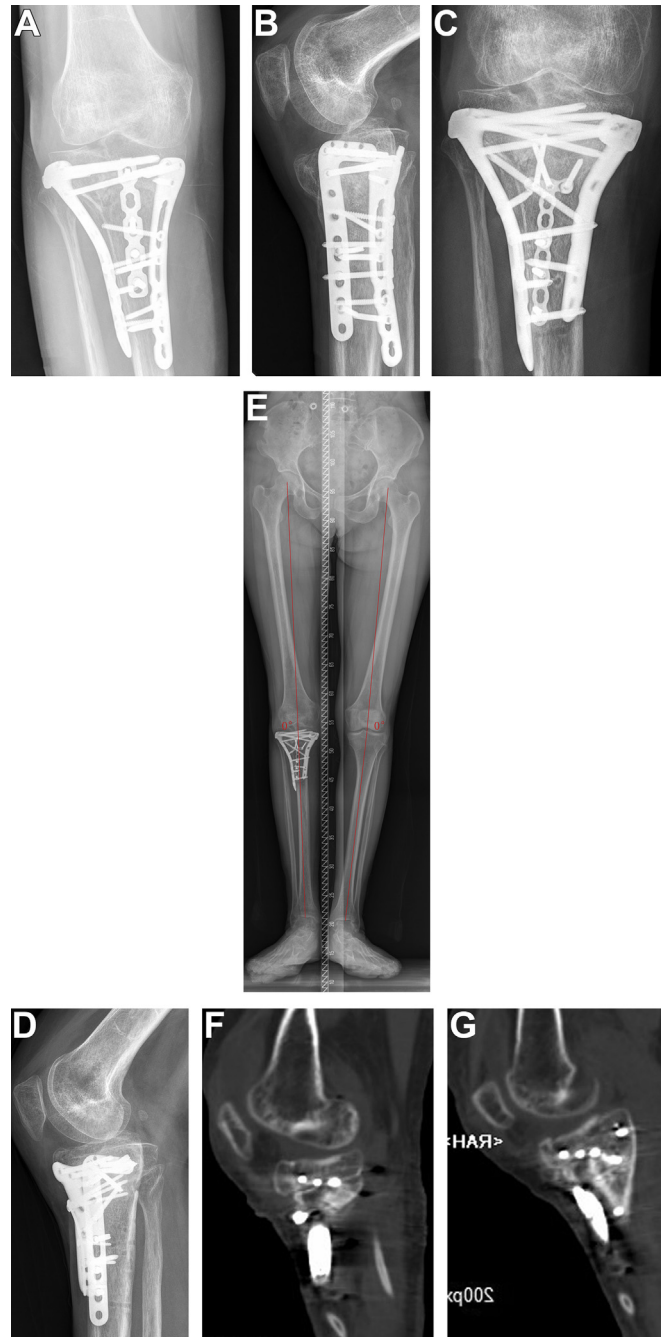
#### Statistical analysis

Preoperative and postoperative Rasmussen scores and preoperative and postoperative knee joint range of motion were compared by paired-sample *t* test. The significance level was defined as  $P < 0.05$ . This study was recorded and analysed using the SPSS software package (version 22.0, SPSS, Chicago, IL).

## Results

### General results

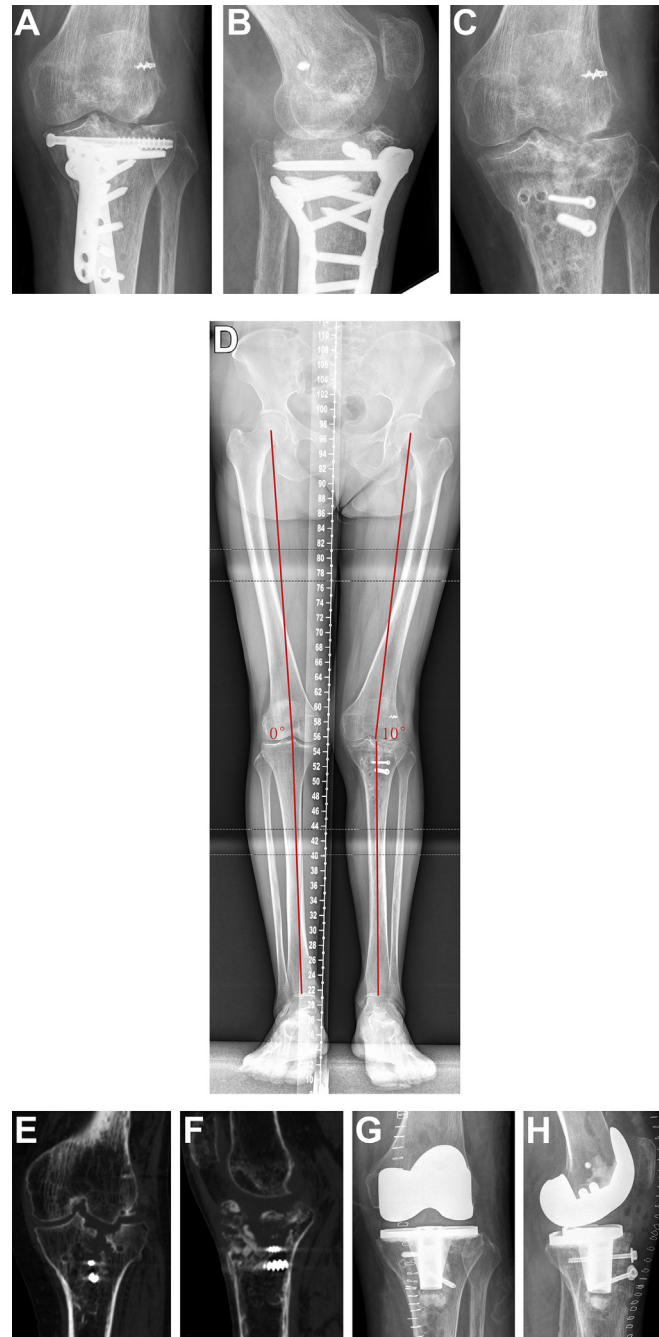
All patients were followed up for 12–30 months (mean 16.8 months). The operation time ranged from 120 to 300 min (mean 180 min). Four patients had a previous infection, so we removed the initial internal fixation and performed debridement. After the infection was controlled, second-stage internal fixation or external fixation operation was performed (Fig. 1). Among the



**Fig. 4.** A 53-year-old woman. (A, B) X-rays before the operation showed that the medial tibial plateau collapsed 4 mm, varus alignment, and a tibial plateau posterior slope angle of about  $-10^\circ$ . (C–E) X-rays after revision operation showed the fracture healed, the collapse of articular surface was reduced, the tibial plateau posterior slope angle was about  $0^\circ$ , and the lower limb alignment was normal. (F, G) CT scan showed the articular surface was well reduced.

other patients, 4 had a depressed articular surface with complete articular cartilage. We used the open window reduction rod technique and redid the internal fixation during the revision surgery (Fig. 2). In the osteotomy group, 7 patients were treated by original fracture line osteotomy and internal fixation (Fig. 3), 5 patients were treated by tibial tubercle + original fracture line osteotomy and internal fixation (Fig. 4), and 3 patients were treated by fibular head + original fracture line osteotomy and internal fixation. Two patients were treated with total knee arthroplasty due to severe osteoarthritis or bone defect (Fig. 5).

All patients achieved bone healing at the last follow-up. Fracture healing time was 3–6 months, with an average of 3.8 months. None of the patients had significant knee pain, and all were able to walk with full weight and unlimited walking distance. The postoperative Rasmussen score was 19–29 (average 23.8), and the postoperative knee mobility was 60°–110° (average 95°), both of which improvement significantly as compared with before surgery ( $P < 0.05$ ). There was still 2 mm of articular surface collapse in 6 cases, and 4 patients still had mild valgus (less than 5°).



**Fig. 5.** A 60-year-old woman. (A–D) X-rays before the operation showed that the lateral tibial plateau collapsed 10 mm and the valgus alignment was 10°. (E, F) CT scan after internal fixation removal showed severe local bone defect and osteoporosis and valgus alignment. (G, H) X-rays after revision operation showed the patient received total knee arthroplasty.

**Table 2**  
Patient surgical and postoperative data.

No.	Operation methods	Fixation methods	Operation time	Fracture healing time	Articular surface	Force line	Postoperative functional score	Knee mobility (°)	Complications
1	Tibial tubercle + original fracture line osteotomy and re-internal fixation	Medial and lateral plates	200 (min)	3 months	Reduced	Normal	21	95	–
2	Open window reduction rod technique	Lateral plate	120 (min)	6 months	Reduced	Normal	22	100	–
3	Original fracture line osteotomy and re-internal fixation	Medial and lateral plates	210 (min)	3 months	Reduced	Normal	24	100	–
4	Fibular head + original fracture line osteotomy and re-internal fixation	Medial and lateral plates	215 (min)	3 months	Reduced	Normal	23	90	–
5	Remove the original internal fixation to control the infection, then use external fixation	External fixation	185 (min)	6 months	Collapsed 2 mm	Normal	23	80	–
6	Original fracture line osteotomy and re-internal fixation	Lateral plate	140 (min)	5 months	Reduced	Varus less than 5°	25	100	–
7	Remove the original internal fixation to control the infection, then use external fixation	External fixation	170 (min)	6 months	Collapsed 2 mm	Valgus less than 5°	24	60	–
8	Total knee arthroplasty	Total knee prosthesis	130 (min)	–	–	Normal	29	110	–
9	Open window reduction rod technique	Lateral plate	200 (min)	3 months	Reduced	Normal	26	110	–
10	Total knee arthroplasty	Total knee prosthesis	120 (min)	–	–	Normal	28	110	–
11	Original fracture line osteotomy and re-internal fixation	Lateral plate	150 (min)	4 months	Reduced	Normal	24	100	Postoperative infection
12	Remove the original internal fixation to control the infection, then use re-internal fixation	Lateral plate	150 (min)	4 months	Reduced	Normal	25	110	–
13	The tibial tubercle + original fracture line osteotomy and re-internal fixation	Lateral plate	200 (min)	3 months	Reduced	Normal	22	90	Postoperative infection
14	Open window reduction rod technique	Lateral plate	180 (min)	3 months	Reduced	Normal	25	100	–
15	Remove the original internal fixation to control the infection, then use re-internal fixation	Lateral plate	130 (min)	4 months	Reduced	Valgus less than 5°	20	90	–
16	Original fracture line osteotomy and re-internal fixation	Medial and lateral plates	180 (min)	4 months	Collapsed 2 mm	Normal	22	70	–
17	Tibial tubercle + original fracture line osteotomy and re-internal fixation	Medial, anterior and lateral plates	200 (min)	4 months	Reduced	Normal	23	90	–
18	Original fracture line osteotomy and re-internal fixation	Lateral plate	200 (min)	3 months	Reduced	Normal	25	100	–
19	Fibular head + original fracture line osteotomy and re-internal fixation	Lateral plate + rim plate	250 (min)	4 months	Reduced	Normal	24	80	–
20	Tibial tubercle + original fracture line osteotomy and re-internal fixation	Medial and lateral plates	300 (min)	3 months	Collapsed 2 mm	Normal	19	70	Postoperative infection
21	Original fracture line osteotomy and re-internal fixation	Lateral plate	160 (min)	3 months	Reduced	Normal	20	110	–
22	Open window reduction rod technique	Lateral plate	150 (min)	3 months	Reduced	Normal	27	110	–
23	Original fracture line osteotomy and re-internal fixation	Medial and lateral plates	180 (min)	4 months	Collapsed 2 mm	Normal	25	100	–
24	Tibial tubercle + original fracture line osteotomy and re-internal fixation	Medial and lateral plates	200 (min)	5 months	Collapsed 2 mm	Valgus less than 5°	24	90	–
25	Fibular head + original fracture line osteotomy and re-internal fixation	Lateral plate + rim plate	160 (min)	4 months	Reduced	Normal	26	110	–

### Fracture reduction

Except for 2 cases of total knee arthroplasty, fracture reduction was excellent in 15 cases and good in 8 cases, and the excellent and good rate was 100% (Table 2).

### Complications

Three patients suffered superficial wound infection after our treatment, with wound exudation and incisions that did not heal.

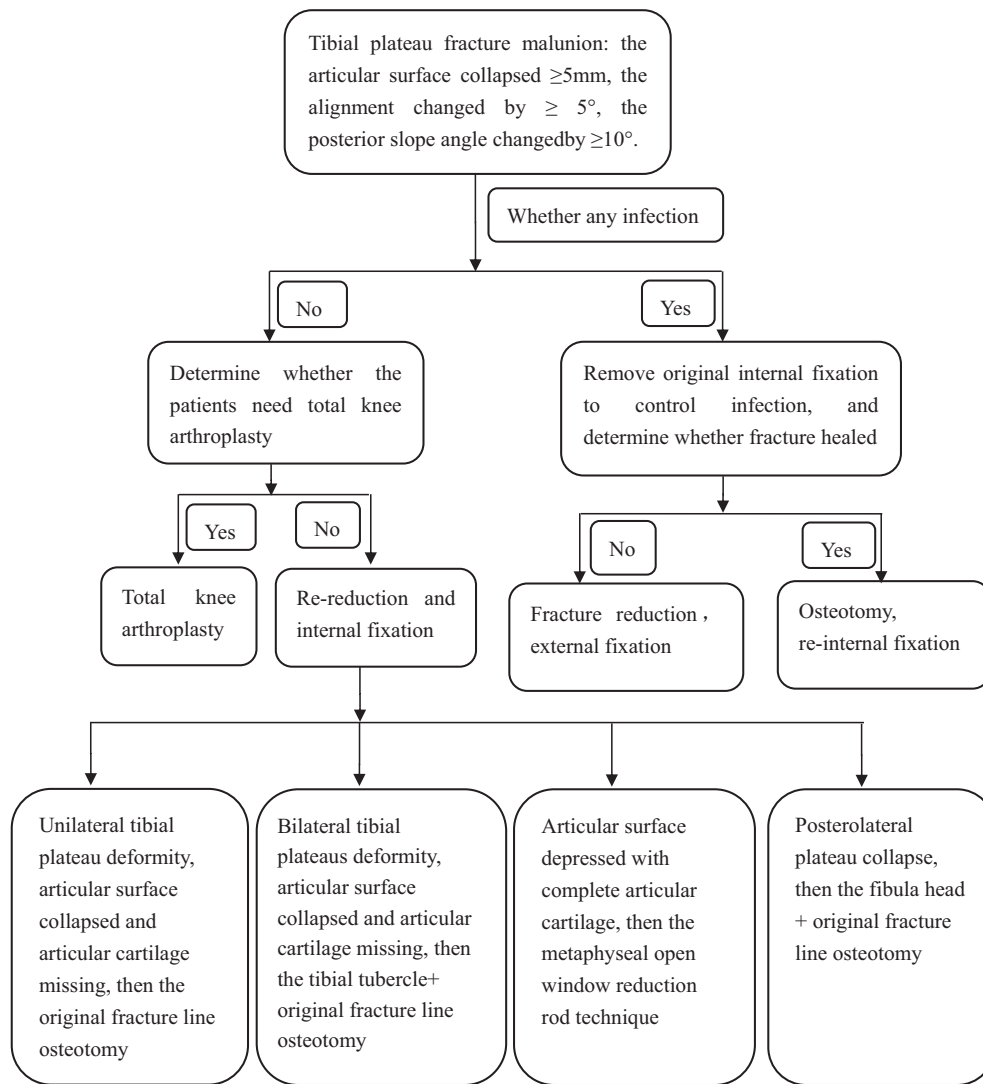
After debridement and negative vacuum pressure treatment, the infection was controlled. None of the patients had vascular or nerve injury, and there were no cases of internal fixation failure.

### Discussion

Currently, revision methods for tibial plateau fracture malunion mainly include the following: 1) Extra-articular osteotomy to correct the alignment of the lower limb. Open medial tibial



**Table 3**  
Tibial plateau fracture malunion revision treatment strategy.



plateau osteotomy was used for the treatment of tibial plateau fracture varus deformity, and good results were achieved.<sup>9,10</sup> Because most of the tibial plateau fracture malunion consisted of intra-articular deformity, this application of the extra-articular osteotomy was limited. 2) Total knee arthroplasty. There have been many reports on the satisfactory effect of total knee arthroplasty on tibial plateau fracture malunion.<sup>11–13</sup> However, total knee arthroplasty has specific indications and is appropriate for elderly patients, those with serious osteoarthritis, and patients with severe bone defect, so only two patients in our series with severe osteoarthritis or bone defect were treated with total knee arthroplasty. 3) Intra-articular osteotomy. Wang Y et al<sup>14</sup> treated patients with posterolateral tibial plateau fracture malunion by the intra-articular osteotomy method. These patients had a posterolateral plateau collapse from 15.4 mm preoperatively to 3.3 mm postoperatively. Because the tibial plateau fracture malunion mostly consisted of intra-articular deformity, the intra-articular osteotomy was suitable for most revision surgeries. However, there some specific differences still exist in intra-articular osteotomy because of different characteristics of the deformity.

In our study, most patients were treated with intra-articular osteotomy (15 cases). When the unilateral plateau was deformed, original fracture line osteotomy was able to obtain a satisfactory exposure. However, when the bilateral tibial plateaus were deformed, exposure and osteotomy were difficult because of severe deformity. We used tibial tubercle osteotomy to obtain better exposure. Because of associated complications such as non-union, displacement of the tibial tubercle, and skin necrosis,<sup>15–17</sup> tibial tubercle osteotomy has gradually fallen out of practice. However, we thought it was useful in our cases. A cadaveric study showed that tibial tubercle osteotomy effectively increased the exposure range by 148% compared with non-osteotomy.<sup>18</sup> Full exposure was the very important prerequisite for satisfactory reduction. The deformities of the medial and lateral tibial plateau were completely exposed after tibial tubercle osteotomy. We believe that the occurrence of complications could be effectively prevented by careful operation during surgery, protection of the surrounding soft tissue, prevention of damage to the patellar tendon, and good reduction and fixation of the tibial tubercle.<sup>19</sup> Tibial tubercle osteotomy is an effective way to increase total plateau exposure and help plateau reduction in bilateral tibial plateaus fracture malunion.

Kerkhoffs GM et al.<sup>20,21</sup> performed extra-articular osteotomy + intra-articular bone grafting in patients with lateral articular surface collapse and valgus alignment. We believe that the malalignment in such patients was often caused by nonreduction of the lateral plateau and articular surface collapse. As long as the lateral plateau was reduced and the articular surface rebuilt, the alignment was recovered without extra-articular osteotomy. Therefore, we used the intra-articular osteotomy + iliac bone fragment method to replace the articular surface in such patients. Krettek C et al.<sup>22</sup> also suggested the use of intra-articular osteotomy to treat tibial plateau fracture malunion. It is easier to obtain anatomical plateau reduction, a smooth articular surface, and alignment recovery using our methods, and we achieved better clinical results than extra-articular osteotomy.

This study evaluated the revision strategy of tibial plateau fracture malunion. Previous studies have focused on a certain revision technique, and to date, no summary has yet been published. We developed a revision operation strategy for the tibial plateau fracture malunion based on our patients' experiences (Table 3). We believe that through this revision treatment strategy, these patients could be systemically classified. Based on the different fracture characteristics of patients, a different revision surgical strategy could be adapted. Our revision treatment strategy could simplify the treatment process, make treatment decisions easier, assist the revision operation, and improve patient prognosis.

## Conclusion

Because revision of tibial plateau fracture malunion caused by failure of initial treatment is difficult, it is necessary to create a detailed surgical plan before surgery. Satisfactory clinical outcomes can be obtained for patients if the correct revision strategy is used. The key to successful treatment is the adoption of a proper revision strategy that is based on the unique characteristics of the patient's tibial plateau fracture malunion.

## References

- Urruela AM, Davidovitch R, Karia R, Khurana S, Egol KA. Results following operative treatment of tibial plateau fractures. *J Knee Surg.* 2013;26(3):161–165.
- Kugelman D, Qatu A, Haglin J, Leucht P, Konda S, Egol K. Complications and unplanned outcomes following operative treatment of tibial plateau fractures. *Injury.* 2017;48(10):2221–2229.
- Mahadeva D, Costa ML, Gaffey A. Open reduction and internal fixation versus hybrid fixation for bicondylar/severe tibial plateau fractures: a systematic review of the literature. *Arch Orthop Trauma Surg.* 2008;128(10):1169–1175.
- Bennett WF, Browner B. Tibial plateau fractures: a study of associated soft tissue injuries. *J Orthop Trauma.* 1994;8(3):183–188.
- Rasmussen PS. Tibial condylar fractures. Impairment of knee joint stability as an indication for surgical treatment. *J Bone Joint Surg Am.* 1973;55(7):1331–1350.
- Scott CE, Davidson E, MacDonald DJ, White TO, Keating JF. Total knee arthroplasty following tibial plateau fracture: a matched cohort study. *Bone Joint J.* 2015;97-B(4):532–538.
- Xu YF, Luo CF. Progress in revision of malunion of tibial plateau fractures. *Int J Ortho.* 2015;36(1):40–44.
- Biggi F, Di Fabio S, D'Antimo C, Trevisani S. Tibial plateau fractures: internal fixation with locking plates and the MIPO technique. *Injury.* 2010;41(11):1178–1182.
- Sundararajan SR, Nagaraja HS, Rajasekaran S. Medial open wedge high tibial osteotomy for varus malunited tibial plateau fractures. *Arthroscopy.* 2017;33(3):586–594.
- Singh H, Singh VR, Yuvarajan P, Maini L, Gautam VK. Open wedge osteotomy of the proximal medial tibia for malunited tibial plateau fractures. *J Orthop Surg (Hong Kong).* 2011;19(1):57–59.
- Moyad TF, Estok D. Simultaneous femoral and tibial osteotomies during total knee arthroplasty for severe extra-articular deformity. *J Knee Surg.* 2009;22(1):21–26.
- Xiao-Gang Z, Shahzad K, Li C. One-stage total knee arthroplasty for patients with osteoarthritis of the knee and extra-articular deformity. *Int Orthop.* 2012;36(12):2457–2463.
- Papagelopoulos PJ, Karachalios T, Themistocleous GS, Papadopoulos E, Savvidou OD, Rand JA. Total knee arthroplasty in patients with preexisting fracture deformity. *Orthopedics.* 2007;30(5):373–378.
- Wang Y, Luo C, Hu C, Sun H, Zhan Y. An innovative intra-articular osteotomy in the treatment of posterolateral tibial plateau fracture malunion. *J Knee Surg.* 2017;30(4):329–335.
- Burki H, von Knock M, Heiss C, Drobny T, Munzinger U. Lateral approach with osteotomy of the tibial tubercle in primary total knee arthroplasty. *Clin Orthop Relat Res.* 1999;(362):156–161.
- Lorbach O, Anagnostakos K, Kohn D. Osteotomy for approaches to the knee joint. Tibial tubercle, lateral epicondyle of the femur and head of the fibula. *Der Orthop.* 2013;42(5):332–340.
- Piedade SR, Pinaroli A, Servien E, Neyret P. Tibial tubercle osteotomy in primary total knee arthroplasty: a safe procedure or not? *Knee.* 2008;15(6):439–446.
- Khan H, Grob K, Milne LP, Kuster MS. Tibial tubercle osteotomy to improve exposure in complex knee fractures: cadaveric study and case series. *Injury.* 2016;47(10):2331–2338.
- Hay G, Kampshoff J, Kuster M. Lateral subvastus approach with osteotomy of the tibial tubercle for total knee replacement: a two-year prospective, randomised, blinded controlled trial. *J Bone Jt Surg Br.* 2010;92(6):862–866.
- Kerkhoffs GM, Rademakers MV, Altena M, Marti RK. Combined intra-articular and varus opening wedge osteotomy for lateral depression and valgus malunion of the proximal part of the tibia. Surgical technique. *J Bone Joint Surg Am.* 2009;91(Suppl 2 Pt 1):101–115.
- Kerkhoffs GM, Rademakers MV, Altena M, Marti RK. Combined intra-articular and varus opening wedge osteotomy for lateral depression and valgus malunion of the proximal part of the tibia. *J Bone Joint Surg Am.* 2008;90(6):1252–1257.
- Krettek C, Hawi N, Jagodzinski M. Intracondylar segment osteotomy: correction of intra-articular malalignment after fracture of the tibial plateau. *Unfallchirurg.* 2013;116(5):413–426.