

Review Article

Angiosome and Tissue Healing

Miki Fujii, MD, PhD¹ and Hiroto Terashi, MD, PhD²

For the treatment of patients with critical limb ischemia (CLI), the angiosome concept is essential in revascularization and wound treatment. In this article, we describe how we use the angiosome concept for surgically treating CLI wounds and review some essential reports. For wounds in patients with CLI to heal, both successful revascularization and wound management are crucial. In order to preserve the blood supply as much as possible intraoperatively, surgeons should always consider the angiosome concept.

Keywords: angiosome, wound healing, critical limb ischemia, foot surgery

Introduction

Taylor, a plastic surgeon, proposed the angiosome concept in 1987.¹ The authors defined angiosome as a three-dimensional block of tissue that is supplied blood by an underlying source artery. In the treatment of patients with critical limb ischemia (CLI), revascularization based on this concept is widely accepted as the most effective way to restore the blood supply to an ischemic lesion. For wound healing in patients with CLI, this concept is also essential in order to make use of the blood supply as much as possible when performing a surgical procedure such as debridement, amputation, or reconstruction. In this article, we describe how we use the angiosome concept

in the surgical treatment of wounds with CLI and review some essential reports.

Angiosome of Patients with CLI

Generally, six angiosomes originate from the three main source arteries and their branches in the foot and ankle. The anterior tibial artery (ATA) becomes the dorsalis pedis artery (DPA), which supplies to the dorsum of the foot. The posterior tibial artery has three main branches and three angiosomes as follows: the medial plantar artery (MPA) supplies to the instep, the lateral plantar artery supplies to the lateral midfoot and forefoot, and the calcaneal branch supplies to the heel. The peroneal artery (PA) has two main branches and two angiosomes as follows: the anterior perforating branch supplies the lateral anterior upper ankle and the calcaneal branch supplies the heel. Between the arteries feeding the angiosomes, there are numerous arterial–arterial connections, i.e., the collateral artery. These connections allow the blood flow to bypass the direct route if it is disrupted. Each angiosome is linked with very small vessels, i.e., choke vessels that allow a given angiosome to provide blood flow to an adjacent angiosome if the latter's source artery is damaged.

As for the patients with peripheral arterial disease, their angiosomes are different from those of patients without peripheral arterial disease because of the occlusion of the main source arteries. Osawa et al.² showed that the location of the wound and occlusion of the original main source artery were different in about 18% of the cases of CLI (26/145 limbs). In more than half of the cases, the DPA and three branches of the posterior tibial artery were fed by the proximal arteries, not by the other main source arteries through arterial–arterial connections. Because the ischemic changes in patients with CLI progress so gradually, these compensation systems develop more than in non-ischemic patients. This process is different from that in patients with acute limb ischemia. They do not have enough of a compensation system and so the symptom is severe and progresses immediately, which sometimes causes irreversible tissue loss or permanent nerve damage. The choke vessels also require 4 to 10 days to become patent after a given angiosome becomes ischemic.

Therefore, recognition of each angiosome is very important for treatment. To identify the alternative angiosome

¹Department of Plastic and Reconstructive Surgery, Critical Limb Ischemia Center, Kitaharima Medical Center, Ono, Hyogo, Japan

²Department of Plastic and Reconstructive Surgery, Kobe University Hospital, Kobe, Hyogo, Japan

Received: March 15, 2019; Accepted: March 18, 2019
Corresponding author: Miki Fujii, MD, PhD. Department of Plastic and Reconstructive Surgery, Critical Limb Ischemia Center, Kitaharima Medical Center, 926-250 Ichiba-cho, Ono, Hyogo 675-1392, Japan
Tel: +81-794-88-8800, Fax: +81-794-62-9911
E-mail: mikidtma@gmail.com


 ©2019 The Editorial Committee of Annals of Vascular Diseases. This article is distributed under the terms of the Creative Commons Attribution License, which permits use, distribution, and reproduction in any medium, provided the credit of the original work, a link to the license, and indication of any change are properly given, and the original work is not used for commercial purposes. Remixed or transformed contributions must be distributed under the same license as the original.

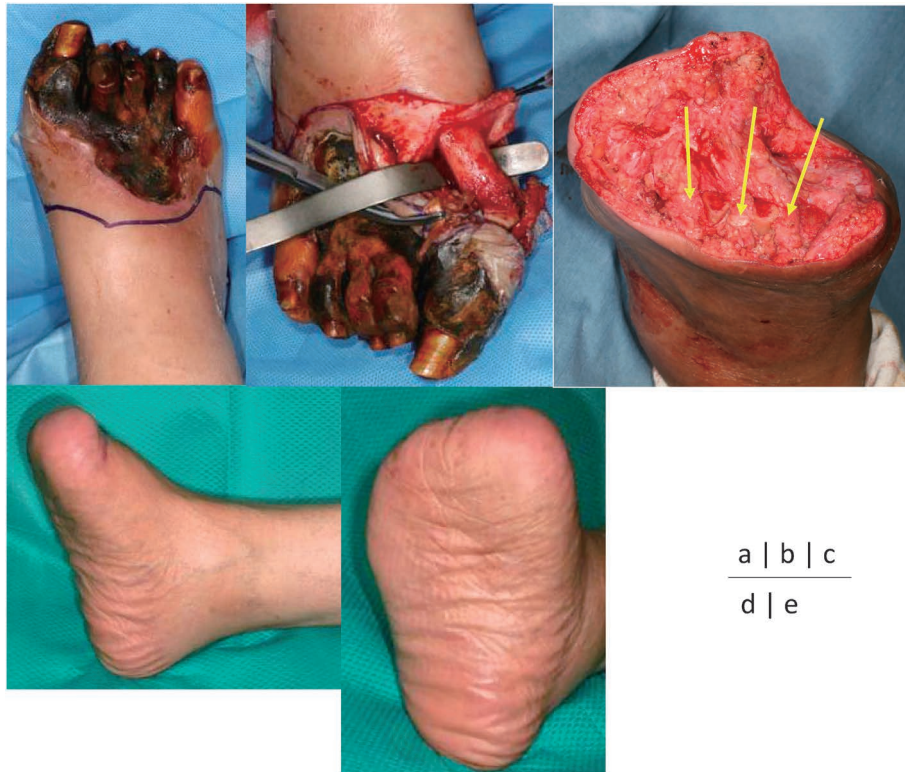

Fig. 1 (a) A 52-year-old woman (case 1) with right foot gangrene. After revascularization by femoral–popliteal bypass surgery, the skin perfusion pressure values of the dorsum and plantar were 42 and 35 mmHg, respectively. (b) The modified transmetatarsal amputation is performed. (c) The vascular complex (arrows) between the metatarsal bone is preserved. (d, e) The patient has been able to walk with custom-made footwear for 10 years postoperatively.

of the ischemic foot, Terashi et al.³⁾ proposed the use of dynamic skin perfusion pressure (SPP). SPP is one of the most reliable measurements for accurately predicting wound healing because it can measure the blood flow state at the adjacent point to the wound exactly.^{4,5)} To identify the main source artery of the wound area, they measured SPP while occluding one of the main arteries by hand. For example, if SPP at the target point decreases when the ATA is occluded manually, it means that the main source artery at the target point is the ATA.

Foot Surgery Based on the Angiosome Concept

Attinger et al., also a plastic surgeon, adopted this concept for treating patients with ischemic diabetic foot.⁶⁾ On the basis of this concept, the authors proposed a safe incision, planning for local flaps, and a plan for revascularization. They recommended that if there is good flow from the source artery feeding each angiosome, the safest incisions should be made along the border between two adjacent angiosomes because each side of the incision has maximal

blood flow. If the signal of a source artery to one of the two adjacent angiosomes is absent, the affected ischemic angiosome will depend on the surrounding angiosomes via the choke vessels or the collateral artery from the patent source artery. Therefore, the incision should include the surrounding angiosomes and collateral artery, away from the patent source artery. In the case of more severe ischemia, revascularization should be performed first.

Recently, the use of microvascular free tissue transfer in diabetic patients has increased. The advantages of the free flap are reconstruction of the defect and the fact that it provides an adequate blood source to the ischemic region. However, in ischemic patients, it is often difficult to use free flaps because of the lack of proper recipient vessels. Hong and Suh performed supermicrosurgery based on the angiosome concept for reconstruction in diabetic ischemic ulcers.⁷⁾ The ischemic ulceration follows the angiosome concept, where the source vessel is obliterated due to calcification and the corresponding skin becomes ischemic and necrotic. Thus, the recipient vessel should be detected in a different angiosome territory. They used small perforating arteries from the healthy angiosome adjacent to the isch-

emic lesion as recipient vessels. In the case of severe ischemia, revascularization by endovascular therapy (EVT) or bypass surgery was performed to improve the blood flow to the distal limb before reconstruction. By using this technique, their overall success rate for supermicrosurgery in diabetic foot was 90.5%. Compared to their success rate when using major vessels in an end-to-side manner or when using the branch artery from the major vessel (91.7%), the overall success rate is slightly lower, but this is an acceptable result.

Terashi et al.⁸⁾ proposed a modified transmetatarsal amputation (TMA) based on this concept. TMA is one of the minor amputations that is often performed when two or more toes become infected or gangrened beyond the metatarsophalangeal joint in patients with CLI. Among minor amputations, TMA seems to be the most effective in terms of limb salvage rates and in maintaining foot and ankle biomechanics.⁹⁾ In order to maintain foot and ankle biomechanics, the entire metatarsal shaft should be preserved as much as possible, and the stump should be covered distally with good plantar skin, avoiding the use of split skin grafts.¹⁰⁾ However, nonhealing often occurs after TMA because of vascular insufficiency, uncontrolled infection, or inappropriate wound care.¹¹⁾ In patients with CLI, adequate blood flow is essential for wound healing. In order to maintain the blood flow as much as possible, they proposed a modified TMA to preserve the vascular complex (e.g., muscles, periosteum, and vessels) between the metatarsal bone, including the first proximal perforating artery, which is the biggest arterial–arterial connection between the DPA and MPA. This connection may be larger to compensate for a small lateral plantar artery or be replaced by a large perforating branch of the peroneal artery. By using this method, the authors showed complete healing in all 11 patients. Originally, the angiosome of the plantar flap was vascularized by the MPA and lateral plantar artery. Although this direct route is disrupted, the plantar flap can be vascularized by the DPA through the retained first proximal perforating artery (Figs. 1a–1e).

Reconstruction by the flap based on the angiosome concept can be useful in a smaller area. Sakakibara et al.¹²⁾ reported the efficacy of the fillet toe flap in toe amputation. The fillet flap is one of the options for primary coverage of the toe, which was introduced as a neurovascular flap by Snyder and Edgerton¹³⁾ in 1965. By including the neurovascular bundle of the digital artery, this flap restores both sensation and vascularity. We often experience patients with CLI who have an ulcer that is limited to half of the toe, which is injured by the next nail or toe. In such cases, if the digital artery of the non-affected half side is preserved, we can resect the necrotic and infected half of the toe and cover it with a fillet toe flap safely. However, if the digital artery is disrupted, the flap should not be used, and

revascularization or more proximal amputation should be considered.

Revascularization Based on the Angiosome Concept

Osawa et al.²⁾ showed that in the case of patency of the arterial–arterial connections, even if a patient undergoes EVT for any of the three vessels in the lower leg, direct blood flow to the wound is achieved. They found no significant difference in the wound healing rate between the one straight line EVT group and the direct group through arterial–arterial connections. As for bypass surgery, Azuma et al.¹⁴⁾ reported that the angiosome concept seems unimportant, at least in non-end-stage renal disease cases. The location and extent of ischemic wounds as well as comorbidities may be more relevant. Blood flow through the bypass graft is directly perfused into a foot artery at a blood pressure similar to the central pressure; therefore, perfusion may be achieved beyond the angiosome, differing from EVT. However, Varela et al.¹⁵⁾ showed no significant difference in the healing and limb salvage rates between the directly revascularized group and the indirectly revascularized via arterial–arterial connections group. On the other hand, there was a significant difference between both groups when compared to the indirectly revascularized group without arterial–arterial connections. As stated in the comment by Attinger,¹⁶⁾ the best method is direct revascularization of the artery feeding a given angiosome. The second best method would be indirect revascularization of the artery feeding a given angiosome via arterial–arterial connections. The third best method would be indirect revascularization where the artery feeding the angiosome remains occluded.

The goal of revascularization is not only to recanalize the vessels to the foot but also to reperfuse the tissue adequately. Therefore, doctors who perform EVT or distal bypass surgery have to confirm the reperfusion states of the wound themselves after revascularization. Utsunomiya et al.¹⁷⁾ proposed the wound blush concept modeled after the myocardial blush grade, which has been established as a useful assessment of reperfusion at the myocardial tissue level after angioplasty for acute myocardial infarction. They reported that the presence of wound blush after EVT is associated with higher skin perfusion pressure, both of which are associated with higher rates of limb salvage in patients with CLI. After distal bypass surgery, intraoperative angiography is often performed; therefore, wound blush will appear at an angiographic end point after revascularization and will be a novel predictor of limb salvage in patients with CLI.

Conclusion

For wounds in patients with CLI to heal, both successful revascularization and wound management are crucial. In order to preserve the blood supply as much as possible intraoperatively, surgeons should always consider the angiosome concept.

Disclosure Statement

There is no conflict of interest.

Author Contributions

Study conception: MF

Data collection: MF

Analysis: MF

Investigation: MF

Writing: MF

Critical review and revision: all authors

Final approval of the article: all authors

Accountability for all aspects of the work: all authors

References

- 1) Taylor GI, Palmer JH. The vascular territories (angiosomes) of the body: experimental study and clinical applications. *Br J Plast Surg* 1987; **40**: 113-41.
- 2) Osawa S, Terashi H, Tsuji Y, et al. Importance of the six angiosomes concept through arterial-arterial connections in CLI. *Int Angiol* 2013; **32**: 375-85.
- 3) Terashi H, Iwayama T, Iida O, et al. Dynamic skin perfusion pressure: a new measure of assessment for wound healing capacity and alternative angiosome in critical limb ischemia. *Plast Reconstr Surg* 2010; **126**: 215e-8e.
- 4) Castronuovo JJ Jr, Adera HM, Smiell JM, et al. Skin perfusion pressure measurement is valuable in the diagnosis of critical limb ischemia. *J Vasc Surg* 1997; **26**: 629-37.
- 5) Tsuji Y, Terashi H, Kitano I, et al. Importance of skin perfusion pressure in the treatment of critical limb ischemia. *Wounds* 2008; **20**: 95-100.
- 6) Attinger CE, Evans KK, Bulan E, et al. Angiosomes of the foot and ankle and clinical implications for limb salvage: reconstruction, incisions, and revascularization. *Plast Reconstr Surg* 2006; **117 Suppl**: 261S-93S.
- 7) Suh HS, Oh TS, Lee HS, et al. A new approach for reconstruction of diabetic foot wounds using the angiosome and supermicrosurgery concept. *Plast Reconstr Surg* 2016; **138**: 702e-9e.
- 8) Terashi H, Kitano I, Tsuji Y, et al. A modified transmetatarsal amputation. *J Foot Ankle Surg* 2011; **50**: 441-4.
- 9) Ammendola M, Sacco R, Butrico L, et al. The care of transmetatarsal amputation in diabetic foot gangrene. *Int Wound J* 2017; **14**: 9-15.
- 10) Bowker JH, San Giovanni TP. Minor and major lower-limb amputation in persons with diabetes mellitus. In: Bowker JH, Pfeifer MA eds. *Levin and O'Neal's the Diabetic Foot*, 7th ed. Philadelphia: Mosby, 2008: 403-28.
- 11) Nguyen TH, Gordon IL, Whalen D, et al. Transmetatarsal amputation: predictors of healing. *Am Surg* 2006; **72**: 973-7.
- 12) Sakakibara S, Terashi H, Sakurai S, et al. The fillet toe flap in toe amputation. *Sosyo* 2012; **3**: 123-8. (in Japanese)
- 13) Snyder GB, Edgerton MT Jr. The principle of the island neurovascular flap in the management of ulcerated anesthetic weightbearing areas of the lower extremity. *Plast Reconstr Surg* 1965; **36**: 518-28.
- 14) Azuma N, Uchida H, Kokubo T, et al. Factors influencing wound healing of critical ischaemic foot after bypass surgery: is the angiosome important in selecting bypass target artery? *Eur J Vasc Endovasc Surg* 2012; **43**: 322-8.
- 15) Varela C, Acín F, de Haro J, et al. The role of foot collateral vessels on ulcer healing and limb salvage after successful endovascular and surgical distal procedures according to an angiosome model. *Vasc Endovascular Surg* 2010; **44**: 654-60.
- 16) Attinger C. Comment on: 'Factors influencing wound healing of critical ischaemic foot after bypass surgery: is the angiosome important in selecting bypass target artery?' *Eur J Vasc Endovasc Surg* 2013; **45**: 99.
- 17) Utsunomiya M, Nakamura M, Nakanishi M, et al. Impact of wound blush as an angiographic end point of endovascular therapy for patients with critical limb ischemia. *J Vasc Surg* 2012; **55**: 113-21.