

Subcutaneous implantable cardioverter-defibrillator implantation in a patient with bilateral pectoral deep brain stimulators



Thor Tejada, MD,* Faisal M. Merchant, MD, FHRS,[†] Mikhael F. El-Chami, MD, FHRS[†]

From the *Division of Cardiology, Department of Medicine, Emory University, Atlanta, Georgia, and

[†]Section of Electrophysiology, Division of Cardiology, Department of Medicine, Emory University, Atlanta, Georgia.

Introduction

Deep brain stimulators (DBS), used in the treatment of Parkinson disease (PD), may interfere with the function of implantable cardioverter-defibrillators (ICD) used for prevention of sudden cardiac death. DBS have been implanted in 150,000 patients worldwide. Few reports of implantation of an ICD in patients with preexisting DBS have reported safe outcomes when the 2 devices are placed away from each other (ie, in the contralateral shoulders or the abdomen and shoulder).^{1,2} One report of a subcutaneous ICD (S-ICD) implantation in a patient with a right pectoral DBS demonstrated feasibility without evidence of oversensing or inappropriate shocks.³

Case report

A 72-year-old man with ischemic cardiomyopathy (ejection fraction = 25%) and advanced PD was referred for an ICD implantation for primary prevention of sudden cardiac death. He had a history of myocardial infarction and coronary artery bypass graft surgery. He also had bilateral globus pallidus internus DBS for the management of PD.

His electrocardiogram (ECG) showed normal sinus rhythm, QRS duration < 120 ms, and significant noise artifact from the DBS (Figure 1A). The patient's DBS Medtronic generators were implanted in 2014 in a prepectoral location bilaterally, just below the deltopectoral groove, similar to a standard location for an ICD.

In general, it is recommended for an ICD to be implanted at least 6 inches away from a DBS generator or on the contralateral side to avoid interference between devices and during

telemetry reprogramming.^{1,2} Given the anatomical limitations in this patient, the option of S-ICD implantation was offered to the patient and risks of potential interaction with the DBS discussed. The patient was an appropriate candidate at the time of S-ICD screening and the procedure was completed successfully (Figure 1B). The DBS was programmed in the "monopolar" setting (equivalent to unipolar setting for a pacemaker or an ICD) because programming in the bipolar setting in this case did not result in tremor suppression. At the time of implant, no interaction between the DBS and S-ICD was detectable on interrogation in the 3 sensing vectors (primary, secondary, and alternate) (Figure 2). Defibrillation threshold was \leq 65 joules with appropriate ventricular fibrillation detection. The device was programmed with the secondary vector for sensing. At 6 months' follow-up, it was noted that QRS complexes were labeled as noise on the S-ICD electrogram (Figure 3A). This occurred around the same time of an increase in the amplitude of deep brain stimulation during follow-up in the neurology clinic. Sensing in the primary and alternate vectors, however, showed appropriate sensing and no noise (Figure 3B). The S-ICD was programmed in primary vector configuration. At 12 months' follow-up, the patient had healed well and no further sensing abnormalities were detected. He has not experienced any S-ICD shocks. DBS function remains unhindered and his tremor appropriately suppressed.

Discussion

To our knowledge, this is the first case of S-ICD implantation in a patient with bilateral DBS.

Prior cases of concurrent implantation of standard single-coil ICD and DBS have been reported, but such implantation is believed to be safe, at least in part owing to the use of an integrated bipole for arrhythmia detection and the implantation of the 2 devices in the contralateral shoulders, thus avoiding potential oversensing, given a "smaller antenna" effect and relative separation of the 2 devices.^{1,2} In addition, a

KEYWORDS Subcutaneous ICD; Deep brain stimulator; Oversensing; Sudden cardiac death; Inappropriate shocks (Heart Rhythm Case Reports 2018;4:109–112)

Dr El-Chami is a consultant for Medtronic and Boston Scientific. **Address reprint requests and correspondence:** Dr Mikhael F. El-Chami, Division of Cardiology, Department of Medicine, Emory University, 6th Floor Medical Office Tower, 550 Peachtree St NE, Atlanta, GA 30308. E-mail address: melcham@emory.edu.

KEY TEACHING POINTS

- Subcutaneous implantable cardioverter-defibrillators (S-ICD) can be implanted safely in patients with deep brain stimulators (DBS).
- DBS could affect sensing in patients with S-ICD.
- Changing sensing vectors on the S-ICD could overcome sensing abnormalities due to device–device interaction in this setting.

report of an S-ICD implanted in a patient with a preexisting DBS in the right pectoral area suggested lack of interaction between the 2 devices.³ In the aforementioned report, the DBS was programmed in the bipolar configuration to minimize the risk of device–device interactions. Also, the

presence of the 2 devices in the contralateral chest area probably helped minimize the risk of oversensing.

In our case, the presence of bilateral DBS makes the option of a prepectoral transvenous ICD less appealing. This is owing to the anatomic constraints and the proximity of the DBS and the ICD pulse generator, which could increase the risk of device–device interactions and oversensing.

Tunneling of a transvenous ICD lead (from a transiliac or even subclavian approach) to an abdominal pocket could be considered in this situation to ensure that the ICD generator and DBS are separated anatomically. However, this approach is cumbersome and has its own drawbacks. For instance, using the iliac vein for implanting a transvenous lead and tunneling the lead to the abdominal pocket could potentially carry a higher risk for infection owing to the location of the entry point (groin area). In addition, tunneled leads could have a higher risk of lead fracture and also dislodgement.

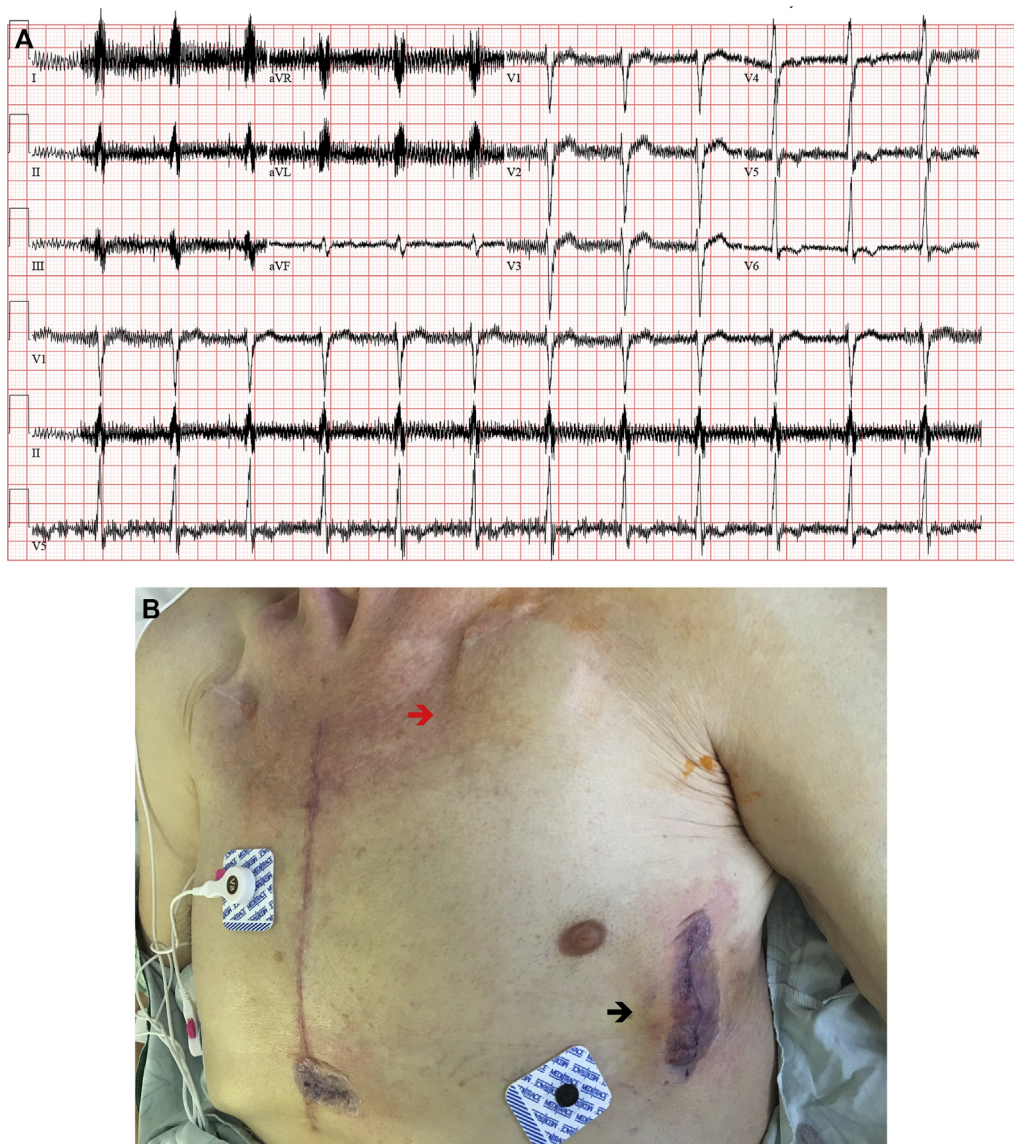


Figure 1 A: Twelve-lead electrocardiogram with baseline noise. B: Patient with a subcutaneous implantable cardioverter-defibrillator (S-ICD) (indicated by black arrow) and 2 deep brain stimulators (DBS) in prepectoral location (red arrow).

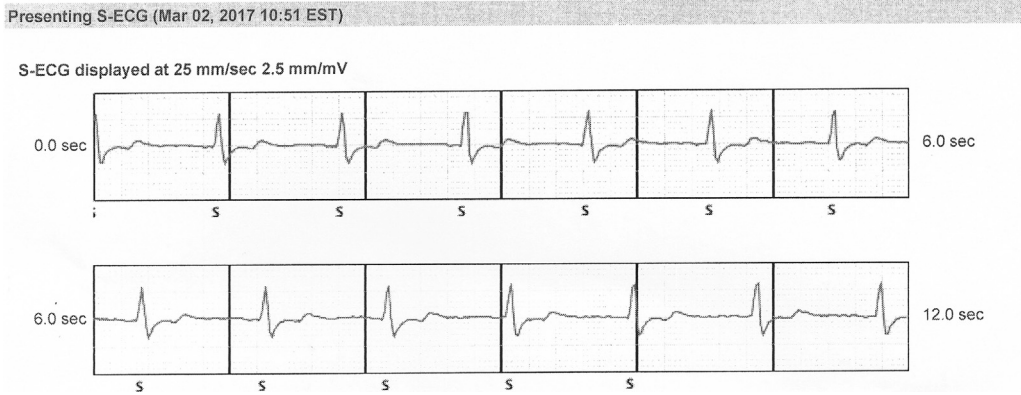


Figure 2 A subcutaneous implantable cardioverter-defibrillator electrogram recording showing appropriate sensing post implant.

An S-ICD was considered in this situation with acknowledgment of the potential for oversensing. Interestingly, appropriate sensing was seen in all 3 S-ICD vectors at implant, despite the fact that the DBS was programmed in the monopolar setting. Upon follow-up, increasing the output on the DBS resulted in altered sensing on the S-ICD (Figure 3A), highlighting the importance of communicating programming changes between the neurology clinic and the electrophysiology clinic during follow-up. The S-ICD sensing algorithm was developed to minimize muscle noise (myopotentials). The sensing algorithm uses the ECG within

the refractory duration following each detected event to identify the presence of muscle noise. The algorithm is designed to detect frequencies higher than 30–35 Hz characteristic of the muscle noise. As a result, the high-frequency nature of the DBS system is being identified as noise by the S-ICD system.

The S-ICD labels QRSs as noise primarily because the noise induced by the DBS system is similar to the muscle/burst noise characteristic. On the other hand, the S-ICD aims to remove continuous noise (50/60 Hz noise) while it intends to identify and mark burst noise (muscle,

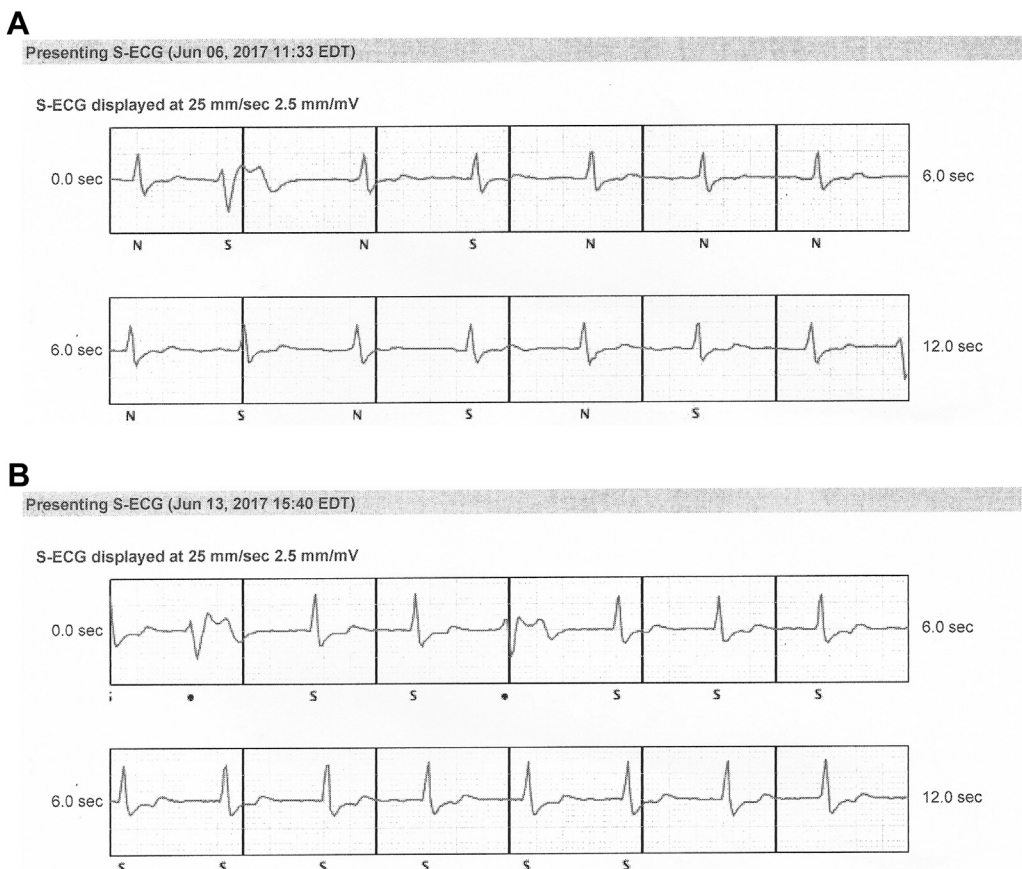


Figure 3 **A:** A subcutaneous implantable cardioverter-defibrillator (S-ICD) electrogram recording showing QRS complexes labeled as noise (N) in secondary vector. **B:** An S-ICD electrogram recording showing QRS appropriately sensed in primary vector.

electrocautery, etc). Because the noise by the DBS system is similar to the muscle noise, the sensing algorithm labels it as noise without removing it. The S-ICD also employs additional bandpass and notch filters to further reduce electromagnetic interference effects; for example, the S-ICD system labels QRSs during cautery as noise.

Changing the sensing vector on the S-ICD in our case eliminated the sensing abnormality (Figure 3B). Throughout follow-up, the output on the DBS was routinely adjusted in the neurology clinic but did not result in an alteration in sensing while the S-ICD was programmed in the primary vector.

Conclusion

This case illustrates the feasibility and safety of implanting an S-ICD in a patient with bilateral DBS. Despite the proximity

of an S-ICD to the DBS (left pectoral area), the complex sensing algorithm of the S-ICD is effective in avoiding oversensing and ensures adequate sensing of intracardiac signals. Also, this case illustrates the importance of communicating any device parameter changes done by either the neurology or the electrophysiology clinic, as it might affect device function and could result in harm.

References

1. Karimi A, Conti JB, Beaver TM. Implantation of a cardiac resynchronization therapy defibrillator in a patient with bilateral deep brain stimulator: feasibility and technique. *J Interv Card Electrophysiol* 2012;35:351–353. discussion 353.
2. Obwegeser AA, Uitti RJ, Turk MF, Wszolek UM, Flipse TR, Smallridge RC, Witte RJ, Wharen RE Jr. Simultaneous thalamic deep brain stimulation and implantable cardioverter-defibrillator. *Mayo Clin Proc* 2001;76:87–89.
3. Bader Y, Weinstock J. Successful implantation of a subcutaneous cardiac defibrillator in a patient with a preexisting deep brain stimulator. *HeartRhythm Case Rep* 2015;1:241–244.