



## ■ HIP

# The outcome of the uncemented acetabular component in delayed total hip arthroplasty following acetabular fractures

**A. El-Bakoury,  
W. Khedr,  
M. Williams,  
Y. Eid,  
A. S. Hammad**

*From Derriford Hospital, Plymouth University Hospitals NHS Trust, Plymouth, UK, and El-Hadara University Hospital, Alexandria University, Alexandria, Egypt.*

## Aims

After failed acetabular fractures, total hip arthroplasty (THA) is a challenging procedure and considered the gold standard treatment. The complexity of the procedure depends on the fracture pattern and the initial fracture management. This study's primary aim was to evaluate patient-reported outcome measures (PROMs) for patients who underwent delayed uncemented acetabular THA after acetabular fractures. The secondary aims were to assess the radiological outcome and the incidence of the associated complications in those patients.

## Methods

A total of 40 patients underwent cementless acetabular THA following failed treatment of acetabular fractures. The postoperative clinical and radiological outcomes were evaluated for all the cohort.

## Results

The median (interquartile range (IQR)) Oxford Hip Score (OHS) improved significantly from 9.5 (7 to 11.5), (95% confidence interval (CI) (8 to 10.6)) to 40 (39 to 44), (95% CI (40 to 43)) postoperatively at the latest follow-up ( $p < 0.001$ ). It was worth noting that the initial acetabular fracture type (simple vs complex), previous acetabular treatment (ORIF vs conservative), fracture union, and restoration of anatomical centre of rotation (COR) did not affect the final OHS. The reconstructed centre of rotation (COR) was restored in 29 (72.5%) patients. The mean abduction angle in whom acetabular fractures were managed conservatively was statistically significantly higher than the surgically treated patients  $42.6^\circ$  (SD 7.4) vs  $38^\circ$  (SD 5.6)) ( $p = 0.032$ ). We did not have any case of acetabular or femoral loosening at the time of the last follow-up. We had two patients with successful two-stage revision for infection with overall eight-year survival rate was 95.2% (95% CI 86.6% to 100%) with revision for any reason at a median (IQR) duration of follow-up 50 months (16 to 87) months following THA.

## Conclusion

Delayed cementless acetabular THA in patients with previous failed acetabular fracture treatments produces good clinical outcomes (PROMs) with excellent survivorship, despite the technically demanding nature of the procedure. The initial fracture treatment does not influence the outcome of delayed THA. In selected cases of acetabular fractures (either nondisplaced or with secondary congruency), the initial nonoperative treatment neither resulted in large acetabular defects nor required additional acetabular reconstruction at the time of THA.

**Cite this article:** *Bone Jt Open* 2021;2-12:1067–1074.

**Keywords:** Acetabular fracture, Uncemented, PROMs, Oxford Hip Score (OHS), Total hip arthroplasty (THA)

Correspondence should be sent to Waseem Khedr; email: Waseemkhdr@gmail.com

doi: 10.1302/2633-1462.212.BJO-2021-0118.R1

*Bone Jt Open* 2021;2-12:1067–1074.

## Introduction

Fractures of the acetabulum are complex, high-energy injuries with the potential for

poor outcomes regardless of the treatment method.<sup>1</sup> Although anatomical reduction of displaced acetabular fractures is

associated with more favourable functional outcome,<sup>2</sup> post-traumatic arthritis can still occur, with an incidence approaching 30%. This can be attributed to the articular cartilage damage at the time of injury, non-anatomical reduction, intra-articular screws, or avascular necrosis of the femoral head.<sup>2,3</sup>

The surgical management of symptomatic post-traumatic arthritis is mainly limited to total hip arthroplasty (THA).<sup>4,5</sup> However, THA following acetabular fractures can be challenging and might result in increased surgical time, blood loss, or unsatisfactory acetabular component placement.<sup>6</sup> Moreover, those patients have inferior clinical outcomes compared to others undergoing THA for primary osteoarthritis (OA).<sup>7</sup> Heterotopic ossification, surgical site infection, and implant loosening are among the leading reasons for the increased reoperation rate in those patients.<sup>8</sup> Initial open reduction and internal fixation (ORIF) of acetabular fractures may facilitate the subsequent THA, as it aids in the restoration of the bony landmarks and hip centre. However, following ORIF, the arthroplasty surgeon has to deal with potential challenges such as extensive soft-tissue scarring, heterotopic ossification, retained internal devices, and residual bone defects.<sup>9</sup> On the other hand, THA following nonoperatively treated acetabular fractures has its difficulties as patients often present with a high hip centre, acetabular protrusion, acetabular bone defects and/or nonunion.

Both cemented and uncemented acetabular components have been used to manage post-acetabular fracture OA.<sup>10,11</sup> Recent advances in uncemented acetabular fixation have led to improvement of the radiological and functional parameters of THA after acetabular fractures.<sup>12-15</sup> Therefore, the primary aim of this study was to evaluate patient-reported outcome measures (PROMs) for patients who underwent delayed uncemented acetabular THA after acetabular fractures. The secondary aims were to assess the radiological outcome and the incidence of the associated complications in those patients.

## Methods

This is a retrospective cohort study that involved patients from two major trauma centres. We included 40 patients who underwent delayed uncemented or hybrid THA for post-traumatic OA and/or femoral head osteonecrosis following acetabular fractures. The THA procedure was performed between September 2007 and April 2019. Internal review board approval was obtained for this study at both institutions.

There were 31 (77.5%) males. The right hip was affected in 23 (67.5%) patients. The mean age at the time of initial acetabular fracture was 44.7 years (standard deviation (SD) 16.3, 18 to 76) and the mean interval between the acetabular fracture and the THA was 20 months (SD 25.4, 3 to 144). The mean patient age at the time of THA

**Table 1.** Demographic, initial fracture, operative, and outcome data for whole cohort.

Variable	Total (n = 40)
Mean age at time of injury, yrs (range)	44.7 (18 to 76)
Mean age at the time of THA, yrs (range)	46.7 (21 to 77)
<b>Fracture union, n (%)</b>	
United	35 (87.5)
Not united	5 (12.55)
<b>Paprosky classification, n (%)</b>	
I	8 (20)
IIA	10 (25)
IIB	8 (20)
IIC	12 (30)
IIIA	2 (5)
<b>Bone graft use, n (%)</b>	
Used	27 (67.5)
Not used	13 (32.5)
<b>Median OHS (IQR)</b>	
Preoperative	9.5 (7 to 11.5)
Postoperative	40 (39 to 44)
p-value*	< 0.001
Test value	Z = -5.5
<b>Postoperative hip COR, n (%)</b>	
Restored	29 (72.5)
Not restored	11 (27.5)

\*Wilcoxon signed-rank test for comparing between preoperative and postoperative OHS.

COR, centre of rotation; IQR, interquartile range; OHS, Oxford Hip Score; THA, total hip arthroplasty.

was 46.7 years (SD 16.1, 21 to 77). All patients data are detailed in Table 1.

**Preoperative.** All patients were evaluated clinically and radiologically. Routine laboratory investigations including inflammatory markers, were performed for all patients. If the latter were suggestive of potential infection, a preoperative hip aspiration was also performed. Acetabular bone deficiencies were evaluated on the preoperative radiographs and were classified according to Paprosky's classification.<sup>16</sup> Details of the preoperative acetabular defects are described in Table 1.

**Surgical technique.** The posterior approach was used for all patients. Retained hardware was not routinely removed unless it interfered with acetabular reaming or placement of the acetabular component. The fracture union was evaluated. Impaction bone graft was used in the cases of contained acetabular defects. Small segmental defects (less than 20%) were not reconstructed if adequate stability of the acetabular component was achieved. Larger segmental defects were reconstructed with femoral head auto or allograft. If there was evidence of nonunion of the acetabular fracture, additional posterior plate osteosynthesis was performed. The uncemented acetabular components (Trident Tritanium (Stryker, USA), Continuum (Zimmer Biomet, USA), Novae E TH cup (SERF, France) were used in all patients with additional screw

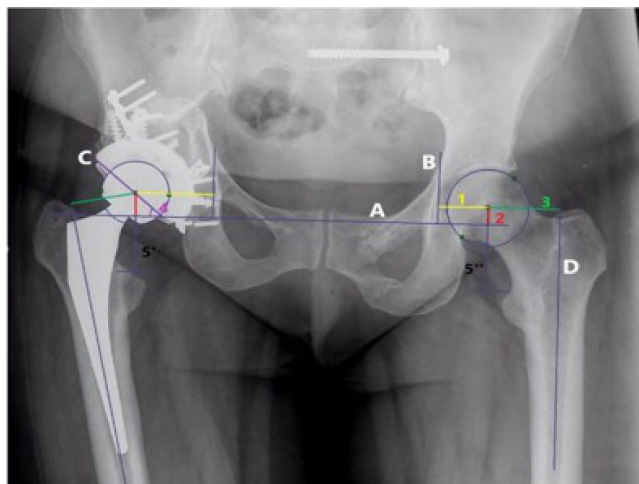


Fig. 1

Analysis of postoperative radiograph after uncemented total hip arthroplasty. A, horizontal teardrop line. B, vertical teardrop line. C, line along the lateral surface of the acetabular component. D, femoral shaft line. 1, horizontal hip centre of rotation (COR). 2, vertical hip COR. 3, Horizontal femoral offset. 4, the abduction angle. 5, limb length discrepancy: difference between 5' (vertical distance from the tear-drop line to lesser trochanter in the operated side) and 5'' (vertical distance from the tear-drop line to lesser trochanter in the nonoperated side).

augmentation when required. In 11 (27.5 %) hips, cemented stem was used, and in the remaining 29 (72.5%), a cementless stem was used.

**Postoperative.** All patients had thromboembolic chemoprophylaxis with either Enoxaparin for 28 days or Rivaroxaban for 35 days. Prophylaxis against heterotopic ossification was not routinely used. Patients were routinely mobilized full weightbearing from day one postoperatively. However, patients who had received bone graft and/or had additional plate osteosynthesis were instructed to mobilize with partial weightbearing (50% of their body weight) for six weeks postoperatively and gradually increase this to full weightbearing after that.

**Follow-up.** All patients were subjected to clinical and radiological evaluation at six weeks, six months, and one year. PROMs in the form of Oxford Hip Score (OHS)<sup>17</sup> were obtained from all patients preoperatively and at the final follow-up.

**Radiological assessment.** The initial acetabular fractures were radiologically assessed and classified using the Judet and Letournel classification.<sup>3</sup> Radiological evaluation was performed using the end of follow-up plain radiographs for all patients. The radiological assessment involved the evaluation of cup position, hip centre restoration, bone graft integration, signs of radiological loosening, and potential limb length discrepancy. The centre of rotation (COR) of the acetabular component was evaluated according to the method of Massin et al<sup>18</sup> (Figure 1). The anatomical restoration of COR was defined as a horizontal and vertical variation of less than 10 mm from the contralateral hip.<sup>19</sup> The leg length discrepancy was

determined by extending a line, perpendicular to the tear drop line, to the top of the lesser trochanter and the difference in measurement equals the limb length discrepancy.<sup>20</sup> The osseointegration of the acetabular component was assessed according to the criteria of Della Valle et al.<sup>21</sup> Heterotopic ossification was classified according to Brooker's classification.<sup>22</sup>

**Statistical analysis.** All statistical analyses were performed using SPSS v.19 software (IBM, USA). Where appropriate, the arithmetic mean and SD, together with median and interquartile range (IQR), were calculated. Comparisons between groups for categorical variables were assessed using chi-squared test, Fisher's exact test, or Monte Carlo correction. Paired *t*-test was used to compare two groups for normally distributed quantitative variables. Mann-Whitney U test was used to compare between two groups for not normally distributed quantitative variables while Wilcoxon signed-rank test was assessed for comparison between two periods for not normally distributed quantitative variables. Statistical significance was defined as  $p < 0.05$ . The mean duration to revision was estimated using Kaplan-Meier estimator with 95% confidence intervals (CIs). The endpoint was defined as acetabular component revision or intention to revise (patient awaiting revision surgery) for any reason.

## Results

The initial acetabular fractures were classified as simple fractures in 22 (55%) patients and complex fractures in 18 (45%) patients. A total of 25 patients had a previous internal fixation and 15 patients were managed nonoperatively. The indications for THA were post-traumatic arthritis in 30 (75%) patients and femoral head osteonecrosis in ten (25%) patients.

We demonstrated fracture nonunion in five (12.5%). Four of them were with displaced acetabular fractures managed nonoperatively in other centres and then were referred to our institution. One patient had a nonunited transverse fracture acetabulum after anterior fixation.

The bone graft was used in 27 (67.5%) patients either as a morcellized graft for cavity defects in 21 patients or a structural graft for segmental defects in six patients. The dual-mobility cup was used in seven cases (17.5%). The articulation was either metal-on-polyethylene in 14 (35%), ceramic-on-ceramic in 19 (47.5%), or ceramic-on-polyethylene in seven cases (17.5%).

**Clinical outcome.** The median duration of follow-up following THA was 50 months (IQR 16 to 87). The preoperative median OHS improved significantly from 9.5 (IQR 7 to 11.5, 95% CI (8 to 10.6)) to 40 (IQR 39 to 44, 95% CI (40 to 43)) postoperatively at the latest follow-up ( $p < 0.001$ ) (Table I).

We evaluated several factors which could potentially affect the final OHS. The previous management of acetabular fractures did not affect the final OHS, as the median

**Table II.** Comparative data between the open reduction and internal fixation and conservative groups.

Variable	ORIF (n = 25)	Conservative (n = 15)	p-value
Initial acetabular fracture displacement, n (%)	25 (100)	4 (26.6)	< 0.001*
<b>Fracture union, n (%)</b>			
United	24 (96)	11 (73.3)	0.056*
Not united	1 (4)	4 (26.6)	
<b>Paprosky classification, n (%)</b>			0.302†
I	8 (32)	0 (0)	
IIA	7 (28)	3 (20)	
IIB	2 (8)	6 (40)	
IIC	7 (28)	5 (33.3)	
IIIA	1 (4)	1 (6.6)	
<b>Bone graft use, n (%)</b>			0.298*
Used	15 (60)	12 (80)	
Not used	10 (40)	3 (20)	
<b>Median OHS (IQR)</b>			
Preoperative	9 (7 to 11.25)	10 (7 to 11.75)	0.937‡
Postoperative	40 (38.75 to 43.25)	41 (39.25 to 44)	0.485‡
p-value§	< 0.001	< 0.001	
Restoration of the hip (COR), n (%)	19 (76)	10 (66.7)	0.736*
Mean abduction angle, ° (SD)	38 (5.6)	42.6 (7.4)	0.032¶
Complication after THA, n (%)	5 (20)	1 (6.6)	0.552*
Revision, n (%)	2 (8)	0 (0)	1.000*

\*Fisher's exact test.

†Monte Carlo correction.

‡Mann-Whitney U test to compare the two studied groups.

§Wilcoxon signed-rank test to compare the preoperative and postoperative OHS.

¶Paired *t*-test.

COR, centre of rotation; IQR, interquartile range; OHS, Oxford Hip Score; ORIF, open reduction and internal fixation; SD, standard deviation; THA, total hip arthroplasty.

OHS among the ORIF-treated patients was not statistically significantly different from that of the conservatively treated patients. Detailed comparison between the ORIF and conservative patients groups are described in Table II. It is worth noting that the acetabular fracture type (simple vs complex), fracture union, bone graft use, and restoration of anatomical COR did not affect the final OHS (Table III). Infection was the only reason for revision in our study.

**Radiological outcome.** The reconstructed COR was restored in 29 (72.5%) patients (Table I). The mean post-THA limb length discrepancy was 5.3 mm (SD 3.7). The mean abduction angle for the cohort was 39.7° (SD 6.7). The mean abduction angle in the conservative group (42.6° (SD 7.4)) was statistically significantly higher than that in the ORIF group (38° (SD 5.6)) ( $p = 0.032$ , paired *t*-test) (Table II). There were no signs of acetabular or femoral component loosening at the time of the last follow-up (Figures 2 and 3).

**Table III.** Factors affecting the Oxford Hip Score in all patients.

Factor	n (%)	Mean postoperative Oxford Hip Score (SD)	p-value*
<b>Fracture type</b>			0.900
Simple	22 (55.0)	40.4 (5.2)	
Complex	18 (45.0)	40.6 (4.2)	
<b>Fracture union</b>			0.785
United	35 (87.5)	40.4 (4.9)	
Not united	5 (12.5)	41.0 (3.3)	
<b>Bone graft use</b>			0.645
Not used	27 (67.5)	40.3 (3.8)	
Use	13 (32.5)	40.6 (6.48)	
<b>Hip centre of rotation</b>			0.752
Restored	29 (72.5)	40.6 (5.2)	
Not restored	11 (27.5)	40.1 (3.5)	

\*Paired *t*-test for comparing between different categories.

**Complications.** Complications developed in six (15%) patients (Table IV): they occurred in five (20%) patients from the ORIF group and one (6.6%) patient from the conservative group ( $p = 0.552$ , Fisher's exact test) (Table II).

Periosthetic joint infection (PJI) occurred in three (7.5%) patients. Two patients from the ORIF group required two-stage revision THA and one patient from the conservative group managed successfully with debridement, antibiotics and implant retention (DAIR) procedure. The mean abduction angle in patients with dislocation (two patients, one from each group) was 43° (SD 14.1).

We had two patients with transient sciatic nerve injury (recovered within six months postoperatively), one patient had psoas tendinitis resolved after ultrasound-guided steroid injection to the psoas bursa, and one patient had trochanteric bursitis resolved after open trochanteric bursectomy. No patients had developed heterotopic ossification after the THA at the time of the last follow-up.

**Survival.** Only two patients (5%) (from the ORIF group) underwent successful two-stage revision for infection. The overall eight-year probability of survival was 95.2% (95% CI 86.6% to 100%). The mean time to revision was estimated, using Kaplan-Meier estimator, at 152.9 months (95% CI 137.0 to 168.7) (Figure 4).

## Discussion

Delayed THA for the treatment of acetabular fractures is considered a challenging reconstructive procedure, with inferior results compared to those who underwent primary THA for osteoarthritis.<sup>1,23</sup> Our study demonstrated that uncemented acetabular THA for failed treatment of acetabular fractures provides excellent improvement of PROMs. Other studies reported similar clinical outcomes (Table V).<sup>1,6,9,12,24–26</sup>



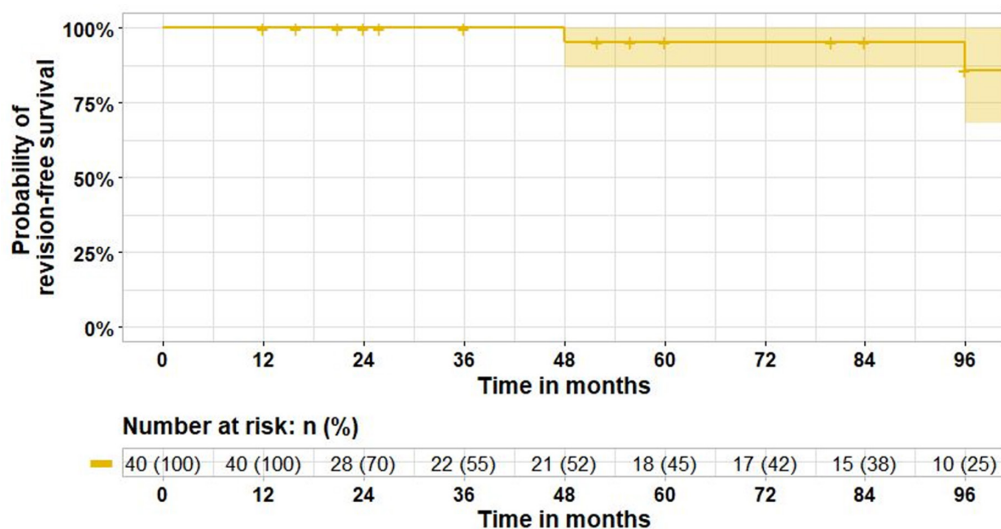


Fig. 2

Kaplan-Meier survival curve for implant revision in the entire cohort.

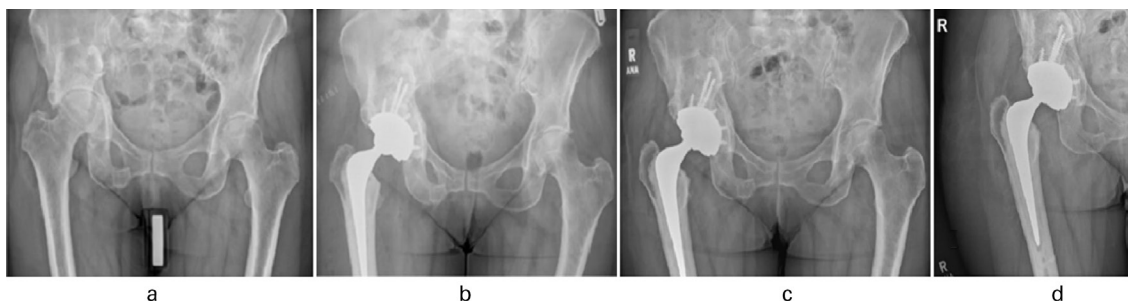


Fig. 3

73-year-old female patient who had a delayed right-sided uncemented total hip arthroplasty (THA). a) Preoperative anteroposterior (AP) radiograph showing osteoarthritis of right hip. b) Immediate postoperative AP radiograph view with right THA. c) and d) AP radiograph view after one-year follow-up following right THA.

**Table IV.** Distribution of complications in our study.

Patient	Group	Complication
1	Conservative	Infection required DAIR, dislocation, transient nerve injury
2	ORIF	Infection required two-stage revision, dislocation
3	ORIF	Infection required two-stage revision
4	ORIF	Transient nerve injury
5	ORIF	Trochanteric bursitis
6	ORIF	Psoas tendinitis

DAIR, debridement, antibiotics and implant retention; ORIF, open reduction and internal fixation.

Our cohort showed no significant difference in the postoperative OHS in patients who underwent initial ORIF versus those in whom acetabular fractures were managed conservatively. Wang et al<sup>24</sup> mentioned that they did not find evidence that ORIF could improve the subsequent THA's functional outcomes. On the other hand, Salama et al<sup>25</sup> reported that the Harris Hip Score<sup>27</sup> was higher in the ORIF group. However, their series included a small number of patients ( four patients) with

THA following conservative treatment, versus 17 patients who underwent THA following ORIF.

Our study demonstrated a significant higher nonunion in the conservative group (26.6%) ( $p = 0.056$ , Fisher's exact test) (Table II) and all of them required rigid fixation and bone graft at the time of THA surgery. Similar results have been reported by Wang et al,<sup>24</sup> who reported nonunion in four (33.3%) patients from the conservative group, and Gavaskar et al,<sup>9</sup> with a reported nonunion in nine (45%) patients from the conservative group. Nevertheless, our study displayed no statistically significant difference between both groups regarding acetabular defects and bone graft use, which may be related to the small number of patients included or surgeon's selection bias. It seems that the surgeons had a tendency to manage less displaced fractures nonoperatively prior to THA. In 11 (73.4 %) patients from the conservative group, the acetabular fracture was either non-displaced or with secondary congruency, and this might have resulted in less severe bone defects. Similar results were reported

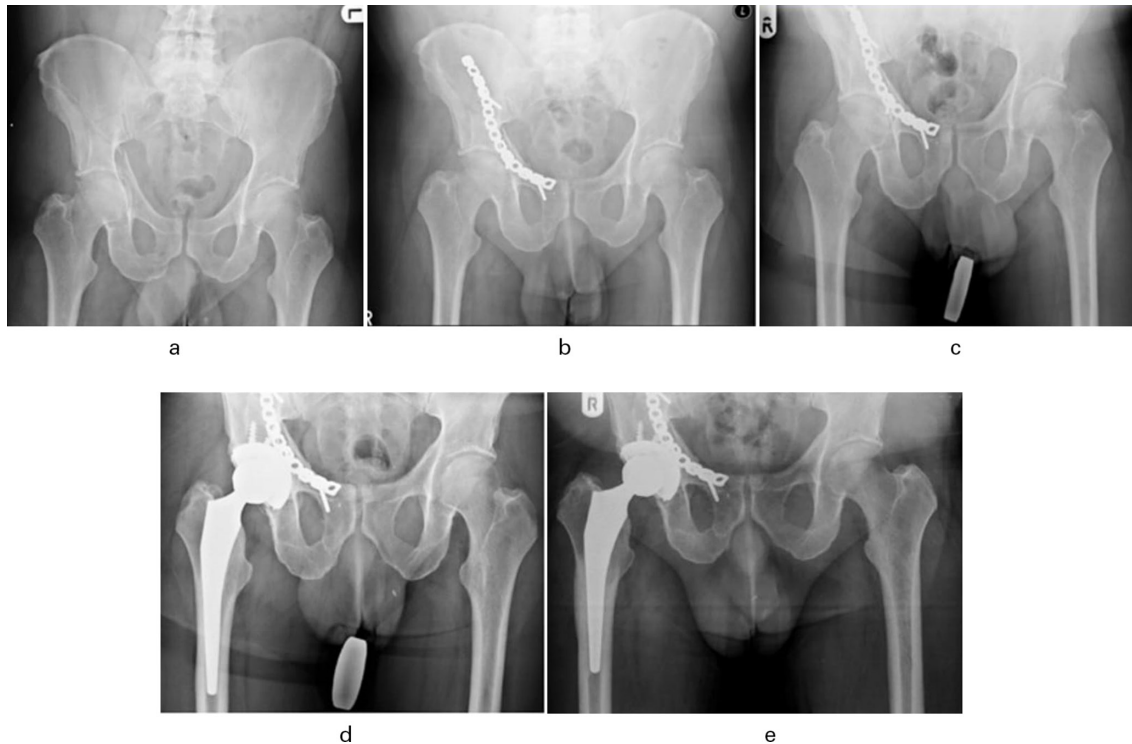

Fig. 4

58-year-old male patient who had a delayed right-sided uncemented total hip arthroplasty (THA). a) Initial injury anteroposterior (AP) radiograph showing right acetabular fracture. b) Initial AP radiograph post-open reduction and internal fixation of the right acetabular fracture. c) Preoperative AP radiograph showing osteoarthritis of the right hip. d) Immediate AP radiograph post-THA. e) A seven-year follow-up AP radiograph showed no loosening or osteolysis around the acetabular or femoral component.

by Wang et al.<sup>24</sup> Moreover, Zhang et al.<sup>26</sup> reported more extensive acetabular defects in the surgically treated group (75%), compared to the conservative group (39%). They explained that the number of complex fractures was significantly higher in the ORIF group than the conservative group, which resulted in more extensive acetabular defects.

Although Ranawat et al.<sup>1</sup> mentioned that restoration of hip COR was paramount, as it was ultimately associated with the need for revision surgery ( $p < 0.05$ ), they did not find any correlation between the postoperative HHS and restoration of anatomical hip COR. Similarly to their findings, our study did not show any difference in the mean OHS between the restored and non-restored hip COR patients (Table III). Contrary to their results, the non-anatomical restoration of the hip COR did not increase the risk for revision. This could be explained as all our non-anatomical restored COR patients were below 20 mm, while the patients in Ranawat et al.'s<sup>1</sup> study who required revision after non-anatomical restoration of the hip COR had a hip COR greater than 20 mm compared to the unaffected hip. The mean abduction angle in the conservative group was statistically significantly higher than that in the ORIF group ( $p = 0.032$ , paired *t*-test). This could be justified as the superolateral rim defect (Paprosky IIB) was greater in the conservative group of

patients (Table II), and the surgeons wanted to maximize the host bone-cup contact by increasing the abduction angle in the conservative group.

The improvement in cementless fixation THA implant designs and bone impaction grafting techniques have improved the delayed THA outcomes following acetabular fractures.<sup>1,6,12,13</sup> We did not have any case of acetabular or femoral loosening at the time of the last follow-up. Huo et al.<sup>6</sup> reported loosening of the acetabular component in four (19%) patients. The failed cup designs were truncated and without porous coating, while all of the hemispherical porous coating cups did well with stable fixation. They believed that these failures were due to suboptimal cup designs and surgical techniques rather than cementless fixation principles.

Although the major complications (including deep infection, dislocation, and nerve injury) occurred in four (10%) patients in our study which is good compared to other similar studies, such as Bellabarba et al.<sup>12</sup> with a complication rate of 17%, and Ranawat et al.<sup>1</sup> with 28% complication rate, this rate is higher when compared to the reported complications after primary THA following osteoarthritis.<sup>28</sup> In our study, the two revision cases were from the ORIF group and the rate of complications seemed to be higher in the ORIF group (20%) compared to the conservative group (6.6%) ( $p = 0.552$ , Fisher's exact test).

**Table V.** Summary of the published results of total hip arthroplasty following acetabular fractures.

Study	Patient numbers	Year	Methods	Mean follow-up, yrs (range)	Results	Complications
Huo et al <sup>6</sup>	21 (uncemented THA)	1999	N/A	5.4 (4 to 9)	HHS	HO (n = 6) Nerve palsy (n = 1) Dislocation (n = 1) Revision (n = 1)
Bellabarba et al <sup>12</sup>	30 (uncemented THA after acetabular fractures)	2001	15 ORIF, 15 conservative	5.25 (2 to 11.7)	HHS; no difference in THA outcomes between the two groups; more acetabular bone graft needed in the conservative group.	HO (n = 13) Revision (n = 1)
Ranawat et al <sup>1</sup>	32 (uncemented THA)	2009	24 ORIF, 8 conservative	4.7 (2 to 9.7)	HHS; no difference in THA outcomes between the two groups.	HO (n = 14) Revision (n = 6) Deep infection (n = 3) Dislocation (n = 3)
Zhang et al <sup>26</sup>	53 (47 uncemented / 7 cemented THA)	2011	30 ORIF, 23 conservative	5.3 (2.6 to 10.2)	HHS; higher number of patients with bone defects in the ORIF group	Nerve injuries (n = 3) HO (n = 3) Dislocation (n = 1)
Gavaskar et al <sup>9</sup>	47 (uncemented THA)	2017	27 ORIF, 20 conservative	7 (5.5 to 8.5)	OHS; no difference in THA outcomes between the two groups; higher number of patients with bone defects in the conservative group.	HO (n = 17) Nerve palsy (n = 2) Dislocations (n = 2) Revision (n = 2)
Wang et al <sup>24</sup>	33 (uncemented THA)	2018	21 ORIF, 12 conservative	11.5 (8 to 17)	HHS; no difference in THA outcomes between the two groups.	Dislocation (n = 1) HO (n = 10) Revision (n = 3)
Salama et al <sup>25</sup>	21 (uncemented THA)	2018	17 ORIF, 4 conservative	2.2 (2 to 3)	HHS was higher in the ORIF group	HO (n = 2)
This study	40 (uncemented THA)	2021	25 ORIF, 15 conservative	3.9 (1 to 13.7)	OHS; no difference between both groups regarding acetabular defects, bone graft use and THA outcomes.	Infection (n = 3) Dislocation (n = 2) Revision (n = 2) Transient nerve injury (n = 2) Psoas tendinitis (n = 1) Trochanteric bursitis (n = 1)

HHS , Harris Hip Score; HO , heterotopic ossification; OHS , Oxford Hip Score; ORIF , open reduction internal fixation ; THA , total hip arthroplasty.

It is worth noting that infection is a recurrent problem in this group of patients due to multiple prior surgeries and retained hardware. In our study, deep infection complicated the postoperative course of three (7.5%) patients, which is considered higher when compared to the infection rate post-THA following osteoarthritis, with a range from 0.4% to 1.4%.<sup>29</sup> Ranawat et al<sup>1</sup> reported six (18%) patients who suffered a periprosthetic joint infection. All of them had a previous history of infection related to prior ORIF, despite having a negative workup of infection before the arthroplasty procedure. Contrary to Ranawat et al's<sup>1</sup> findings, none of our infected cases had a previous infection profile related to the initial acetabular fracture treatment.

Reviewing the literature, we found that the reported five to 11 -year survival of uncemented acetabular component with revision for any reason ranged between 79% to 98%.<sup>1,9,12,24</sup> Our study demonstrated eight-year probability of survival was 95.2% (95% CI 86.6% to 100%), with revision for any reason (Figure 4). Although we had two revisions for infection, those two hips had well-fixed implants with no radiological signs of loosening, and had a good clinical outcome (OHS of 37 and 46, respectively)

at the final follow-up. We also noted that the initial fracture treatment did not influence the acetabular component survival at a median follow-up of 50 months (IQR 16 to 87). However, this study has some limitations, including being retrospective and with relatively short to medium term follow-up. Also, we could not estimate the probability of survival with sufficient precision after eight years, as the number of patients at risk was < ten.

In conclusion, our study showed that delayed uncemented acetabular component THA in patients with previous failed acetabular fractures treatment resulted in good patient-reported outcomes with excellent survivorship in short to medium term follow-up. In selected cases of acetabular fractures (either non-displaced or with secondary congruency), the initial nonoperative treatment neither resulted in large acetabular defects nor required additional acetabular reconstruction at the time of THA.



### Take home message

- The delayed cementless acetabular total hip arthroplasty (THA) in patients with previous failed acetabular fracture treatments is a successful operation despite the technically demanding nature of the procedure.
- The initial fracture treatment (surgical or conservative) does not influence the outcome of the delayed THA.

### References

- Ranawat A, Zelken J, Helfet D, Buly R.** Total hip arthroplasty for posttraumatic arthritis after acetabular fracture. *J Arthroplasty.* 2009;24(5):759–767.
- Matta JM.** Fractures of the acetabulum: accuracy of reduction and clinical results in patients managed operatively within three weeks after the injury. *J Bone Joint Surg Am.* 1996;78-A(11):1632–1645.
- Judet R, Judet J, Letournel E.** Fractures of the acetabulum: classification and surgical approaches for open reduction. Preliminary report. *J Bone Joint Surg Am.* 1964;46-A(8):1615–1646.
- Burd TA, Lowry KJ, Anglen JO.** domethacin compared with localized irradiation for the prevention of heterotopic ossification following surgical treatment of acetabular fractures. *J Bone Joint Surg Am.* 2001;83-A(12):1783–1788.
- Greiss ME, Thomas RJ, Freeman MAR.** Sequelae of arthrodesis of the hip. *J R Soc Med.* 2018;73(7):497–500.
- Huo MH, Solberg BD, Zatorski LE, Keggi KJ.** Total hip replacements done without cement after acetabular fractures: A 4- to 8-year follow-up study. *J Arthroplasty.* 1999;14(7):827–831.
- Mears DC, Velyvis JH.** Primary total hip arthroplasty after acetabular fracture. *Instr Course Lect.* 2001;50:335–354.
- Sierra RJ, Mabry TM, Sems SA, Berry DJ.** Acetabular fractures: the role of total hip replacement. *Bone Joint J.* 2013;95-B(11 Suppl A):11–16.
- Gavaskar AS, Gopalan H, Karthik B, Srinivasan P, Tummala NC.** Delayed total hip arthroplasty for failed acetabular fractures: the influence of initial fracture management on outcome after arthroplasty. *J Arthroplasty.* 2017;32(3):872–876.
- Scott CEH, MacDonald D, Moran M, White TO, Patton JT, Keating JF.** Cemented total hip arthroplasty following acetabular fracture. *Bone Joint J.* 2017;99-B(10):1399–1408.
- Konan S, Abdel MP, Haddad FS.** Cemented versus uncemented hip implant fixation: Should there be age thresholds? *Bone Joint J.* 2019;8-B(12):604–607.
- Bellabarba C, Berger RA, Bentley CD, et al.** Cementless acetabular reconstruction after acetabular fracture. *J Bone Joint Surg Am.* 2001;83-A(6):868–876.
- Berry DJ, Halasy M.** Uncemented acetabular components for arthritis after acetabular fracture. *Clin Orthop Relat Res.* 2002;405:164–167.
- McLaughlin JR, Lee KR, Johnson MA.** Second-generation uncemented total hip arthroplasty: a minimum 20-year follow-up. *Bone Jt Open.* 2021;2(1):33–39.
- Lewis PM, Khan FJ, Feathers JR, Lewis MH, Morris KH, Waddell JP.** Uncemented total hip arthroplasty can be used safely in the elderly population. *Bone Jt Open.* 2021;2(5):293–300.
- Paprosky WG, Perona PG, Lawrence JM.** Acetabular defect classification and surgical reconstruction in revision arthroplasty. A 6-year follow-up evaluation. *J Arthroplasty.* 1994;9(1):33–44.
- Dawson J, Fitzpatrick R, Carr A, Murray D.** Questionnaire on the perceptions of patients about total hip replacement. *J Bone Joint Surg Br.* 1996;78-B(2):185–190.
- Massin P, Schmidt L, Engh CA.** Evaluation of cementless acetabular component migration. An experimental study. *J Arthroplasty.* 1989;4(3):245–251.
- Martell JM, Pierson RH, Jacobs JJ, Rosenberg AG, Maley M, Galante JO.** Primary total hip reconstruction with a titanium fiber-coated prosthesis inserted without cement. *J Bone Joint Surg Am.* 1993;75-A(4):554–571.
- Bono JV.** Digital templating in total hip arthroplasty. *J Bone Joint Surg Am.* 2004;86-A Suppl 2:118–122.
- Valle AGD, Zoppi A, Peterson MGE, Salvati EA.** Clinical and radiographic results associated with a modern, cementless modular cup design in total hip arthroplasty. *J Bone Joint Surg Am.* 2004;86-A(9):1998–2004.
- Brooker AF, Bowerman JW, Robinson RA, Riley LH Jr.** Ectopic ossification following total hip replacement. Incidence and a method of classification. *J Bone Joint Surg Am.* 1973;55-A(8):1629–1632.
- Makridis KG, Obakponvwe O, Bobak P, Giannoudis PV.** Total hip arthroplasty after acetabular fracture: incidence of complications, reoperation rates and functional outcomes: evidence today. *J Arthroplasty.* 2014;29(10):1983–1990.
- Wang T, Sun JY, Zha JJ, Wang C, Zhao XJ.** Delayed total hip arthroplasty after failed treatment of acetabular fractures: an 8- to 17-year follow-up study. *J Orthop Surg Res.* 2018;13(1):208.
- Salama W, Ditto P, Mousa S, et al.** Cementless total hip arthroplasty in the treatment after acetabular fractures. *Eur J Orthop Surg Traumatol.* 2017;28(1):59–64.
- Zhang L, Zhou YM, Li Y, Xu H, Guo X, Zhou Y.** Total hip arthroplasty for failed treatment of acetabular fractures: a 5-year follow-up study. *J Arthroplasty.* 2011;26(8):1189–1193.
- Harris WH.** Traumatic arthritis of the hip after dislocation and acetabular fractures: treatment by mold arthroplasty. An end-result study using a new method of result evaluation. *J Bone Joint Surg Am.* 1969;51-A(4):737–755.
- Park C, Merchant I.** Complications of Total Hip Replacement. In: Bagaria V, ed. Total Hip Replacement - An Overview. InTech Open, 2018. <https://www.intechopen.com/chapters/61241> (date last accessed 19 November 2021).
- Pulido L, Ghanem E, Joshi A, Purtill JJ, Parvizi J.** Periprosthetic joint infection: the incidence, timing, and predisposing factors. *Clin Orthop Relat Res.* 2008;466(7):1710–1715.

#### Author information:

- A. El-Bakoury, MCh Orth, PhD Orth, FRCS Orth, Consultant Orthopaedic Surgeon
- W. Khedr, MBBCh, MCh Orth, MRCS, Registrar of Orthopaedics and Trauma Derriford Hospital, University Hospitals Plymouth NHS Trust, Plymouth, UK; El-Hadara University Hospital, Alexandria University, Alexandria, Egypt.
- M. Williams, FRCS Orth, Consultant Orthopaedic Surgeon, Derriford Hospital, University Hospitals Plymouth NHS Trust, Plymouth, UK.
- Y. Eid, MCh Orth, DrCh Orth, Professor of Orthopaedics and Trauma
- A. S. Hammad, MBBCh, MCh, MD, Associate Professor of Orthopaedics and Trauma El-Hadara University Hospital, Alexandria University, Alexandria, Egypt.

#### Author contributions:

- A. El-Bakoury: Writing – review & editing, Methodology, Validation, Supervision.
- W. Khedr: Data curation, Investigation, Methodology, Writing – original draft.
- M. Williams: Supervision.
- Y. Eid: Supervision.
- A. S. Hammad: Conceptualization, Writing – review & editing, Investigation, Methodology, Supervision.

#### Funding statement:

- No benefits in any form have been received or will be received from a commercial party related directly or indirectly to the subject of this article.

#### Acknowledgements:

- This study was performed at Derriford Hospital, Plymouth University Hospitals NHS Trust, Plymouth, UK, and El-Hadara University Hospitals, Alexandria University, Alexandria, Egypt.

#### Open access funding

- The authors confirm that the open access fee for this study was self-funded.

© 2021 Author(s) et al. This is an open-access article distributed under the terms of the Creative Commons Attribution Non-Commercial No Derivatives (CC BY-NC-ND 4.0) licence, which permits the copying and redistribution of the work only, and provided the original author and source are credited. See <https://creativecommons.org/licenses/by-nc-nd/4.0/>