

Mesenteric Fibromatosis in Crohn's Disease as a Potential Effect of Adalimumab

Abdelhai Abdelqader, MD¹, Aditya Goud, MD¹, and Albert S. Fleisher, MD²

¹Department of Internal Medicine, MedStar Franklin Square Hospital Center, Baltimore, MD

²Department of Gastroenterology, MedStar Franklin Square Hospital Center, Baltimore, MD

Abstract

A 36-year-old woman with no medical or surgical history was evaluated for weight loss. Abdominal computed tomography (CT) showed signs of Crohn's disease, which was later confirmed endoscopically. She was started on tumor necrosis factor- α (TNF- α) inhibitor therapy. Nine months after treatment, she experienced additional weight loss and a 7 x 8 x 8-cm mass on repeat CT. Biopsy revealed retroperitoneal fibromatosis, so TNF- α was continued. Repeat CT showed an enlarged mass. TNF- α therapy had a suspected role in mass growth, therapy was discontinued, and the mass surgically resected. One year after resection, she has regained weight with no recurrence of the mesenteric fibromatosis.

Introduction

Desmoid tumor (DT), also referred to as aggressive fibromatosis, is a monoclonal proliferation of myofibroblasts that extensively infiltrate adjacent muscle tissue, tendons, and musculoskeletal structures.^{1,2} The pathogenesis of these tumors is not fully understood, but multiple mechanisms have been proposed. The development of DT has been most commonly associated with mutations in the β -catenin gene, given its high prevalence rate in familial adenomatous polyposis (FAP). DT affect about 15% of patients with FAP-associated with Gardner's syndrome, which is caused by adenomatous polyposis coli gene (5q21-22) mutations.^{3,4}

Despite not commonly metastasizing, their morbidity and mortality are often due to a functional disorder of the extensively infiltrated structures. When associated with FAP, DT are usually intra-abdominal, more aggressive, often surgically unresectable, and carry an increased mortality of about 11%.⁵ The primary treatment is surgical resection, though recurrence is possible, especially when associated with FAP in which radiation and, less commonly, chemotherapy are used.^{6,7}

Case Report

A 36-year-old woman with no prior medical or surgical history presented with continued unexplained weight loss and nonspecific abdominal pain and anorexia. Abdominal computed tomography (CT) showed no distinct masses but did show extensive segmental small bowel wall thickening, suggestive of Crohn's disease (CD), which was confirmed by endoscopy. Two weeks after initial upper endoscopy, intrauterine levonorgestrel, a synthetic progestin, was inserted to decrease menorrhagia, and remained implanted throughout her care.

Systemic glucocorticoids were initially started, but were poorly tolerated. She was started on adalimumab and tolerated treatment for 9 months, when she presented with an additional 5-kg weight loss. Repeat CT showed a 7 x 8 x 8-cm enhancing, lobulated mass to left of the abdomen and mesenteric adenopathy. A PET/CT showed a possible

ACG Case Rep J 2016;3(3):184-186. doi:10.14309/crj.2016.44. Published online: April 15, 2016.

Correspondence: Abdelhai Abdelqader, MD, 9000 Franklin Square Drive, Baltimore, MD, 21237 (abdelhai.abdelqader@medstar.net).



Copyright: © 2016 Abdelqader et al. This work is licensed under a Creative Commons Attribution-NonCommercial-NoDerivatives 4.0 International License. To view a copy of this license, visit <http://creativecommons.org/licenses/by-nc-nd/4.0>.

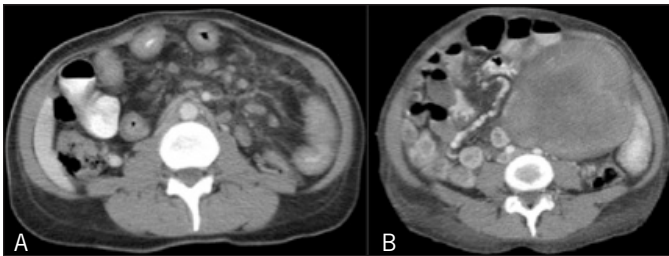


Figure 1. Abdominal CT showing (A) extensive segmental small bowel wall thickening suggestive of Crohn's disease and centrally mesenteric adenopathy, but no distinct mass, and (B) a 12.1 x 10.8 cm enlarging homogeneous, solid mass left of the midline.

necrotic center. A CT-guided biopsy revealed retroperitoneal fibromatosis. Given the benefits of biologic therapy for a patient with symptomatic CD and lack of evidence of desmoid tumors associated with adalimumab, TNF- α inhibitor therapy was continued.

Several months later, surveillance abdominal CT showed the mass had enlarged (Figure 1). She underwent an exploratory laparotomy, during which 107 cm of segmental small bowel was resected with en bloc tumor resection, and a 1° side-to-side functional end-to-end jejunal anastomosis was completed (Figure 2). Histology suggested the tumor originated from the small bowel wall rather than via infiltrative process (Figure 3). Margins were negative, so adjuvant radiotherapy was reserved for potential recurrence. One year after resection, she is off of biologic therapy, has regained her weight, and there is no evidence of mass recurrence. She will be monitored for recurrence with annual CT scans.

Discussion

Development of mesenteric fibromatosis (MF) has been associated with CD in patients with a history of FAP, after any

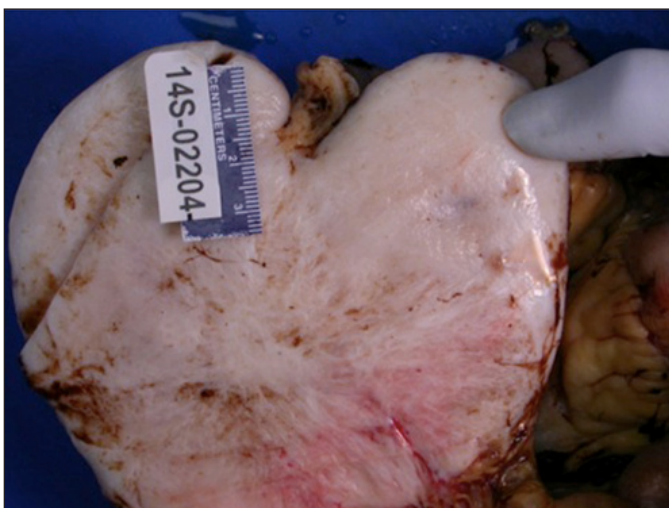


Figure 2. Gross specimen of the 14 x 13 x 11-cm mesenteric desmoid tumor originating from the proximal jejunum, adherent unifocally to the small bowel.

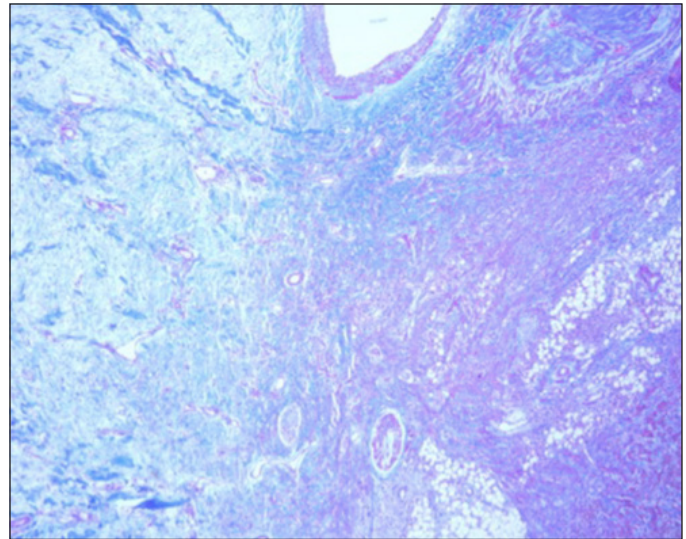


Figure 3. Trichrome stain showing the desmoid tumor (left) and the muscularis layer of the small bowel (right) with a regular, non-disrupted interface.

abdominal surgery,⁸ and in a hyper-estrogenemic state.⁹⁻¹¹ DTs can develop sporadically throughout the body and abdominal wall, and can be site-specific if induced by trauma. It is essential to exclude possible modifiable triggers. She was in a low-estrogen state due to intrauterine (IU) synthetic progestin therapy. Her IU progestin therapy remained before and continued after en-bloc resection more than 1 year. Given the lack of recurrence based on radiography, it is unlikely that progesterone played a role in this case. The relation of progesterone with DT and respective treatment options remains trivial and inconclusive.¹⁰

The literature relating MF to TNF- α therapy is limited. A meta-analysis showed a 0.36% increased incidence of cancer events, about 4.5 times higher than that of the control group within 6 months of treatment with adalimumab.¹² Another meta-analysis of rheumatoid arthritis patients initiated on adalimumab found there was a dose-dependent increased incidence of solid malignancies as early as 6–12 months.¹³ Differences in study populations, study practices, and data reporting create challenges in conclusively determining the relationship of TNF- α therapy and malignancy in CD. Despite the low incidence of new neoplastic events, our case underscores that CD patients taking TNF- α therapy should be closely monitored, even in the absence of risk factors for malignancy.

Disclosures

Author contributions: All authors contributed equally to the creation of this manuscript. A. Abdelqader is the article guarantor.

Financial disclosure: None to report.

Informed consent was obtained for this case report.

Previous Presentation: This case report was presented as a poster at the ACG Annual Meeting; October 16–21, 2015; Honolulu, Hawaii.

Received August 17, 2015; Accepted December 3, 2015

References

1. Devata S, and Chugh R. Desmoid tumors: A comprehensive review of the evolving biology, unpredictable behavior, and myriad of management options. *Hematol Oncol Clin North Am.* 2013;27(5):989–1005.
2. Salas S, Dufresne A, Bui B, et al. Prognostic factors influencing progression-free survival determined from a series of sporadic desmoid tumors: A wait-and-see policy according to tumor presentation. *J Clin Oncol.* 2011;9(26):3553–3558.
3. Nieuwenhuis MH, Lefevre JH, Bülow S, et al. Family history, surgery, and APC mutation are risk factors for desmoid tumors in familial adenomatous polyposis: An international cohort study. *Dis Colon Rectum.* 2011;54(10):1229–34.
4. Lips DJ, Barker N, Clevers H, Hennipman A. The role of APC and beta-catenin in the aetiology of aggressive fibromatosis (desmoid tumors). *Eur J Surg Oncol.* 2009;35(1):3–10.
5. Arvanitis ML, Jagelman DG, Fazio VW, et al. Mortality in patients with familial adenomatous polyposis. *Dis Colon Rectum.* 1990;33(8):639–42.
6. Seegenschmiedt MH, Micke O, Niewald M, et al. DEGRO guidelines for the radiotherapy of non-malignant disorders Part III: Hyperproliferative disorders. *Strahlenther Onkol.* 2015;191(7):541–8.
7. Patel SR, Benjamin RS. Desmoid tumors respond to chemotherapy: Defying the dogma in oncology. *J Clin Oncol.* 2006;24(1):11–2.
8. Lewis JJ, Boland PJ, Leung DH, et al. The enigma of desmoid tumors. *Ann Surg.* 1999;229(6):866–72; discussion 872–3.
9. Johner A, Tiwari P, Zetler P, Wiseman SM. Abdominal wall desmoid tumors associated with pregnancy: Current concepts. *Expert Rev Anticancer Ther.* 2009;9(11):1675–82.
10. Halevy A, Samuk I, Halpern Z, et al. Mifepristone (RU486), a pure anti-progesterone drug, in combination with vinblastine for the treatment of progesterone receptor-positive desmoid tumor. *Tech Coloproctol.* 2010;14(3):265–7.
11. Santos GA, Cunha IW, Rocha RM, et al. Evaluation of estrogen receptor alpha, estrogen receptor beta, progesterone receptor, and cKIT expression in desmoids tumors and their role in determining treatment options. *Biosci Trends.* 2010;4(1):25–30.
12. Bacac M, Migliavacca E, Stehle JC, et al. A gene expression signature that distinguishes desmoid tumours from nodular fasciitis. *J Pathol.* 2006;208(4):543–53.
13. Askling J, Fahrback K, Nordstrom B, et al. Cancer risk with tumor necrosis factor alpha (TNF) inhibitors: Meta-analysis of randomized controlled trials of adalimumab, etanercept, and infliximab using patient level data. *Pharmacoepidemiol Drug Saf.* 2011;20(2):119–30.

Publish your work in ACG Case Reports Journal

ACG Case Reports Journal is a peer-reviewed, open-access publication that provides GI fellows, private practice clinicians, and other members of the health care team an opportunity to share interesting case reports with their peers and with leaders in the field. Visit <http://acgcasereports.gi.org> for submission guidelines. Submit your manuscript online at <http://mc.manuscriptcentral.com/acgcr>.