


Hashimoto's Encephalopathy Revealed by Hypochondriacal Delusion: A Case Report Involving a Male Patient

American Journal of Men's Health
September-October 1–4
© The Author(s) 2020
Article reuse guidelines:
sagepub.com/journals-permissions
DOI: 10.1177/1557988320955080
journals.sagepub.com/home/jmh


Badii Amamou¹, Imen Ben Saida², Amjed Ben Haouala¹,
Ahmed Mhalla¹, Ferid Zaafrane¹, and Lotfi Gaha¹

Abstract

Hashimoto's encephalopathy (HE) is a rare autoimmune disorder. It associates encephalopathy with autoimmune thyroiditis, presenting abnormal elevations of thyroid antibodies. It is more common in females. It can present with various symptoms, including seizures, myoclonus, psychosis, hallucinations, and mood disturbances. Hypochondriacal delusion is an unusual clinical presentation of this disorder. The authors report a case of HE in a male patient whose clinical presentation was dominated by hypochondriacal delusion. The absence of response to antipsychotics, high serum antithyroid peroxidase antibodies of about 199 UI/ml, the normality of magnetic resonance imaging, and improvement with corticosteroids confirmed the diagnosis. This neuroendocrine disorder is often misdiagnosed and it represents a diagnostic challenge for clinicians. It should be considered in patients presenting a refractory or an atypical neuropsychiatric disorder and having a family history of autoimmune disease.

Keywords

Psychiatry, autoimmune diseases, psychotic disorders, thyroiditis

Received April 25, 2020; revised July 30, 2020; accepted August 12, 2020

Hashimoto's encephalopathy (HE) is a rare autoimmune disorder. It associates encephalopathy with autoimmune thyroiditis, presenting a high serum level of antithyroglobulin antibody (TG Ab) and/or antithyroid peroxidase antibody (TPO Ab; Crotty et al., 2019). It was first described by Brain et al. in 1966 (Menon et al., 2017). The pathophysiology of HE is still unknown. However, it is considered as an autoimmune disease due to the autoantibodies against the antigens shared by the thyroid and the brain, resulting in either vasculitis or damage to the brain cells (Crotty et al., 2019). Diagnosis is often made following the presence of a wide variety of symptoms, including neurological, endocrinological, and psychiatric manifestations and after ruling out all possible infectious etiologies (e.g., *Treponema pallidum* [causing syphilis] and *Borrelia burgdorferi* [causing Lyme disease], and viruses such as herpes simplex viruses [HSV-1 and HSV-2] and HIV; Karthik et al., 2017; Zhou et al., 2017). HE is a rare disorder having an estimated prevalence of 2/100,000 (Crotty et al., 2019). An interdisciplinary approach is required for an early diagnosis and an appropriate management of this

disorder (Menon et al., 2017). The authors report the case of a young male patient, hospitalized in the psychiatric department of Fattouma Bourguiba University Hospital (Monastir, Tunisia), whose clinical presentation was dominated by hypochondriacal delusion caused by HE.

Case

A 39-year-old male patient (LG) having no personal psychiatric or somatic history and with a family history of

¹Department of Psychiatry, Fattouma Bourguiba University Hospital, Faculty of Medicine of Monastir, University of Monastir, Monastir, Tunisia

²Medical Intensive Care Unit, Farhat Hached University Hospital, Faculty of Medicine of Sousse, University of Sousse, Sousse, Tunisia

Corresponding Author:

Badii AMAMOU, Department of Psychiatry, Fattouma BOURGUIBA University Hospital of Monastir, Faculty of Medicine of Monastir, University of Monastir, Avenue Farhat HACHED, Monastir 5000, Tunisia.

Emails: amamoubadii@hotmail.fr / badii.amamou@rns.tn



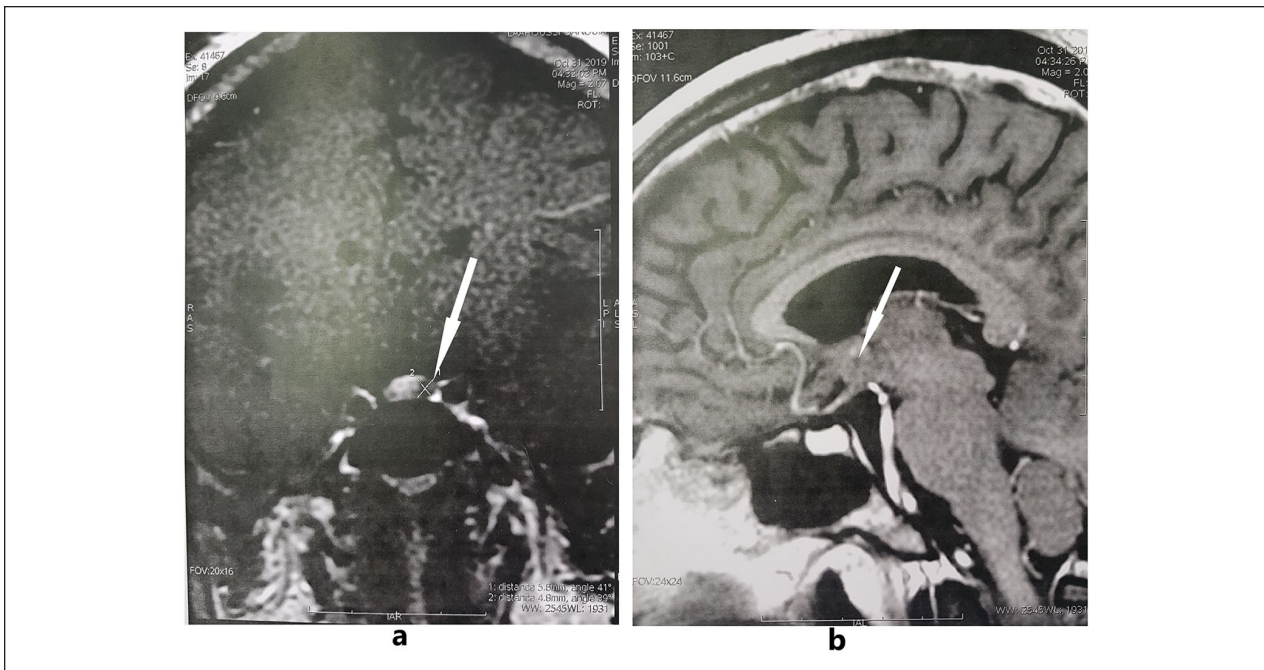


Figure 1. Brain magnetic resonance imaging obtained from (a) coronal plane and (b) sagittal plane illustrating microadenoma on the left side of the anterior pituitary gland (arrows).

dysthyroidism (brother with Basedow's disease and a maternal cousin with hypothyroidism) was hospitalized in the psychiatric department at the request of a third party for the management of suicidal thoughts and a suicide attempt by the ingestion of household bleach. The family interview revealed that the patient had anxiety, insomnia, and bizarre thinking and reported strange physical sensations (presence of "soap" all over his body). The symptoms were first neglected by the patient and his family and they had been evolving for 2 years before the first consultation. During hospitalization, the psychiatric interviews revealed hypochondriacal delusion with depressive symptomatology (motor retardation, slowing down of thought). Physical examination was normal with no palpable goiter. Biological tests showed macrocytic anemia (hemoglobin = 10 g/dl; mean corpuscular volume [MCV] = 121 fl) and vitamin B12 deficiency [vitamin B12 = 50 pg/ml [normal range: 191–663 pg/mL]]. Routine thyroid function tests (e.g., thyroid-stimulating hormone [TSH]) were within the normal range (TSH = 2.8 μ U/ml [normal range: 0.25–4 μ U/ml]). Fundic biopsy revealed fundic atrophy and intestinal metaplasia compatible with Biermer's disease. Injection of vitamin B12 was introduced. Brain computerized tomography scan (CT scan) showed no abnormalities. Psychiatric diagnosis was a major depressive disorder with psychotic features (*Diagnostic and Statistical Manual of Mental Disorders*, 5th edition [DSM-5 code = 296.24; F32.3]). The patient was treated with a combination of paroxetine (20 mg/day) and

risperidone (4 mg/day). A partial improvement was noticed, but delusional thoughts persisted. The patient was discharged and followed up at the outpatient clinic.

One year later, the patient was readmitted to the psychiatric department at the request of a third party (his mother) because he had suicidal thoughts. Psychiatric examination found the same hypochondriacal delusion ("I have soap all over my body") together with anxiety and delusional ideas of incurability. On examination, vital signs were normal. Neurologic examination revealed an extrapyramidal rigidity in the upper limbs. Biological tests showed a normal range of vitamin B12 in the blood (vitamin B12 = 586 pg/ml [normal range: 191–663 pg/ml]) and hyperprolactinemia (prolactin = 1,349 mUI/L [normal range: 90–330 mUI/L]). Thyroid function tests revealed subclinical hypothyroidism with TSH = 8.44 μ U/ml (normal range: 0.25–4 μ U/ml) and thyroxine (T4) = 12.78 pmol/L (normal range: 9–20 pmol/L). Serum TPO Ab was high; it was about 199 UI/ml (normal <50 IU/ml). The patient was receiving levothyroxine 25 mg/day with a euthyroid status. Cervical ultrasound showed hypertrophy of the left thyroid lobe with a heterogeneous and hypoechoic parenchymal echo pattern and a moderate increased vascularity of the thyroid parenchyma on color Doppler. Brain magnetic resonance imaging (MRI) showed "a 6*5 mm micro adenoma on the left side of the anterior pituitary gland without signs of complication" (Figure 1). Electroencephalography revealed a characteristic diffuse slowing, suggestive of encephalopathy.

The presence of refractory hypochondriacal delusion associated with depressive symptoms and high serum anti-TPO antibodies, and the exclusion of other possible causes of encephalopathy, led to the diagnosis of HE. Thus, a corticosteroid treatment (prednisone) was initiated at a dose of 1 mg/kg/day. It was prescribed for 6 months and was gradually reduced, and then it was stopped. A significant improvement in the patient's clinical condition was observed within 1 week. Risperidone was slowly reduced and then stopped. The patient was followed up in both the psychiatric and internal medicine departments. No relapse occurred during 5 months without any medication.

Discussion

HE is a rare condition (Crotty et al., 2019). Its prevalence is estimated to be 2/100,000. The average age of patients for this disease is 55 years. It is more commonly reported in females (sex ratio = 4:1; Zhou et al., 2017). The first case was reported in 1966 and it involved a 58-year-old male patient treated for Hashimoto's thyroiditis and presenting psychiatric manifestations (severe heart attack, altered mental state, and somnolence; Szydelko et al., 2019). Since then, more than 230 cases have been reported (Menon et al., 2017; Szydelko et al., 2019; Zhou et al., 2017).

The clinical features are various, with a wide spectrum ranging from weakness to severe psychiatric disorders (Fiore et al., 2019; Netuluri et al., 2018). To the best of the authors' knowledge, this is the first reported case of HE with hypochondriacal delusions as a sole manifestation.

Three potential organic causes have been suspected to generate the patient's hypochondriacal delusion:

1. Biermer's disease: Several cases with psychiatric signs, namely, somatic delusion, in association with vitamin B12 deficiency have been reported (Rajkumar & Jebaraj, 2008; Tufan et al., 2012). Psychiatric symptoms can occur in the absence of characteristic hematological or neurological symptoms of Biermer's disease (Dogan et al., 2012). The pathophysiology of this relationship remains unknown. This may be due to the excitotoxic effects of glutamate on the brain neurons with destroyed myelin sheaths secondary to vitamin B12 deficiency (Akaike et al., 1993; Silva et al., 2019). Given the lack of improvement of the patient's symptoms after vitamin substitution, this hypothesis was unlikely.
2. Prolactin adenoma: Prolactinoma can induce psychotic features (hallucinations, delusions etc; Ali et al., 2010). This is explained by the dopaminergic hyperactivity caused by prolactin adenoma. In fact, excessive secretion of unregulated prolactin could induce an increase in dopamine by positive feedback (Liu et al., 2019). In the present case, this type

of adenoma was most likely due to the iatrogenic effects of the neuroleptic treatments received by the patient. Indeed, antipsychotics drugs constitute the most involved pharmacological class in the occurrence of hyperprolactinemia. Neuroleptics proceed by blocking D2 dopamine receptors; therefore, they decrease the dopamine. They consequently cause a lifting of inhibition on the secretion of prolactin (Besnard et al., 2014). As the brain CT scan performed during the first hospitalization when the patient had the same symptomatology was normal, this hypothesis was also unlikely.

3. HE: After excluding the other possible etiologies of encephalopathy, the clinical resolution of psychiatric symptoms with prednisone was in favor of this diagnosis. HE is often successfully treated with corticosteroids (Szydelko et al., 2019). About half of the cases respond completely to this therapy (Berger et al., 2010; Netuluri et al., 2018; Zimmermann & Stranzinger, 2012).

The pathogenesis of hypochondriacal delusion remains unclear (Feusner et al., 2008). It involves a complex interplay of damages to several brain networks including the dorsal striatum, the frontal, parietal, and temporal cortices, and the thalamus as areas of structural dysfunctions (Huber et al., 2018). According to the literature (Chang & Chang, 2014; Lee & House, 2017; Mazzù et al., 2012), hallucinations and psychotic symptoms can be seen in HE. The inducing mechanism can be an autoimmune reaction creating antibodies directed against specific brain cell receptors in the above-mentioned territories (Iglesias-Alonso & Iglesias-García, 2017).

Treatment of HE is specific (Szydelko et al., 2019; Zhou et al., 2017). Most patients respond favorably to corticosteroid therapy (Berger et al., 2010; Tang et al., 2012). Prednisone (50 to 150 mg per day or 1 to 2 mg/kg per day) is recommended (Zhou et al., 2017).

Conclusion

HE is a challenging diagnosis for clinicians. It can present with variable clinical manifestations. This case study highlights the importance of considering the diagnosis of HE when patients present some refractory or atypical psychotic signs associated with an autoimmune disease. Although rare, HE is one of the few completely treatable causes of psychosis.

Authors' Note

(1) Substantial contributions to the conception and design, data acquisition, or data analysis and interpretation; (2) drafting the article or revising it critically for intellectual content; (3) approval on the final version to be published. All authors contributed equally to all aspects of the study.

BA (MD, associate professor, amamoubadii@hotmail.fr): **1,2,3**
IBS (MD, assistant professor, imen.bensaida@yahoo.com): **1,2,3**
ABH (MD, amjedpro@gmail.com): **1,2,3**
AM (MD, associate professor, ahmed.mhalla@yahoo.fr): **1,2,3**
FZ (MD, ferid.zaafrane@rns.tn): **1,2,3**
LG (MD, professor, gaha.lotfi@rns.tn): **1,2,3**

Declaration of Conflicting Interests

The author(s) declared no potential conflicts of interest with respect to the research, authorship, and/or publication of this article.



Funding

The author(s) received no financial support for the research, authorship, and/or publication of this article.

Informed Consent

Written informed consent was obtained from the patient for the publication of this case report.

ORCID iDs

Badii AMAMOU  <https://orcid.org/0000-0001-5079-6252>
 Imen BEN SAIDA  <https://orcid.org/0000-0001-8698-9339>

References

- Akaike, A., Tamura, Y., Sato, Y., & Yokota, T. (1993). Protective effects of a vitamin B12 analog, methylcobalamin, against glutamate cytotoxicity in cultured cortical neurons. *European Journal of Pharmacology*, *241*(1), 1–6.
- Ali, S., Miller, K. K., & Freudenreich, O. (2010). Management of psychosis associated with a prolactinoma: Case report and review of the literature. *Psychosomatics*, *51*(5), 370–376.
- Berger, I., Castiel, Y., & Dor, T. (2010). Paediatric Hashimoto encephalopathy, refractory epilepsy and immunoglobulin treatment—unusual case report and review of the literature. *Acta Paediatrica*, *99*(12), 1903–1905.
- Besnard, I., Auclair, V., Callery, G., Gabriel-Bordenave, C., & Roberge, C. (2014). Hyperprolactinémies induites par les antipsychotiques: physiopathologie, clinique et surveillance. *L'Encéphale*, *40*(1), 86–94.
- Chang, J. S., & Chang, T. C. (2014). Hashimoto's encephalopathy: Report of three cases. *Journal of the Formosan Medical Association*, *113*(11), 862–866.
- Crotty, G. F., Doherty, C., Solomon, I. H., Berry, J. D., & Samuels, M. A. (2019). Learning from history: Lord Brain and Hashimoto's encephalopathy. *Practical Neurology*, *19*(4), 316–320.
- Dogan, M., Ariyuca, S., Peker, E., Akbayram, S., Dogan, S. Z., Ozdemir, O., & Cesur, Y. (2012). Psychotic disorder, hypertension and seizures associated with vitamin B12 deficiency: a case report. *Human & Experimental Toxicology*, *31*(4), 410–413.
- Feusner, J. D., Yaryura-Tobias, J., & Saxena, S. (2008). The pathophysiology of body dysmorphic disorder. *Body Image*, *5*(1), 3–12.
- Fiore, A. A., Pfeiffer, W. B., Rizvi, S. A., Cortes, A., Ziembinski, C., Pham, R., Graves, S., & Patel, U. (2019). Hashimoto encephalopathy as a complication of autoimmune thyroiditis. *Medical Principles and Practice*, *28*(1), 91–95.
- Huber, M., Wolf, R. C., Lepping, P., Kirchlner, E., Karner, M., Sambataro, F., Herrnberger, B., Corlett, P. R., & Freudenmann, R. W. (2018). Regional gray matter volume and structural network strength in somatic vs. non-somatic delusional disorders. *Progress in Neuro-Psychopharmacology and Biological Psychiatry*, *82*, 115–122.
- Iglesias-Alonso, A., & Iglesias-García, C. (2017). Case Report: Anti-N-methyl-D-aspartate receptor encephalitis with psychiatric symptoms. *Actas Españolas de Psiquiatría*, *45*(1), 39–46.
- Karthik, M. S., Nandhini, K., Subashini, V., & Balakrishnan, R. (2017). Hashimoto's encephalopathy presenting with unusual behavioural disturbances in an adolescent girl. *Case Reports in Medicine*, 2017. <https://doi.org/10.1155/2017/3494310>
- Lee, Y., & House, E. M. (2017). Treatment of steroid-resistant Hashimoto encephalopathy with misidentification delusions and catatonia. *Psychosomatics*, *3*(58), 322–327.
- Liu, X., Tang, C., Wen, G., Zhong, C., Yang, J., Zhu, J., & Ma, C. (2019). The mechanism and pathways of dopamine and dopamine agonists in prolactinomas. *Frontiers in Endocrinology*, *9*, 768.
- Mazzù, I., Mosti, S., Caltagirone, C., & Carlesimo, G. A. (2012). Hashimoto's encephalopathy: neuropsychological findings. *Neurological Sciences*, *33*(3), 653–656.
- Menon, V., Subramanian, K., & Thamizh, J. S. (2017). Psychiatric presentations heralding Hashimoto's encephalopathy: a systematic review and analysis of cases reported in literature. *Journal of Neurosciences in Rural Practice*, *8*(2), 261.
- Netuluri, N. L., Ramavathu, N. K. N., & Kumar, V. R. (2018). A case report on Hashimoto's encephalopathy. *World Journal of Pharmaceutical Research*, *7*(9), 7.
- Rajkumar, A. P., & Jebaraj, P. (2008). Chronic psychoses associated with vitamin B12 deficiency. *Journal-Association of Physicians of India*, *56*(B), 115.
- Silva, B., Velosa, A., & Barahona-Corrêa, J. B. (2019). Reversible dementia, psychotic symptoms and epilepsy in a patient with vitamin B12 deficiency. *BMJ Case Reports CP*, *12*(5), e229044.
- Szydelko, J., Litwińczuk, M., & Szydelko, M. (2019). Hashimoto's encephalopathy—an up-to-date overview. *Journal of Education, Health and Sport*, *9*(9), 852–873.
- Tang, Y., Xing, Y., Lin, M. T., Zhang, J., & Jia, J. (2012). Hashimoto's encephalopathy cases: Chinese experience. *BMC Neurology*, *12*(1), 60.
- Tufan, A. E., Bilici, R., Usta, G., & Erdoğan, A. (2012). Mood disorder with mixed, psychotic features due to vitamin b12 deficiency in an adolescent: case report. *Child and Adolescent Psychiatry and Mental Health*, *6*(1), 1–5.
- Zhou, J. Y., Xu, B., Lopes, J., Blamoun, J., & Li, L. (2017). Hashimoto encephalopathy: literature review. *Acta Neurologica Scandinavica*, *135*(3), 285–290.
- Zimmermann, P., & Stranzinger, E. (2012). Steroid-responsive encephalopathy associated with Hashimoto thyroiditis. *Pediatric Radiology*, *42*(7), 891–893.