

Torsion of epiploic appendix presenting as acute pancreatitis

Charles Greenbury¹, Peter Thurley² and Altaf Awan¹

¹Department of General Surgery, Royal Derby Hospital, Derby, UK

²Department of Radiology, Royal Derby Hospital, Derby, UK

Corresponding author: Charles Greenbury, Department of General Surgery, Royal Derby Hospital, Derby DE22 3NE, UK.

Email: charles.greenbury@nhs.net

Lesson

Epiploic appendagitis is a little-diagnosed condition capable of mimicking various pathologies. Here, we present a case presenting as acute pancreatitis.

Keywords

epiploic appendagitis, pancreatitis, surgical abdomen

Case

A 64-year-old lady initially presented with a brief history of abdominal pain, nausea and vomiting. Examination revealed a soft abdomen with tenderness in the left upper quadrant and suprapubic areas, and she was found to be afebrile with normal observations. Blood analysis revealed a normal haemoglobin with a mildly raised C-reactive protein of 7 mg/L, a moderate leukocytosis of $13.7 \times 10^9/L$ (mild neutrophilia of $8.08 \times 10^9/L$), and a serum amylase of 180 IU/L – not considered diagnostic for acute pancreatitis. Urinary amylase was raised at 896 IU/L, and serum calcium was normal. She had an ultrasound scan showing no gallstones and no intrahepatic duct dilatation.

She had an emergency contrast computed tomography (CT) which appeared to suggest changes in line with pancreatitis, demonstrating inflammatory changes adjacent to the tail of pancreas and extending along Gerota's fascia and into the conal fascia. The gallbladder, liver, common bile duct and pancreatic duct were normal. Her condition improved with a period of conservative management, and she was discharged home two days post-admission. She returned 10 days later for a repeat ultrasound which was negative for gallstones.¹ She had a negative auto-antibody screen, and serum lipids were within the normal range.

As her clinical condition and biochemical markers were not typical of acute pancreatitis, her CT images were brought to a weekly radiology meeting where they were reviewed by a gastrointestinal radiologist. Here, it was noted that the inflammatory changes

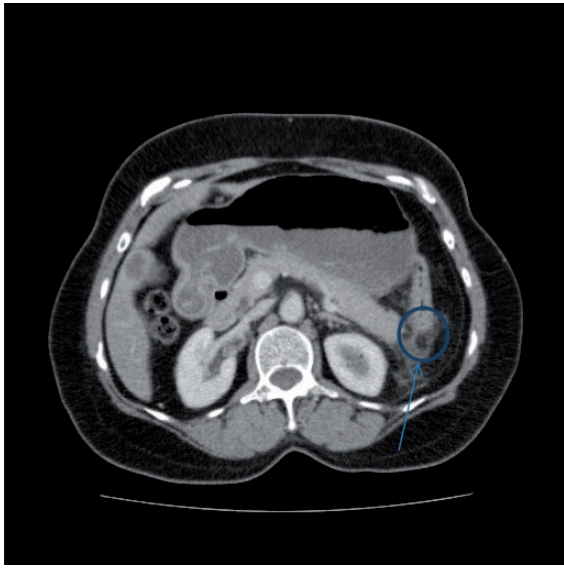
were localised to the point where the splenic flexure of the colon lay adjacent to the tail of the pancreas, and that there was an area of fat density within this suggestive of an inflamed epiploic appendage rather than primary pancreatitis (see Figure 1). There was no CT evidence of primary venous thrombosis of the appendage and neither the patient's history nor her blood tests suggested infection as a cause of the inflammation – at no point did she become septic and her condition resolved with the use of simple analgesia. These findings together with the presentation and history led to a diagnosis of acute epiploic appendagitis (EA) secondary to torsion.

Discussion

EA is an infrequently diagnosed benign inflammatory condition affecting the fatty appendices which run in two rows – anterior and posterior – along the serosal surface of the colon. These appendices are adipose out-pouchings of peritoneum with an, as yet, uncertain function. EA occurs most frequently as a response to torsion, or less commonly due to venous thrombosis, of an epiploic appendix and can present as several other inflammatory causes of the acute abdomen depending upon the location of the culprit. The majority of affected appendices are found attached to the sigmoid colon and caecum, and so most cases are appropriately initially thought to be presentations of acute diverticulitis or appendicitis. Those attached to the sigmoid become inflamed most often and so the most common presentation of EA is as diverticulitis.²

Patients do not commonly present with nausea and vomiting, they are rarely febrile and tend not to show a leukocytosis, but they will often have localised abdominal tenderness on examination.³ In addition, EA affects both sexes equally with no age discrimination, and so there is no typical patient demographic.⁴ The imaging modality of choice is an abdominal CT with intravenous contrast – the

Figure 1. Arrow points to area of inflammation at the splenic flexure of the colon and the tail of pancreas showing an area of central fat density.



infarcted appendix can be seen on ultrasound, although the appearance is more likely to be confused with the inflammation of adjacent organs.⁵ Findings on CT include inflammatory changes surrounding a fatty central core in close proximity to the large bowel (the most common finding), focal colon wall thickening and a central high-density focus within the epiploic appendix – the ‘central dot’ sign, seen in a minority of cases, indicating thrombosis.⁶ Accurate CT diagnosis is vital as many of the causes of the surgical abdomen mimicked by EA – or even the risk of them – necessitate surgical intervention, thus failure to pick up the diagnosis at this stage can lead to an unnecessary operation subjecting the patient to the risks associated with any invasive procedure.

That said, surgical management of EA has been described, advocating excision of the infarcted epiploic appendix.^{4,7} However, EA is a self-limiting disease and as such can be managed conservatively with patient reassurance and analgesia if needed.^{8,9}

Conclusion

EA is an uncommonly diagnosed cause of the acute abdomen and can be managed conservatively. The signs and symptoms are often attractively misleading as are the images on ultrasound and CT leading to diagnoses of other surgical conditions. This is all the more easy to do, as the imaging is often reported as an emergency due to the nature of the differentials. Thus, the clinician must first be aware of this condition and

its ability to convincingly mimic other pathologies. Accurate imaging reporting is vital, as it can obviate the need for surgical intervention and prevent further investigations, leading to a better patient outcome. Here, the role of the radiology meeting was pivotal in arriving at the correct diagnosis. The opinion of experienced radiologists gained outside the emergency situation is key when there is a disparity between the clinical picture and the initial imaging report, or when there is a high index of suspicion of EA.

Declarations

Competing interests: None declared

Funding: Gastrointestinal Funds Surgery, Royal Derby Hospital

Ethical approval: Written informed consent for publication was obtained from the patient.

Guarantor: AA

Contributorship: Writing and editing of this paper has been undertaken by CG and AA, image selection performed by PT.

Acknowledgements: None

Provenance: Not commissioned; peer-reviewed by Chung Lim

References

1. BSG guidelines advocate a thorough search for gallstones in the setting of acute pancreatitis without any other clear cause, these being the most common culprit. Probable cause should be identified in 80% of cases and only 20% should be labelled as idiopathic. UK guidelines for the management of acute pancreatitis. *GUT* 2005; 54: 1–9.
2. Sand M, Gelos M, et al. Epiploic appendagitis – clinical characteristics of an uncommon surgical diagnosis. *BMC Surg* 2007; 7: 11.
3. Choi YU, Choi PW, et al. Clinical characteristics of primary epiploic appendagitis. *J Korean Soc Coloproctol* 2011; 27: 114–121.
4. Iyer G, Seenu V, Bhat A, Sharma MC, Mathew R and Verma GPN. Torsion of appendix epiploica: a rare cause of acute right iliac fossa pain. *Oman Med J* 2010; 25(1). Available at: <http://www.omjournal.org/casereports/pdf/201001/torsionofappendix.pdf> (accessed 23 October 2014).
5. van Breda Vriesman AC and Puylaert JB. Old and new infarction of an epiploic appendage: ultrasound mimicry of appendicitis. *Abdom Imaging* 1999; 24: 129–131.
6. Singh AK, Gervais DA, et al. CT appearance of acute appendagitis. *Am J Roentgenol* 2004; 183: 1303–1307.
7. Pogorelić Z, Stipić R, et al. Torsion of epiploic appendage mimic acute appendicitis. *Coll Antropol* 2011; 35: 1299–1302.
8. Hasbahceci M, Erol C and Seker M. Epiploic appendagitis: is there need for surgery to confirm diagnosis on spite of clinical and radiological findings? *World J Surg* 2012; 36: 441–446.
9. van Breda Vriesman AC. Infarction and idiopathic inflammation of intraperitoneal fat. *Digital academic repository, University of Amsterdam*, p.53. <http://dare.uva.nl/record/202944> (last checked 12 November 2012).