



Cavernous Sinus Epidermoid Cyst Removal through a No-Keyhole Pterional Craniotomy: Operative Video and Technical Nuances

Carlos Candanedo¹ Samuel Moscovici¹ Sergey Spektor¹

¹ Department of Neurosurgery, Hadassah-Hebrew University Medical Center, Jerusalem, Israel

Address for correspondence Carlos Candanedo, MD, Department of Neurosurgery, Hadassah-Hebrew University Medical Center, P.O. Box 12000, Jerusalem 91120, Israel (e-mail: ccandanedomd@hotmail.com).

J Neurol Surg B Skull Base 2022;83(suppl S3):e623–e624.

Abstract

Intracranial epidermoid cysts are considered benign tumors with good general prognosis. However, their radical removal may be associated with certain morbidity, especially when the capsule is attached to neurovascular structures. Epidermoid cysts located in the cavernous sinus are very rare. We present an operative video of a 22-year-old female patient, who suffered a right-sided headache for 5 years. The video demonstrates main steps and surgical nuances of resection of a right interdural cavernous sinus epidermoid cyst, measuring 22 × 19 × 21 mm (4.3 cc) (►Fig. 1A). On initial physical examination, the patient had a right partial third nerve palsy (mild ptosis with minimal diplopia), without any other cranial nerve deficit. A right no-keyhole pterional craniotomy was performed, followed by extradural anterior clinoidectomy and peeling of the outer dural layer of the lateral wall of the cavernous sinus. The dura matter was also detached from the distal carotid dural ring, which was exposed by the clinoidectomy (►Fig. 2A). This maneuver provided excellent exposure of the interdural epidermoid cyst, which severely compressed the oculomotor nerve against the posterior petroclinoid dural fold (►Fig. 2B). Gross total resection of the epidermoid cyst was achieved (►Fig. 1B and C). The patient developed a transient worsening of the third nerve palsy, which recovered completely 3 months after the surgery. Postoperative magnetic resonance imaging revealed no signs of residual tumor.

The link to the video can be found at: <https://youtu.be/pobhYb5ZNig>.

Keywords

- anterior clinoidectomy
- cavernous sinus
- epidermoid cyst
- oculomotor nerve
- operative video
- posterior petroclinoid ligament
- pterional craniotomy



www.thieme.com/skullbasevideos

www.thieme.com/jnlsbvideos

received
March 28, 2020
accepted
November 3, 2020
published online
May 3, 2021

DOI <https://doi.org/10.1055/s-0041-1727118>.
ISSN 2193-6331.

© 2021. The Author(s).

This is an open access article published by Thieme under the terms of the Creative Commons Attribution-NonDerivative-NonCommercial-License, permitting copying and reproduction so long as the original work is given appropriate credit. Contents may not be used for commercial purposes, or adapted, remixed, transformed or built upon. (<https://creativecommons.org/licenses/by-nc-nd/4.0/>)

Georg Thieme Verlag KG, Rüdigerstraße 14, 70469 Stuttgart, Germany

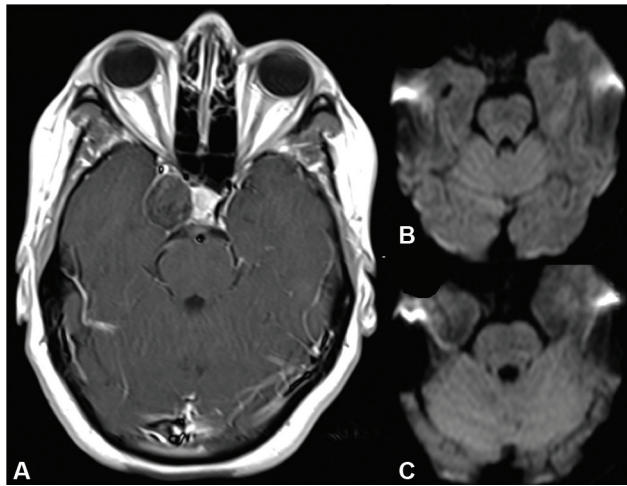


Fig. 1 (A) Preoperative axial T1 gadolinium-enhanced magnetic resonance imaging showing the right cavernous sinus epidermoid cyst. (B, C) Two different axial views on postoperative diffusion weighted imaging without any sign of restricted diffusion, meaning no signs of tumor residual.

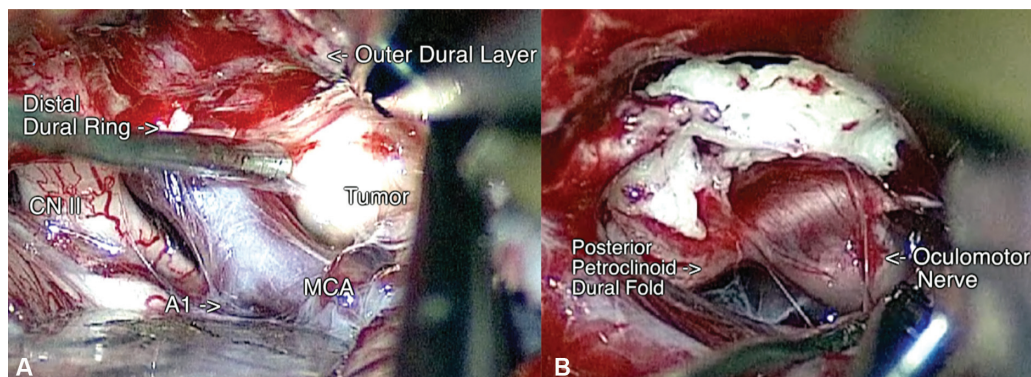


Fig. 2 Intraoperative imaging in the right pterional approach showing (A) neurovascular structures including the optic nerve (CN II), middle cerebral artery, first segment of the anterior cerebral artery (A1) and the distal dural ring exposed thanks to the previously performed extradural anterior clinoidectomy, and (B) severe compression to the oculomotor nerve from the tumor against the posterior petroclinoid dural fold.

Conflict of Interest
None declared.