

The Facial Growth Pattern and the Amount of Palatal Bone Deficiency Relative to Cleft Size Should Be Considered in Treatment Planning

Samuel Berkowitz, DDS,
MS, FICD

Background: The aim of this study is to determine the best surgical/orthodontic treatment plan for the complete bilateral and unilateral cleft lip and palate patient to achieve all treatment goals of facial aesthetics, speech, dental function, and psychosocial development.

Methods: Review of 40 years of serial complete bilateral cleft lip and palate and complete unilateral cleft lip and palate dental casts and photographs from birth to adolescence, with serial cephs starting at 4 years. This was part of a multicenter international 3-dimensional palatal growth study of serial dental casts of patients who developed good speech, occlusion, and facial growth.

Results: Nasoalveolar molding and gingivoperiosteoplasty were introduced without proven longitudinal benefits. The procedure bodily retruded the premaxilla, which “telescoped” backward causing synostosis at the premaxillary vomerine suture. The resulting midfacial recessiveness with an anterior dental crossbite can only be corrected by midfacial protraction or a Le Fort I surgery.

Conclusions: Staged orthodontic/surgical treatment limiting premaxillary retraction forces to lip adhesion or forces that cause only premaxillary ventroflexion produce the best results. The palatal cleft should be closed between 18 and 24 months when the ratio of the cleft to the palatal size medial to the alveolar ridge is at least 10%. The protruding premaxilla should only be ventroflexed but never bodily retruded. The facial growth pattern and degree of palatal bone deficiency are the main items to be considered in treatment planning. (*Plast Reconstr Surg Glob Open* 2016;4:e705; doi: 10.1097/GOX.0000000000000629; Published online 6 May 2016.)

All facial skeletal surgery in growing or non-growing patients can be regarded as an investigation of craniofacial growth, form, and function. Because facial skeletal surgery in growing

children often affects craniofacial growth and function, informed decisions should be made concerning which structures need to be repositioned and reformed. Based on these decisions, a treatment plan is then formulated and a working hypothesis for successful treatment is established. The 3 following points need to be made at this juncture. First, remembering the value of failures as learning opportunities: clinicians cannot afford to forget them; rather, they must take ceph and dental cast records to thoroughly analyze results so that they are not repeated. Second, clinical investigators

From the Department of Orthodontics, University of Illinois College of Dentistry, Coral Gables, Fla.

Received for publication July 5, 2015; accepted January 21, 2016.

Copyright © 2016 The Author. Published by Wolters Kluwer Health, Inc. on behalf of The American Society of Plastic Surgeons. All rights reserved. This is an open-access article distributed under the terms of the Creative Commons Attribution-Non Commercial-No Derivatives License 4.0 (CCBY-NC-ND), where it is permissible to download and share the work provided it is properly cited. The work cannot be changed in any way or used commercially.

DOI: 10.1097/GOX.0000000000000629

Disclosure: *The author has no financial interest to declare in relation to the content of this article. The Article Processing Charge was paid for by the author.*

must be able to explain why some surgical procedures are successful and others fail. Third, clinicians must be able to fit the proper procedure to each individual problem and be willing to work with the consequences of their choices. Faces and clefts of the lip and/or palate within the same cleft type are not alike when considering possible physical growth changes¹(Figs. 1–3).

The collected serial casts and cephalometric radiographs, beginning with those of the unoperated infant and continuing through adolescence, provide a view of the wide spectrum of variations encountered within each cleft type in its untreated state and a record of the changes that occurred thereafter resulting from natural growth or specific therapeutic procedures (Figs. 4 and 5). Clinical experience points out 1 important fundamental fact: all clefts cannot be lumped together as a single phenomenon (Fig. 2). Within each type of cleft patient, there are great individual differences in the palatal geometry and size relative to the extent

of the cleft defect, and these differences are clinically significant. The first line in the first article to emerge from Pruzansky’s² research stated “Not all congenital clefts of the lip and palate are alike.” This statement was to become the leitmotif of his and my subsequent research.^{3–10}

SURGICAL TREATMENT MODIFICATION AND REMODIFICATION BUT WITH NO OUTCOME REPORTS

Millard,¹¹ in his lengthy and excellent book *Cleft Craft*, Volume 3, describes the contributions of many plastic surgeons involved in treating children with clefts. Many of the listed surgeons have used a modification of an earlier failed palatal surgical procedure. In many of the cases, the initial repositioned jaw relationship looked good but soon after additional growth, facial deformities became apparent. For example, the surgeon is confronted with the following options when faced with a protruding premaxilla at birth:

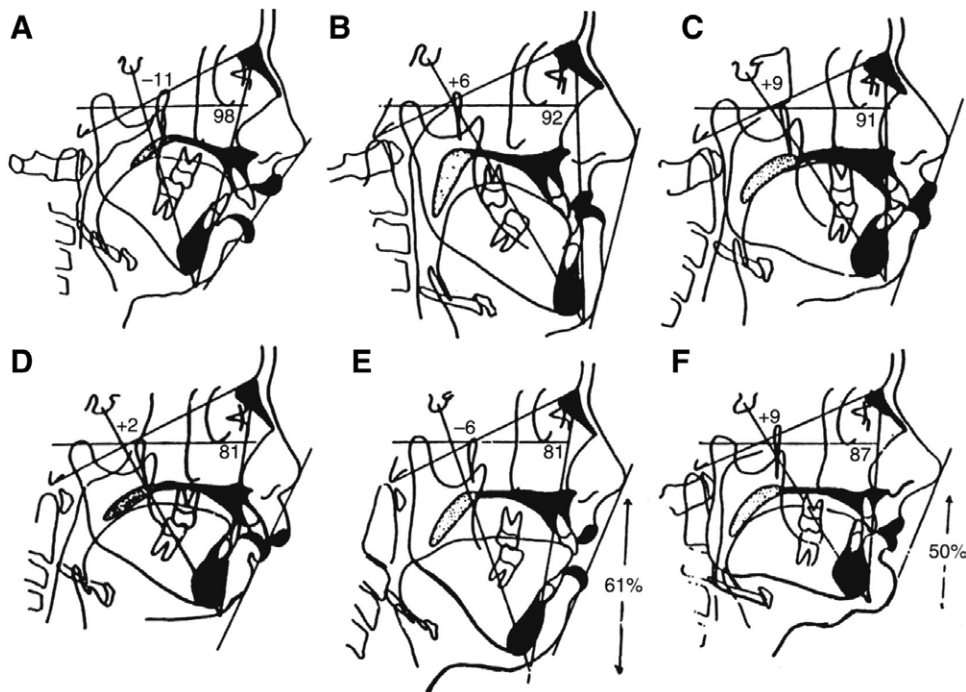


Fig. 1. Not all faces are the same; therefore, treatment must vary according to the facial growth pattern. Various types of facial patterns. A, Retrognathic mandible with steep mandibular plane angle. Severe overbite and overjet. Chronic mouth breather. B, Prognathic mandible with recessive maxilla. C, Brachyfacial type with dental protrusion. D, Slightly retrognathic type with protrusive maxillary denture and severe deep bite. E, Long shallow face with severe tongue problems, extremely wide openbite and an inability to close the lips. F, Extremely closed bite with short denture height. Courtesy of R. Ricketts. *The Biology of Occlusion and the Temporomandibular Joint in Modern Man*, 1957.) Reprinted with permission by Springer Science + Business Media from Berkowitz S, ed. *Cleft Lip and Palate: Diagnosis and Management*. 3rd ed. Heidelberg, Berlin, New York: Springer Verlag; 2013.

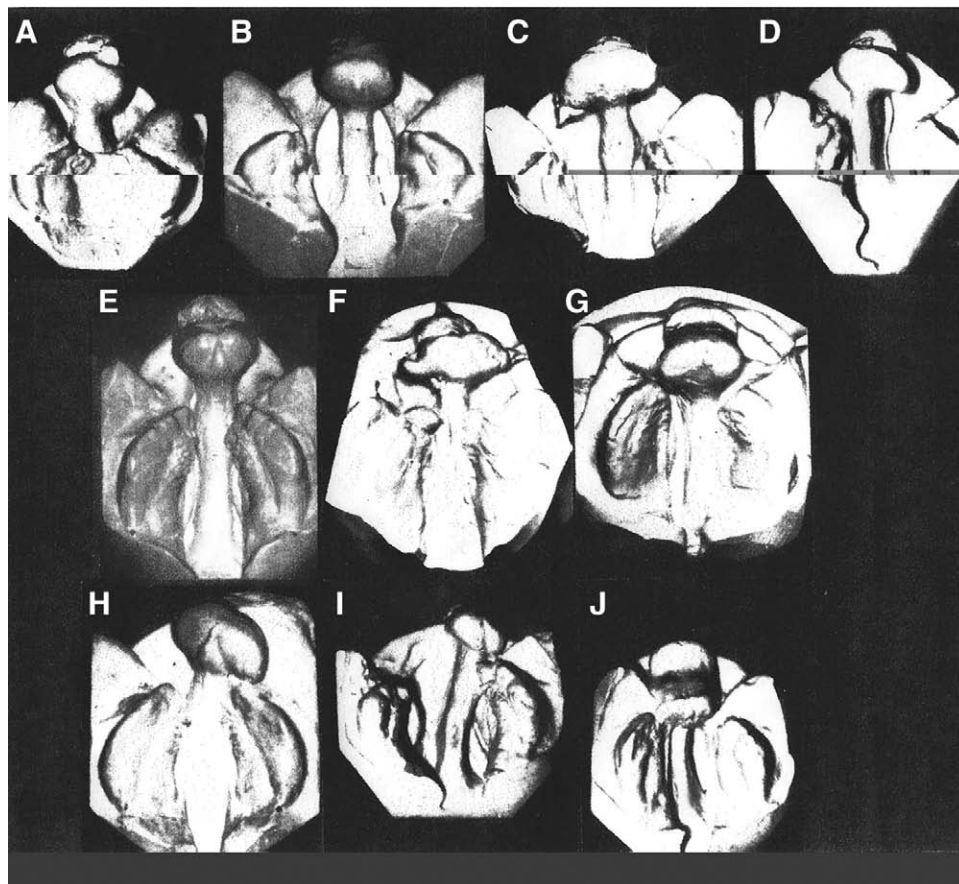


Fig. 2. A–J, Variations in bilateral cleft lip and palate. The size of the premaxilla varies with the number of teeth it contains. Classification is dependent on the completeness of clefting of the lip and alveolus and whether there is a cleft of the hard and soft palate. Yet 1 or both sides of the hard palate may or may not be attached to the vomer. If it is attached to the vomer, it is classified as being incomplete. Even in complete clefts of the lip and alveolus, the extent of premaxillary protrusion will vary. A, Incomplete bilateral cleft lip and palate. Complete cleft lip and palate (left side). Incomplete cleft lip and palate (right side). B, Complete bilateral cleft lip and palate. Complete cleft palate (both sides). C, Incomplete bilateral cleft lip and palate. Incomplete palatal clefts (both sides). D, Complete bilateral cleft of lip and palate. Incomplete right and complete left palate. E, Incomplete bilateral cleft lip and palate. Incomplete left palate and complete right palate. F, Complete bilateral cleft of the lip and palate. Incomplete right and left palatal segments. G, Complete bilateral cleft of the lip and palate. Incomplete left palate and complete right palatal segment. H, Complete bilateral cleft lip and palate. Incomplete left palate and complete right palate. I, Incomplete bilateral cleft lip and alveolus. J, Complete bilateral cleft lip and palate (left side).

1. Uniting the lip over the protruding premaxilla and considering later surgical setback and other surgical options.
2. External elastics attached to a head bonnet or elastic tape to the cheeks to ventroflex the premaxilla (Figs. 4 and 5).
3. Early surgical premaxillary setback.
4. Complete removal (excision of the premaxilla).
5. Early lip surgery or presurgical orthopedic treatment with or without primary bone grafting or periosteoplasty (Figs. 4–6).

6. Lip adhesion followed by definitive lip surgery at a later age (Figs. 4–6).

After a number of poor treatment outcomes, a new surgical modification of a previous modification was made. An example of this is Brophy,¹² who decided that the surgical setback of the protruding premaxilla was not successful and decided to use elastics off a facial mask to set the premaxilla posteriorly. He believed that because all palatal segments were of normal size, early neonatal palatal and alveolar cleft

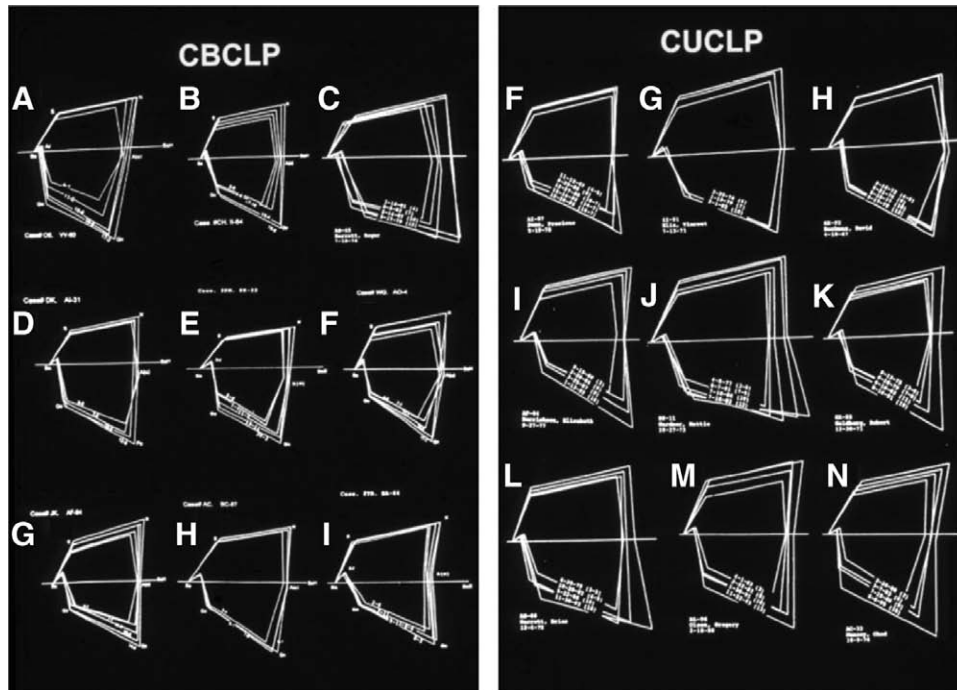


Fig. 3. Variations in facial growth patterns shown in cephalometric tracings when superimposed using basion horizontal analyses by Coben¹⁵ in both CBCLP and complete unilateral cleft lip and palate. The facial growth pattern determines the final facial profile. It shows very clearly that midfacial growth is retarded, while the upper and lower facial growths proceed forward, resulting in a flattening of the facial profile convexity. These changes are greater in the bilateral cases because of the reduced gradual protrusion of the premaxilla. Reprinted with permission from Berkowitz S., www.cleftlipalateaudiovisuallectures.org. © 2013.

closure was beneficial. This procedure soon became popular even though no supporting outcome studies were published. Like many other procedures that were introduced earlier, it was later found to be unsuccessful and discontinued.

From 1960 to 1980, Millard and I successfully used a conservative nonpresurgical palatal orthopedic treatment with a facial strap from a head bonnet to ventroflex the protruding premaxilla (Figs. 4–6). Lip adhesion was performed at 3 months and lip revision, called rotation advancement surgery, at 6 to 8 months. A von Langenbeck with a vomer flap palatal cleft closure procedure was used in most cases. Cleft closure was performed between 18 and 24 months of age and an alveolar bone graft at 7 to 8 years. It was hoped that performing palatal cleft closure at 18 to 24 months, additional palatal bone growth would prevent growth inhibiting scarring without disturbing good speech development (Figs. 5–11).¹³ In the latter 1970s, even after achieving good results at 7 to 8 years, Millard changed his procedure and believed that cleft lip and palate (CLP) staged treatment was not necessary and the same successful results could be attained by 2 years of age and adopted the use of presurgical orthopedics developed and introduced by Latham¹⁴ (Figs. 9 and 10¹⁵).

Latham, working with the anatomist James Scott in England, went to Ontario, Canada, to become an orthodontist and be involved in cleft treatment. He soon developed a presurgical orthopedic appliance held in place by pins into the palate. Its mechanics were very efficient and quickly moved the laterally distorted palatal segments into a normal anatomic relationship. He continued his procedure at Duke University¹⁶ and then went to Miami to work with D. Ralph Millard, Jr. at The University of Miami School of Medicine. Millard started with lip adhesion followed by the Latham appliance and added an alveolar periosteoplasty hoping to replace the need for a secondary alveolar bone graft. Although there were no outcome studies from Canada or Duke, Millard still wished all cleft surgery to be completed earlier than was previously done. The new treatment plan with presurgical orthopedics, periosteoplasty, and lip adhesion (POPLA)¹⁷ was used for 20 years.

Because of my reluctance to use the untested procedure, another orthodontist in Miami performed the manipulation of the palatal segments, whereas I took extensive serial records of casts, cephs, and photographs as well as performing the later orthodontia for 20 years. A comparative study by Berkowitz et al¹⁶

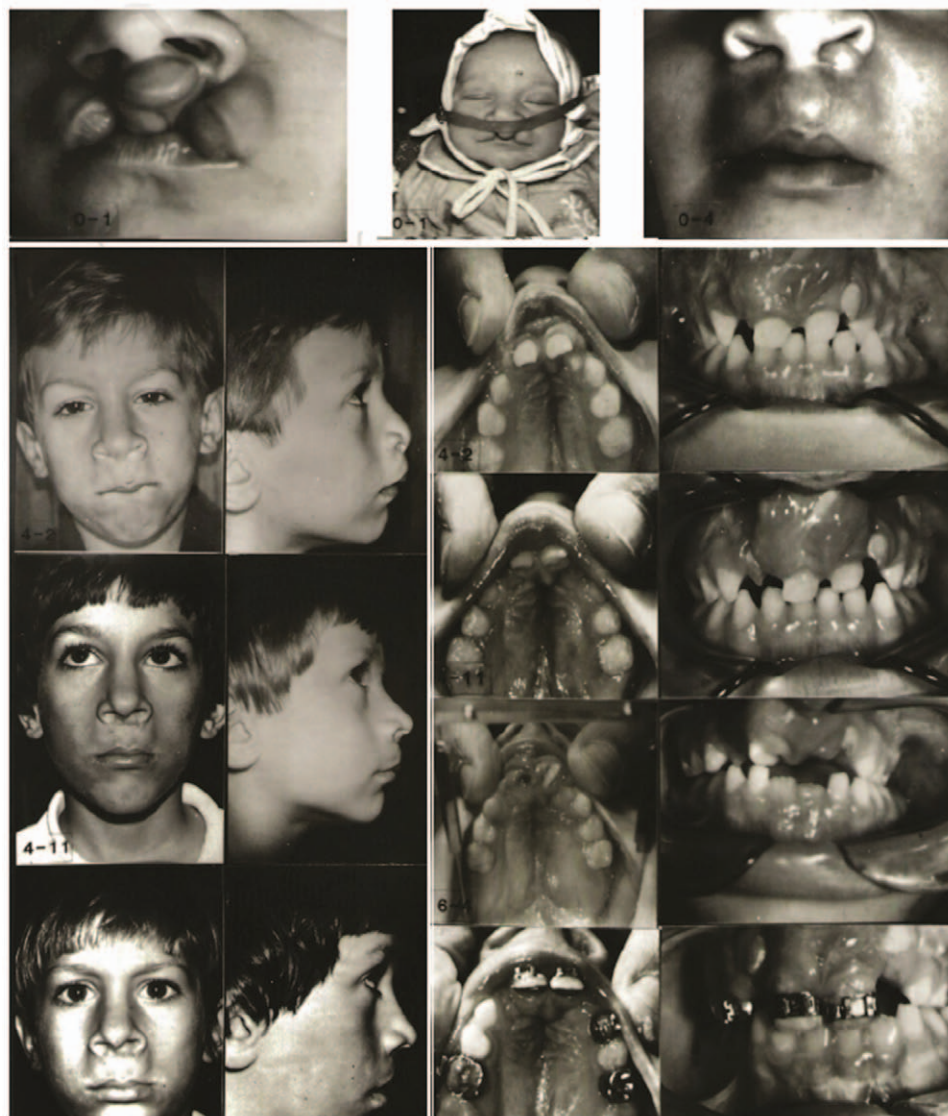


Fig. 4. Conservative CBCLP treatment surgery: Head bonnet with facial strap to ventroflex the protruding premaxilla. Lip adhesion at 3 months followed by a lip revision (rotation advancement) at 6 months. Palatal cleft closure at 18 months using a von Langenbeck with a modified Vomer Flap to maintain the vault space for tongue accommodation. First row, Head bonnet with facial elastic against the protruding premaxilla. Second row: The ventroflexed premaxilla bends at the premaxillary vomerine suture. The palatal segments are in a slight anterior and posterior crossbite. The molded positioned palatal segments cover a small fistula. Cleft closure at 18 months when the palatal segments were already medially positioned by external forces. Third row, Fixed palatal expander—corrected posterior and anterior crossbites exposing the small palatal fistula. In complete unilateral cleft lip and palate, the retracted anterior alveolar portion of the noncleft segment was brought laterally by opening the lateral incisor space. The medial molding of both palatal segments created an anterior crossbite either by an appliance or by lip adhesion. The teeth became more noticeable when the deciduous teeth were lost, and the permanent incisor erupted. The “thin” bony alveolar bridge created by the periosteoplasty permitted the right and the left palatal segments to be moved later, and the lateral incisor space opened. Opening of the lateral incisor space is dependent on the thickness of the bony bridge created by the periosteoplasty. A lower incisor was extracted, and the incisors were retracted to create an incisor overbite and overjet. The correction of the alignment of the upper incisor teeth was not stable even though an upper retainer was worn. Occlusal stability is dependent on the position of the basal bone, distorted nostrils, and lip because of aberrant muscle pull. Lip adhesion surgery reduces nasal and lip distortion. Rotation advancement surgery is used to improve aesthetics. Note that the vertical facial growth pattern creates an elongated anterofacial height. As a result, the midface does not appear to be retrusive. A facial protraction mask was utilized with an intraoral palatal expander to advance the maxillary incisors. Even though there was crowding of the maxillary anterior segments, the vertical facial growth pattern neutralized the obtaining of midfacial recessiveness. Lip/nose revisions were excellent in creating symmetry.

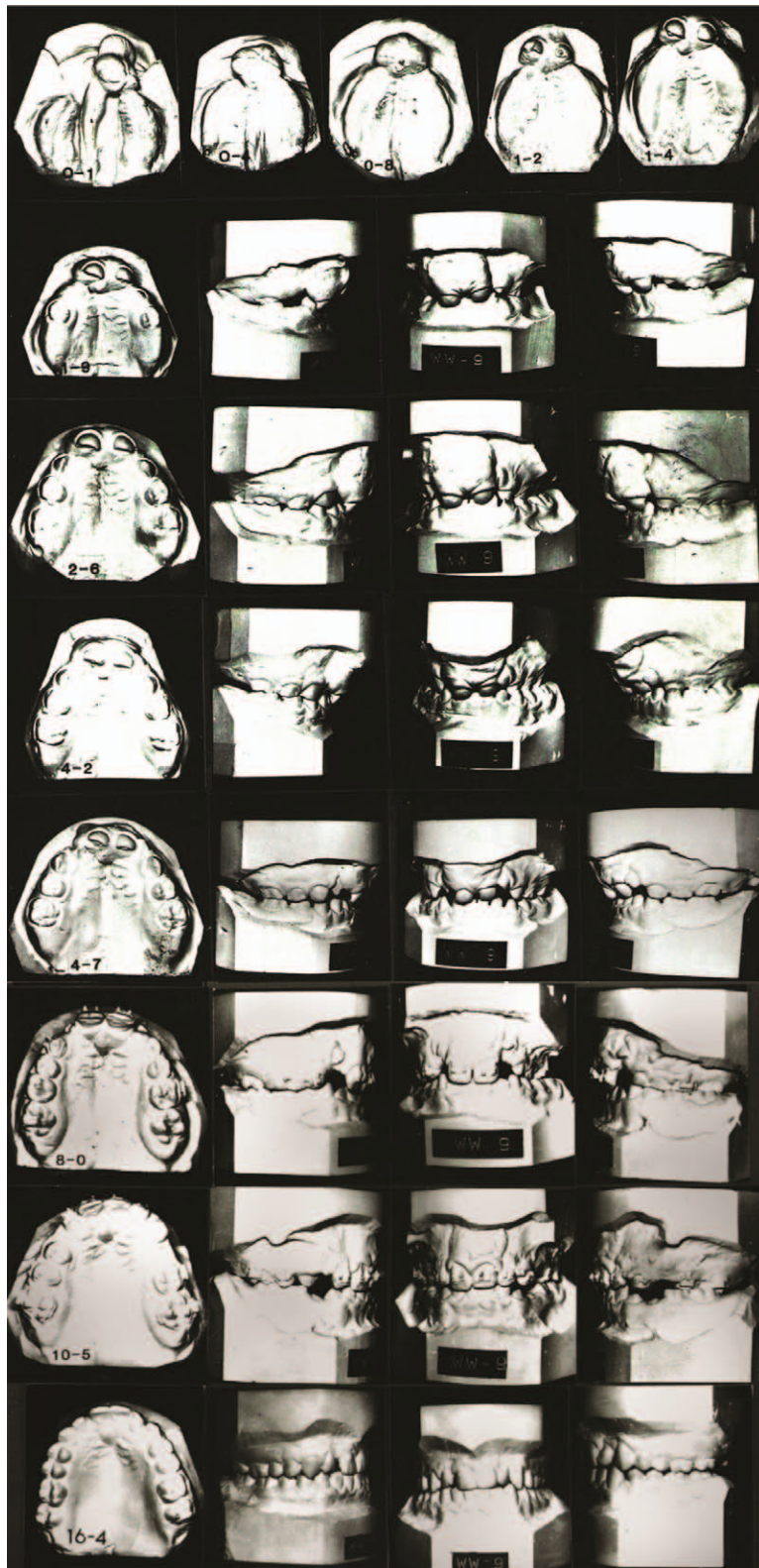
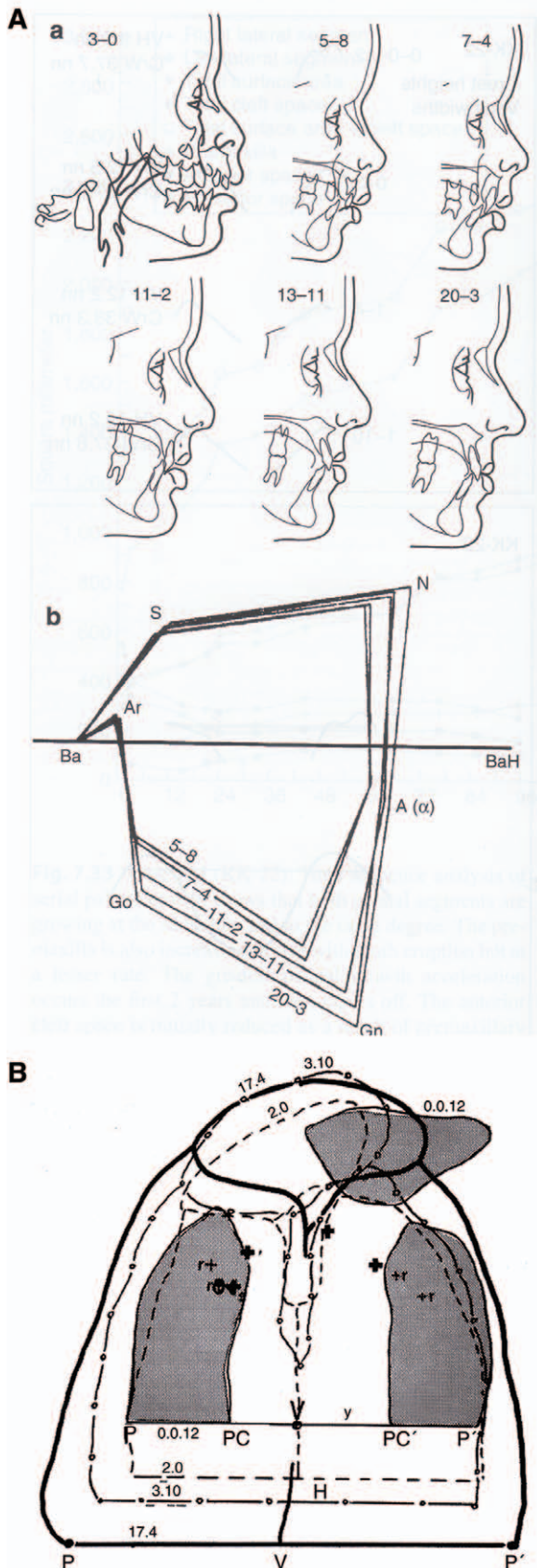


Fig. 5. Serial dental casts: The ventroflexed premaxilla is making contact with both lateral palatal segments resulting in anterior and posterior crossbites. Fixed palatal expander placed at 4 years corrected the crossbites. The premaxillary overjet decreased with growth. This is highlighted in Figure 6. Reprinted with permission by Springer Science + Business Media from Berkowitz S, ed. *Cleft Lip and Palate: Diagnosis and Management*. 3rd ed. Heidelberg, Berlin, New York: Springer Verlag; 2013.



followed to compare it with the conservative protocol previously described. The results clearly showed that POPLA led to severe facial and occlusal distortions. In both complete unilateral cleft lip and palate and complete bilateral cleft lip and palate (CBCLP), the resulting midface recessiveness with an anterior crossbite became more severe over time. Computerized tomography scans and periapical films of CBCLP cases showed a synostotic premaxillary vomerine suture changes with solid bone uniting the retruded premaxilla to the vomer. The closed alveolar cleft space became occupied with the solid bone preventing the opening of the lateral incisor space. This outcome study was the only comparative POPLA longitudinal treatment study published on the use of neonatal premaxillary orthopedics in complete unilateral cleft lip and palate and CBCLP cases. Unfortunately other surgeons, both Mulliken and Cutting, who had also used POPLA for many years, have failed to perform their own facial and occlusal outcome studies as well.

After 15 years, Cutting discontinued POPLA's use and joined with Grayson, an orthodontist at NYU, to introduce a modification of POPLA calling it nasoalveolar molding (NAM) with a removable appliance and a gingivoperiosteoplasty (GPP).^{19,20} The removable palatal appliance carried an extended stent to contact the premaxilla hoping to stimulate columella size. Their palatal appliance was found to accomplish one of its goals of bodily retracting the premaxilla to

Fig. 6. Conservative CBCLP cases. A (a), Cephalometric serial tracings of the skeletal and soft tissue profile show marked reduction of the midfacial protrusion. A (b), Superimposed serial tracings using Coben's Basion Horizontal method show an excellent facial growth pattern, which flattens the skeletal profile. There is very little midfacial forward growth between 11 and 20 years of age. During the same time period, growth at the anterior cranial base and the mandible contributed to flattening of the facial profile. B, Palatal outlines were superimposed using the palatal rugae and vomer imprint for registration. This series shows that the premaxilla's position within the maxillary complex at 17 years of age is similar to that seen at birth. Excellent growth occurs in all dimensions and is similar to the growth pattern seen in noncleft patients. Increased posterior palatal growth is necessary to accommodate the developing molars. Alveolar bone growth with tooth eruption increases midfacial height. The position of the anterior premaxilla relative to the anterior cranial base (nasion) to the anterior position of the mandibular symposium (pogonion) shows the same relative facial position from birth to 17 years of age. This study confirms that midfacial growth is retarded as the face grows at all other points. Reprinted with permission by Springer Science + Business Media from Berkowitz S, ed. *Cleft Lip and Palate: Diagnosis and Management*. 3rd ed. Heidelberg, Berlin, New York: Springer Verlag; 2013.

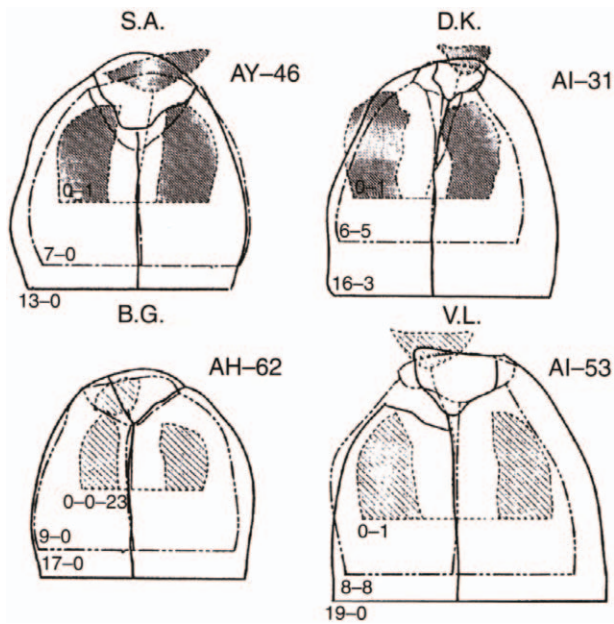


Fig. 7. Use of premaxillary orthopedics to retract the protruding premaxilla in the CBCLP neonatal period versus no presurgical orthopedics. In recent years, serial documentation of the natural evolution of postnatal facial and palatal development of children with complete bilateral and unilateral cleft lip and palate has yielded important objective data that help explain the dynamics of facial skeletal and palatal growth under the influence of various surgical and mechanical procedures. Superimposed palatal cast tracings of the premaxilla and the hard palate of 4 patients were acquired using a 3-dimensional electromechanical digitizer. In each tracing, the alveolar ridge is the lateral border of the measured surface area. The tracings are superimposed horizontally using the vomer impression and the rugae for anterior–posterior registration. In conservatively treated CBCLP cases, it shows very limited anterior alveolar growth changes but extensive posterior palatal growth to accommodate the developing molars. In conservative CBCLP treatment, the premaxilla is initially ventroflexed and ultimately needs to be elevated to open the lateral incisor spaces. The palate’s anterior–posterior position remains in the same position within the face. The premaxilla’s forward growth is retarded by forces generated by the lip repair. Upper and lower facial growth meanwhile reduces the facial convexity. These studies highlight that the protruding premaxilla should not be brought posteriorly at the neonatal stage. To do so will cause the premaxilla to be retropositioned in the mixed dentition creating an anterior crossbite. These cases will need either orthodontic orthopedic and/or surgical treatment to improve aesthetics and the occlusion. Reprinted with permission by Springer Science + Business Media from Berkowitz S, ed. *Cleft Lip and Palate: Diagnosis and Management*. 3rd ed. Heidelberg, Berlin, New York: Springer Verlag; 2013.

create an aesthetic lip and nose during the neonatal period. They only reported aesthetic lip/nose results avoiding any developing occlusal comments but for-

tunately a serial cephaloradiographic study of the NAM + GPP procedure from Taiwan²¹ reported severe midfacial recessiveness. No similar comparative cast, ceph, or photographic study has been published by Cutting and Grayson since its inception. Unfortunately, none of the surgeons who adopted the NAM + GPP treatment procedure reported their occlusal/profile outcome studies either.

WHAT WE LEARNED

My 40-year serial clinical records of more than 400 patients from birth through adolescence of all cleft types with conservative treatment have shown that varied surgical staged treatment procedures were necessary to achieve *good treatment results with all treatment goals to be reached* at least by 7 to 8 years of age.

Current methods of treatment favor *staged treatment*, ie, closing the lip cleft in 2 stages: the first year and the palate at a later age usually between 18 and 24 months⁸ or sometimes earlier, or even later, depending on the 15% to 20% ratio of cleft to palate size. Doing so offers a more encouraging prognosis than that of the surgeons who closed the palatal cleft before 1 year, a practice that has prevailed for the last 50 years. This finding was determined by a Multi-center International serial cast study from the South Florida Cleft Palate Clinic, the University of Illinois College of Dentistry Cleft-Craniofacial Clinic and Northwestern University Craniofacial Clinic in the United States, the University of Goteborg in Sweden, the University of Amsterdam, and the University of Nijmegen in the Netherlands. The age of the patient and the type of surgery to be applied are the 2 variables needed in determining the long-term effect of surgery on facial growth. Quantitative and qualitative characteristics of the cleft defect, plus the general health and genotype (facial growth pattern) of the individual patient, are additional determining factors that affect outcome results. Under certain conditions, surgical repair of the palate is feasible quite early, at about 1 year of age, when the cleft space is very small with good posterior occlusion. In others, as already stated, optimal conditions for repair will not become evident until a later age to reduce cleft size and encourage good palatal growth (Fig. 11).

DISCUSSION

The pattern of progress in dealing with the sequence of scientific advances with the evolution of diagnosis and therapy in cleft lip and palate is excellent. Although the literature on facial clefts can be traced back for several centuries, it is principally concerned with surgical and prosthetic rehabilitation.

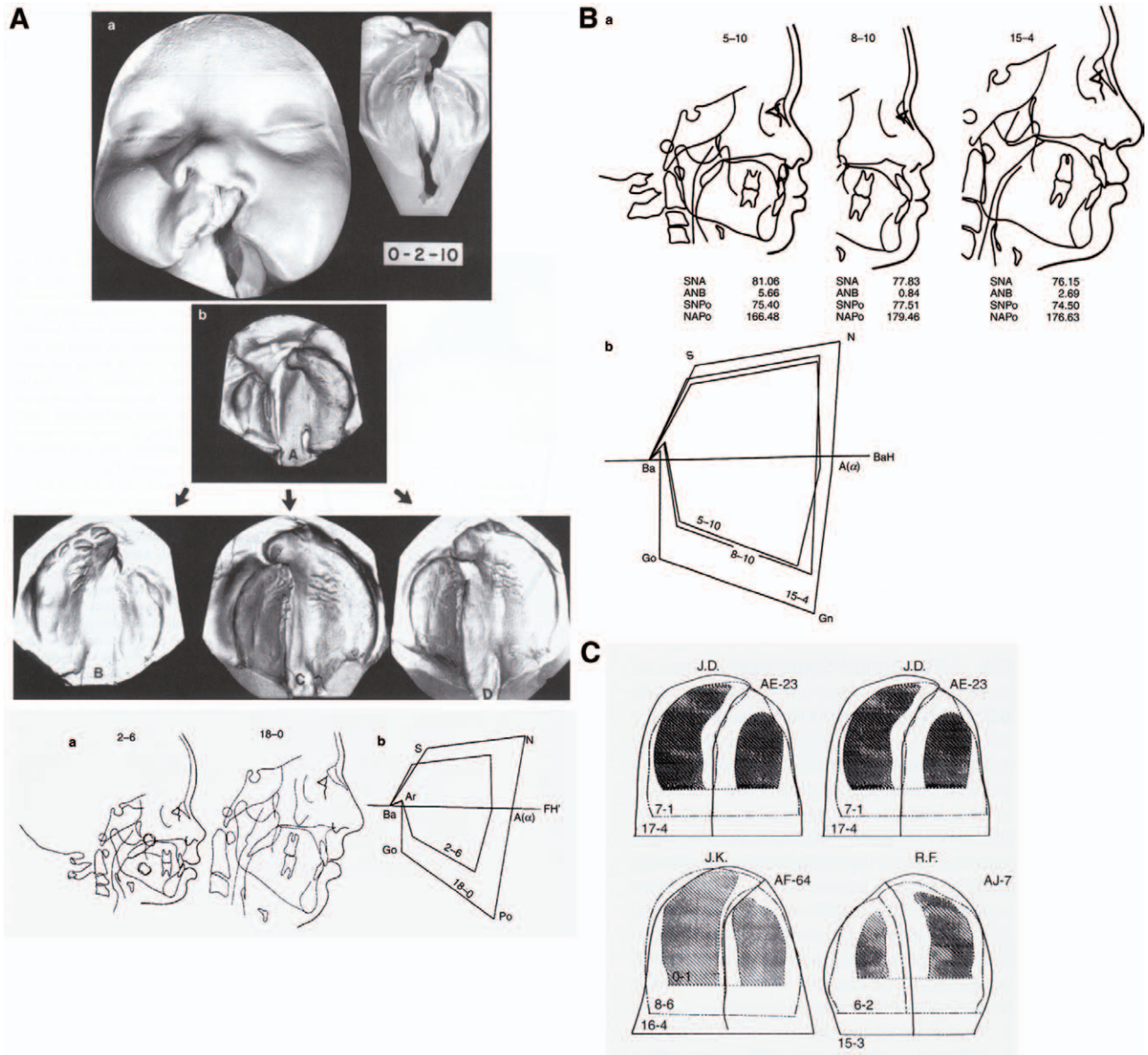


Fig. 8. A, Complete unilateral cleft lip and palate (CUCLP)—early repair. (a) CUCLP. (b) Facial and palate casts. Complete unilateral cleft lip (CUCLP) before (A) and after (B) lip surgery. With the establishment of muscle continuity, the lesser segment moves medially, whereas the premaxillary portion of the larger segment moves medioinferiorly, both acting to reduce the cleft width. Any of the following segmental relationships can result. (B) No contact between segments. The inferior turbinate on the cleft side makes premature contact with the bowed nasal septum. (C) The premaxillary portion of the larger segment overlaps the smaller segment. (D) The segments form a butt joint showing good approximation. Aduss and Pruzansky's serial cast records have shown that there is no correlation between the original cleft width and the resultant arch form. Wider clefts seemed to demonstrate less of a tendency toward collapse than did the narrower clefts.¹³ It must be understood that it is best for the patient that all the goals to be achieved should be postponed until approximately 6 to 7 years of age. To concentrate on having the child's treatment goals completed before 2 years of age, is basically treating the parents and not the child. In time things that look good, that is facial aesthetics, will look satisfactory within the first year, but as growth occurs, it can negatively affect the various structures of the face. So it is best to think in terms of obtaining all the goals of good speech, facial aesthetics, dental occlusion, and just as significantly, the psychosocial development. There should be no priority of one goal versus another. With that in mind one is treating the patient and the parents should be educated to believe that time is an ally and they will be satisfied with the result at a later age. B, Serial growth of the palatal segments in CUCLP. Lateral ceph computer-generated images of serial CUCLP casts superimposed on the rugae and registered on the vomer. The alveolar ridge is the outer limits of the palatal surface area. Surgery: Lip adhesion at approximately 3 months, definitive lip surgery at approximately 6 months, and hard and soft palate closure between 18 and 24 months

Furthermore, such therapy in the recent past was based largely on empiricism and reflected no real understanding of the morphology and pathophysiology. Reconstructive procedures were rarely founded on an intimate knowledge of the embryology and comparative anatomy of the region involved.

These criticisms do not imply that surgery for cleft lip and palate is in a state of chaotic disorganization. As in all branches of surgery, plastic reconstruction of the face has benefited from advances in all of the sciences. Indeed, plastic repair of the face reflects some of our most imaginative and skillful surgery and has produced remarkable cosmetic and functional results. Nevertheless, it is only in recent years that we have noted attempts to classify and delineate clinical entities among the large variety of anomalies that comprise the complex of cleft lip and palate, and only recently we have begun to make full use of the new radiographic techniques, cephs, and dental casts to study palate size, position, and function in the oropharyngeal region. The accumulation of longitudinal data to describe the natural history of facial anomalies during postnatal development and the effects of various modes of therapy is still in progress. Our understanding of the developmental processes in the formation of the face is adequate to explain the variety of prob-

lems encountered and their varying patterns of postnatal development.

As the relationship between speech, facial growth, the timing of palatal surgery, and the use of presurgical orthopedics to bodily retract the premaxilla, the reliance on clinical insight and upon case reports that lack independent documentation of results, still prevails. On the one hand, one must commend the continuing and indeed zealous pursuit of this critical question: Are serial records necessary? On the other hand, we must ask whether there is a way to increase the relative proportion of reliable, valid data and decrease the dependence on undocumented opinion.

A bilateral cleft of the lip and palate can be complete or incomplete on 1 or both sides. Any number of variations can exist in all cleft types, and the size and shape of the premaxilla is dependent on the number of tooth buds and their distribution making it symmetrical or asymmetrical. Because clefts of the lip/alveolus and the hard and soft palate come from different embryological sources, the cleft may involve the lip and alveolus with or without involving the hard and soft palate.

A critical review of the literature on the clinical management of the cleft lip and cleft palate, together with an evaluation of the cumulative palatal and cleft size data from longitudinal palatal growth studies, has led most orthodontists to the following hypothesis: conservative lip and palatal surgery facilitates rather than inhibiting growth in both the maxillofacial skeletal complex and the soft tissue of the labio-facial complex. In the cleft palate cases, operative intervention that involved bone growth potential will guide maxillofacial growth in the individual in such a way that postoperative “catch up” growth of the palate will result in acceptably normal development (Fig. 12).

Most facial and palatal skeletal malformations in cleft patients are the result of surgical procedures that cause some growth retardation or there are osteogenic deficiencies that lead to maxillary hypoplasia. All maxillary discrepancies are 3 dimensional, and bone size relative to cleft size at the time of surgery is crucial.

Differences between surgeons, variance in the performance by the same surgeon from day to day, and during the course of several years, and differences in techniques that are difficult to identify and compare, complicate the analysis. However, the research objectives to test the influence of presurgical orthopedic treatment and the relationship of cleft palate space to surgical outcome can be reached. It is possible to statistically test and covary for effects because of difference between and within surgeons.

Fig. 8. (Continued). using a von Langenbeck procedure with a Vomer Flap. No presurgical orthopedics. Results: The 4 illustrations show the result of molding and growth. Although the least growth occurs anteriorly, most of the growth occurs posteriorly to accommodate the developing deciduous and permanent molars. The palatal mucoperiosteum covering the cleft space led to increase in size. Because the most rapid period of growth occurs between 18 and 24 months when differentiated cells are most active, it is best to postpone palatal surgery to permit normal growth. C, Serial growth of the palatal segments in CUCLP. Computer-generated images if serial CUCLP casts superimposed on the rugae and registered on the vomer AP line. The alveolar ridge is the outer limits of the palatal surface area. Surgery: Lip adhesion at approximately 3 months, definitive lip surgery at approximately 6 months, and hard and soft palate closure 18 to 24 months using a von Langenbeck procedure with a Vomer Flap. No presurgical orthopedics. Results: The 4 illustrations show the result of molding and growth. Although the least growth occurs anteriorly, most of the growth occurs posteriorly to accommodate the developing deciduous and permanent molars. The palatal mucoperiosteum covering the cleft space led to increase in size. Because the most rapid period of growth occurs between 18 and 24 months when differentiated cells are most active, it is best to postpone palatal surgery to permit normal growth. Reprinted with permission by Springer Science + Business Media from Berkowitz S, ed. *Cleft Lip and Palate: Diagnosis and Management*. 3rd ed. Heidelberg, Berlin, New York: Springer Verlag; 2013.

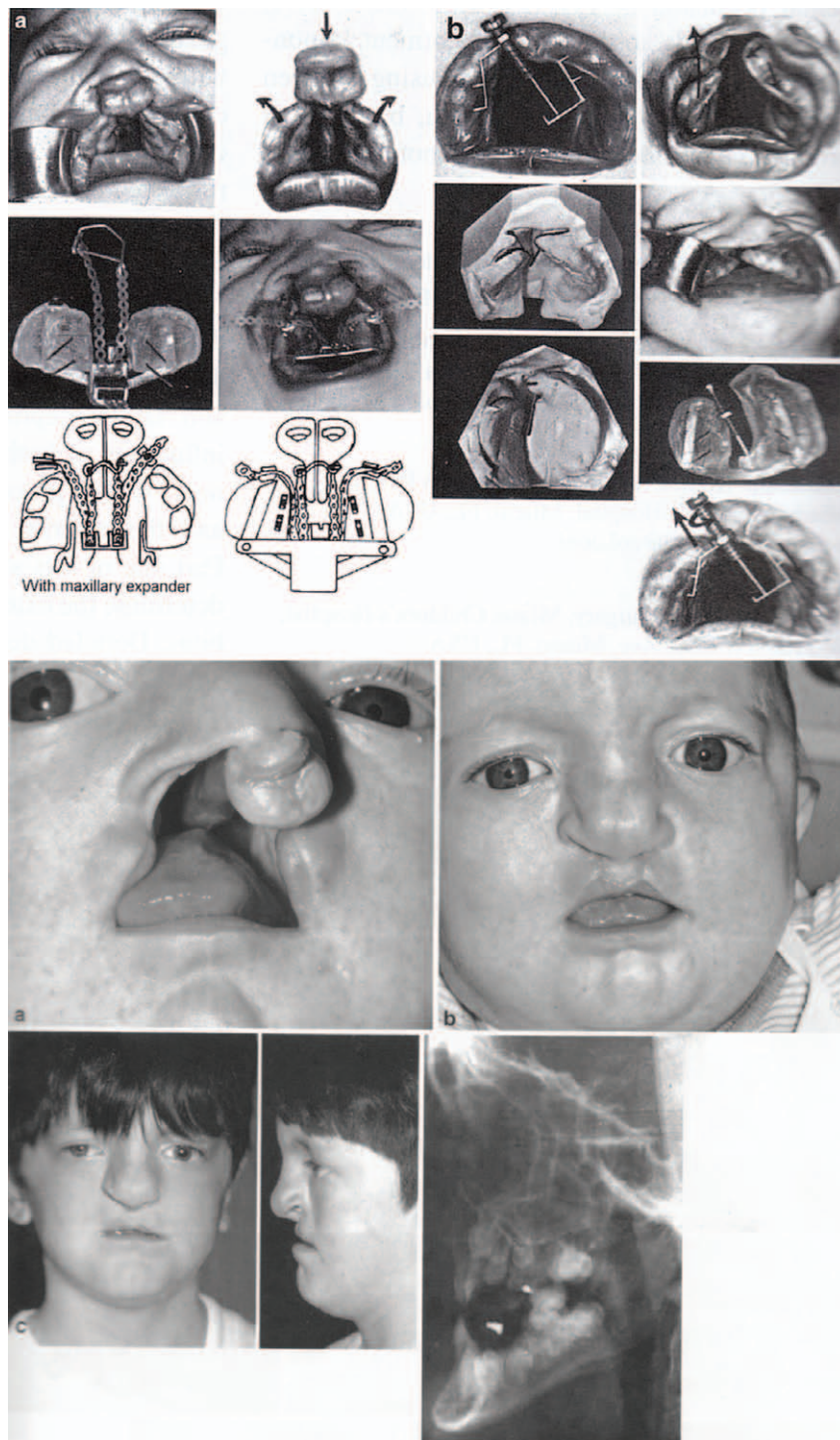


Fig. 9. The Millard-Latham presurgical orthopedics, periosteoplasty then lip adhesion (POPLA). These complete unilateral and bilateral cleft lip and palate appliances are pinned to both the palatal segments soon after birth. In the bilateral case, the palatal segments is first expanded to widen the intracuspisid space, and then the premaxilla is bodily retracted creating ideal arch form and facial aesthetics. The periosteoplasty hopefully will replace the missing lateral incisor bone and stabilize the corrected arch. The bodily retruded premaxilla ultimately results in midfacial recessiveness with an anterior crossbite. The synostosis of the premaxillary vomerine suture is because of the “bodily” retraction, but not from united lip forces. The closure of the lateral incisors space(s) with new bone prevents the premaxilla from being advanced and the crossbite and recessiveness corrected. Additional comment: nasoalveolar molding + gingivoperiosteoplasty usage is similar in its action to the Latham-Millard (POPLA), in that it bodily retrudes the premaxilla. Reprinted with permission by Springer Science + Business Media from Berkowitz S, ed. *Cleft Lip and Palate: Diagnosis and Management*. 3rd ed. Heidelberg, Berlin, New York: Springer Verlag; 2013.

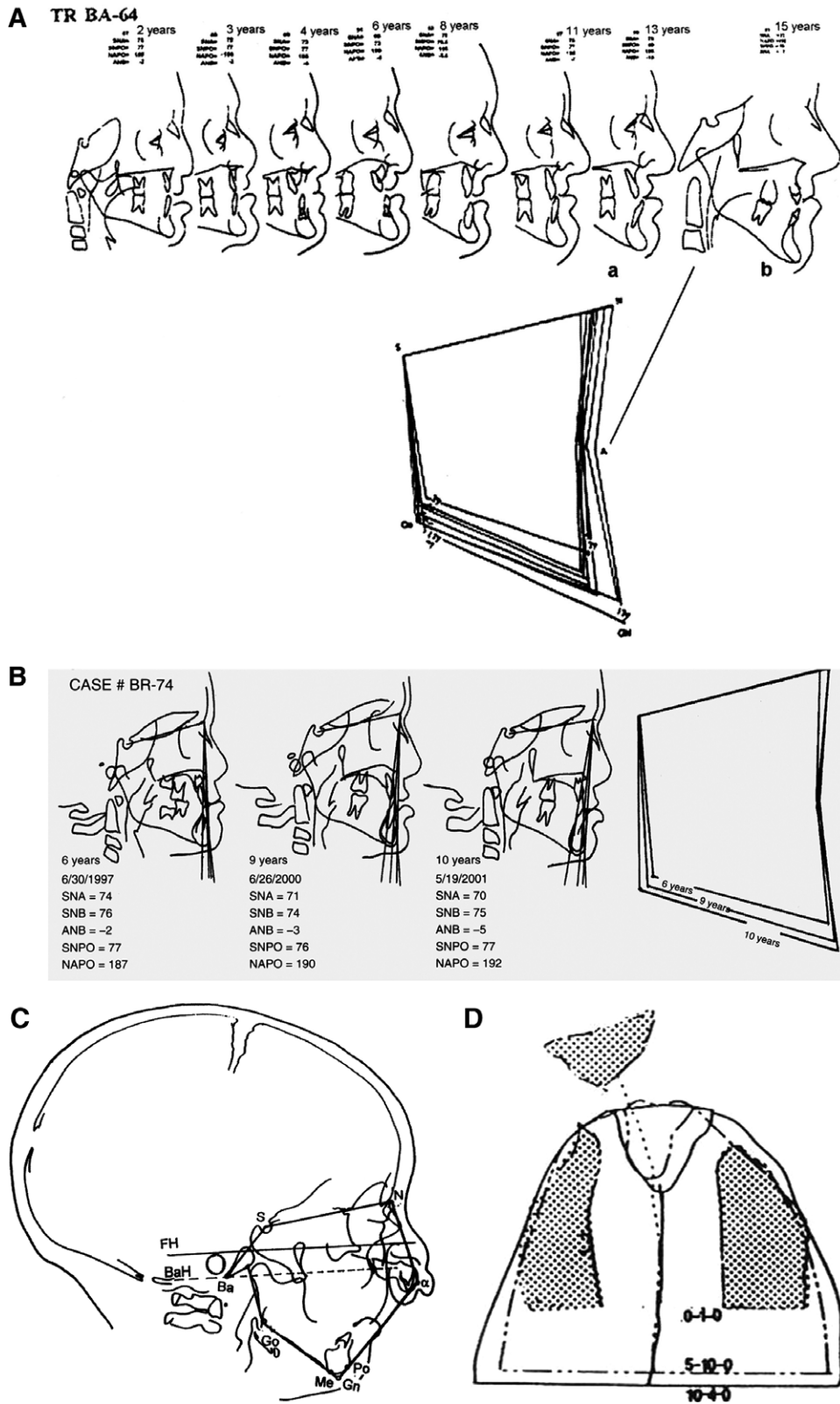


Fig. 10. POPLA. A (a), Serial cephalometric tracings showing the stability of the midfacial recessiveness even after the use of a protraction facial mask. There was no change in the class I buccal occlusion because the orthopedic forces were directed to only advance the retruded premaxilla. A (b) Postmaxillary distraction osteogenesis. Because of severe hypernasality, maxilla advancement was discontinued. B, Complete unilateral cleft lip and palate. Severe anterior crossbite with crowding of the maxillary incisor teeth as

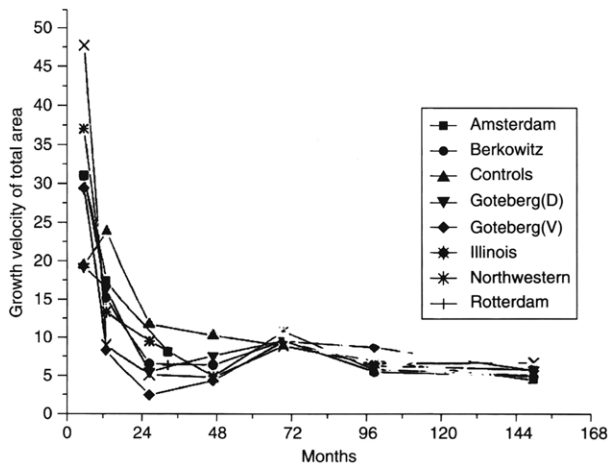


Fig. 11. Velocity curve: 3-dimensional study of palatal closure after various palatal procedures. All surface growth studies were calculated from the alveolar ridge medially extending posteriorly to the end of the hard palate (pterygopalatine fissure) and medially to the cleft space. All cases examined were complete unilateral cleft lip and palate. The delayed treatment series are from Goteberg, Sweden. Berkowitz cases are from Miami (closure between 18 and 24 months). This graph shows a rapid growth between 18 and 24 months no matter what procedure was utilized and then a plateauing of the growth curve. The results show that Berkowitz's cases have grown very well for the entire investigation, but the controls (no cleft) grew to a larger size, so whatever cleft treatment procedure was utilized, it had reduced palatal growth. The vomer flap treatment grew the worst. The study also shows that all velocity curves are very similar: palatal growth is very rapid in the first 18 to 24 months and then slows down before plateauing. They grew the most amount at approximately 50 months. Good growth was maintained even after the adolescent period. Reprinted with permission by Springer Science + Business Media from Berkowitz S, ed. *Cleft Lip and Palate: Diagnosis and Management*. 3rd ed. Heidelberg, Berlin, New York: Springer Verlag; 2013.

RESULTS

The facial and palatal natural history of children with clefts and those with specific syndromes demonstrates that some improve over time, some grow worse, and others remain unchanged despite the surgical effort. Presurgical orthopedics to bodily re-true the premaxilla by “telescoping” it, except for

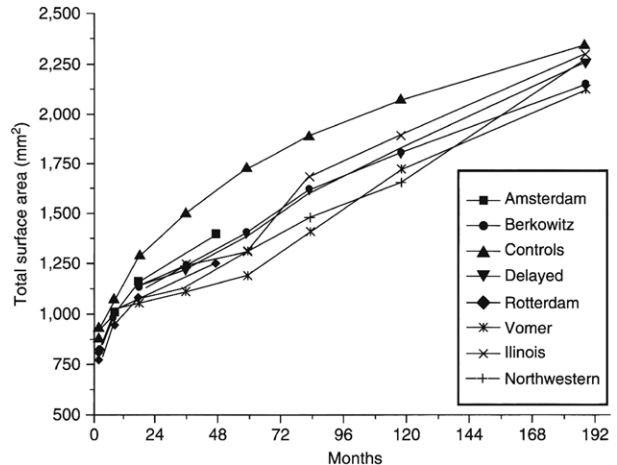


Fig. 12. International study—total surface area measurements from birth to mixed dentition. The control groups are cases from Amsterdam, who have had no surgery or orthopedics. They were part of a clinical trial study to determine the effectiveness of presurgical orthopedics. The other cases represent various good treatment programs. The delayed treatment and vomer flap treatment cases are from Goteberg, Sweden. They clearly show that vomer flap surgery has interfered with the palatal growth. Other cases using various surgical procedures have similar effects on the palatal growth; however, in each case, there was a retardation in growth when compared with the control series. This study highlights that the Berkowitz's (Miami) timing of surgery, between 18 and 24 months, had the least negative effect on growth. Reprinted with permission by Springer Science + Business Media from Berkowitz S, ed. *Cleft Lip and Palate: Diagnosis and Management*. 3rd ed. Heidelberg, Berlin, New York: Springer Verlag; 2013.

the use of a facial elastic to ventroflex the premaxilla to aid the surgeon before uniting the lip, have no long-term utility. Primary bone grafting at the neonatal period also has a deleterious effect on future palatal and facial growth.

CONCLUSIONS

These findings show that within certain defined limits, the success or failure of the surgical procedure depends on the initial state and the variables inherent in the maneuver. Subtle differences among

Fig. 10. (Continued). a result of retracting the premaxillary portion of the larger segment. This created a concave facial profile (cephalometric analysis). C, Basion Horizontal facial polygon (Coben).¹⁵ The method of superimposing tracings graphically reflects the overall concept of facial growth. A plane at the level of the anterior border of foramen magnum (basion) parallel to Frankfort horizontal where basion is the point of differential reference for the analyses of craniofacial growth. D, Because the conservative CBCLP cases show that the stability of the premaxilla's position within the face with growth, it is, therefore, obvious that the retruded premaxilla will not be able to be advanced out of anterior dental crossbite to correct the midfacial recessiveness and the occlusion. This is because of the synostosis of the premaxillary vomerine suture: this change in position is also inhibited by the periosteoplasty connecting all the palatal segments so that the lateral cleft spaces cannot be recovered. The only successful correction treatment is maxillary surgery. Reprinted with permission by Springer Science + Business Media from Berkowitz S, ed. *Cleft Lip and Palate: Diagnosis and Management*. 3rd ed. Heidelberg, Berlin, New York: Springer Verlag; 2013.

patients will be prognostic of the subsequent state and the differences between surgeons. No matter what type of treatment surgeons have favored, they have not been able to explain why their surgical method of choice, when performed on similar clefts at the same age, often yielded different results. Why some cases appear to show “catch-up growth” resulting in good facial and palatal form and functional dental occlusion, whereas others show poor facial and palatal development?

If we assume that qualified surgeons within a given institution or region, practicing a specific series of techniques over a given period of time represent a constant, the differences in success or failure should reside in (1) the initial state (the geometric and size relationship of the palatal segments to the size and shape of the cleft space, which reflects the degree of palatal-skeletal deficiency and palatal segment displacement) and (2) the facial growth pattern. Of course, the sample must separate cases, subjected to or not subjected to presurgical maxillary orthopedics, as well as cases utilizing various cleft closure procedures, because these variables can influence the subsequent state.

Cleft palate surgery is best performed between 18 and 24 months or later if the ratio of the cleft space to the palatal soft tissue medial to the alveolar ridges is greater than 15%.⁷

Samuel Berkowitz, DDS, MS, FICD

University of Illinois School of Dentistry
11035 Paradela Street
Coral Gables, FL 33156
E-mail: sberk3140@aol.com

REFERENCES

- Ricketts, R. The biology of the occlusion and the temporomandibular joint in the modern man. *The Angle Orthodontist*. 1957;27:(1).
- Pruzansky S. Not all dwarfed mandibles are alike. Proceedings of 1st Conference on Clinical Delineation of Birth Defects. Part 2. Malformation syndromes. In: Bergsma D, ed. *Birth Defects. Original Article Series*. Vol 2. New York, NY: The National Foundation; 1969:120–129
- Berkowitz S, Krischer J, Pruzansky S. Quantitative analysis of cleft palate casts. A geometric study. *Cleft Palate J*. 1974;11:134–161.
- Berkowitz S. A comparison of treatment results in complete bilateral cleft lip and palate using a conservative approach versus Millard-Latham PSOT procedure. In: Sadowsky PL, ed. *Cleft Lip and Palate*. Philadelphia: Saunders Co.; 1996:169–184.
- Millard DR, Berkowitz S, Latham RA, Wolfe SA. A discussion of presurgical orthodontics in patients with clefts. *Cleft Pal J*. 1998;25:4.
- Lestrel PE, Berkowitz S, Takahashi O. Shape changes in the cleft palate maxilla: a longitudinal study. *Cleft Palate Craniofac J*. 1999;76:292–230
- Berkowitz S, Mejia M, Bystrick A. A comparison of the effects of the Latham-Millard procedure with those of a conservative treatment approach for dental occlusion and facial aesthetics in unilateral and bilateral complete cleft lip and palate; part I. Dental occlusion. *Plast Reconstr Surg*. 2004;113:1–18.
- Berkowitz S, Duncan R, Evans C, et al. Timing of cleft palate closure should be based on the ratio of the area of the cleft to that of the palatal segments and not on age alone. *Plast Reconstr Surg*. 2005;115:1483–1499.
- Berkowitz S. Ch. 17: Timing of cleft palate closure should be based on the ratio of the area of the cleft to that of the palatal segments and not on age alone. In: Berkowitz S, ed. *Cleft Lip and Palate: Diagnosis and Management*. 2nd ed. Heidelberg-Berlin, Springer Verlag; 2006.
- Berkowitz S, ed. *Cleft Lip and Palate: Diagnosis and Management*. 3rd ed. Heidelberg, Berlin, New York: Springer Verlag; 2013.
- Millard DR, Jr. *The Evolution of Its Surgery: Alveolar and Palatal Deformities*. *Cleft Craft*. Vol. III. Boston: Little Brown; 1980.
- Brophy TW. *Cleft Lip and Palate*. Philadelphia, PA: Blakiston's; 1923
- Aduss H, Pruzansky S. The nasal cavity in complete unilateral cleft lip and palate. *Arch Otolaryngol*. 1967;85:53–61.
- Latham RA. Orthopedic advancement of the cleft maxillary segment: a preliminary report. *Cleft Palate J*. 1980;17:227–233.
- Georgiade NG, Latham RA. Maxillary arch alignment in the bilateral cleft lip and palate infant, using pinned co-axial screw appliance. *Plast Reconstr Surg*. 1975;56:52–60.
- Millard DR Jr, Latham RA. Improved primary surgical and dental treatment of clefts. *Plast Reconstr Surg*. 1990;86:856–871.
- Berkowitz S, Mejia M, Bystrick A. A comparison of the effects of the Latham-Millard procedure with those of a conservative treatment approach for dental occlusion and facial aesthetics in unilateral and bilateral complete cleft lip and palate. Part 1. *Plast Reconstr Surg*. 2004;115:1483–1499.
- Grayson B, Cutting C. Presurgical nasoalveolar orthopedic molding in primary correction of the nose, lip and alveolus of infants born with unilateral and bilateral clefts. *Cleft Pal Craniofac J*. 2000;37:528–532
- Grayson BH, Cutting CB. Presurgical nasoalveolar orthopedic molding in primary correction of the nose, lip, and alveolus of infants born with unilateral and bilateral clefts. *Cleft Palate Craniofac J*. 2001;38:193–198.
- Hsin-Yi Hsieh C, Wen-Ching Ko E, Kuo-Ting Chin P, Chiung-Shinget H. The effect of gingivoperiosteoplasty on facial growth in patients with complete unilateral cleft lip and palate. *Cleft Pal Craniofac J*. 2010;47:439–446