





Retinal Vein Occlusion Amongst People Vaccinated by mRNA- and Viral Vector- COVID-19 Vaccines: A Systematic Review

Maria Jessica Rachman ^{1,2}, Viskasari P Kalanjati ³, Rimbun Rimbun ³, Fira Khadijah ¹

¹Master Program of Basic Medical Science, Faculty of Medicine, Universitas Airlangga, Surabaya, East Java, Indonesia; ²Faculty of Medicine, Universitas Ciputra, Surabaya, East Java, Indonesia; ³Department of Anatomy, Histology, and Pharmacology, Faculty of Medicine, Universitas Airlangga, Surabaya, East Java, Indonesia

Correspondence: Viskasari P Kalanjati, Department of Anatomy, Histology, and Pharmacology, Faculty of Medicine, Universitas Airlangga, Jl. Mayjen Prof. Dr. Moestopo No. 47, Surabaya, East Java, Indonesia, Tel +62 5020251, Email viskasari-p-k@fk.unair.ac.id

Abstract: Vaccines are highly effective in lowering the mortality due to COVID-19. Although several suspected adverse events or side effects after vaccination including retinal vein occlusion (RVO) have been reported. We conducted a systematic review using PRISMA methods to analyze the occurrence of RVO among people vaccinated by COVID-19 mRNA- vs viral vector- vaccines on 4 databases from 1-1-2021 to 31-12-2022 using specified MeSH terms. All included studies were assessed using JBI critical appraisal tools for eligibility. The final included studies are 31 studies (n=78 cases from 75 patients; 3 of these patients suffered twice). The median age of the patients was 61 years (28 to 96 years old) and most of them were female (52.00%). Thirty-nine patients received the mRNA vaccine (52.00%), while 36 patients received the viral vector vaccine (48.00%) before the event. The RVO diagnoses are based on physical examination confirmed by Fluorescein Angiography (FA), and/or Optical Coherence Tomography (OCT). The median time interval between vaccination and RVO was 6 days in the mRNA vaccine group and 4 days in the viral vector vaccine group. Central retinal vein occlusion (CRVO) and Branch Retinal Vein Occlusion (BRVO) were tied as the most common diagnosis in the mRNA vaccine group (20.51% and 20.51%), whilst in the viral vector vaccine group CRVO was the most common diagnosis (17.94%). Most of these cases had good outcomes with improved visual impairment in one or both eyes. From this review, we could not ascertain that the RVO occurs due to the type of COVID-19 vaccines because of the detailed data on the dosage and the history of illness of each patient. However, the awareness that the RVO could develop after COVID-19 vaccination must be taken into consideration, even though it is rare.

Keywords: COVID-19, retinal vein occlusion, vaccines, adult visual impairment

Introduction

World Health Organization (WHO) pronounced Coronavirus Disease (COVID-19) a global pandemic in 2020 after incidences of pneumonia were reported in Wuhan, China, in 2019 and spread to numerous other countries.¹⁻³ It was later determined that the 2019-new coronavirus (2019-nCov), a novel enveloped beta-coronavirus with a single-stranded positive-sense RNA genome, was the cause of the pandemic.^{4,5} The virus is also known as the severe acute respiratory syndrome coronavirus 2 (SARS-CoV-2) since the illness resembles viral cases of pneumonia like SARS and MERS.⁴ Some cases are mild and usually self-limiting, and some cases are asymptomatic.^{4,6,7} However, many patients with comorbidities suffer from more severe symptoms, such as acute respiratory distress syndrome (ARDS), septic shock, or even multiple-organ failure.^{4,7,8}

SARS-CoV-2 is very contagious. It is transmissible by inhalation or contact with droplets that contain the virus. Even asymptomatic COVID-19 patients can spread the disease unknowingly.⁹ Because of the emergence of the pandemic, countries have set strategies to overcome it, such as social and physical distancing, travel restriction, self-quarantine, lockdown, personal hygiene, and sanitation, boosting immunity, case detection, and contact tracing, and vaccine

development.^{3,10} The vaccines were developed, and as of July 2, 2020, there are 158 COVID-19 vaccine candidates, out of which 135 are in the certain phase of their development, while there are only 11 COVID-19 Vaccines included in WHO Emergency Use Listing (EUL).^{11–13} The very first vaccine to be recommended to EUL is Comirnaty, on December 31, 2020.¹¹ The vaccines can be categorized as protein subunit vaccines, such as Novavax (Nuvaxovid or Covovax); viral vector vaccines, such as Oxford/AstraZeneca (AZD1222, ChAdOx1 nCoV-19, Vaxzevria or Covishield), Janssen (Ad26.COV2.S or Jcovden), or Gamaleya (Sputnik V, or Gam-COVID-vac); mRNA vaccines, such as Moderna (Spikevax or mRNA-1273) or Pfizer/BioNTech (Comirnaty or BNT162b2); and inactivated vaccines, such as Sinovac, Sinopharm, or Bharat Biotech; and each has their strengths and weaknesses.^{12,13}

Even though vaccines are highly effective in preventing COVID-19 and also lowering mortality due to COVID-19,¹⁴ some researchers have found adverse events and side effects after receiving vaccines, specifically in the eyes. A narrative review discovered some studies that reported eye abnormalities linked to the COVID-19 vaccination, including facial nerve paralysis, abducens nerve paralysis, acute macular neuroretinopathy, central serous chorioretinopathy, ophthalmic vein thrombosis, corneal transplant rejection, newly developed uveitis, and retinal artery or vein occlusion.^{15,16}

Retinal vein occlusion (RVO) is a retinal vascular disease that can be classified as central retinal vein occlusion (CRVO), branch retinal vein occlusion (BRVO), and hemispheric retinal vein occlusion (HRVO). Generally, the manifestation of RVO is painless visual loss with any combination of a tortuous retinal vein, retinal hemorrhage (blot and flame-shaped), cotton wool spots, optic disc swelling, and/or macular edema. Studies suggest that RVO usually follows a thrombotic event and is likely to develop in a patient with a systemic risk factors, such as hypertension and hyperlipidemia, or with hematological disorders, such as thrombophilia or hyperhomocysteinemia.¹⁷ There is still a lack of understanding of the events of RVO following the COVID-19 vaccine.¹⁸ So, this study aims to analyze the occurrence of RVO among people vaccinated by COVID-19 mRNA- and viral vector- vaccines, the two types of vaccines that have been approved in most countries.¹³

Materials and Methods

This Systematic review used the Preferred Reporting Items for Systematic Reviews and Meta-Analyses (PRISMA) checklist and is registered under PROSPERO (CRD42023393304).¹⁹ The literature search was conducted using PubMed, Web of Sciences (WoS), Scopus, and Google Scholar to find cases of RVO following the COVID-19 vaccine from January 2021 to December 2022. The medical subject headings (MeSH) terms used were “COVID-19 Vaccines” OR “2019 nCoV Vaccine” OR “SARS CoV 2 Vaccines” AND “Retinal Vein Occlusion” OR “Retinal Vein Thrombosis” OR “Central Retinal Vein Occlusion” OR “Branch retinal vein occlusion”. A manual search was also conducted in this systematic review by searching similar articles on PubMed and articles on the reference list of the included articles.

After excluding the duplicates, two independent reviewers screened the titles and abstracts for relevance. The criteria of the included studies were studies that were published in the English language and published between 1-1-2021 and 31-12-2022, observational studies, case reports, case series, case-control, cohorts, and cross-sectional studies. Included articles must be original articles that (1) report subjects who had COVID-19 Vaccines, (2) report subjects suffering from RVO diagnosed by physical examination, fluorescein angiography (FA), and/or optical coherence tomography (OCT).²⁰ We excluded systematic reviews, meta-analyses, commentaries, guidelines, clinical trials, and randomized controlled trials. We also excluded studies that had insufficient and irrelevant data on the COVID-19 vaccine and RVO, and duplicated medical records or records with overlapping datasets were also excluded.

All included full texts were assessed for eligibility using Joanna Briggs Institute (JBI) Critical Appraisal Tools.²¹ Two independent reviewers assessed the studies, and if there were any disagreements, the third reviewer would assess the said study, and his/her decision would be final. The data collected were as follows: (1) characteristics of the included articles; (2) data of reported RVO events, such as patient demographic (age and sex), history of COVID-19 vaccination (type and dose), type of vaccine (mRNA or Viral Vector), history of other medical condition/comorbidities, the onset of RVO after the vaccine, symptoms, physical examination, diagnoses, treatments, and the outcome after treatment. The narrative synthesis of the existing data about the comparison of the occurrence of RVO between people vaccinated by COVID-19 mRNA vaccines and viral vector vaccines will be a part of this systematic review.²²

Results

The search yielded 1073 results (Figure 1), and 107 duplicate studies were removed. Using the title and abstracts, 966 studies were screened and 926 of them were excluded. We searched 40 studies to read the full text. Furthermore, 9 studies that reported irrelevant data on the clinical were excluded. Finally, a total of 31 studies met the inclusion criteria and were added to the analysis process (Tables 1 and Supplementary Files). There were 78 cases from 75 patients that developed RVO following COVID-19 vaccination from Oman (Case #1), Qatar (Case #2), Colombia (Case #3), Japan (Case #5–7, 16, 26, 28–29), Taiwan (Case #10), USA (Case #15, 18), Canada (Case #19), Spain (Case #12–13, 21, 49), United Kingdom (Case #8–9), India (Case #4, 11, 17, 23–25), Greece (Case #14), Italy (Case #20, 22, 30–35, 65–78), South Korea (Case #37–47, 52–59), Hungary (Case #27), Australia (Case #60–64), and Brazil (Case #48, 50–51). One patient in the viral vector vaccine group developed 2 cases of RVO in both eyes following each dose of vaccine alternately (case #12–13) and 2 patients in the mRNA vaccine group developed 2 cases of RVO in both eyes simultaneously after the second dose (case #35–36 and #69–70).

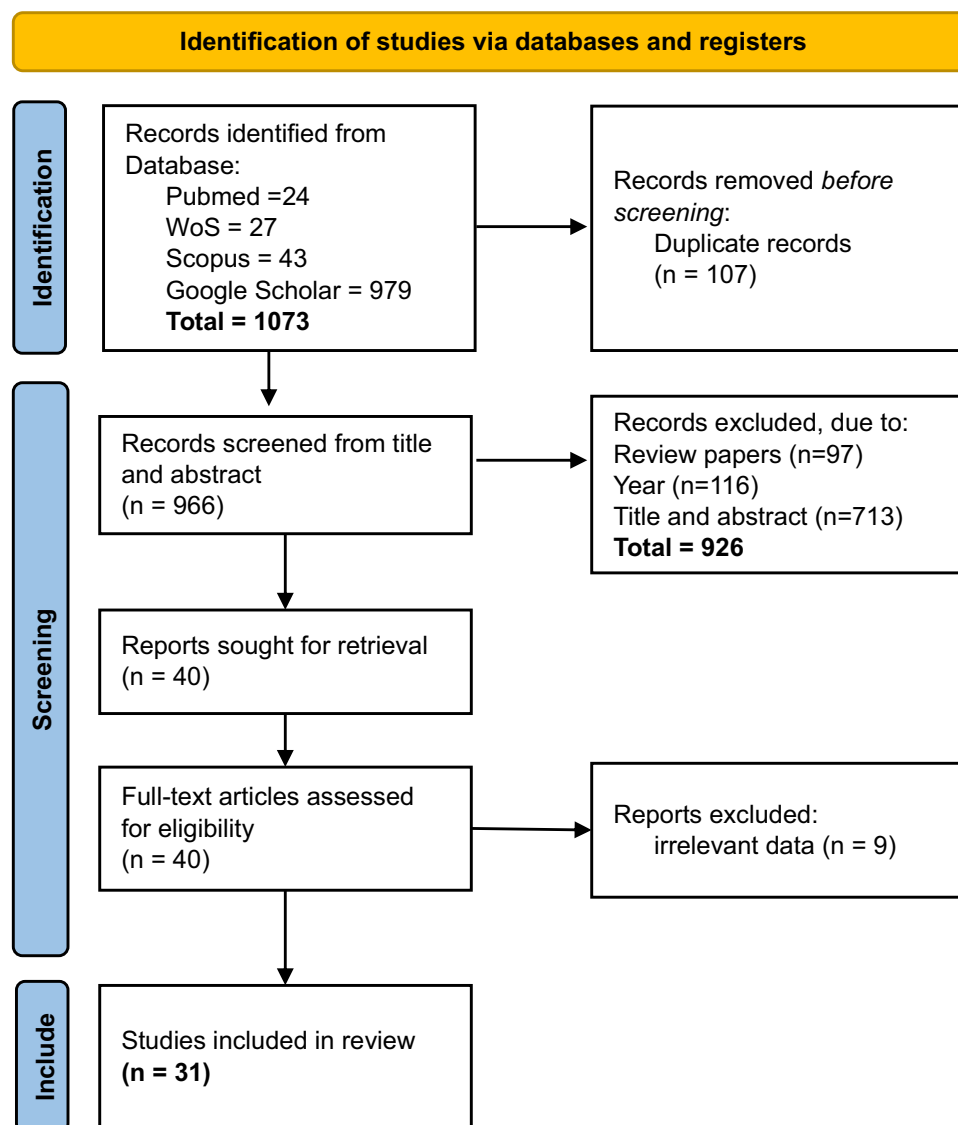


Figure 1 PRISMA flowchart.

Notes: PRISMA figure adapted from Page MJ, Moher D, Bossuyt PM, et al. PRISMA 2020 explanation and elaboration: updated guidance and exemplars for reporting systematic reviews. *BMJ*. 2021;372:n160. Creative Commons.¹⁹

Table I Summary of Studies Included in Our Systematic Review

No	Author (Year)	Article Type	Country	Case Number (#)	Age (Sex)	Vaccine Type (Dose)	Other Medical Condition	The Time Interval from Vaccine to Symptoms	Diagnosis	Treatment	Outcome
1	Al-Abri et al (2021) ²³	CR	Oman	Case #1	33 (M)	mRNA vaccine (I)	Mild obese, COVID-19 infection six months prior	2 hours	CRVO	Combination therapy	Improved
2	Bialasiewicz et al (2021) ²⁴	CR	Qatar	Case #2	50 (M)	mRNA vaccine (II)	Atopic dermatitis	15 minutes	CRVO	Combination therapy	Improved
3	Endo et al (2021) ²⁵	CR	Colombia	Case #3	52 (M)	mRNA vaccine (I)	None	15 days	CRVO	Combination therapy	Improved
4	Goyal et al (2021) ²⁶	CR	India	Case #4	28 (M)	Viral vector vaccine (II)	None	11 days	HRVO	Combination therapy	Improved
5	Ikegami et al (2022) ²⁷	CR	Japan	Case #5	54 (F)	mRNA vaccine (II)	Hypothyroidism	2 days	CRVO + CRAO	NR	NR
6	Tanaka et al (2021) ²⁸	CR	Japan	Case #6	71 (F)	mRNA vaccine (I)	BRVO + secondary ME	1 day	BRVO	Anti-VEGF	Improved
				Case #7	74 (M)	mRNA vaccine (I)	BRVO	2 days	BRVO	Anti-VEGF	Improved
7	Cackett et al (2022) ²⁹	CR	United Kingdom	Case #8	44 (F)	Viral vector vaccine (I)	None	5 days	CRVO	Observation	Improved
				Case #9	49 (F)	Viral vector vaccine (I)	None	4 days	CRVO	Observation	Improved
8	Chen (2022) ³⁰	CR	Taiwan	Case #10	72 (M)	mRNA vaccine (II)	Elevated D-Dimer	8 days	CRVO + CRAO	Combination therapy	Improved
9	Dutta Majumder et al (2022) ³¹	CR	India	Case #11	28 (M)	Viral vector vaccine (III)	None	25 days	CRVO	Corticosteroid	Improved
10	Fernández-Vigo et al (2022) ³²	CR	Spain	Case #12-13	69 (F)	Viral vector vaccine (I & II)	BRVO after the first vaccine	10 days, 30 days	BRVO, CRVO	Observation, corticosteroid	Improved, persisted

11	Karageorgiou et al (2022) ³³	CR	Greece	Case #14	60 (M)	Viral vector vaccine (NR)	None	7 days	BRVO	Anti-VEGF	NR
12	Lee et al (2022) ³⁴	CR	USA	Case #15	34 (M)	mRNA vaccine (II)	HL, mildly elevated ESR	10–12 days	CRVO + CRAO	Combination therapy	Worsened
13	Noguchi et al (2022) ³⁵	CR	Japan	Case #16	46 (F)	mRNA vaccine (II)	None	NR	CRVO	Anti-VEGF	Improved
14	Parakh et al (2022) ³⁶	CR	India	Case #17	31 (M)	Viral vector vaccine (I)	Hyperhomocysteinemia	7 days	CRVO	Anti-VEGF	Persisted
15	Priluck et al (2022) ³⁷	CR	USA	Case #18	57 (F)	mRNA vaccine (II)	HTN, dry eye syndrome	NR	BRVO	Anti-VEGF	Persisted
16	Pur et al (2022) ³⁸	CR	Canada	Case #19	34 (M)	mRNA vaccine (I)	None	2 days	BRVO	Observation	Persisted
17	Romano et al (2022) ³⁹	CR	Italy	Case #20	54 (F)	Viral vector vaccine (II)	HTN	2 days	CRVO	Combination therapy	Improved
18	Ruiz et al (2022) ⁴⁰	CR	Spain	Case #21	51 (F)	mRNA vaccine (II)	Hypothyroidism	12 days	CRVO + BRAO	Observation	Worsened
19	Sacconi et al (2022) ⁴¹	CR	Italy	Case #22	74 (F)	mRNA vaccine (II)	Breast cancer, AF	48 hours	HRVO	Anti-VEGF	Persisted
20	Sodhi et al (2022) ⁴²	CR	India	Case #23	43 (M)	Viral vector vaccine (I)	Slightly raised glycated hemoglobin	3 days	CRVO	Corticosteroid	Improved
21	Sonawane et al (2022) ⁴³	CR	India	Case #24	50 (M)	Viral vector vaccine (II)	DM, elevated blood urea, creatinine, HbA1C	4 days	CRVO	Anti-VEGF	NR
				Case #25	43 (F)	Viral vector vaccine (II)	Elevated CRP, Rheumatoid factor, d-Dimer	3 days	CRVO	Observation	NR
22	Sugihara et al (2022) ⁴⁴	CR	Japan	Case #26	38 (M)	mRNA vaccine (II)	None	2 days	BRVO	Anti-VEGF	Improved

(Continued)

Table I (Continued).

No	Author (Year)	Article Type	Country	Case Number (#)	Age (Sex)	Vaccine Type (Dose)	Other Medical Condition	The Time Interval from Vaccine to Symptoms	Diagnosis	Treatment	Outcome
23	Takacs et al (2022) ⁴⁵	CR	Hungary	Case #27	35 (M)	mRNA vaccine (I)	Elevated prothrombin activity, elevated serum homocysteine	2 weeks	CRVO	Combination therapy	Improved
24	Tanaka et al (2022) ⁴⁶	CR	Japan	Case #28	50 (F)	mRNA vaccine (I)	Breast cancer	3 days	BRVO	Anti-VEGF	Improved
				Case #29	56 (F)	mRNA vaccine (I)	None	3 days	BRVO	Anti-VEGF	Improved
25	Bolletta et al (2021) ⁴⁷	CS	Italy	Case #30	39 (M)	mRNA vaccine (II)	None	30 days	CRVO	Anti-VEGF	Improved
				Case #31	53 (F)	Viral vector vaccine (I)	SAH	2 days	BRVO	Anti-VEGF	Improved
				Case #32	61 (F)	Viral vector vaccine (II)	None	2 days	BRVO	Anti-VEGF	Improved
				Case #33	50 (M)	mRNA vaccine (II)	DM	3 days	BRVO	Anti-VEGF	Improved
				Case #34	48 (M)	mRNA vaccine (II)	SAH	23 days	BRVO	Anti-VEGF	Improved
26	Girbardt et al (2021) ⁴⁸	CS	Unspecified	Case #35-36	81 (F)	mRNA vaccine (II)	HTN	12 days	Unspecified RVO + RAO, BRVO	Observation, Anti-VEGF	NR
27	Park et al (2021) ⁴⁹	CS	South Korea	Case #37	68 (F)	Viral vector vaccine (I)	Dyslipidemia, vitreous hemorrhage	1 day	Unspecified RVO	Observation	NR
				Case #38	76 (M)	mRNA vaccine (I)	HTN, Cataract, NTG	3 days	Unspecified RVO	Observation	NR
				Case #39	85 (F)	mRNA vaccine (II)	DM, HTN, ESRD, tuberculosis, dementia, vitreous hemorrhage	1 day	Unspecified RVO	Anti-VEGF	NR
				Case #40	59 (M)	Viral vector vaccine (I)	DM, HTN	2 days	Unspecified RVO	Observation	NR

				Case #41	61 (M)	Viral vector vaccine (I)	None	2 days	Unspecified RVO	Anti-VEGF	NR
				Case #42	79 (M)	mRNA vaccine (II)	DM, gastric cancer	2 days	Unspecified RVO	Anti-VEGF	NR
				Case #43	77 (F)	mRNA vaccine (I)	HTN, Hepatitis B Virus Carrier, colon cancer on chemotherapy, cataract	16 days	Unspecified RVO	Anti-VEGF	NR
				Case #44	63 (M)	mRNA vaccine (I)	DM, DME	13 days	Unspecified RVO	Anti-VEGF	NR
				Case #45	51 (F)	Viral vector vaccine (I)	HTN	21 days	Unspecified RVO	Anti-VEGF	NR
				Case #46	81 (F)	mRNA vaccine (I)	HTN, cataract	4 days	Unspecified RVO	Observation	NR
				Case #47	61 (M)	Viral vector vaccine (I)	HTN, uveitis	3 days	Unspecified RVO	Observation	NR
28	da Silva et al (2021) ⁵⁰	CS	Brazil	Case #48	66 (F)	Viral vector vaccine (NR)	Endometrial hypertrophy, overweight, increased apolipoprotein a	16 days	BRVO	NR	NR
			Spain	Case #49	51 (M)	mRNA vaccine (NR)	COVID-19 infection 10 months prior	6 days	CRVO	NR	NR
			Brazil	Case #50	66 (M)	Viral vector vaccine (NR)	HTN	4 days	Unspecified RVO	NR	NR
			Brazil	Case #51	54 (F)	Viral vector vaccine (NR)	None	10 days	Unspecified RVO	NR	NR
29	Choi et al (2022) ⁵¹	CS	South Korea	Case #52	64 (M)	Viral vector vaccine (I)	None	1 day	CRVO	Anti-thrombotic	NR
				Case #53	33 (F)	mRNA vaccine (II)	None	6 days	CRVO	Anti-VEGF	NR
				Case #54	48 (M)	mRNA vaccine (III)	None	6 days	CRVO	Anti-VEGF	NR

(Continued)

Table I (Continued).

No	Author (Year)	Article Type	Country	Case Number (#)	Age (Sex)	Vaccine Type (Dose)	Other Medical Condition	The Time Interval from Vaccine to Symptoms	Diagnosis	Treatment	Outcome
				Case #55	69 (F)	Viral vector vaccine (I)	None	3 days	BRVO	Anti-thrombotic	NR
				Case #56	66 (M)	Viral vector vaccine (II)	None	7 days	BRVO	Observation	NR
				Case #57	68 (F)	Viral vector vaccine (I)	BRVO	1 day	BRVO	Observation	NR
				Case #58	74 (F)	Viral vector vaccine (II)	HTN, Nasal cavity Cancer, BRVO	6 days	BRVO	Other modalities	NR
				Case #59	63 (F)	Viral vector vaccine (I)	CRVO	3 days	CRVO	Anti-VEGF	NR
30	Peters et al (2022) ⁵²	CS	Australia	Case #60	71 (M)	Viral vector vaccine (I)	None	48 hour	BRVO	Anti-VEGF	NR
				Case #61	58 (M)	Viral vector vaccine (I)	Pterygium	72 hour	HRVO	Anti-VEGF	NR
				Case #62	73 (F)	Viral vector vaccine (I)	Retinal detachment, HTN	72 hour	BRVO	Anti-VEGF	NR
				Case #63	47 (F)	mRNA vaccine (I)	Hyperthyroidism	5 days	BRVO	Anti-VEGF	NR
				Case #64	36 (M)	mRNA vaccine (II)	None	24–72 hour	CRVO	Anti-VEGF	NR
31	Vujosevic et al (2022) ⁵³	CS	Italy	Case #65	69 (F)	Viral vector vaccine (I)	DVT	1 week	BRVO	Other modalities	Improved
				Case #66	82 (F)	mRNA vaccine (II)	None	2 weeks	BRVO	Corticosteroid	Improved
				Case #67	96 (F)	mRNA vaccine (II)	HTN, DM	1 week	CRVO	Corticosteroid	Persisted
				Case #68	91 (F)	mRNA vaccine (II)	None	1.5 week	CRVO	Observation	Persisted
				Case #69-70	78 (F)	mRNA vaccine (II)	None	1 week	BRVO, BRVO	Anti-VEGF, observation	Improved

				Case #71	70 (M)	Viral vector vaccine (I)	None	1 week	CRVO	Observation	Improved
				Case #72	40 (M)	Viral vector vaccine (I)	Hyperhomocysteinemia	2 weeks	BRVO	Observation	Improved
				Case #73	91 (M)	mRNA vaccine (II)	DM	4 weeks	BRVO	Corticosteroid	Persisted
				Case #74	72 (F)	mRNA vaccine (II)	HTN, HL	3 weeks	BRVO	Corticosteroid	Improved
				Case #75	88 (M)	mRNA vaccine (II)	HTN, HL, CVD, Alzheimer, Prostate cancer	2 weeks	HRVO	Corticosteroid	Persisted
				Case #76	73 (F)	Viral vector vaccine (II)	HTN, HL, CVD, NET	4 weeks	CRVO	Corticosteroid	Persisted
				Case #77	65 (F)	Viral vector vaccine (I)	HTN, HL, DM	1 week	CRVO	Corticosteroid	Improved
				Case #78	72 (F)	Viral vector vaccine (I)	HTN, CVD	2 weeks	HRVO	Other modalities	Persisted

Abbreviations: AF, atrial fibrillation; anti-VEGF, anti-vascular endothelial growth factor; BCVA, best-corrected visual acuity; BRVO, branch retinal vein occlusion; COVID-19, Coronavirus Disease-19; CRVO, central retinal vein occlusion; CVD, cardiovascular disease; DM, diabetes mellitus; DME, diabetic macular edema; DVT, deep vein thrombosis; ESRD, end stage renal disease; FA, fluorescein angiography; FE, fundal examination; FFA, Fundus fluorescein angiography; HL, hyperlipidemia; HTN, hypertension; HRVO, hemispheric retinal vein occlusion; IOP, intraocular pressure; LE, left eye; ME, macular edema; NET, neuroendocrine tumour; NR, not reported; NTG, normal tension glaucoma; OCT, optical coherence tomography; OCTA, optical coherence tomography angiography; RE, right eye; RVO, retinal vein occlusion; SAH, subarachnoid hemorrhage; UWPC, ultra-wide-field pseudo-color; VF, visual field.

Out of 75 patients, 39 patients (52.00%) were female (case #5, 6, 8–9, 12–13, 16, 18, 20–22, 25, 28–29, 31–32, 35–37, 39, 43, 45–46, 48, 51, 53, 55, 57–59, 62–63, 65–70, 74, 76–78), while 36 patients (48.00%) were male (case #1–4, 7, 10–11, 14–15, 17, 19, 23–24, 26–27, 30, 33–34, 38, 40–42, 44, 47, 49–50, 52, 54, 56, 60–61, 64, 71–73, 75). The median age of patients was 61 years (28 to 96 years old). Only 2 patients had COVID-19 infection before developing RVO (case #1, 49), 6 patients had a history of RVO before receiving the COVID-19 vaccine (case #6–7, 12–13, 57–59), 19 patients had hypertension (case #18, 20, 35–36, 38–40, 43, 45–47, 50, 58, 62, 67, 74–78), 6 patients had hyperlipidemia (case #15, 37, 74–77), 9 patients had diabetes mellitus (case #24, 33, 39–40, 42, 44, 67, 73, 77), 7 patients had cardiovascular disease (such as atrial fibrillation, subarachnoid hemorrhage, deep vein thrombosis, or unspecified cardiovascular disease) [case #22, 31, 34, 65, 75–76, 78], 3 patients had thyroid dysfunction (hypothyroidism or hyperthyroidism) [case #5, 21, 63], 20 patients had other medical conditions (such as obesity, breast cancer, prostate cancer, nasal cavity cancer, gastric cancer, colon cancer, atopic dermatitis, dry eyes syndrome, diabetic macular edema, retinal detachment, cataract, uveitis, neuroendocrine tumor, dementia, or Alzheimer) [case #1, 2, 18, 22, 24, 28, 37–39, 42–44, 46–48, 58, 61–62, 75–76], 7 patients had hypercoagulability conditions, such as hyperhomocysteinemia, elevated erythrocyte sedimentation rate (ESR), elevated D-Dimer, elevated C-reactive protein (CRP) or raised hemoglobin (case #10, 15, 17, 23, 25, 27, 72), and 25 patients had no other medical condition (case #3–4, 8–9, 11, 14, 16, 19, 26, 29–30, 32, 41, 51–56, 60, 64, 66, 68–71) (details can be seen in [Supplementary Files](#)).

Table 2 shows the characteristics of the 75 patients included in the study, categorized by COVID-19 vaccination type. Table 3 shows the characteristics of the 78 cases in this study, categorized by COVID-19 vaccination type. Thirty-nine patients received the mRNA vaccine (52.00%), while 36 patients received the viral vector vaccine (48.00%) before the event. Forty-one eyes developed RVO following the mRNA vaccine in 39 patients (case #1–3, 5–7, 10, 15–16, 18–19, 21–22, 26–30, 33–36, 38–39, 42–44, 46, 49, 53–54, 63–64, 66–70, 73–75) and 37 eyes developed RVO following the viral vector vaccine in 36 patients (case #4, 8–9, 11–14, 17, 20, 23–25, 31–32, 37, 40–41, 45, 47–48, 50–52, 55–62, 65, 71–72, 76–78).

Twenty-six cases out of 41 cases in the mRNA vaccine group or 33.33% of all cases in both groups developed RVO after the second dose of the vaccine (case #2, 5, 10, 15–16, 18, 21–22, 26, 30, 33–36, 39, 42, 53, 64, 66–70, 73–75). In contrast with the viral vector vaccine group, 23 cases out of 37 cases or 29.49% of all cases in both groups RVO after the first dose (case #8–9, 12, 17, 23, 31, 37, 40–41, 45, 47, 52, 55, 57, 59–62, 65, 71–72, 77–78), and 5 cases did not report the vaccine dose (case #14, 48–51). In the mRNA vaccine group, the median was 6 days, ranging from 15 minutes to 30

Table 2 Demographic Characteristics of the 75 Patients Included in this Systematic Review

Characteristic Demographic	COVID-19 Vaccination		Total n (%)
	mRNA Vaccine n (%)	Viral Vector Vaccine n (%)	
Age	56.00 (33–96) ^a	61 (28–74) ^a	61 (28–96) ^a
<30	0 (0)	2 (2.67)	2 (2.67)
31–40	8 (10.67)	2 (2.67)	10 (13.33)
41–50	7 (9.33)	5 (6.67)	12 (16.00)
51–60	6 (8.00)	7 (9.33)	13 (17.33)
61–70	1 (1.33)	15 (20.00)	16 (21.33)
71–80	9 (12.00)	5 (6.67)	14 (18.67)
>80	8 (10.67)	0 (0)	8 (10.67)
Sex			
Male	20 (26.67)	16 (21.33)	36 (48.00)
Female	19 (25.33)	20 (26.67)	39 (52.00)
Total	39 (52.00)	36 (48.00)	75 (100)

Note: ^aMedian (minimum-maximum).

Abbreviation: COVID-19, Coronavirus Disease-19.

Table 3 Clinical Characteristics of 78 Cases Included in this Systematic Review

Characteristic	COVID-19 Vaccination		Total, n (%)
	mRNA Vaccine, n (%)	Viral Vector Vaccine, n (%)	
The interval between vaccination and RVO (days)	6 (0.01–30) ^{a,b}	4 (1–30) ^a	6 (0.01–30) ^a
≤ 7 days	23 (29.49)	27 (34.61)	50 (64.10)
8–14 days	10 (12.82)	5 (6.41)	15 (19.23)
15–21 days	3 (3.85)	2 (2.56)	5 (6.41)
22–28 days	2 (2.56)	2 (2.56)	4 (5.12)
>28 days	1 (1.28)	1 (1.28)	2 (2.56)
Not reported	2 (2.56)	0 (0)	2 (2.56)
Vaccine dose			
RVO events after the first dose	13 (16.67)	23 (29.49)	36 (46.15)
RVO events after the second dose	26 (33.33)	9 (11.53)	35 (44.87)
RVO events after the third dose	1 (1.28)	1 (1.28)	2 (2.56)
Not reported	1 (1.28)	4 (5.12)	5 (6.41)
Laterality			
Right eye	21 (26.92)	19 (24.36)	40 (51.28)
Left Eye	18 (23.07)	13 (16.67)	31 (39.74)
Not reported	2 (2.56)	5 (6.41)	7 (8.97)
Symptoms			
Visual disturbance	23 (29.49)	16 (20.51)	39 (50.00)
Asymptomatic	0 (0)	1 (1.28)	1 (1.28)
Not reported	18 (23.08)	20 (25.64)	38 (48.72)
BCVA			
Perfect (20/20)	5 (6.41)	7 (8.97)	12 (15.38)
Worse BCVA (<20/20)	35 (44.87)	27 (34.61)	62 (79.48)
Not reported	1 (1.28)	3 (3.84)	4 (5.12)
Diagnosis			
CRVO	16 (20.51)	14 (17.94)	30 (38.46)
BRVO	16 (20.51)	13 (16.67)	29 (37.18)
HRVO	2 (2.56)	3 (3.84)	5 (6.41)
Unspecified RVO	7 (8.97)	7 (8.97)	14 (17.94)
Treatment			
Anti-VEGF	21 (26.92)	11 (14.10)	32 (41.02)
Corticosteroid	5 (6.41)	5 (6.41)	10 (12.82)
Anti-thrombotic	0 (0)	2 (2.56)	2 (2.56)
Combination	6 (7.69)	2 (2.56)	8 (10.25)
Other modalities	0 (0)	3 (3.84)	3 (3.84)
Observation	7 (8.97)	11 (14.10)	18 (23.07)
Not reported	2 (2.56)	3 (3.84)	5 (6.41)
Outcome after treatment			
Improved	18 (23.07)	13 (16.67)	31 (39.74)
Persisted	7 (8.97)	4 (5.12)	11 (14.10)
Worsened	2 (2.56)	0 (0)	2 (2.56)
Not reported	14 (17.94)	20 (25.64)	34 (43.59)
Total	41 (52.56)	37 (47.43)	78 (100)

Notes: ^aMedian (minimum-maximum); ^bMissing data = 2.

Abbreviations: anti-VEGF, anti-vascular endothelial growth factor; BRVO, branch retinal vein occlusion; COVID-19, Coronavirus Disease-19; CRVO, Central retinal vein occlusion; HRVO, hemispheric retinal vein occlusion; RVO, retinal vein occlusion.

days, and in the viral vaccine group, the median was 4 days, ranging from 1 to 30 days. We identified that both groups mostly developed RVO in under 7 days, 23 cases (29.49%) in the mRNA vaccine group (1–2, 5–7, 19, 22, 26, 28–29, 33, 38–39, 42, 46, 49, 53–54, 63–64, 67, 69–70), and 27 cases (34.61%) in the viral vector vaccine group (case # 8–9, 14, 17,

20, 23–25, 31–32, 37, 40–41, 47, 50, 52, 55–62, 65, 71, 77). However, in the mRNA vaccine group, 2 cases did not report the interval between the vaccination and the RVO events (case #16 and #18).

We found most of the RVO cases developed in the right eye with 21 cases (26.92%) and 19 cases (24.36%) in the mRNA vaccine group and viral vector vaccine group, respectively. The most reported symptoms of visual disturbance were blurred vision or vision loss, with 1 case reported flashes and floaters instead of vision loss (case #18), 1 case reported additional retrobulbar pain (case #2), and central scotoma (case #13). Eighteen cases (23.08%) and 20 cases (25.64%) in the mRNA vaccine group and viral vector vaccine group, respectively, did not report any symptoms in the reports. In the mRNA vaccine group, at the initial examination, 5 (6.41%) cases reported perfect Best-corrected Visual Acuity (BCVA) of 20/20 (case #1, 3, 18, 19, 70), while 35 cases (44.87%) had worse BCVA, with the worst BCVA was no light perception (case #5). In the viral vector vaccine group, at the initial examination, 7 (8.97%) cases reported a perfect BCVA of 20/20 (case #8, 12, 14, 55–56, 71–72), while 27 (34.61%) cases had worse BCVA, with the worst BCVA being hand motion (case #37, 57–58). Three cases (case #5, #10, and #15), one eye (case #21) with CRVO, and one eye (case #35) with unspecified RVO in the mRNA vaccine group were also additionally diagnosed with central retinal artery occlusion (CRAO), branch retinal artery occlusion (BRAO), and unspecified retinal artery occlusion (RAO) respectively.

Some studies reported the details of each treatment, while others did not. In the mRNA vaccine group, 21 cases (26.92%) were treated with Anti-Vascular endothelial growth factor (Anti-VEGF) only. Studies used intravitreal injections of anti-VEGF such as Aflibercept (case #6–7, 18, 26, 64), Ranibizumab (case #16, 22, 28–29), or Bevacizumab (case #39, 42–44, 63), while some studies did not report the specific type of anti-VEGF (case #30, 33–34, 36, 53–54, 69). We identified corticosteroids used in the mRNA group in the form of intravitreal injection, intravenous, or oral dexamethasone, methylprednisolone, or prednisolone, and some studies did not report the details of the steroid treatment (case #66–67, 73–75). Some studies used anti-thrombotics used Rivaroxaban, Acetylsalicylic acid, Low Molecular Weight Heparin (LMWH), or Apixaban in combination with other therapies. Combination treatments consisting of anti-thrombotic, anti-VEGF, corticosteroid, and/or other modalities, such as hyperbaric or pan-retinal photocoagulation, were done in 6 cases (7.69%) (case #1–3, 10, 15, 27; details can be seen in [Supplementary Files](#)). The follow-up period for observation treatment ranged from 3 weeks to 10 months.

In contrast with the mRNA vaccine group, 11 cases out of 37 cases (14.10%) in the viral vector vaccine group were observed and followed up (case #8–9, 12, 25, 37, 40, 47, 56–57, 71–72), and 11 cases (14.10%) were treated with Anti-VEGF (case #14, 17, 24, 31–32, 41, 45, 59–62). We could only identify one of the detailed anti-VEGF used in one study, which was the intravitreal injection of Ranibizumab and Aflibercept, and the patient also received folic acid B6 and B12 vitamin supplementation (case #17), while most of the details of the treatment were not reported. We also identified corticosteroids that were used in the studies, such as intravenous Methylprednisolone (case #11), intravitreal implant Dexamethasone (case #13), or intravitreal injection of Triamcinolone Acetonide (case #23), and some were unknown (case #76–77). Two cases reported combination therapy using corticosteroid, anti-thrombotic, and/or pan-retinal photocoagulation (case #4, 20), and other modalities in this viral vector vaccine group were vitrectomy and photocoagulation (case #59, 65, 78; details can be seen in [Supplementary Files](#)).

Although most of the patients in both groups improved in terms of BCVA and fundal findings (such as macular edema and hemorrhage) after treatment, some persisted and even worsened. In the mRNA vaccine group, one eye was additionally diagnosed with non-arteritic anterior ischemic optic neuropathy (NAION) (case #15) and one eye had a worsened BCVA after a 2-month observation (case #21). However, in the viral vector vaccine, 20 cases (25.64%) did not report any outcome in their studies (case #14, 24–25, 37, 40–41, 45, 47–48, 50–52, 55–62), in contrast with the mRNA group which only had 14 cases that did not report the outcome (case #5, 35–36, 38–39, 42–44, 46, 49, 53–54, 63–64).

Discussion

Retinal vein occlusion (RVO) usually develops in older ages, especially over the age of 70 and there was no predilection for gender and race.^{17,54} In our study, we found the age range to be wider and more diverse (28–96 years) and similar between mRNA and viral vector vaccine groups. However, if we analyze it further, we identify that RVO mostly happens in adults and older ages. We could not find any study that reported RVO events following COVID-19 vaccination in

children and adolescents. Though the symptoms were mostly similar, the BCVA at the initial examination were all various. Both prior medical conditions and vaccines might be taking part in the RVO manifestation in each patient. For example, in case #15, a 34-year-old male with hyperlipidemia developed CRVO 11 days after the second dose of the mRNA vaccine. He had bad BCVA (counting fingers) and even with the combination therapy, his condition was considered to worsen as he developed NAION.³⁴ In contrast with case #74, 72 years old female, had hypertension and hyperlipidemia, but she developed RVO 3 weeks after the second dose of mRNA vaccine. She also had better BCVA (20/25) and improved to 20/20 after steroid treatment only.⁵³ By this point, it is suggested that age was not the only aspect that RVO events and their severity.

Retinal vein occlusion (RVO) pathogenesis was unclear and there were some conditions that lead to RVO, such as thrombotic events. In CRVO, the thrombotic event might occur in the central retinal vein when passing through the lamina cribrosa or in its journey alongside the central retinal artery.⁵⁵ In BRVO, a thrombotic event was thought to be caused by arterial compression of the vein at the arteriovenous crossing secondary to pre-existing endothelial damage.⁵⁶ Some studies also suggested that RVO pathogenesis was caused by conditions like hemodynamic changes, endothelial changes, and hypercoagulability. Those conditions were known as Virchow's triad and it applied to some diseases like deep vein thrombosis (DVT).^{17,33,57} It was suggested to share the risk factor with RVO, such as cardiovascular and systemic risk factors, like hypertension, hyperlipidemia, diabetes mellitus, hematological disorders, glaucoma/ocular hypertension, or familial RVO.¹⁷

From this review, studies from Bialasiewicz et al, Sugihara et al, and Tanaka et al suggested that RVO following COVID-19 vaccination was due to thromboembolic events since the patient did not have any medical condition related to the risk factor of RVO.^{24,44,46} Endo et al, and Pur et al, hypothesized that those conditions were caused by an immunogenic reaction in COVID-19 vaccination in previously healthy patients, the same reaction observed in patients infected with COVID-19.^{25,38} Noguchi et al, further stated that COVID-19 vaccine triggered the production of neutralizing antibodies, that supposed to recognize and target COVID-19 virus. The neutralizing antibodies could cross-react with proteins and antigens in vessels and retinal layers.^{35,38} A study by Parakh et al, suggested that the COVID-19 vaccine might trigger venous thromboembolism in background homocysteinemia and might have a potential effect on endothelial cells and autoimmunity.³⁶ However, the hypothesis was still doubtful because of the weak or unclear association of homocysteine and venous thromboembolic events and the effectivity of the homocysteine-lowering drugs in reducing the risk of venous thromboembolic events. It was also hypothesized by Leung et al, that the COVID-19 vaccine can induce inflammation in retinal vasculature and will induce thromboembolic events, and has been observed for other types of vaccination like influenza, although it was also still unclear. It was also further suggested that mRNA vaccines might cause transient endothelial dysfunction, especially after the second dose, and can expose vasculature to thrombosis.⁵⁸

In mRNA vaccines, the antigen (the mRNA) was stabilized in the pre-fusion stage which then translated to Spike Protein (S Protein). S proteins were expressed on the cell surface and induced antibody production. In viral vector vaccines, DNA that encodes the spike protein is delivered, and our immune system produces the antibodies for this protein. It is possible that the S protein in viral vector vaccine especially AstraZeneca (AZ), can induce the proinflammatory/procoagulant response or disrupt endothelial cells because the immunogen in AZ has not been modified to stabilize and mitigate shedding of that expressed S protein.^{54,59} It also suggested to be the cause of RVO following a viral vector vaccine, especially AZ, as stated by Dutta Majumder et al.³¹ While endothelial damage was hypothesized due to the cross-reaction of antigen that disrupts the vessels, Cackett et al, suggested that blood clots following AZ was a rare immune response and resembled heparin-induced thrombocytopenia, although the pathogenesis remained unclear.²⁹ The condition was referred to as vaccine-induced immune thrombotic thrombocytopenia (VITT). Platelet-activating antibodies recognize and bind to complexes of cationic platelet factor (PF4) and anionic heparin, causing a prothrombotic state.^{60,61} However, this phenomenon was not concluded yet because of the lack of study on the measurement of the anti-PF4.⁵⁸ Systemic diseases or medical conditions, such as metabolic syndrome (hypertension, hyperlipidemia, diabetes mellitus), atherosclerosis, smoking, and old age were known to be strongly associated with RVO development.^{17,57,62} Unfortunately, the majority of the cases in our review had other medical conditions (53/78, 67.94%). Thus, it is difficult to differentiate whether the events of RVO were due to the

COVID-19 vaccine reaction, other medical conditions, and/ or comorbidities. The results stayed the same in studies that reported the medical conditions of each patients.^{23,30,34,37,41–43,47,51,53}

Al-Abri et al reported a CRVO following the first dose of the mRNA vaccine. However, as the patient was a healthy young man with a history of COVID-19 infection, Al-Abri et al suggested that the RVO was associated with the previous COVID-19 infection rather than the vaccine itself.²³ RVO also reported in some studies about COVID-19 infection,⁶³ but as in this study, there were only two patients who developed RVO following the COVID-19 vaccine who had a previous COVID-19 infection (case #1 and 49). A recent cohort study using the TriNetX platform, found using a post-hoc analysis that a new-encounter RVO diagnosis has a greater risk to develop acutely after COVID-19 infection rather than after a mRNA vaccine.⁶⁴ In contrast with the said study, a retrospective study by Sunny and Au, found that there was no evidence of the rising concern of developing an RVO in patients with COVID-19 infection and the occurrence of CRVO and COVID-19 infection might be coincidental.⁶⁵

Other conditions such as hypothyroidism, especially subclinical hypothyroidism was also found to be a risk factor for RVO because it is associated with atherosclerotic.⁶⁶ It should also be considered in two patients (case #5 and 21) that are found in this systematic review, but the related study did not have further information about hypothyroidism and did not explain any connection to the RVO.^{27,40} Previous studies reported the RVO in breast cancer⁶⁷ and prostate cancer⁶⁸ patients, although it was rare. It was suggested that malignancy associated with RVO diagnosis, and malignancy might be a cause of hypercoagulability disorders.^{69,70} One study reported an association between retinal artery/vein occlusion and the risk of Alzheimer's dementia and vascular dementia. There was no association between Alzheimer's dementia and retinal artery/vein occlusion with or without an Apolipoprotein E (APOE) ϵ 4 allele. However, it was suggested that retinal artery and vein occlusion is significantly associated with vascular dementia with at least one APOE ϵ 4 allele.⁷¹

This review presented various doses of each type of COVID-19 vaccine followed by RVO. The underlying mechanism was unclear; the dose of either mRNA or viral vector vaccines for adults is approximately similar between studies; arguably the RVO occurrence was not significantly associated with this factor but instead with the type of vaccines that interacted with the underlying conditions in each case. Sugihara et al suggested that there might be different levels or pathways in an immune response that happened after each dose of vaccine which triggered RVO development.⁴⁴ One cohort study compared the risk of thrombocytopenia and venous thrombosis after the first vaccine. It stated that there is an increased risk of 30% in thrombocytopenia for patients who had the first dose of ChAdOx-1 compared to BNT162b2. There was also an increased risk of venous thrombosis with thrombocytopenia in patients with the first dose of Ad26.COV2.S.⁷² First dose of ChAdOx1 was also found to be associated with idiopathic thrombocytopenic purpura (ITP).⁷³ Second dose of ChAdOx1 was also associated with an increased risk of ITP and cerebral venous sinus thrombosis (CVST) while the second dose of BNT162b2 was not found to be associated with increased risks of thromboembolic, hemorrhagic, or thrombocytopenic events.⁷⁴ This systematic review found that number of RVO after the first dose of mRNA vaccine was lower than cases after the first dose of viral vector vaccine: 13 cases [case #1, 3, 6–7, 19, 27–29, 38, 43–44, 46, 63]^{23,25,28,38,46,49,52} vs 23 cases [case #8–9, 12, 17, 23, 31, 37, 40–41, 45, 47, 52, 55, 57, 59–62, 65, 71–72, 77–78].^{29,32,36,42,47,49,51–53} However, the number of cases of RVO after the second dose of the mRNA vaccine was higher than the viral vector vaccine: 26 cases [case #2, 5, 10, 15–16, 18, 21–22, 26, 30, 33–36, 39, 42, 53, 64, 66–70, 73–75]^{24,25,27,28,30,34,35,37,40,41,44,47–49,51–53} vs 9 cases [case #4, 13, 20, 24–25, 32, 56, 58, 76].^{26,32,39,43,47,51,53} A recent risk assessment study using big data from the TriNetX network found a significant increase in the risk of RVO during the first 2 weeks after vaccination and persisted for 12 weeks. The study did not detect any disparity between the increased risk of RVO 2 years following vaccination in individuals with first and second doses of mRNA vaccines (BNT162b2 and mRNA-1273).⁷⁵ Another study from Dorney et al stated that although there was a potential vision-threatening adverse events after receiving COVID-19 vaccination, such as a new-encounter RVO, the risk was extremely low.⁶⁴ Further analysis regarding this matter is warranted to determine risk factors and/or comorbidities that significantly reacted to either type of COVID-19 vaccine.

Both mRNA and viral vector vaccine groups in our review have an acute onset (6 days in the mRNA vaccine group and 4 days in the viral vector vaccine group), the onset of RVO signs and symptoms ranged from 15 minutes to 30 days in the mRNA group and 1 to 30 days in the viral vector group. These results matched a previous study by Smadja et al, that observed a significant difference in the time frame between the COVID-19 vaccine and venous thrombosis events

(the median of 6 days for AZ, and 4 days for Comirnaty and Moderna). In their study, the time after each vaccine to cerebral venous thrombosis was: AZ (2–16 days), Moderna (2–39 days), and Comirnaty (1–10 days).⁷⁶ In a retrospective study using big data from the Vaccine Adverse Events Reporting System (VAERS) by Singh et al, confirmed by a post-hoc analysis ($p < 0.0001$) that the mean onset interval for developing an RVO was significantly longer in patients who received a viral vector vaccine (Ad26.Cov2.S) compared to mRNA vaccine (BNT162b2 and mRNA-1273). It was also further stated that the risk of RVO following an mRNA vaccine (BNT162b2) was higher compared to other vaccines ($p < 0.0001$).⁷⁷

This systematic review also identified that in total, CRVO was the most widely diagnosed (30/78, 38.46%). The result was different from previous studies which stated that BRVO was more common than CRVO.^{17,57} However, if we looked at each group, BRVO was the most diagnosed in the mRNA vaccine group with 16 cases (20.51%) [case #6–7, 18–19, 26, 28–29, 33–34, 36, 63, 66, 69–70, 73–74],^{28,37,38,44,46–48,52,53} tied with CRVO with 16 cases (20.51%) [case #1–3, 5, 10, 15–16, 21, 27, 30, 49, 53–54, 64, 67–68],^{23–25,27,30,34,35,40,45,47,50–53} while in the viral vector vaccine group, 14 cases (17.95%) were diagnosed with CRVO [case #8–9, 11, 13, 17, 20, 23–25, 52, 59, 71, 76–77],^{29,31,32,36,39,42,43,51,53} and 13 cases (16.67%) were diagnosed with BRVO [case #12, 14, 31–32, 48, 55–58, 60, 62, 65, 72].^{32,33,47,50–53}

All of the treatments were based on the pathogenesis of RVO, which included anti-VEGF therapy, corticosteroid, anti-thrombotic therapy, and other modalities, such as laser photocoagulation.¹⁷ The treatments were all in accordance with previous studies.^{17,57} The high number of observations in both groups (18/78, 23.07%) were contributed by patients who rejected the treatment or patients with perfect BCVA in the initial examination. Most of the cases were improved after the treatment (31/78, 39.74%), even though 34 cases did not report any outcome [case #5, 14, 24–25, 35–64].^{27,33,43,48–52} It is identified that out of 11 cases that have persisted outcome [case #13, 17–19, 22, 67–68, 73, 75–76, 78],^{32,36–38,53} 9 cases had a record of other medical conditions, such as hypercoagulability, hypertension, cardiovascular disease, diabetes mellitus, and history of RVO. However, we also could identify that 11 cases out of 29 cases with medical conditions in the mRNA vaccine group and 6 cases out of 24 cases with medical conditions in the viral vector vaccine group, were improved even though they had another medical condition, while 2 out of 28 cases in mRNA vaccine group have worsened outcome [case #15, 21].^{34,40} The outcome might also be associated with the therapy given to each case. Anti-VEGF was a trending therapy in RVO with a total of 32 cases (41.02%). It is also considered to be a great therapy because of the great outcome we identified in this study, with 12 cases having improved outcomes after the treatment [case #6, 7, 16, 26, 28–34, 69].^{28,35,44,46,47,53}

In this review, more patients (52.00%) were vaccinated with the mRNA vaccine, even though viral vector vaccines were approved in more countries. In Emergency Use Listing (EUL) by WHO, approved viral vector vaccines were Jcovden (Janssen/Johnson & Johnson), Vaxzevria (Oxford/AstraZeneca), and Covishield (Oxford/AstraZeneca formulation – Serum Institute of India) which were approved in 113, 149, and 49 countries, respectively. Approved mRNA vaccines in EUL on the other hand, Spikevax (Moderna) and Comirnaty (Pfizer/BioNTech) were approved in 88 and 149 countries, respectively.¹³ This review also included another viral vector vaccine that has been approved by WHO but not listed in EUL, such as Gamaleya (Gam-COVID-vac/Sputnik V) (case #4).^{26,78}

We only included studies that had sufficient data on vaccine types and RVO, however the latter is relatively rare. Interpretation of the results of this review must be done with discretion, due to inclusion criteria, the final analyses were done on the studies from 16 out of 201 countries included in EUL. Furthermore, several included studies in this review, did not report the exact dosage of each vaccine, the onset of the RVO, treatment, and the outcome. We also could not perform relative risk analysis due to this insufficiency, and the nature of data from the included study, which are quite heterogeneous. However, to the best of our knowledge, this review is one of the first that report the RVO in mRNA- and viral vector COVID-19 vaccines, which will be beneficial for clinicians and to be more aware of the pathology for earlier detection and proper treatment plan. Nevertheless, COVID-19 vaccination still had benefits against SARS-COV-2 infection. Most RVO cases we found were also improved with treatments and some were self-limiting. Future studies should evaluate the risk factors in RVO cases following COVID-19 vaccination to further explain the causal relationship and mechanism between RVO and COVID-19 vaccination and between the type of vaccines, in more diverse populations or using big data from databases, such as Vaccine Adverse Events Reporting System (VAERS) or National Registry of Drug-Induced Ocular Side Effects to assist the investigation of COVID-19 vaccination's adverse events.⁷⁹

Conclusion

Retinal Vein Occlusion (RVO) following COVID-19 vaccination was rare but has become one of the major concerns after some cases were found since global vaccination started. It should be noted that there might be an occurrence of visual disturbance after the COVID-19 vaccine, which clinicians should monitor closely. We could not suggest any association between RVO and COVID-19 vaccination because of other underlying conditions and/or risk factors that the patients had before the event. Therefore, further analysis with larger data is warranted.

Acknowledgments

We want to thank the Faculty of Medicine Universitas Airlangga and the Faculty of Medicine Universitas Ciputra Surabaya.

Disclosure

The authors report no conflicts of interest in this work.

References

- Cucinotta D, Vanelli M. WHO declares COVID-19 a pandemic. *Acta Biomed.* 2020;91(1):157–160. doi:10.23750/abm.v91i1.9397
- Zhu N, Zhang D, Wang W, et al. A novel Coronavirus from patients with Pneumonia in China, 2019. *N Engl J Med.* 2020;382(8):727–733. doi:10.1056/NEJMoa2001017
- Adriana DN, Miftahussurur M. Current strategy to combat COVID-19 in Indonesia. *New Armen Med J.* 2020;14(4):16–28.
- Xie M, Chen Q. Insight into 2019 novel coronavirus — an updated interim review and lessons from SARS-CoV and MERS-CoV. *Int J Infect Dis.* 2020;94:119–124. doi:10.1016/j.ijid.2020.03.071
- Lu H, Stratton CW, Tang Y. Outbreak of pneumonia of unknown etiology in Wuhan, China: the mystery and the miracle. *J Med Virol.* 2020;92(4):401–402. doi:10.1002/jmv.25678
- Triyono EA, Seipalla F, Djaja N, et al. Clinical characteristics of patients with COVID-19 admitted to the COVID-19 emergency field hospital of Bangkalan, Indonesia. *F1000Research.* 2022;11:414. doi:10.12688/f1000research.110716.2
- Soedarsono S, Semedi BP, Setiawati R, et al. Case report: survival of a coronavirus disease-2019 (Covid-19) patient with Acute Respiratory Distress Syndrome (ARDS) in Dr. Soetomo Hospital, Surabaya, Indonesia. *Folia Med.* 2021;56(3):235. doi:10.20473/fmi.v56i3.24584
- Haryati H, Isa M, Assagaf A, Nurrasyidah I, Kusumawardhani E. Clinical characteristics of hospitalized individuals dying with COVID-19 in Ulin Regional Hospital Banjarmasin. *J Respirasi.* 2021;7(1):1. doi:10.20473/jr.v7-i1.2021.1-7
- Centers for Disease Control and Prevention. How COVID-19 Spreads. Centers for Disease Control and Prevention; 2022. Available from: <https://www.cdc.gov/coronavirus/2019-ncov/prevent-getting-sick/how-covid-spreads.html?> Accessed January 13, 2023.
- Yamani LN, Syahrul F. Public health perspective of the COVID-19 pandemic: host characteristics and prevention of COVID-19 in the community (Review). *World Acad Sci J.* 2020;2(6). doi:10.3892/wasj.2020.62
- World Health Organization. COVID-19 vaccines with WHO emergency use listing. *Vaccines;* 2023. Available from: <https://extranet.who.int/pqweb/vaccines/vaccines-covid-19-vaccine-eul-issued>. Accessed January 13, 2023.
- Kaur SP, Gupta V. COVID-19 vaccine: a comprehensive status report. *Virus Res.* 2020;288:198114. doi:10.1016/j.virusres.2020.198114
- World Health Organization. 11 vaccines granted emergency use listing (EUL) by WHO. COVID 19 vaccine tracker; 2023. Available from: <https://covid19.trackvaccines.org/agency/who/>. Accessed March 19, 2023.
- Arbel R, Hammerman A, Sergienko R, et al. BNT162b2 vaccine booster and mortality due to Covid-19. *N Engl J Med.* 2021;385(26):2413–2420. doi:10.1056/NEJMoa2115624
- Ng XL, Betzler BK, Testi I, et al. Ocular adverse events after COVID-19 vaccination. *Ocul Immunol Inflamm.* 2021;29(6):1216–1224. doi:10.1080/09273948.2021.1976221
- Kumari S, Anand R, Sambyal B, Singh Y. Ocular adverse effects of COVID-19 vaccines: a systematic review. *J Family Med Prim Care.* 2022;11(9):5041 doi:10.4103/jfmpc.jfmpc_747_22.
- Karia N. Retinal vein occlusion: pathophysiology and treatment options. *Clin Ophthalmol.* 2010;809. doi:10.2147/OPHT.S7631
- Feltgen N, Ach T, Ziemssen F, et al. Retinal vascular occlusion after COVID-19 vaccination: more coincidence than causal relationship? Data from a retrospective multicentre study. *J Clin Med.* 2022;11(17):5101. doi:10.3390/jcm11175101
- Page MJ, Moher D, Bossuyt PM, et al. PRISMA 2020 explanation and elaboration: updated guidance and exemplars for reporting systematic reviews. *BMJ.* 2021;372:n71. doi:10.1136/bmj.n71
- Shah VA, Randolph J, Hsu J, Gurnani B, Lim JI, Marcet MM. Retinal vein occlusion. *EyeWiki;* 2022. Available from: https://eyewiki.aao.org/Retinal_Vein_Occlusion. Accessed January 15, 2023.
- Moola S, Munn Z, Tufanaru C, et al. Systematic reviews of etiology and risk. In: editors, Aromataris E, Munn Z. *JBI Manual for Evidence Synthesis.* JBI; 2020. doi:10.46658/JBIMES-20-01
- Rachman MJ, Kalanjati VP, Khadijah F, Nasution MHF. Retinal vein occlusion amongst people vaccinated by COVID-19 mRNA- and viral vector-vaccines: a systematic review. *Prospero.* 2023. Available from: https://www.crd.york.ac.uk/prospero/display_record.php?ID=CRD42023393304. Accessed September 19, 2023.
- Al-Abri M, Al-Musalami A, Al-Rawahi B, Al-Hinai A, Al-Fadhil N. Central retinal vein occlusion in a young healthy COVID-19 patient: a case report and literature review. *Middle East Afr J Ophthalmol.* 2021;28(3):199. doi:10.4103/meajo.meajo_271_21
- Bialasiewicz AA, Farah-Diab MS, Mebarki HT. Central retinal vein occlusion occurring immediately after 2nd dose of mRNA SARS-CoV-2 vaccine. *Int Ophthalmol.* 2021;41(12):3889–3892. doi:10.1007/s10792-021-01971-2

25. Endo B, Bahamon S, Martínez-Pulgarín D. Central retinal vein occlusion after mRNA SARS-CoV-2 vaccination: a case report. *Indian J Ophthalmol.* 2021;69(10):2865. doi:10.4103/ijo.IJO_1477_21
26. Goyal M, Murthy S, Srinivas Y. Unilateral retinal vein occlusion in a young, healthy male following Sputnik V vaccination. *Indian J Ophthalmol.* 2021;69(12):3793. doi:10.4103/ijo.IJO_2412_21
27. Ikegami Y, Numaga J, Okano N, Fukuda S, Yamamoto H, Terada Y. Combined central retinal artery and vein occlusion shortly after mRNA-SARS-CoV-2 vaccination. *QJM an Int J Med.* 2021;114(12):884–885. doi:10.1093/qjmed/hcab287
28. Tanaka H, Nagasato D, Nakakura S, et al. Exacerbation of branch retinal vein occlusion post SARS-CoV2 vaccination. *Medicine (Baltimore).* 2021;100(50):e28236. doi:10.1097/MD.00000000000028236
29. Cackett P, Ali A, Young SL. Phenotypic appearance of central retinal vein occlusion post AstraZeneca vaccine. *Int J Ophthalmol.* 2022;15(4):672–673. doi:10.18240/ijo.2022.04.24
30. Chen YC. Combined central retinal artery occlusion and vein occlusion with exudative retinal detachment following COVID -19 vaccination. *Kaohsiung J Med Sci.* 2022;38(10):1020–1021. doi:10.1002/kjm2.12591
31. Dutta Majumder P, Prakash V. Retinal venous occlusion following COVID-19 vaccination: report of a case after third dose and review of the literature. *Indian J Ophthalmol.* 2022;70(6):2191. doi:10.4103/ijo.IJO_592_22
32. Fernández-Vigo JI, Perálvarez Conde C, Burgos-Blasco B, Fernández-Vigo JA. Bilateral retinal vein occlusion after two doses of SARS-CoV-2 adenovirus vector-based vaccine. *J Fr Ophthalmol.* 2022;45(9):e397–e399. doi:10.1016/j.jfo.2022.05.006
33. Karageorgiou G, Chronopoulou K, Georgalas I, Kandarakis S, Tservakis I, Petrou P. Branch retinal vein occlusion following ChAdOx1 nCoV-19 (Oxford-AstraZeneca) vaccine. *Eur J Ophthalmol.* 2023;33(5):NP121–3. doi:10.1177/11206721221124651
34. Lee S, Sankhala KK, Bose S, Gallemore RP. Combined central retinal artery and vein occlusion with ischemic optic neuropathy after COVID-19 vaccination. *Int Med Case Rep J.* 2022;15:7–14. doi:10.2147/IMCRJ.S328931
35. Noguchi K, Takahashi R, Makino S. Central retinal vein occlusion following mRNA severe acute respiratory syndrome coronavirus 2 vaccination. *Int J Case Rep Images.* 2022;13(2):105–107. doi:10.5348/101337Z01KN2022CI
36. Parakh S, Maheshwari S, Das S, et al. Central retinal vein occlusion post ChAdOx1 nCoV-19 vaccination – can it be explained by the two-hit hypothesis? *J Ophthalmic Inflamm Infect.* 2022;12(1):34. doi:10.1186/s12348-022-00311-4
37. Priluck AZ, Arevalo JF, Pandit RR. Ischemic retinal events after COVID-19 vaccination. *Am J Ophthalmol Case Rep.* 2022;26:101540. doi:10.1016/j.ajoc.2022.101540
38. Pur DR, Bursztyn LLCD, Iordanous Y. Branch retinal vein occlusion in a healthy young man following mRNA COVID-19 vaccination. *Am J Ophthalmol Case Rep.* 2022;26:101445. doi:10.1016/j.ajoc.2022.101445
39. Romano D, Morescalchi F, Romano V, Semeraro F. COVID-19 AdenoviralVector vaccine and central retinal vein occlusion. *Ocul Immunol Inflamm.* 2022;30(5):1286–1288. doi:10.1080/09273948.2022.2079534
40. Ruiz OAG, González-López JJ. Simultaneous unilateral central retinal vein occlusion and branch retinal artery occlusion after Coronavirus disease 2019 (COVID-19) mRNA vaccine. *Arq Bras Oftalmol.* 2022;87(2). doi:10.5935/0004-2749.2022-0010
41. Sacconi R, Simona F, Forte P, Querques G. Retinal vein occlusion following two doses of mRNA-1237 (Moderna) immunization for SARS-Cov-2: a case report. *Ophthalmol Ther.* 2022;11(1):453–458. doi:10.1007/s40123-021-00441-3
42. Sodhi PK, Yadav A, Sharma B, Sharma A, Kumar P. Central retinal vein occlusion following the first dose of COVID vaccine. *Cureus.* 2022;14(6). doi:10.7759/cureus.25842
43. Sonawane NJ, Yadav D, Kota AR, Singh HV, Panigrahi PK. Central retinal vein occlusion post-COVID-19 vaccination. *Indian J Ophthalmol.* 2022;70(5):308–309. doi:10.4103/ijo.IJO_1757_21
44. Sugihara K, Kono M, Tanito M. Branch retinal vein occlusion after messenger RNA-based COVID-19 vaccine. *Case Rep Ophthalmol.* 2022;13(1):28–32. doi:10.1159/000521838
45. Takacs A, Ecsedy M, Nagy ZZ. Possible COVID-19 mRNA vaccine-induced case of unilateral central retinal vein occlusion. *Ocul Immunol Inflamm.* 2022;1–6. doi:10.1080/09273948.2022.2094811
46. Tanaka H, Nagasato D, Nakakura S, et al. Branch retinal vein occlusion post severe acute respiratory syndrome coronavirus 2 vaccination. *Taiwan J Ophthalmol.* 2022;12(2):202. doi:10.4103/tjo.tjo_24_22
47. Bolletta E, Iannetta D, Mastrofilippo V, et al. Uveitis and other ocular complications following COVID-19 vaccination. *J Clin Med.* 2021;10(24):5960. doi:10.3390/jcm10245960
48. Girbardt C, Busch C, Al-Sheikh M, et al. Retinal vascular events after mRNA and adenoviral-vectored COVID-19 vaccines—A case series. *Vaccines.* 2021;9(11):1349. doi:10.3390/vaccines9111349
49. Park HS, Byun Y, Byeon SH, Kim SS, Kim YJ, Lee CS. Retinal hemorrhage after SARS-CoV-2 vaccination. *J Clin Med.* 2021;10(23):5705. doi:10.3390/jcm10235705
50. da Silva LSC, Finamor LPS, Andrade GC, et al. Vascular retinal findings after COVID-19 vaccination in 11 cases: a coincidence or consequence? *Arq Bras Oftalmol.* 2022;85(2). doi:10.5935/0004-2749.20220071
51. Choi M, Seo MH, Choi KE, et al. Vision-threatening ocular adverse events after vaccination against coronavirus Disease 2019. *J Clin Med.* 2022;11(12):3318. doi:10.3390/jcm11123318
52. Peters MC, Cheng SSH, Sharma A, Moloney TP. Retinal vein occlusion following COVID -19 vaccination. *Clin Experiment Ophthalmol.* 2022;50(4):459–461. doi:10.1111/ceo.14056
53. Vujosevic S, Limoli C, Romano S, Vitale L, Villani E, Nucci P. Retinal vascular occlusion and SARS-CoV-2 vaccination. *Graefe's Arch Clin Exp Ophthalmol.* 2022;260(11):3455–3464. doi:10.1007/s00417-022-05707-5
54. Jampol LM, Tauscher R, Schwarz HP. COVID-19, COVID-19 vaccinations, and subsequent abnormalities in the retina. *JAMA Ophthalmol.* 2021;139(10):1135. doi:10.1001/jamaophthalmol.2021.3483
55. Green WR, Chan CC, Hutchins GM, Terry JM. Central retinal vein occlusion: a prospective histopathologic study of 29 eyes in 28 cases. *Retina.* 1981;1(1):27–55.
56. Frangieh GT, Green WR, Barraquer-Somers E, Finkelstein D. Histopathologic study of nine branch retinal vein occlusions. *Arch Ophthalmol.* 1982;100(7):1132–1140. doi:10.1001/archophth.1982.01030040110020
57. Kolar P. Risk factors for central and branch retinal vein occlusion: a meta-analysis of published clinical data. *J Ophthalmol.* 2014;2014:1–5. doi:10.1155/2014/724780

58. Leung HM, Au SCL. Retinal vein occlusion after COVID-19 vaccination—A review. *Vaccines*. 2023;11(8):1281. doi:10.3390/vaccines11081281
59. Almeheidi AM, Khoder G, Alchakee AS, Alsayyid AT, Sarg NH, Soliman SSM. SARS-CoV-2 spike protein: pathogenesis, vaccines, and potential therapies. *Infection*. 2021;49(5):855–876. doi:10.1007/s15010-021-01677-8
60. Greinacher A, Thiele T, Warkentin TE, Weisser K, Kyrle PA, Eichinger S. Thrombotic thrombocytopenia after ChAdOx1 nCov-19 vaccination. *N Engl J Med*. 2021;384(22):2092–2101. doi:10.1056/NEJMoa2104840
61. Schultz NH, Sørvoll IH, Michelsen AE, et al. Thrombosis and thrombocytopenia after ChAdOx1 nCov-19 vaccination. *N Engl J Med*. 2021;384(22):2124–2130. doi:10.1056/NEJMoa2104882
62. Dodson PM, Kubicki AJ, Taylor KG, Kritzing EE. Medical conditions underlying recurrence of retinal vein occlusion. *Br J Ophthalmol*. 1985;69(7):493–496. doi:10.1136/bjo.69.7.493
63. Ullah I, Sohail A, Shah MUFA, et al. Central retinal vein occlusion in patients with COVID-19 infection: a systematic review. *Ann Med Surg*. 2021;71:102898. doi:10.1016/j.amsu.2021.102898
64. Dorney I, Shaia J, Kaelber DC, Talcott KE, Singh RP. Risk of new retinal vascular occlusion after mRNA COVID-19 vaccination within aggregated electronic health record data. *JAMA Ophthalmol*. 2023;141(5):441. doi:10.1001/jamaophthalmol.2023.0610
65. Au CL. Prevalence of SARS-CoV-2 among central retinal vein occlusion patients. *Indian J Ophthalmol*. 2021;69(5):1355. doi:10.4103/ijo.IJO_88_21
66. Gupta AK, Lahiri KD. Subclinical hypothyroidism: a modifiable risk factor for retinal vein occlusion. *J Clin Diagn Res*. 2021;15(4). doi:10.7860/JCDR/2021/47113.14793
67. Madanagopalan VG, Paneer Selvam V, Sarath Sivan NV, Govindaraju NV. Central retinal vein occlusion in a patient with breast carcinoma. *GMS Ophthalmol Cases*. 2019;9:Doc04. doi:10.3205/oc000093
68. Castro-Navarro V, Odaibo SG, Ghodasra DH, Besirli CG. Bilateral BRVO in a patient with recurrent prostate cancer. *BMJ Case Rep*. 2015; bcr2015212463. doi:10.1136/bcr-2015-212463
69. Thomas RH. Hypercoagulability syndromes. *Arch Intern Med*. 2001;161(20):2433–2439. doi:10.1001/archinte.161.20.2433
70. Toft-Petersen AP, Muttuvolu DV, Heegaard S, Torp-Pedersen C. Correlation between retinal vein occlusion and cancer - a nationwide Danish cohort study. *Acta Ophthalmol*. 2018;96(8):800–803. doi:10.1111/aos.13860
71. Lee CS, Lee ML, Gibbons LE, et al. Associations between retinal artery/vein occlusions and risk of vascular dementia. *J Alzheimer's Dis*. 2021;81(1):245–253. doi:10.3233/JAD-201492
72. Li X, Burn E, Duarte-Salles T, et al. Comparative risk of thrombosis with thrombocytopenia syndrome or thromboembolic events associated with different covid-19 vaccines: international network cohort study from five European countries and the US. *BMJ*. 2022:e071594. doi:10.1136/bmj-2022-071594
73. Simpson CR, Shi T, Vasileiou E, et al. First-dose ChAdOx1 and BNT162b2 COVID-19 vaccines and thrombocytopenic, thromboembolic and hemorrhagic events in Scotland. *Nat Med*. 2021;27(7):1290–1297. doi:10.1038/s41591-021-01408-4
74. Simpson CR, Kerr S, Katikireddi SV, et al. Second-dose ChAdOx1 and BNT162b2 COVID-19 vaccines and thrombocytopenic, thromboembolic and hemorrhagic events in Scotland. *Nat Commun*. 2022;13(1):4800. doi:10.1038/s41467-022-32264-6
75. Li JX, Wang YH, Bair H, et al. Risk assessment of retinal vascular occlusion after COVID-19 vaccination. *NPJ Vaccines*. 2023;8(1):64. doi:10.1038/s41541-023-00661-7
76. Smadja DM, Yue QY, Chocron R, Sanchez O, Lillo-le Louet A. Vaccination against COVID-19: insight from arterial and venous thrombosis occurrence using data from VigiBase. *Eur Respir J*. 2021;58(1):2100956. doi:10.1183/13993003.00956-2021
77. Singh RB, Parmar UPS, Gupta R, et al. Retinal vascular occlusion following SARS-CoV-2 vaccination: a VAERS database analysis. *Ophthalmol Sci*. 2023;100354. doi:10.1016/j.xops.2023.100354
78. World Health Organization. Approved vaccines. COVID 19 Vaccine tracker; 2023. Available from: <https://covid19.trackvaccines.org/vaccines/approved/>. Accessed August 17, 2023.
79. Lam WY, Au SCL. Big data are needed for analysis of the association of retinal vascular occlusion and COVID-19. *Graefes Arch Clin Exp Ophthalmol*. 2023;261(9):2717–2718. doi:10.1007/s00417-023-06043-y

Clinical Ophthalmology

Dovepress

Publish your work in this journal

Clinical Ophthalmology is an international, peer-reviewed journal covering all subspecialties within ophthalmology. Key topics include: Optometry; Visual science; Pharmacology and drug therapy in eye diseases; Basic Sciences; Primary and Secondary eye care; Patient Safety and Quality of Care Improvements. This journal is indexed on PubMed Central and CAS, and is the official journal of The Society of Clinical Ophthalmology (SCO). The manuscript management system is completely online and includes a very quick and fair peer-review system, which is all easy to use. Visit <http://www.dovepress.com/testimonials.php> to read real quotes from published authors.

Submit your manuscript here: <https://www.dovepress.com/clinical-ophthalmology-journal>