

OPERATIVE TECHNIQUE

Arthroscopic Anatomical Acromioclavicular Joint Reconstruction using a Button Device and a Semitendinosus Graft

Carlos Maia Dias, MD^{1,2,3}, Maria João Leite, MD⁴ , Manuel Ribeiro da Silva, MD, PhD^{4,5}, Pedro Granate, MD^{1,2}, José Manuel Teixeira, MD^{6,7}

¹Hospital da Luz Lisboa and ²Unidade Cuidados Médicos de Acidentes Fidelidade Lisboa, Lisbon, ³Hospital CUF Santarém, Santarém, ⁴Centro Hospitalar Universitário São João, ⁵Hospital CUF Porto and ⁷Unidade Cuidados Médicos de Acidentes Fidelidade Porto, Porto and ⁶Hospital da Luz Arrábida, Vila Nova de Gaia, Portugal

Abstract

Objective: To report a new technique for anatomical acromioclavicular (AC) joint reconstruction.

Methods: In order to minimize such complications, the authors describe a new anatomical and biological AC joint repair. This technique aims to provide greater stability by using two anatomically placed clavicular tunnels and a combined construct with a double endobutton cortical fixation for primary stabilization, and to be biologically advantageous by using an autologous semitendinosus (ST) tendon graft. Additionally, the coracoclavicular ligament reconstruction is complemented with an AC joint cerclage and capsular reinforcement, which will protect the biological construction in its initial stage of healing.

Results: This technique provides adequate primary and secondary biomechanical stability by passing both a semitendinosus autogenous graft and a double endobutton device, through anatomically placed and small diameter clavicle holes, without the need for coracoid drilling. Our technique showed encouraging results regarding pain resolution, range of motion, and function. At final follow-up we experienced excellent results with average pain score of 1.6, and average ROM of 159° of forward flexion, 160° of abduction, 68° of external rotation, and internal rotation level at T11. Postoperative function also showed great improvements with average ASES of 85 points, an average Constant Score of 87 and a Subjective Shoulder Value of 89 points. This technique also achieved perfectly acceptable radiographic results, with an average coracoclavicular distance increase of 0.8 mm. Regarding complications, our sample showed one case of AC joint subluxation, two cases of internal saphenous nerve injury, and two partial graft tears at the suture-button interface, with none of these requiring surgical revision.

Conclusion: This technique is advantageous in treatment of acromioclavicular joint dislocation and can be performed in both the subacute and chronic setting.

Key words: Acromioclavicular joint dislocation; Arthroscopic; Coracoclavicular anatomical reconstruction

Introduction

Acromioclavicular (AC) joint dislocations represent a frequent condition, affecting a very specific and generally active population and accounting for around 9% of all shoulder

injuries¹. Controversy remains concerning surgical indication and stabilization technique for the treatment of these injuries, especially in the grade III acromioclavicular dislocations²⁻⁴. Although no gold standard treatment has been established, once

Address for correspondence Maria João Leite, MD, Alameda Professor Hernani Monteiro, Centro Hospitalar Universitário de São João, Serviço de Ortopedia e Traumatologia, Porto, Portugal 4200-319 Tel: 0351 913713591; Email: mjlcma@gmail.com

Disclosure: All authors, their immediate family, and any research foundation with which they are affiliated did not receive any financial payments or other benefits from any commercial entity related to the subject of this article.

Received 4 February 2021; accepted 20 December 2021

surgical treatment is advised, a tendency towards an arthroscopic approach has been noticed, which is demonstrated to be extremely safe and reliable¹. Furthermore, the arthroscopic acromioclavicular joint dislocation treatment showed many advantages, such as the possibility of diagnosis and treatment of intra-articular pathology¹. However, controversy remains concerning the most appropriated stabilization technique for the treatment of these injuries and over seventy-five different procedures have been described for this purpose, each with its own advantages and pitfalls²⁻⁴.

Another source of controversy regarding acromioclavicular dislocation treatment is the type of reconstruction. Anatomic studies emphasized the biomechanical importance of the coracoclavicular ligaments for vertical stability⁵⁻⁷, with some of the failures seen with isolated AC stabilization procedures attributed to CC ligaments non-healing. The Weaver–Dunn procedure tried to overcome this problem recreating vertical stability with a biological component⁸, however with discouraging results^{9,10}. The loss of AC joint congruence with the Weaver–Dunn procedure suggested that possibly the problem wasn't only biological⁸⁻¹⁰. Mazzoca¹¹ described the Anatomical Coracoclavicular Ligament Reconstruction (ACCR), that showed better mechanical properties, but did not address previously described problems, such as the risk of fracture or subsidence due to inadequate AC secondary fixation or graft distension¹².

Other authors^{13,14} have modified this technique by passing the graft around the coracoid and diminishing the diameter of the clavicle holes in order to minimize these complications and allow an anatomical reconstruction of the CC ligaments.

Regarding graft distention or secondary rupture, some authors also tried to associate a secondary synthetic fixation to increase the construct mechanical strength, in order to protect the graft¹⁵⁻¹⁷.

Furthermore, and despite significant evolution in fixation materials and techniques, postoperative loss of reduction is a concern, affecting up to 28% of operated patients¹². Considering all the risks inherent to these procedures, the authors developed an anatomic AC joint repair, using a combined double endobutton/autogenous-semitendinosus (ST) graft for coracoclavicular ligament reconstruction, that to our knowledge still has not been described.

This technique aims to be biomechanically stable first by recreating the local anatomy with anatomically placed clavicular tunnels, and secondly, by ensuring AC joint reduction and stable fixation with the endobutton construct, until the autogenous semitendinosus graft used for coracoclavicular ligament reconstruction has healed. As proposed by Weaver–Dunn procedure⁸, biology is important to ensure CC ligament healing and thereafter AC joint vertical stability restoration⁸⁻¹⁰. According to this principle⁸⁻¹⁰, this new technique has the advantage of using a combination of synthetic fixation for primary stabilization, provided by the double endobutton cortical fixation, and local biological support using the autologous semitendinosus graft. Besides that, the

anatomic reconstruction technique uses smaller diameter and anatomically placed clavicle bone tunnels to pass the fixation construct. This fact, in addition to the avoidance of the coracoid drilling, may help diminish the complication rate of this procedure by decreasing the risk of clavicle or coracoid fractures, which represents one of most critical complications of coracoclavicular reconstruction.

The objective of this technical note is to: (i) describe a technique to allow accurate reduction of the AC joint; (ii) ensure reproducible anatomic reconstruction of the coracoclavicular ligaments; and (iii) minimize loss of reduction following CC arthroscopic fixation by means of a stable and adequate fixation, and the addition of a biologic support to the coracoclavicular reconstruction.

Surgical Procedure

Technique Indications

Although this technique can be used in any AC joint dislocation to be treated surgically, it's especially advantageous in subacute or chronic AC joint dislocations after 3 weeks, when the healing potential of the native CC ligaments is diminished¹⁸.

Patient Positioning and Graft Preparation

The patient is anesthetized using a combined technique (general anesthesia and a regional brachial plexus block), positioned in dorsal decubitus, and the surgical team proceeds with the ST graft harvesting according to Colombet and Gravelau¹⁹.

The ST graft is prepared by passing two #2 Ultrabraid[®] (Smith&nephew, London, United Kingdom) Krackow or modified whipstitch sutures through the entire length of the

TABLE 1 Arthroscopy portals used during this technique

Portal	Description of the arthroscopic portals
Posterior	In the soft spot, 2 cm medial and inferior to the postero-lateral angle of the acromion
Antero-lateral (AL)	1–2 cm below the anterolateral acromion angle in line with the anterior border of the clavicle. Generally using a needle outside-in technique in order to prevent rotator cuff damage. The portal should be directed to the rotator cuff interval in its lateral frontier
Antero-medial (AM)	1 cm inferior and lateral to the coracoid process, also using an outside-in technique to allow direct access to the inferior, lateral and superolateral part of the coracoid process
Superior Coracoid (SC)	1 cm superior to the coracoid, slightly medial to it, also performed outside-in

Abbreviations: AL, antero-lateral portal; AM, antero-medial portal; SC, superior coracoid portal.

tendon, starting at each end of it. At this stage all the components that will slide in the bone tunnels (ST tendon + Endobutton system® [Smith&nephew, London, United Kingdom]) have their conjoined diameter measured using a cruciate ligament measurement device for that purpose.

The patient is then positioned in the beach chair position, and the arm draped and positioned in an arm holder (Trimano®, Maquet, Rastatt, Alemanha). Shoulder marking is then performed with generally four portals being used (Table 1).

Coracoid Space Debridement and Preparation

Using a 30° arthroscope, the joint is inspected through the posterior portal. Using the antero-lateral (AL) portal, the rotator interval is opened and the subcoracoid bursae is completely removed in order to expose the inferior and lateral part of the coracoid (Figures 1 and 2).

The antero-medial (AM) portal is then created, and the coracoid attachment of the coracoacromial and the

coracohumeral ligaments are detached, exposing the superior part of the coracoid.

Under direct visualization, either through the AL or AM portal, the superior-coracoid (SC) portal is created allowing the surgeon to perform a pectoralis minor partial tenotomy (Figure 3, Table 2).

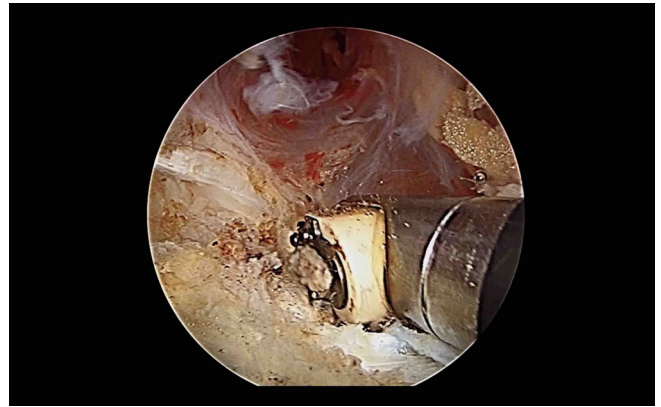


Fig. 3 Arthroscopic pectoralis minor tenotomy.

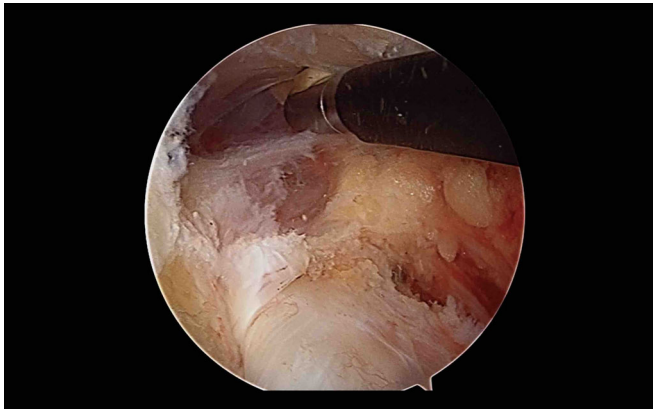


Fig. 1 Coracoid view from posterior portal during arthroscopic debridement.

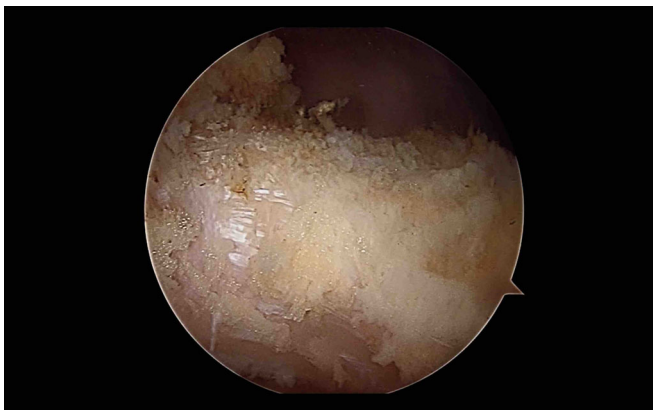

Fig. 2 Inferior, lateral, and superior coracoid fully exposed.

TABLE 2 Technique pearls and pitfalls

Technique pearls and pitfalls

- 1 After harvesting of the ST, fully suturing the tendon ends may minimize the risk of tendon rupture either by frictional wear or direct trauma by the buttons
- 2 The pectoralis minor partial tenotomy should not extend too far posteriorly to avoid a potential suprascapular nerve injury
- 3 The clavicle tunnels should not exceed 6 mm in diameter to prevent clavicle fracture. In order to minimize tunnel dimension, one can disassemble the double endobutton removing one of the buttons. By doing this, only the graft and tapes will be passed through the tunnels. If that is the case, at the end of the procedure, a Nice knot²⁰ is performed, to lock the system
- 4 Both for subcoracoid bursae removal, and to identify clavicle tunnels needle and suture, it is sometimes necessary to temporarily increase the pump pressure to increase visualization
- 5 Both clavicle drill holes should be slightly oriented towards the coracoid (30° anterior) to facilitate suture and graft retrieving, while lowering friction between the clavicle holes and the graft/suture
- 6 While the lateral clavicle drill hole is usually easy to identify, the more medial one might be trickier, for that reason it's adequate to try to find the medial clavicle drill hole suture first
- 7 When passing the graft, occasionally the assistant may need to use a suture retriever to facilitate the graft and sutures passage under the coracoid by slightly pulling the sutures downward from the AM portal
- 8 During direct AC joint fixation with the K wire, care should be taken not to trespass the lateral clavicle drill hole

Abbreviations: AC, acromioclavicular; AM, anteromedial portal; ST, semitendinosus.

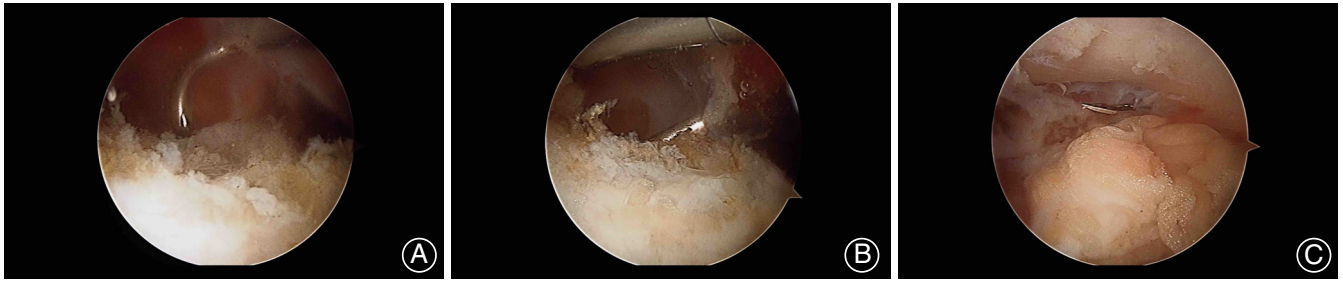


Fig. 4 Arthroscopic passage of the shuttle around the coracoid using a suture passer. (A) Suture shuttle passing over and medially to the coracoid. (B) Suture shuttle passing around coracoid. (C) Suture shuttle under the coracoid.

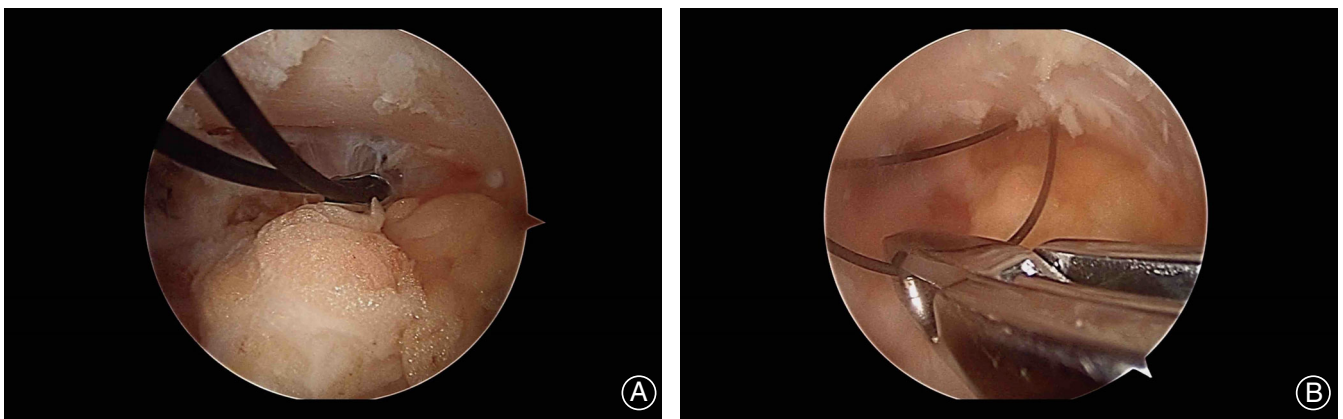


Fig. 5 Passage and retrieval of the suture shuttle for coracoclavicular reconstruction. (A) Suture under the coracoid. (B) Suture grasping from the antero-medial portal.

Through the SC portal, a 45° or 60° degree suture shuttle is passed under the coracoid, from a medial to lateral and superior to inferior fashion (Figure 4A–C), retrieving it from the AL or AM portal with a grasper (Figure 5A,B).

A loop of # 2 non-absorbable suture is then passed under the coracoid (Figure 6), that will later shuttle the graft and endobutton device.

Acromioclavicular Joint Preparation

The arthroscopic procedure is stopped, and a 6-cm supraclavicular incision centered over the AC joint is made, exposing the AC joint which is opened and cleaned of all debris (Figure 7). The distal clavicle should be preserved unless severe degenerative changes are present.

Coracoclavicular Ligament Reconstruction

Two bone tunnels are then created in the clavicle with 0.5 mm more than the previously measured diameter (ST + endobutton device) (Figure 8, Table 2). One of the drill holes should be centered over the clavicle 2–2.5 cm medial from its lateral border, and the other 4–4.5 cm medial to the previous mentioned reference, but in a slightly more posterior location²¹ (Table 2). Both drill holes should be angled

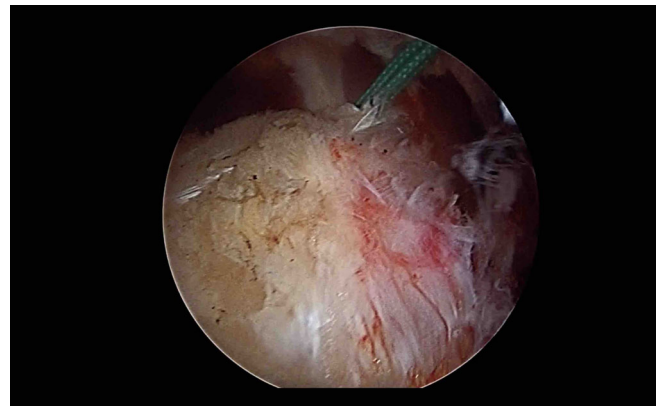


Fig. 6 # 2 nonabsorbable suture loop coming from underneath the coracoid to its medial border and into the superior coracoid portal.

30° anteriorly to allow a smoother graft passage and decrease its friction with the margins of the bone tunnel. The skin incision is then temporarily closed using two or three towel clips, in order to diminish fluid leakage and turbulence, but allowing the subsequent steps.

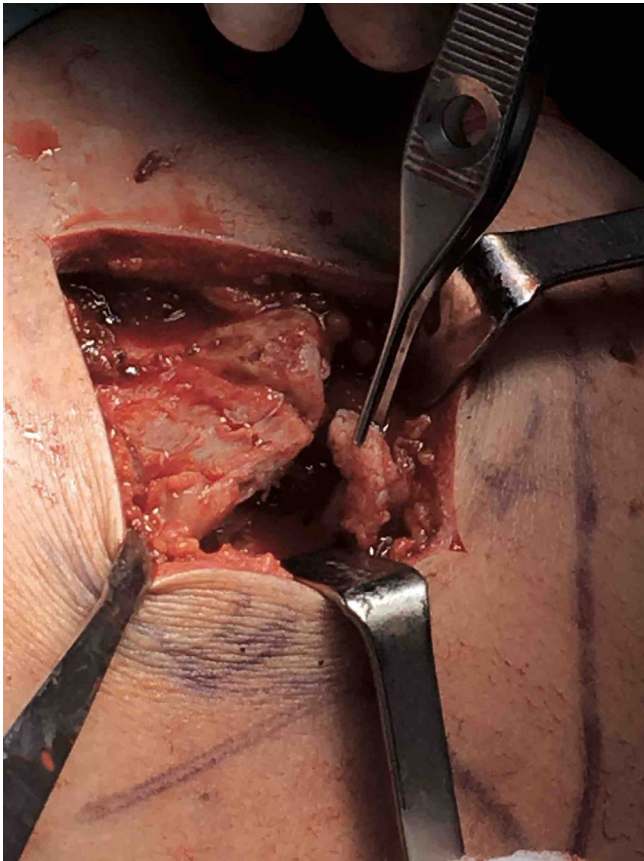


Fig. 7 Ac joint opened and being debrided. Notice the torn meniscus.

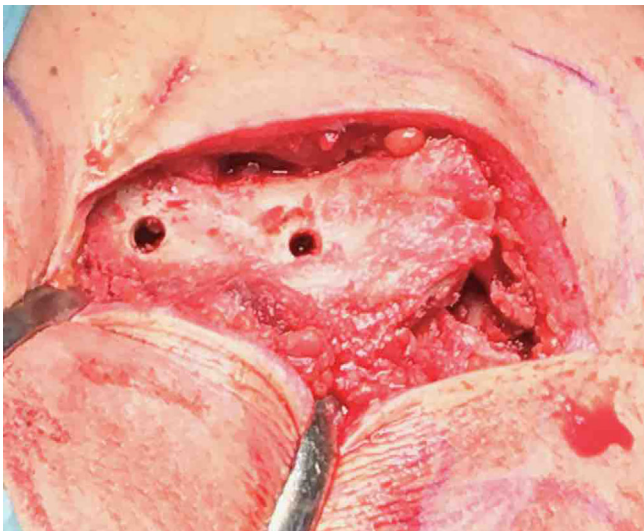


Fig. 8 Clavicle drill holes for anatomic reconstruction, done through the mini-open incision.

Arthroscopy is then resumed through the AL or AM portal, and a spinal needle passed through the drill holes, serving as a shuttle for a #1 nylon loop (Figure 9A).

At this stage it is crucial to identify the inferior border of the clavicle which can be accomplished using a switching stick for subclavicular atraumatic dissection (Table 2).

After correct identification of the medial clavicle hole suture, a suture retriever is used to collect both the suture from that drill hole and the medial sided limb of the #2 non-absorbable suture passed under the coracoid. The nylon loop is then pulled through the corresponding clavicle hole serving as a shuttle for the #2 non-absorbable suture (Figure 9B). The same gesture is performed for the lateral suture limb, rendering the #2 non-absorbable suture as the definitive shuttling suture.

The prepared tendon is then carefully passed together with the endobutton device and tapes, preferably from the medial clavicle drill hole to the lateral one and under the coracoid. In some larger diameter grafts, bathing both the graft and endobutton system in sterile lubricant gel may allow an easier passage.

Acromioclavicular Joint Reduction and Coracoclavicular Fixation

After this step (Figure 10), direct AC joint reduction is performed and a 2.0 K wire is used to maintain AC joint reduction (Table 2).

The graft is then pulled and tied over itself, leaving a larger medial end that will be laterally positioned and used for superior AC joint capsule and deltotrapezial fascia reinforcement (Figure 11).

The endobutton tapes are then pulled and tensioned, while AC joint reduction is confirmed using the image intensifier, and the K wire is slowly pulled back. If reduction is adequate, the double endobutton device tapes are fully tied, and the tendon is sutured to itself using a #2 vicryl for reinforcement.

Acromioclavicular Reconstruction

A figure of eight cerclage over the AC joint is added to increase horizontal stability, by making two 2.0-mm drill holes in the distal clavicle and lateral acromion in an anterior to posterior direction. Using the spinal needle as suture shuttle, a #2 Ultrabraid suture is passed through the drill holes, over the AC joint and then tied.

The remaining AC joint capsule is sutured, using the remaining tendon for reinforcement, and the deltotrapezial fascia carefully closed (Figure 12A,B).

All patients are included in a standardized rehabilitation protocol (Table 3).

Technique Preliminary Results

This technique was used in the treatment of 14 patients with grade 3, 4, and 5 chronic AC dislocation, between 2018 and 2020. At a mean follow-up of 7.2 months, our patient sample showed an average visual analogue pain score (VAS) of 1.6 (SD, 2.1). All regained close to normal range of motion, with no case of stiffness. Final follow-up range of motion assessment demonstrated a mean forward flexion of 159°

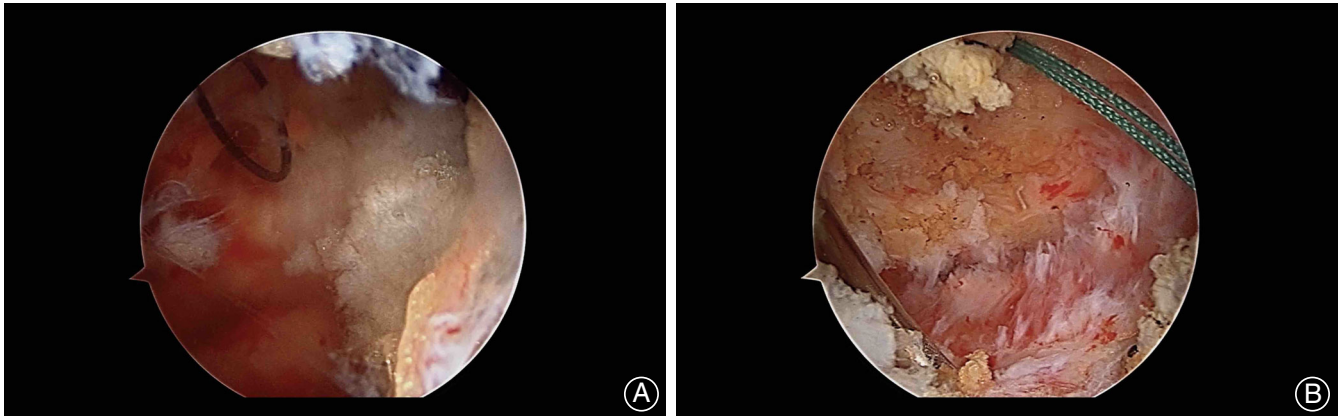


Fig. 9 Passage of the nonabsorbable suture through the clavicle holes. (A) Nylon loop coming from the medial clavicle hole. (B) Spinal needle coming from the lateral clavicle hole with the nonabsorbable suture shuttle already passed in the medial hole.

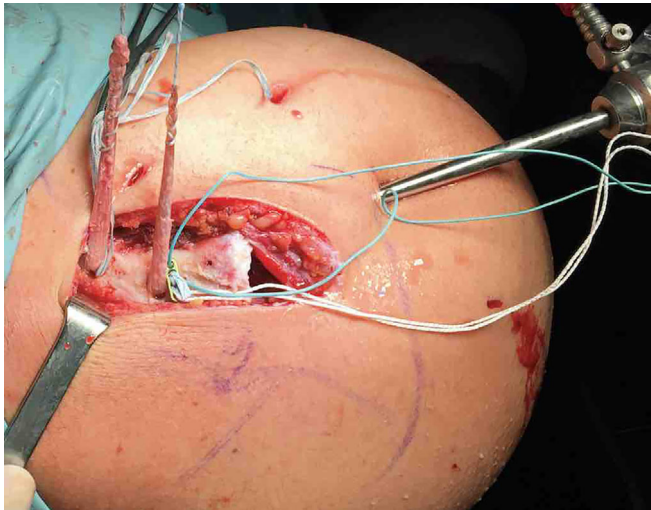


Fig. 10 Tendon and double endobutton device already passed underneath the coracoid and being prepared for final tying. Notice that the medial sided tapes have no button as it was disassembled to facilitate passage underneath the coracoid.

(SD, 6.4°), an external rotation of 68° (SD, 9.9°), an average internal rotation level at T₁₁, and a mean abduction of 160° (SD, 8.1°). Postoperative function was evaluated using the American Shoulder and Elbow Surgeons Shoulder (ASES) score, the Constant Score, and the Subjective Shoulder Value (SSV). A final ASES of 85 points (SD, 16.4 points), a Constant Score of 87 (SD, 16.6), and SSV of 89 points (SD, 8.9 points) were obtained.

Despite the above mentioned results, we also need to report some complications, namely one case of AC joint subluxation, two patients with internal saphenous nerve injury (no full recovery at follow-up), and two partial graft tears at the suture tendon interface (both of them were shortened and did not compromise final result, but those cases made us

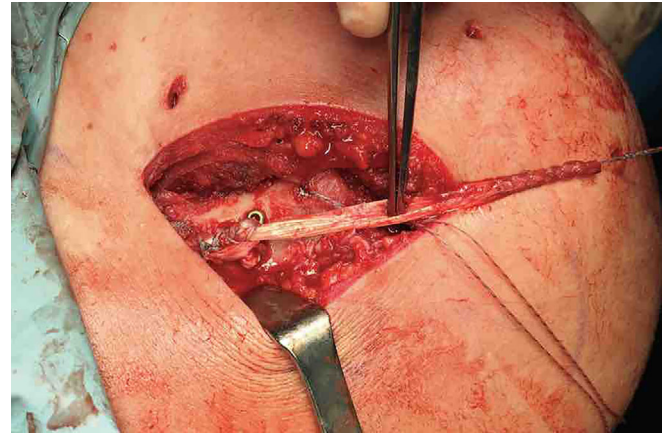


Fig. 11 Tendon and double endobutton assembly complete. Showing the possible superior acromioclavicular (AC) capsule reinforcement.

change our graft preparation to the one presented here, with which we have had no problems). None of the above-mentioned complications required any type of surgical revision.

Our radiographic outcomes demonstrated an average of 0.8-mm coracoclavicular distance increase when compared with the contralateral side (including the subluxation case).

Discussion

Acromioclavicular Reconstruction Challenges

AC joint repair is a constant source of debate in the orthopaedic community, with several specific complications described and believed to be somewhat unavoidable, ranging from biomechanical problems to biologic failure.

The loss of AC joint congruence with the Weaver-Dunn procedure⁹⁻¹² suggested that possibly the problem wasn't only biological. Also, other techniques using single

Fig. 12 Final construct scheme, showing the AC and CC reconstruction. (A) The final aspect of the reconstruction from a superior view showing the double endobutton system (black device and light blue tapes), the autogenous graft (yellow), and the AC joint cerclage (dark blue). (B) The final aspect of the reconstruction from an anterior view showing the double endobutton system (black device and light blue tapes), the autogenous graft (yellow), and the AC joint cerclage (dark blue).

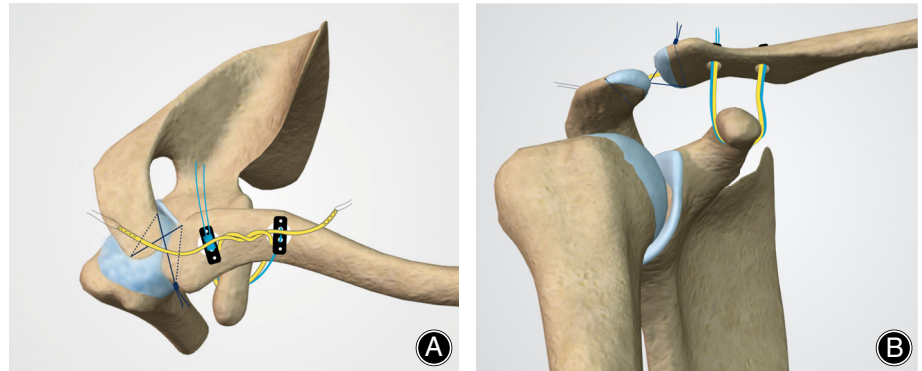


TABLE 3 Rehabilitation protocol

Post-op week	Rehabilitation protocol
0–2nd week	Use of protective sling
2nd week	Start passive internal and external rotation exercises with elbow support
4th week	The sling is progressively abandoned, patients start a self-rehabilitation program as described by Liotard ²² . In compliant patients, physical therapy may be started at this stage to maximize passive range of motion and scapular control acquisition
6th–7th week	Active assisted movements may only be commenced
12th week	Rotator cuff and deltoid strengthening is recommended

tunnel CC reconstruction with autogenous autograft resulted in loss of reduction in 47% of patients²³, confirming that probably the problem was also related to the location and orientation of the grafted CC ligaments.

Spencer²⁴ compared four surgical techniques, with the best results reported in the coracoclavicular fixation with allograft loop plus synthetic cortical button fixation group, demonstrating some advantage in combining a biological and synthetic reconstruction.

Technique Advantages

Having this in mind, the authors developed a surgical technique that is both biomechanically stable, by using anatomically placed clavicular tunnels and a combined construct with a double endobutton cortical fixation for primary stabilization, and biologically advantageous using an autologous tendon graft.

This technique also minimizes the risks of coracoid and clavicle fracture, the first by not drilling it and the later by performing low diameter and anatomically placed tunnels.

There seem to be some advantages with the new described technique:

- i. By using both a synthetic and biological fixation, in theory, the initial stabilization provided by the endobutton

TABLE 4 Key surgical steps

Key surgical steps
1. Safe tendon harvesting and fully sutured tendon graft (sutured throughout graft)
2. Tendon and double endobutton device diameter measurement and assessment of ease of passage. Allow extra 0.5 mm to avoid complications with tendon and tape sliding
3. Inspect the joint and address concomitant injuries
4. Adequate coracoid exposition using both anterior portals for viewing
5. Pectoralis minor tenotomy with direct visualization of the medial border of the coracoid
6. Using a 45° angled suture passer, transport it from medial to lateral under the coracoid. A suture retriever coming from one of the anterior portals available captures the lasso suture
7. Use the lasso suture to transport a #2 non absorbable suture under the coracoid
8. Ensure that clavicle drill holes are correctly placed and if in doubt perform it slightly more laterally. Drill holes should be oriented inferior and slightly anteriorly towards the coracoid
9. Use a switching stick from one of the anterior portals to expose the inferior clavicle and allow adequate visualization of the suture shuttles coming from the clavicle drill holes
10. After pulling the nonabsorbable suture located under the coracoid to the clavicle holes, use it as a shuttle for both the tendon and the double endobutton system/tapes
11. If needed, disassemble the button that has the knot so that only suture tapes are passed in the bone tunnels and under the coracoid
12. Assistance may be required to pull the graft and tapes downward when it is under the coracoid
13. AC opening, cleaning, reduction, and provisional stabilization with 2.0 K wire. If even after AC joint cleaning and meniscus excision, anatomical reduction is not possible, check for deltotracheal fascia incarcerating the clavicle
14. Tendon tensioning, tying and side-to-side stitching, followed by double endobutton device tying with a Nice knot
15. AC joint cerclage and superior capsule reinforcement, followed by deltotracheal fascia repair

Abbreviation: AC, acromioclavicular.

system allows the graft to adapt to its position without excessive tension and also allows its bone integration in the clavicle, rendering a more reliable biologic long-term stability.

- ii. By having a biological and synthetic fixation, stability is increased at time 0, which can minimize the risk of cheese-wiring and coracoid fracture.
- iii. The addition of the AC cerclage, tendon reinforcement²⁵ and deltotrapezial fascia reconstruction can minimize the risk of anterior-posterior graft translation²⁶ and residual instability⁶.
- iv. Part of the technique described is arthroscopically performed, maximizing the diagnostic capability²⁷ and reducing surgery induced comorbidity.
- v. Our technique's preliminary results showed potential gains in pain management, range of motion, and function, with excellent results at final follow-up and perfectly acceptable radiographic results, despite some complications that mandated us to make some technical refinements that are already reported in this paper.

Technique Disadvantages

Nonetheless, this technique also has some pitfalls that cannot be understated:

- i. It's a complex procedure with several key steps (Table 4) that need to be adequately followed to ensure easy graft

sliding and avoidance of graft rupture. These sequential procedures also guarantee that the graft is stabilized with the AC joint in its anatomic position. It's important to understate that the graft should be tied to itself before the endobutton system is locked because if the opposite occurs, graft rupture can occur because after button locking, the tendon gets frequently compressed to the clavicle by the buttons (which adds additional stability).

- ii. It can be a time-consuming procedure especially due to graft harvesting and patient positioning. However, this can be minimized using an allograft, which can also overcome issues related to donor site morbidity.

Conclusion

In conclusion, this technique seems to be especially advantageous as it allows for an anatomic, biological, and minimally invasive procedure while avoiding some of the inconveniences described in other reports. Although demanding, it can be reproducibly performed arthroscopically, and good clinical outcomes should be expected.

References

1. Mazzocca A, Arciero A, Bicos J. Evaluation and treatment of acromioclavicular joint injuries. *Am J Sports Med.* 2007;35:316–29.
2. Ceccarelli E, Bondi R, Alviti F. Treatment of acute grade III acromioclavicular dislocation: a lack of evidence. *J Orthop Traumatol.* 2008;9:105–8.
3. Rolf O, Hann von Weyhern A, Ewers A, Boehm T, Gohlke F. Acromioclavicular dislocation Rockwood III-V: results of early versus delayed surgical treatment. *Arch Orthop Trauma Surg.* 2008;128:1153–7.
4. Tamaoki MJ, Belloti JC, Lenza M, Matsumoto M, Santos J, Faloppa F. Surgical versus conservative interventions for treating acromioclavicular dislocation of the shoulder in adults. *Cochrane Database Syst Rev.* 2010;4:CD007429.
5. Fukuda K, Craig E, An K, Cofield R, Chao E. Biomechanical study of the ligamentous system of the acromioclavicular joint. *J Bone Joint Surg Am.* 1986; 68:434–40.
6. Debsky R, Parsons I, Woo S, Fu H. Effect of capsular injury on acromioclavicular joint mechanics. *J Bone Joint Surg Am.* 2001;83-A: 1344–51.
7. Jari R, Costic R, Rodosky M, Debksi R. Biomechanical function of surgical procedures for acromioclavicular joint dislocations. *Art Ther.* 2004;20: 237–45.
8. Weaver J, Dunn H. Treatment of acromioclavicular injuries, especially complete acromioclavicular joint separation. *J Bone Joint Surg.* 1972;54-A: 1187–94.
9. Tienen T, Oyen J, Eggen P. A modified technique of reconstruction for complete acromioclavicular dislocation. *Am J Sports Med.* 2003;31: 655–9.
10. Martetschlager F, Woran M, Warth R, Millett P. Complications after anatomic fixation and reconstruction of the coracoclavicular ligaments. *Am J Sports Med.* 2013;41:2896–903.
11. Mazzocca A, Santangelo S, Johnson S, Rios C, Dumonski M, Arciero R. A biomechanical evaluation of an anatomical coracoclavicular ligament reconstruction. *Am J Sports Med.* 2006;34:236–46.
12. Weinstein D, McCann P, McIlveen S, Flatow E, Bigliani L. Surgical treatment of complete acromioclavicular dislocations. *Am J Sports Med.* 1995; 23:324–31.
13. Millett PJ, Horan MP, Warth RJ. Two-year outcomes after anatomic coracoclavicular ligament reconstruction. *Art Ther.* 2015;31:1962–73.
14. Beitzel K, Cote M, Apostolakis J, et al. Current concepts in the treatment of acromioclavicular joint dislocations. *Art Ther.* 2013;29:387–97.
15. Natera L, Reiris J, Abat F. Anatomic reconstruction of chronic coracoclavicular ligament tears: arthroscopic-assisted approach with nonrigid mechanical fixation and graft augmentation. *Arthrosc Tech.* 2014;15:e583–8.
16. Frank R, Trenhaile S. Arthroscopic-assisted acromioclavicular joint reconstruction using the tight rope device with allograft augmentation: surgical technique. *Arthrosc Tech.* 2015;4:e293–7.
17. Takase K, Yamamoto K. Arthroscopic procedures and therapeutic results of anatomical reconstruction of the coracoclavicular ligaments for acromioclavicular joint dislocation. *Orthop Traumatol Surg Res.* 2016;102:583–7.
18. Maier D, Tuecking L, Bernstein A, et al. The acromioclavicular ligament shows an early and dynamic healing response following acute traumatic rupture. *BMC Musculoskelet Disord.* 2020;21:593.
19. Colombet P, Graveleau N. Minimally invasive anterior semitendinosus harvest: a technique to decrease saphenous nerve injury. *Arthrosc Tech.* 2016;5: e139–42.
20. Boileau P, Alami G, Rumian A, Schwartz D, Trojani C, Seidl A. The doubled-suture nice knot. *Orthopedics.* 2017;40:e382–6.
21. Rios C, Arciero R, Mazzocca A. Anatomy of the clavicle and coracoid fractures process for reconstruction of the coracoclavicular ligaments. *Am J Sports Med.* 2007;35:811–7.
22. Liotard J. Rééducation d'une épaule douloureuse: comment faire simple. *Rev du Rhum Monogr.* 2010;77:239–45.
23. Choi N, Lim S, Lee S, Lim T. Loss of reduction and complications of coracoclavicular ligament reconstruction with autogenous tendon graft in acute acromioclavicular dislocations. *J Shoulder Elbow Surg.* 2017;26:692–8.
24. Spencer H, Hsu L, Sodl J, Arianjam A, Yian E. Radiographic failure and rates of re-operation after acromioclavicular joint reconstruction – a comparison of surgical techniques. *Bone Joint J.* 2016;98-B:512–8.
25. Naziri Q, Williams N, Hayes W, Kapadia B, Chatterjee D, Urban W. Acromioclavicular joint reconstruction using a tendon graft: a biomechanics study comparing a novel “sutured throughout” tendon graft to a standard tendon graft. *SICOT J.* 2016;2:17.
26. Yoo Y, Tsai A, Ranawat A, et al. A biomechanical analysis of the native coracoclavicular ligaments and their influence on a new reconstruction using a coracoid tunnel and free tendon graft. *Art Ther.* 2010;26:1153–61.
27. Pauly S, Kraus N, Greiner S, et al. Prevalence and pattern of glenohumeral injuries among acute high-grade acromioclavicular joint instabilities. *J Shoulder Elbow Sure.* 2013;22:760–6.