

CASE REPORT

A Rare Case of De Novo Gigantic Ovarian Abscess within an Endometrioma

Aisha Hameed, MRCOG^{a*}; Vaishali Mehta, MBBS^b; and Prabha Sinha, FRCOG, MRCP^c

^aBrighton and Sussex University Hospitals, Royal Sussex County Hospital, Brighton, UK; ^bAshford and St. Peter's Hospitals, Ashford, UK; ^cConquest Hospital, St. Leonards-on-Sea, East Sussex, UK

We are reporting a rare case of de novo ovarian abscess in an endometrioma. Ovarian abscess within an endometrioma is a rare gynecological problem, but de novo abscess in the endometrioma is even rarer. Most of the ovarian abscesses develop in the endometriomas following interventions, e.g., aspiration, pelvic surgery, and oocyte retrieval. We are presenting a case of a spontaneous giant abscess in a large ovarian cyst in a nulliparous woman who presented with acute abdomen. Patient was treated in a district general hospital with multidisciplinary approach. Thirteen liters of the pus were drained. She has had a sub total (supra cervical) hysterectomy and bilateral salpingo-oophorectomy (BSO†) performed. Histology of the abscess wall confirmed endometriotic nature of the cyst. Patient made an uneventful recovery and was discharged home on the 14th postoperative day. This case highlights that endometrioma and its complication can present as a surgical emergency and should be dealt as one.

CASE REPORT

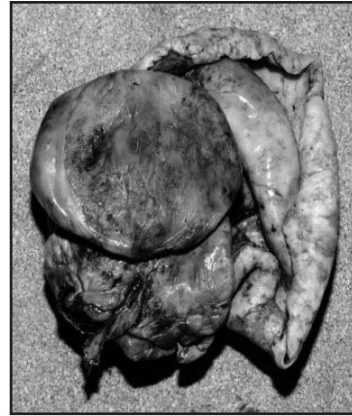
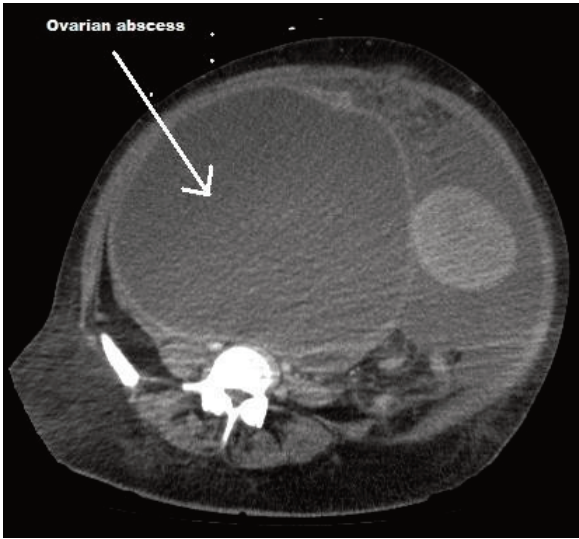
A 47-year-old nulliparous woman with a two-week history of increasing abdominal girth and a two-day history of fever was brought to the Accident and Emergency department via an ambulance. She had no previous significant medical or surgical history. She was a nonsmoker and was in a stable relationship. There was no history of sexually transmitted disease, nor had she

ever used an intra-uterine copper device. She did not have any previous gynecological problems. On examination, her temperature was 38.5 C, pulse was 113 beats per minute, and blood pressure was 76/46 mm of Hg. She appeared pale, clammy, and cachectic. Her abdomen was grossly distended and tense, and a large mass was felt on the right side. The whole abdomen was generally tender, and bowel sound was not

*To whom all correspondence should be addressed: Dr. Aisha Hameed, specialist trainee, Brighton and Sussex University Hospitals, Royal Sussex County Hospital, Eastern Road BN2 5BE, Brighton, United Kingdom. E-mail: aishadr@gmail.com.

†Abbreviations: BSO, bilateral salpingo-oophorectomy; TAH, total abdominal hysterectomy; ASRM, American Society for Reproductive Medicine.

Keywords: endometrioma, ovarian abscess, supra-cervical subtotal abdominal hysterectomy



At right, extent of ovarian abscess on computerized tomography. Above, gross appearance of right endometriotic cyst wall.

audible. A large umbilical hernia was noted. Hemoglobin was 7.8 g/dl, WBC was 21.7, and CRP was 205. A chest X-ray showed clear lung fields, and an abdominal X-ray raised the possibility of extensive intra-abdominal fluid. CT showed a large ovarian mass — 33x23 cm — and large ascites. Left ureter was obstructed. Possible diagnosis was malignant ovarian mass with super imposed infection. She was started on cefuroxime and Metronidazole. Surgeons and gynecologist jointly decided to perform a laparotomy; patient was consented for a total abdominal hysterectomy (TAH), BSO, and repair of umbilical hernia.

A mid-line laparotomy was performed. Six liters of pus were aspirated from the abdominal cavity before any structure was visualized. A large cystic mass originating from the right adnexa and extending to the right hemi diaphragm was seen. Both tubes were edematous. Further, five liters of thick pus were drained from this ovarian cyst. Necrosis was inside the cavity wall. The uterus was large, with multiple fibroids measuring approximately 20 weeks of gestation. Subtotal (supra cervical) hysterectomy was carried out. The left ovary was adherent to the posterior pelvic wall with endometriotic cysts; it was removed as much as possible. Hernial sac was excised, and hernia was repaired. There was no apparent bowel perforation, and appendix was normal. Abdominal wash out with saline was performed, two drains were

inserted, and mass closure of the abdomen was performed. Estimated blood loss was one liter. She was admitted to intensive care post-operatively for the maximum ventilatory and inotropic cardiac support. Over the next 72 hours, she received six units of blood transfusion. On second postoperative day, decision of early tracheostomy was taken, as long-term weaning was expected.

Pus culture grew *Bacteroids fragilis*. No other bacteria, including *Mycobacterium* species, grew from the blood or pus culture. Antibiotics were changed to Tazocine 4.5g TDS as her inflammatory markers were rising, although she became afebrile after the laparotomy. She remained on antibiotics for 10 days.

Histology of the uterus confirmed multiple fibroids. Right ovarian cyst wall showed marked inflammation, and there were glandular foci in the cyst wall representing endometriosis origin. In addition, endometriosis was identified on the surface of this ovary. Endometriotic cyst was confirmed in the left ovary as well.

After the procedure, she started to improve. CRP was 33 on the fourth postoperative day. She made good recovery and was discharged home on the 14th postoperative day.

DISCUSSION

Gary H et al. in 1991 published the first case of spontaneous abscess in the en-

ometrioma, which was possibly a result of a hematogenous spread from the urinary tract. There are a few more case reports after this case, but none presented as an acute abdomen so initially were managed conservatively [1,2].

There are different theories about developing an abscess in the endometrioma. It may be due to an altered immune environment within endometrial glands and stroma. Collection of altered menstrual type of blood in a cystic space in the ovary can be a suitable culture medium for pathogens. Cystic wall of endometrioma is theoretically weak as compared to normal ovarian epithelium, so it is susceptible to bacterial invasion. A retrospective study in Japan concluded that incidence of tubo-ovarian abscess was 2.3 percent in patient with endometrioma and 0.2 percent in patient without endometrioma ($p = 0.0001$) [3]. The same authors found that there were only two cases of isolated ovarian abscess, and both were associated with endometrioma. These findings were confirmed by Chen M J et al. after studying 6,228 patients (OR 2.95, $P < 0.001$). The American Society for Reproductive Medicine (ASRM) found stages III and IV of endometriosis to be a risk factor for tubo-ovarian abscess formation [4]. Nulliparity is one of the major risk factors for developing ovarian abscess in the advanced stages of endometriosis [4].

In our case, patient has no known previous history of pelvic inflammatory disease, IUCD, or any surgical intervention, so she was very unlikely to present with ovarian abscess. It shows that an isolated ovarian abscess can develop in an endometrioma without any recognized risk factor.

Our patient suffered from primary infertility, which was never investigated, so we do not know how long she was suffering from endometriosis. When she was seen in Accident and Emergency, it was her first encounter with a gynecologist. We hypothesize that the abscess might have developed in the endometrioma by an ascending infection from the vaginal canal, as bacteroides are the normal commensals of the vagina. The abscess might have leaked inside the peritoneal cavity, creating peritonitis, sepsis, and the symptoms that brought the patient to the emergency department. This case also has highlighted that ovarian abscess can present as an acute gynecological/surgical emergency. High index of suspicion, prompt imaging, antibiotic cover, and timely drainage of abscess was the key to the successful management of this patient.

Acknowledgment: We thank our patient, who gave us permission to report the case.

REFERENCES

- 1- El-Toukhy T, Hanna L. Spontaneous ovarian abscess associated with an endometrioma. *J Obstet Gynaecol.* 2007;27:328-9.
- 2- Kavoussi SK, Pearlman MD, Burke WM, Lebovic DI. Endometrioma complicated by tubo-ovarian abscess in a woman with bacterial vaginosis. *Infect Dis Obstet Gynecol.* 2006;2006:84140.
- 3- Kubota T, Ishi K, Takeuchi H. A study of tubo-ovarian and ovarian abscesses, with a focus on cases with endometrioma. *J Obstet Gynaecol Res.* 1997;23:421-6.
- 4- Chen MJ, Yang JH, Yang YS, Ho HN. Increased occurrence of tubo-ovarian abscesses in women with stage III and IV endometriosis. *Fertil Steril.* 2004;82:498-9.