

Review

What Should We Do after the COVID-19 Vaccination? Vaccine-Associated Diseases and Precautionary Measures against Adverse Reactions

Toru Awaya ^{*}, Masao Moroi, Yoshinari Enomoto , Taeko Kunimasa and Masato Nakamura 

Department of Cardiovascular Medicine, Toho University Ohashi Medical Center, 2-22-36, Ohashi Meguro-ku, Tokyo 153-8515, Japan; moroi@med.toho-u.ac.jp (M.M.); yenomo1225@oha.toho-u.ac.jp (Y.E.); taesan@live.jp (T.K.); masato@oha.toho-u.ac.jp (M.N.)

* Correspondence: tooru.awaya@med.toho-u.ac.jp; Tel.: +81-334-681-251

Abstract: COVID-19 vaccines have been used to counteract the global COVID-19 pandemic. While these are effective, adverse reactions have been reported, such as injection-site pain, muscle ache, fever, palpitation, and chest discomfort. The release of inflammatory cytokines, such as interleukin (IL)-6 and IL-1 β , is a potential mechanism for post-vaccine side-effects. Chest discomfort after the vaccination, including myocarditis and acute coronary syndrome, is a particularly serious adverse reaction. It is important to be familiar with the differential diagnoses of chest discomfort and organ-specific diseases associated with COVID-19 vaccines as the preparation for booster shots and vaccinations among children aged 5–11 years begins. High-intensity exercise, alcohol, tobacco smoking, and baths promote inflammatory cytokines, such as IL-6, which may exacerbate the adverse reactions after vaccination. Japanese data show that deaths during baths are the most common for several days after mRNA vaccination. Additionally, alcohol and tobacco smoking were identified as predictive factors of lower antibody titers after vaccination. In this review, we aimed to provide a few recommendations to prevent vaccine-associated disease.

Keywords: COVID-19 vaccination; cardiovascular diseases; vaccine-associated diseases; adverse reaction; inflammatory cytokine; autoimmunity; lipid nanoparticles; precautionary measures; exercise; taking a bath



Citation: Awaya, T.; Moroi, M.; Enomoto, Y.; Kunimasa, T.; Nakamura, M. What Should We Do after the COVID-19 Vaccination? Vaccine-Associated Diseases and Precautionary Measures against Adverse Reactions. *Vaccines* **2022**, *10*, 866. <https://doi.org/10.3390/vaccines10060866>

Academic Editor: Nicolaas A. Bos

Received: 5 May 2022

Accepted: 25 May 2022

Published: 28 May 2022

Publisher's Note: MDPI stays neutral with regard to jurisdictional claims in published maps and institutional affiliations.



Copyright: © 2022 by the authors. Licensee MDPI, Basel, Switzerland. This article is an open access article distributed under the terms and conditions of the Creative Commons Attribution (CC BY) license (<https://creativecommons.org/licenses/by/4.0/>).

1. Introduction

In Japan, four COVID-19 vaccines have been approved for public use, namely, the Pfizer-BioNTech (BNT162b2) messenger RNA (mRNA) vaccine, Moderna (mRNA-1273) mRNA vaccine, Oxford/AstraZeneca (ChAdOx1 nCoV-19) adenovirus vectored vaccine, and Novavax (NVXCoV2373) recombinant spike protein nanoparticle vaccine [1,2]. The post-vaccine symptoms often last 1–2 days following the injection [3]. Adverse reactions are more frequently reported in younger individuals, women, individuals who have received the second dose, and individuals with a history of COVID-19 infection [3,4]. The most common systemic reactions, such as muscle aches (69.1%), headaches (48.7%), fever (32.1%), chest discomfort (3.0%), etc., have been reported after the second dose of the BNT162b2 mRNA vaccine [3,4]. The reported rates of serious adverse reactions, including deaths per million doses of mRNA vaccines, are as follows: death was 15, coagulopathy was 14.5, seizure was 9.1, stroke was 6.5, Bells' palsy was 6.4, anaphylaxis was 5.5, myocarditis was 4.4, acute coronary syndrome (ACS) was 3.7, appendicitis was 1.3, and Guillain-Barré syndrome (GBS) was 1.0 [5]. Yeo et al. reported that the second post-vaccination (60.6%) occurs more often than the first vaccination (39.4%) in the death cases [6].

Inflammatory cytokines release [7–10], autoimmunity involvement [11–19], eosinophil association [20–25], and angiotensin-converting enzyme 2 (ACE2) downregulation [26,27]

have been suggested as contributing etiologies of post-vaccine adverse reactions. Inflammatory cytokines, including interleukin (IL)-6 and IL-1 β , are released due to lipid nanoparticles (LNPs) within the mRNA vaccine [9]. The COVID-19 mRNA vaccine encodes the SARS-CoV-2 spike protein, which triggers IL-1 β secretion in macrophages [28]. Not only were immunostimulatory cytokines such as interferon (IFN)- γ released, but inflammatory cytokines were also released, especially following the second vaccination [10].

High-intensity exercise promotes the release of inflammatory cytokines [29]. Drinking alcohol, smoking tobacco, and baths can also increase inflammatory cytokines release [30–32]. In Singapore, individuals are advised against strenuous exercise after vaccination [33]. In Japan, deaths while taking a bath have been reported to occur within one week after mRNA vaccination [34,35] (Figure 1).

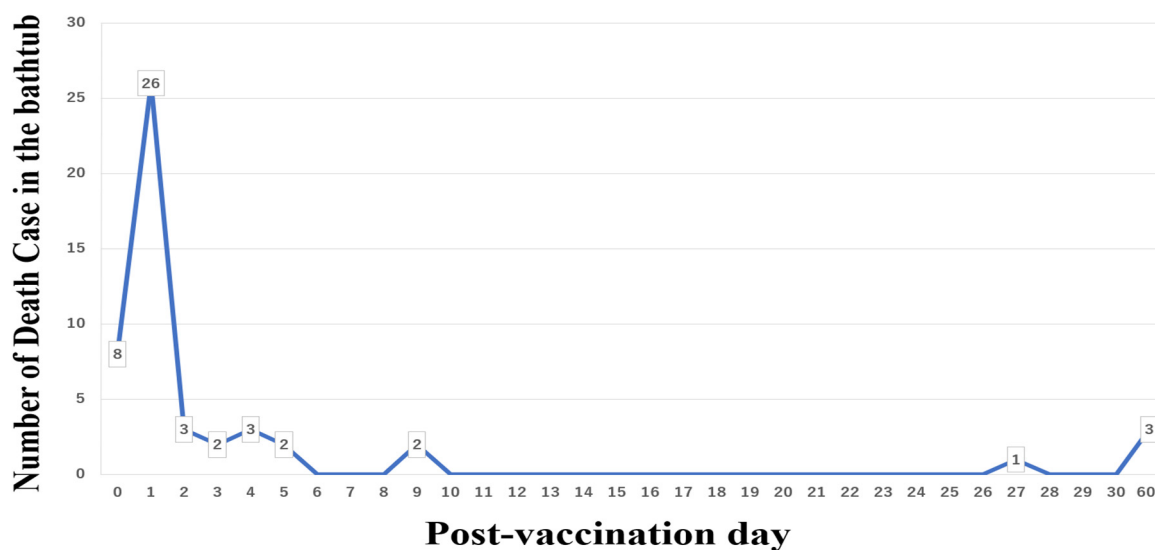


Figure 1. Deaths while sitting in the bathtub after COVID-19 mRNA vaccination.

In this review, we summarized the diseases associated with the COVID-19 vaccines (Table 1) and recommended several precautions to be taken post-vaccination, including limiting high-intensity exercise, alcohol use, tobacco smoking, and baths.

Table 1. Organ-specific diseases associated with the COVID-19 vaccines.

1. Cardiovascular diseases	6. Skin diseases
Acute coronary syndrome (ACS)	Alopecia areata (AA)
Aortic dissection (AD)	Bullous pemphigoid
Arrhythmia	COVID arm
Heart failure (HF)	Eosinophilic cellulitis (EC)
Myocarditis/Pericarditis	Eosinophilic panniculitis (EP)
Pulmonary embolism (PE)	Erythema multiforme (EM)
Takotsubo cardiomyopathy (TCM)	Herpes zoster (skin, oral and facial palsy)
Vasospastic angina (VSA)	Leukocytoclastic vasculitis
2. Respiratory diseases	Non-episodic angioedema with eosinophilia
Asthma attack	Psoriasis
Diffuse alveolar hemorrhage (DAH)	Pyoderma gangrenosum (PG)
Eosinophilic pneumonia (EP)	Steven-Johnson syndrome (SJS)
Interstitial lung disease (ILD)	Subacute cutaneous lupus erythematosus (SCLE)
Sarcoidosis	Urticaria

Table 1. Cont.

3. Gastroenterological diseases	7. Endocrine diseases
Appendicitis	Graves' Disease
Autoimmune hepatitis (AIH)	Hypophysitis
Bleeding duodenal ulcer	Hypothyroidism
Intestinal obstruction/perforation	Syndrome of inappropriate antidiuresis (SIADH)
Mesenteric ischemia	Type 1 diabetes mellitus
Pancreatitis	Thyroiditis (painful, silent, subacute)
4. Renal diseases	8. Collagen diseases
Acute rejection of kidney transplant	Anti-neutrophil cytoplasmic antibody (ANCA)-associated vasculitis
IgA nephropathy	Antiphospholipid syndrome (APS)
IgG4 nephritis	Dermatomyositis (DM)
Membranous nephropathy (MN)	Eosinophilic granulomatosis (EGPA)
Minimal change disease (MCD)	Giant cell arteritis (GCA)
Renal thrombotic microangiopathy	Polymyalgia rheumatica (PMR)
Scleroderma renal crisis	Rheumatoid arthritis (RA)
Vasculitis	Systemic lupus erythematosus (SLE)
5. Neurological diseases	Systemic sclerosis (SSc)
Acute disseminated encephalomyelitis (ADEM)	9. Hematologic diseases
Acute hemorrhagic leukoencephalitis (AHEM)	Aplastic anemia (AA)
Acute meningoencephalitis	Acquires hemophilia A (AHA)
Bells' palsy	Autoimmune hemolytic anemia (AIHA)
Cerebral hemorrhage (CH)	Hemophagocytic lymphohistiocytosis (HLH)
Cerebral infarction (CI)	Immune thrombocytopenia (ITP)
Cerebral venous sinus thrombosis (CVST)	Vaccine-induced immune thrombotic thrombocytopenia (VITT)
Chronic inflammatory demyelinating polyneuropathy (CIDP)	10. Others
Guillain–Barré syndrome (GBS)	Abnormal menstrual cycle
Multiple sclerosis (MS)	Anaphylaxis
Myasthenia gravis (MG)	Gout flares
Neuromyelitis optica spectrum disorder (NMOSD)	Lymphadenopathy
Parsonage–Turner syndrome (Neuralgic amyotrophy)	Rhabdomyolysis
Subarachnoid hemorrhage (SAH)	Shoulder injury related to vaccine administration (SIRVA)
Thrombophlebitis	Vogt-Koyanagi-Harada syndrome
Transverse myelitis	

2. Organ-Specific Diseases Associated with the COVID-19 Vaccines

2.1. Cardiovascular Diseases

Various cardiovascular diseases have been reported to be associated with the COVID-19 vaccine. These include myocarditis and pericarditis [5,20,27,36–41], ACS [5–7,36], aortic dissection [5,6,34,35], vasospastic angina [36], Takotsubo cardiomyopathy [42], heart failure [5,7,27], arrhythmia [5,14,27,39,43], and pulmonary embolism [5,44] (Table 1). Stark et al. reported the interplay between inflammation cytokines and thrombosis in cardiovascular pathology [45]. The COVID-19 vaccine promotes inflammatory cytokine release [7–10] and can cause cardiovascular events, including myocarditis (inflammation), ACS (thrombosis), etc. Cardiovascular diseases are the most common causes of death after COVID-19 vaccination [5,6]. Hence, we created a flowchart of the differential diagnoses of chest discomfort and palpitation after COVID-19 vaccination (Figure 2). Myocarditis and pericarditis are reported to be more common in young males after the second vaccination. In male patients aged 12–15 and 16–17 years, the reported incidence is 162.2/million and 93.0/million, respectively [40]. Patients with myocarditis/pericarditis usually present 24–72 h post-vaccination [38]. In contrast, patients with ACS tend to be older in age and

typically present 24 h post-vaccination [36]. Oster et al. reported that 98% of post-vaccine myocarditis cases showed an elevated troponin level [38]. Troponin is useful for screening post-vaccine myocarditis, but false negatives are possible, especially within 12 h of the vaccine or a few days later [46]. Electrocardiography and transthoracic echocardiography (TTE) have detected 72% and 17% of the abnormalities associated with post-vaccine myocarditis, respectively [46]. Therefore, diagnosis by multi-modality imaging, including cardiac magnetic resonance imaging and longitudinal strain measured by TTE, is important [37,41]. In cases where a definitive diagnosis is difficult due to the inability to perform multi-modality imaging, detailed follow-up is critical in any cases of suspected myocarditis/pericarditis. NSAIDs, colchicine, and steroid therapy are the standard treatments for myocarditis/pericarditis [27]. In severe cases, steroids may be effective in preventing cytokine release, autoimmunity, and eosinophilic myocarditis [20]. Colchicine, which has an inhibitory effect on the NOD-like receptor family pyrin domain containing 3 (NLRP3) inflammasome, which is associated with IL-1 β (inflammatory cytokine) secretion [47], may be also effective for vaccine-associated inflammation [48].

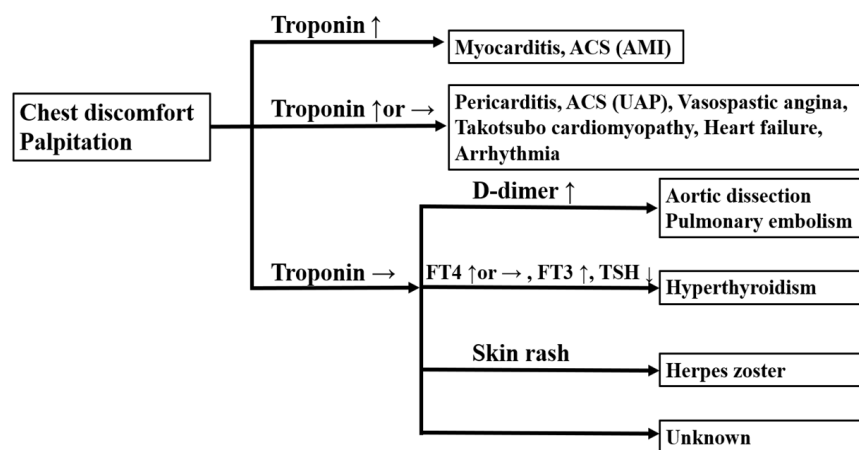


Figure 2. A flowchart of the differential diagnoses of chest discomfort and palpitation after COVID-19 vaccination. ACS: acute coronary syndrome; AMI: acute myocardial infarction; UAP: unstable angina pectoris; FT4: free thyroxine; FT3: free triiodothyronine; TSH: thyroid-stimulating hormone.

2.2. Respiratory Diseases

Asthma attacks [49], diffuse alveolar hemorrhages [50], eosinophilic pneumonia [21], interstitial lung disease [51], and sarcoidosis [52] following COVID-19 vaccination have been reported (Table 1). Although the relationship between the COVID-19 vaccines and asthma attacks and interstitial lung disease is unknown, there have been reports of cardiac arrest after vaccination [34,35,49]. The deaths associated with respiratory disease are the third most common after cardiovascular and cerebrovascular disease [5]. Differentiating these cases from heart failure is important, especially in individuals who exhibit coughing and dyspnea.

2.3. Gastroenterological Diseases

Appendicitis [5,53], autoimmune hepatitis (AIH) [11,13], bleeding duodenal ulcer [6], intestinal obstruction/perforation [5], mesenteric ischemia [5], and pancreatitis [54] have been reported post-vaccination (Table 1). Some reported cases of AIH occurred secondary to autoimmune diseases such as primary biliary cholangitis [55,56].

2.4. Renal Diseases

Wu et al. reported that minimal change disease, IgA nephropathy, and vasculitis are common in post-vaccine renal disease. Other cases following COVID-19 vaccination include membranous nephropathy relapse, the acute rejection of a kidney transplant, IgG4

nephritis relapse, new-onset renal thrombotic microangiopathy, and scleroderma renal crisis [11,12] (Table 1).

2.5. Neurological Diseases

Garg et al. reported many diseases associated with COVID-19 vaccines [57], including acute disseminated encephalomyelitis [58], acute hemorrhagic leukoencephalitis [59], autoimmune encephalitis (AE) [60], Bells' palsy [5,57], cerebral hemorrhage [61], cerebral infarction [6], cerebral venous sinus thrombosis [62], chronic inflammatory demyelinating polyneuropathy (acute-onset) [63], GBS [5,11,64], multiple sclerosis (MS) [65], myasthenia gravis (MG) [66], neuromyelitis optica spectrum disorder (NMOSD) [16], Parsonage-Turner syndrome (Neuralgic amyotrophy) [67], subarachnoid hemorrhage [6,68], thrombophlebitis [69], and transverse myelitis [70] (Table 1). The second most common cause of death after cardiovascular disease is cerebrovascular disease [5]. IL-6 causes blood-brain barrier dysfunction and enhanced leukocyte transmigration [71], leading to inflammation of the central nervous system. Moreover, IL-6 is also involved in producing anti-aquaporin-4 antibodies, and it has been reported that IL-6 has a higher level in NMOSD [72]. Intracerebral hemorrhages after vaccination due to central venous sinus thrombosis [68], vasculitis [61], and Moyamoya disease with Sjogren disease [73] have been reported. In cases of cerebral hemorrhage after COVID-19 vaccination, thrombosis, vasculitis, and autoimmune diseases should also be considered.

2.6. Skin Diseases

Alopecia areata (AA) [74], bullous pemphigoid [75], COVID arm (local injection site reaction) [76,77], eosinophilic cellulitis (Wells syndrome) [22], eosinophilic panniculitis [24], erythema multiforme [78], herpes zoster (skin, oral and facial palsy) [53,57,79,80], leukocytoclastic vasculitis [81], non-episodic angioedema with eosinophilia [23], psoriasis [82], Stevens–Johnson syndrome [83], subacute cutaneous lupus erythematosus [11,84,85], and urticaria [77] have been reported following COVID-19 vaccination (Table 1). AA is an autoimmune disease, and an increase in IFN- γ and inflammatory cytokines, including IL-6 and IL-1 β , have been reported [86]. Eosinophilic cellulitis and panniculitis are thought to be type IV hypersensitivity reactions with an increase in IL-4 and IL-5 [24,87]. AA, eosinophilic cellulitis, and eosinophilic panniculitis have been reported not only after COVID-19 vaccination but also after SARS-CoV-2 infection [74,87]. The reactivation of herpes zoster has been reported after mRNA vaccination. The causes are thought to be the dysregulation of T cell function due to vaccine-induced immunomodulation [57].

2.7. Endocrine Diseases

Graves' Disease [88,89], hypophysitis [90], hypothyroidism [88], thyroiditis (painful, silent, and subacute) [88,91], syndrome of inappropriate antidiuresis [92], and Type 1 diabetes mellitus [15] have been reported following COVID-19 vaccination (Table 1). Jafarzadeh et al. reported thyroid dysfunction following COVID-19 vaccination [88], and Yamamoto et al. reported a case of thyroid storm [14]. Therefore, the evaluation of the thyroid hormones after vaccination is important. It is thought that autoimmune diseases, including Graves' Disease and hypothyroidism, are associated with cross-reactivity. Autoantibodies are produced by the cross-reactivity between thyroid tissue antigen and the SARS-CoV-2 spike proteins produced by mRNA vaccines [93].

2.8. Collagen Diseases

Anti-neutrophil cytoplasmic antibody (ANCA)-associated vasculitis [94], antiphospholipid syndrome (APS) [95], dermatomyositis (DM) [96], eosinophilic granulomatosis (EGPA) relapse [25], giant cell arteritis [97], polymyalgia rheumatica [98], rheumatoid arthritis (RA) [11], systemic lupus erythematosus (SLE) [99], and systemic sclerosis (SSc) [100] have been reported after COVID-19 vaccination (Table 1). Autoimmune diseases, including ANCA-associated vasculitis, DM, RA, SLE, and SSc, have been reported [11,94,99,100].

Jinno et al. reported systemic thrombotic events after vaccination in a patient positive for the antiphospholipid antibody. They also suggested that the vaccine may have triggered the onset of APS (second hit) (95).

2.9. Hematologic Diseases

Aplastic anemia [101], acquires hemophilia A [102], autoimmune hemolytic anemia [103], hemophagocytic lymphohistiocytosis [28], immune thrombocytopenia [104], and vaccine-induced immune thrombotic thrombocytopenia [105] have been reported after COVID-19 vaccination (Table 1). In each reported case, the main disease was suspected to be related to autoimmunity. Hematologic adverse reactions may not be easily diagnosed, especially if anemia progresses slowly or if the onset of symptoms is slow [103].

2.10. Others

Abnormal menstrual cycles (delayed menstruation or increased bleeding or pain) [106], anaphylaxis [44], gout flares [48], lymphadenopathy [107,108], rhabdomyolysis [109], shoulder injuries related to vaccine administration (SIRVA) [109,110], and Vogt–Koyanagi–Harada syndrome [19] have also been reported following COVID-19 vaccination (Table 1). SIRVA is an acute inflammation of the shoulder that causes substantial shoulder pain and a limited range of motion [109,110]. FDG uptake with positron emission tomography imaging, which suggests the inflammation of the deltoid muscle and axillary lymph nodes at the inoculation site, has been reported [107,108].

3. Plausible Causes of Post-Vaccine Adverse Reactions

3.1. Inflammatory Cytokines

One of the most plausible causes of post-vaccine adverse reactions is the increased release of inflammatory cytokines [7–10]. Inflammatory cytokines, such as IL-6, IL-1 β , etc., are released due to the LNP component of the mRNA vaccines [9]. LNPs are also components of the small interfering RNA therapeutics (Patisiran) [111]. Patisiran increases IL-6 and interferon-inducible protein 10 (IP10) levels after infusion [112]. In practice, patisiran requires premedication before infusion, including dexamethasone, an H1/H2 blocker, and acetaminophen, preventing cytokine release and injection-site reaction [112]. The spike protein produced by the COVID-19 mRNA vaccine or by SARS-CoV-2 itself induces IL-1 β secretion in macrophages [28]. NLRP3 inflammasome is associated with IL-1 β secretion. Colchicine has the effect of suppressing the formation of NLRP3 inflammasome [47], which may be useful for vaccine-associated inflammation [48]. The mRNA vaccines increase both immunostimulatory cytokines release and inflammatory cytokines release, especially after the second vaccination and in patients infected by SARS-CoV-2 [10]. The number of deaths after vaccination is higher after the second vaccination (60.6%) than after the first (39.4%) [6]. These similarities may suggest the association in the overproduction of inflammatory cytokines.

3.2. Autoimmunity

Another potential cause of post-vaccine adverse reactions is the involvement of autoimmune phenomena [11–19]. Autoimmunity may result from IL-6 overproduction and cross-reactivity. IL-6 inhibits regulatory T cell (Treg) differentiation, promotes inflammatory helper T cell (Th17) differentiation, and, thus, induces autoimmune and inflammatory diseases [113]. Autoimmune and inflammatory diseases, including AIH [11,13], AE [60], RA [11], and SLE [99], have been implicated in post-vaccine responses. Autoimmunity may also result from the cross-reactivity between human tissue antigen and the SARS-CoV-2 spike protein [93]. As COVID-19 mRNA vaccines encode the SARS-CoV-2 spike protein, autoantibodies may be produced due to the cross-reactivity between the SARS-CoV-2 spike protein and thyroid protein. A link between vaccine-induced autoimmunity and the human leukocyte antigen gene has also been suggested [88].

3.3. Eosinophilia

Eosinophilia may also be responsible for post-vaccine adverse reactions. Eosinophilic myocarditis, eosinophilic pneumonia, EGPA (relapse), eosinophilic cellulitis, eosinophilic panniculitis, and non-episodic angioedema with eosinophilia have been reported following COVID-19 vaccination [20–25]. SARS-CoV-1 vaccines have also been shown to induce eosinophilia in the lungs of mice [114]. Andrew et al. reported that the SARS-CoV-1/-2 spike protein might cause eosinophilia associated with a Th2 immune response [115].

3.4. ACE2 Downregulation

Post-vaccine adverse reactions may also be the result of the downregulation of ACE2 [26,27]. ACE2 converts angiotensin II (Ang II) to Ang1–7, leading to vasodilation and cardioprotection [26]. The SARS-CoV-2 spike protein in a COVID-19 mRNA vaccine binds to ACE2 and induces ACE2 downregulation. ACE2 downregulation causes an increased level of Ang II and decreases Ang1–7, leading to vasoconstriction and cardiovascular events. The increase in Ang II and the decrease in Ang1–7 trigger the NF- κ B pathway, which further promotes the release of inflammatory cytokines, including IL-6, IL-1 β , etc. [116]. Myopericarditis is more common in young men than in women, which may be related to the increased level of ACE2 in the latter due to estrogen [117].

4. Precautionary Measures Including Exercise, Alcohol Intake, Tobacco Smoking, and Baths

4.1. Avoid Strenuous Exercise

High-intensity exercise increases the expression of the NLRP3 gene and inflammatory cytokines (IL-1 β and IL-18) compared to moderate-intensity exercise [29]. Moderate-to-low-intensity training is recommended for athletes instead of high-intensity at the time of vaccination [118]. As a precautionary measure against post-vaccination myocarditis in Singapore, young individuals, including children and adolescents, are advised to avoid strenuous physical activities such as running, weightlifting, competitive sports, or playing ball games for two weeks after receiving a COVID-19 vaccination [33]. High school-aged male students tend to exercise more than adult men [119], and because myocarditis occurs predominantly in male adolescents, exercise restriction is recommended. Regarding infection prevention, lymphocytes decrease on the second day following the mRNA vaccination [120], and 3 to 72 h after the vaccination, high-intensity exercise increases the risk of opportunistic infections, according to the open window theory [118].

4.2. Avoid Consuming Alcohol and Smoking

Alcohol intake and tobacco smoking cause an increased release of inflammatory cytokines [30,31], coronary spasms [121], and arrhythmia [122]. Alcohol intake and tobacco smoking have also been identified as predictive factors for lower antibody titers after vaccination [123,124]. Alcohol intake increases atrial fibrillation (AF) [122]. On the contrary, limiting alcohol reduces the incidence of AF [122]. Therefore, avoiding alcohol consumption and tobacco smoking is important for increasing antibody titers and preventing adverse reactions, such as coronary spasms and arrhythmia.

4.3. Take a Shower Instead of Sitting in a Hot Bath

Taking a bath improves sleep quality, vascular functions, and insulin sensitivity. In contrast, sudden deaths have been associated more frequently with bathing [125]. Inflammatory cytokines, especially IL-6, also increase immediately after bathing [32]. The exact relationship between bathing and COVID-19 vaccination is unknown. However, there have been many sudden deaths while bathing after vaccination in Japan (50 cases; 29 females, 58% and 21 males, 42%; median age 80 (IQR 73–86) years) [34,35] (Figure 1). On the contrary, there have been no reported deaths related to bathing after the influenza vaccine in 2019–2020 [126]. Taking a bath is uniquely customary in Japan. Hot baths are less popular outside of Japan. As such, this issue must be addressed locally. The majority of deaths

that occurred while bathing were reported within one week (44/50 cases) after COVID-19 vaccination [34,35] (Figure 1). Based on these reported cases, we suggest that, immediately after COVID-19 vaccination and for several days afterwards, individuals should be advised to take showers rather than baths

5. Discussion

Deaths after COVID-19 vaccination usually occur within several days. According to the US surveillance data, the most common cause of death after vaccination is cardiovascular events, followed by cerebrovascular events [5]. Similarly, the Japanese data have shown that deaths during baths are the most common for several days after mRNA vaccination [34,35] (Figure 1). The COVID-19 vaccines promote inflammatory cytokine release [7–10], and the overproduction of inflammatory cytokines and thrombosis has been documented in cardiovascular pathology [45].

High-intensity exercise, alcohol intake, tobacco smoking, and taking a bath also increase inflammatory cytokine release [29–32], which may promote cardiovascular events after vaccination. Based on the current evidence, we recommend refraining from high-intensity exercise, alcohol intake, tobacco smoking, and baths immediately after COVID-19 vaccination and for several days afterwards for the prevention of severe adverse reactions, including death. In Singapore, adolescents and younger persons are advised to avoid strenuous physical activities for two weeks after COVID-19 mRNA vaccination [33]. Most post-vaccination deaths have occurred among the elderly (median age: 76 (IQR 66–86) years) [5]. As such, we propose that high-intensity exercise restriction should be recommended for all individuals after COVID-19 vaccination, regardless of age. Alcohol intake and tobacco smoking interfere with the increase in antibody titers after vaccination. Likewise, corticosteroids and immunosuppressive drugs interfere with vaccine efficacy [123,124]. To increase the vaccine's effectiveness against COVID-19, we recommend refraining from drinking alcohol and smoking immediately after vaccination.

In patients who take corticosteroid and immunosuppressive medication, there is a high risk of aggravation due to COVID-19 infection [127]. In particular, pre-existing respiratory disorder cases, including MG, may take advantage of the vaccination to avoid COVID-19 pneumonia [66]. On the other hand, although reports are limited, vaccines are also known to relapse autoimmune diseases such as MG, GBS, Graves' disease, and RA [64,66,89,128]. Therefore, autoimmune diseases require careful observation before and after vaccination.

For patients with a history of COVID-19 infection, vaccination may further increase both inflammatory and immunostimulatory cytokines, including IL-6, compared to patients who have not had the infection [10]. Therefore, receiving a COVID-19 vaccine shortly after COVID-19 infection is likely to cause more pronounced inflammation [10] and autoimmunity due to IL-6 overproduction [113]. In Japan, vaccination is recommended about three months after COVID-19 infection for the healthy population [129].

6. Conclusions

After COVID-19 vaccination, inflammatory cytokines, autoimmune involvement, eosinophilia, and the downregulation of ACE2 have been reported in relation to various symptoms and diseases. We should recognize these adverse effects and recommend the following precautions immediately after vaccination: limit strenuous exercise, alcohol intake, tobacco smoking, and taking baths.

Author Contributions: Conceptualization: T.A., Y.E. and M.M.; methodology: T.A., Y.E, T.K. and M.M.; validation: M.M.; formal analysis: T.A. and M.M.; investigation: T.A.; data curation: T.A.; original draft preparation: T.A.; review and editing of the draft manuscript, T.A., Y.E., T.K., M.M. and M.N.; project administration: M.N. All authors have read and agreed to the published version of the manuscript.

Funding: This research received no external funding.

Institutional Review Board Statement: Not applicable.

Informed Consent Statement: Not applicable.

Data Availability Statement: Japanese COVID-19 vaccine administration dates are available online: <https://www.mhlw.go.jp/content/10601000/000928692.pdf> (accessed on 26 April 2022, in Japanese), <https://www.mhlw.go.jp/content/10601000/000928694.pdf> (accessed on 26 April 2022, in Japanese).

Conflicts of Interest: The authors declare no conflict of interest.

References

- Noor, R.; Shareen, S.; Billah, M. COVID-19 vaccines: Their effectiveness against the severe acute respiratory syndrome coronavirus 2 (SARS-CoV-2) and its emerging variants. *Bull. Natl. Res. Cent.* **2022**, *46*, 96. [CrossRef]
- Dunkle, L.M.; Kotloff, K.L.; Gay, C.L.; Anez, G.; Adelglass, J.M.; Barrat Hernandez, A.Q.; Harper, W.L.; Duncanson, D.M.; McArthur, M.A.; Florescu, D.F.; et al. Efficacy and Safety of NVX-CoV2373 in Adults in the United States and Mexico. *N. Engl. J. Med.* **2022**, *386*, 531–543. [CrossRef]
- Menni, C.; Klaser, K.; May, A.; Polidori, L.; Capdevila, J.; Louca, P.; Sudre, C.H.; Nguyen, L.H.; Drew, D.A.; Merino, J.; et al. Vaccine side-effects and SARS-CoV-2 infection after vaccination in users of the COVID Symptom Study app in the UK: A prospective observational study. *Lancet Infect. Dis.* **2021**, *21*, 939–949. [CrossRef]
- Lee, Y.W.; Lim, S.Y.; Lee, J.H.; Lim, J.S.; Kim, M.; Kwon, S.; Joo, J.; Kwak, S.H.; Kim, E.O.; Jung, J.; et al. Adverse Reactions of the Second Dose of the BNT162b2 mRNA COVID-19 Vaccine in Healthcare Workers in Korea. *J. Korean Med. Sci.* **2021**, *36*, e153. [CrossRef]
- Rosenblum, H.G.; Gee, J.; Liu, R.; Marquez, P.L.; Zhang, B.; Strid, P.; Abara, W.E.; McNeil, M.M.; Myers, T.R.; Hause, A.M.; et al. Safety of mRNA vaccines administered during the initial 6 months of the US COVID-19 vaccination programme: An observational study of reports to the Vaccine Adverse Event Reporting System and v-safe. *Lancet Infect. Dis.* **2022**. [CrossRef]
- Yeo, A.; Kuek, B.; Lau, M.; Tan, S.R.; Chan, S. Post COVID-19 vaccine deaths—Singapore’s early experience. *Forensic Sci. Int.* **2022**, *332*, 111199. [CrossRef]
- Liu, T.; Liang, Y.; Huang, L. Development and Delivery Systems of mRNA Vaccines. *Front. Bioeng. Biotechnol.* **2021**, *9*, 718753.
- Rauch, S.; Jasny, E.; Schmidt, K.E.; Petsch, B. New Vaccine Technologies to Combat Outbreak Situations. *Front. Immunol.* **2018**, *9*, 1963. [CrossRef]
- Ndeupen, S.; Qin, Z.; Jacobsen, S.; Bouteau, A.; Estantbouli, H.; Igyarto, B.Z. The mRNA-LNP platform’s lipid nanoparticle component used in preclinical vaccine studies is highly inflammatory. *iScience* **2021**, *24*, 103479. [CrossRef]
- Bergamaschi, C.; Terpos, E.; Rosati, M.; Angel, M.; Bear, J.; Stellas, D.; Karaliota, S.; Apostolakou, F.; Bagratuni, T.; Patseas, D.; et al. Systemic IL-15, IFN-gamma, and IP-10/CXCL10 signature associated with effective immune response to SARS-CoV-2 in BNT162b2 mRNA vaccine recipients. *Cell Rep.* **2021**, *36*, 109504. [CrossRef]
- Chen, Y.; Xu, Z.; Wang, P.; Li, X.M.; Shuai, Z.W.; Ye, D.Q.; Pan, H.F. New-onset autoimmune phenomena post-COVID-19 vaccination. *Immunology* **2022**, *165*, 386–401. [CrossRef]
- Wu, H.H.L.; PKalra, A.; Chinnadurai, R. New-Onset and Relapsed Kidney Histopathology Following COVID-19 Vaccination: A Systematic Review. *Vaccines* **2021**, *9*, 1252. [CrossRef]
- Vuille-Lessard, E.; Montani, M.; Bosch, J.; Semmo, N. Autoimmune hepatitis triggered by SARS-CoV-2 vaccination. *J. Autoimmun.* **2021**, *123*, 102710. [CrossRef]
- Yamamoto, K.; Mashiba, T.; Takano, K.; Suzuki, T.; Kami, M.; Takita, M.; Kusumi, E.; Mizuno, Y.; Hamaki, T. A Case of Exacerbation of Subclinical Hyperthyroidism after First Administration of BNT162b2 mRNA COVID-19 Vaccine. *Vaccines* **2021**, *9*, 1108. [CrossRef]
- Patrizio, A.; Ferrari, S.M.; Antonelli, A.; Fallahi, P. A case of Graves’ disease and type 1 diabetes mellitus following SARS-CoV-2 vaccination. *J. Autoimmun.* **2021**, *125*, 102738. [CrossRef]
- Chen, S.; XFan, R.; He, S.; Zhang, J.W.; Li, S.J. Watch out for neuromyelitis optica spectrum disorder after inactivated virus vaccination for COVID-19. *Neurol. Sci.* **2021**, *42*, 3537–3539. [CrossRef]
- McKean, N.; Chircop, C. Guillain-Barre syndrome after COVID-19 vaccination. *BMJ Case Rep.* **2021**, *14*, e244125. [CrossRef]
- Scollan, M.E.; Breneman, A.; Kinariwalla, N.; Soliman, Y.; Youssef, S.; Bordone, L.A.; Gallitano, S.M. Alopecia areata after SARS-CoV-2 vaccination. *JAAD Case Rep.* **2022**, *20*, 1–5. [CrossRef]
- Saraceno, J.J.F.; GSouza, M.; Finamor, L.P.D.S.; Nascimento, H.M.; Belfort, R., Jr. Vogt-Koyanagi-Harada Syndrome following COVID-19 and ChAdOx1 nCoV-19 (AZD1222) vaccine. *Int. J. Retin. Vitro.* **2021**, *7*, 49. [CrossRef]
- Takeda, M.; Ishio, N.; Shoji, T.; Mori, N.; Matsumoto, M.; Shikama, N. Eosinophilic Myocarditis Following Coronavirus Disease 2019 (COVID-19) Vaccination. *Circ. J.* **2021**. [CrossRef]
- May, J.; Draper, A.; Aul, R. Eosinophilic pneumonia and COVID-19 vaccination. *QJM* **2022**, *115*, 251–252. [CrossRef] [PubMed]
- Vaccaro, M.; Bertino, L.; Squeri, R.; Genovese, C.; Isola, S.; Spatari, G.; Spina, E.; Cutroneo, P. Early atypical injection-site reactions to COVID-19 vaccine: A case series. *J. Eur. Acad. Dermatol. Venereol.* **2022**, *36*, e24–e26. [CrossRef] [PubMed]
- Ishizuka, K.; Katayama, K.; Kaji, Y.; Tawara, J.; Ohira, Y. Non-episodic angioedema with eosinophilia after BNT162b2 mRNA COVID-19 vaccination. *QJM* **2021**, *114*, 745–746. [CrossRef]
- Kaikati, J.; Ghanem, A.; el Bahtimi, R.; Helou, J.; Tomb, R. Eosinophilic panniculitis: A new side effect of Sinopharm COVID-19 vaccine. *J. Eur. Acad. Dermatol. Venereol.* **2022**, *36*, e337–e339. [CrossRef]

25. Costanzo, G.; ALedda, G.; Ghisu, A.; Vacca, M.; Firinu, D.; del Giacco, S. Eosinophilic Granulomatosis with Polyangiitis Relapse after COVID-19 Vaccination: A Case Report. *Vaccines* **2021**, *10*, 13. [CrossRef]
26. Kuba, K.; Imai, Y.; Penninger, J.M. Multiple functions of angiotensin-converting enzyme 2 and its relevance in cardiovascular diseases. *Circ. J.* **2013**, *77*, 301–308. [CrossRef]
27. Jain, S.S.; Steele, J.M.; Fonseca, B.; Huang, S.; Shah, S.; Maskatia, S.A.; Buddhe, S.; Misra, N.; Ramachandran, P.; Gaur, L.; et al. COVID-19 Vaccination-Associated Myocarditis in Adolescents. *Pediatrics* **2021**, *148*, e2021053427. [CrossRef]
28. Hieber, M.L.; Sprute, R.; Eichenauer, D.A.; Hallek, M.; Jachimowicz, R.D. Hemophagocytic lymphohistiocytosis after SARS-CoV-2 vaccination. *Infection* **2022**. [CrossRef]
29. Khakroo Abkenar, I.; Rahmani-Nia, F.; Lombardi, G. The Effects of Acute and Chronic Aerobic Activity on the Signaling Pathway of the Inflammasome NLRP3 Complex in Young Men. *Medicina* **2019**, *55*, 105. [CrossRef]
30. Lee, M.R.; Abshire, K.M.; Farokhnia, M.; Akhlaghi, F.; Leggio, L. Effect of oral alcohol administration on plasma cytokine concentrations in heavy drinking individuals. *Drug Alcohol Depend.* **2021**, *225*, 108771. [CrossRef]
31. Jain, D.; Chaudhary, P.; Varshney, N.; Razzak, K.S.B.; Verma, D.; Zahra, T.R.K.; Janmeda, P.; Sharifi-Rad, J.; Dastan, S.D.; Mahmud, S.; et al. Tobacco Smoking and Liver Cancer Risk: Potential Avenues for Carcinogenesis. *J. Oncol.* **2021**, *2021*, 5905357. [CrossRef] [PubMed]
32. Hoekstra, S.P.; Bishop, N.C.; Faulkner, S.H.; Bailey, S.J.; Leicht, C.A. Acute and chronic effects of hot water immersion on inflammation and metabolism in sedentary, overweight adults. *J. Appl. Physiol.* **2018**, *125*, 2008–2018. [CrossRef] [PubMed]
33. Singapore Ministry of Health. Does the COVID-19 Vaccine Cause Myocarditis or Pericarditis? Available online: <https://www.moh.gov.sg/covid-19/vaccination/faqs---children-related-vaccination-matters> (accessed on 13 March 2022).
34. Japanese Government Statistics by Ministry of Health, Labour and Welfare. Available online: <https://www.mhlw.go.jp/content/10601000/000928692.pdf> (accessed on 26 April 2022). (In Japanese)
35. Japanese Government Statistics by Ministry of Health, Labour and Welfare. Available online: <https://www.mhlw.go.jp/content/10601000/000928694.pdf> (accessed on 26 April 2022). (In Japanese)
36. Aye, Y.N.; Mai, A.S.; Zhang, A.; Lim, O.Z.H.; Lin, N.; Ng, C.H.; Chan, M.Y.; Yip, J.; Loh, P.H.; Chew, N.W.S. Acute Myocardial Infarction and Myocarditis following COVID-19 Vaccination. *QJM* **2021**, hcab252. [CrossRef]
37. Koizumi, T.; Awaya, T.; Yoshioka, K.; Kitano, S.; Hayama, H.; Amemiya, K.; Enomoto, Y.; Yazaki, Y.; Moroi, M.; Nakamura, M. Myocarditis after COVID-19 mRNA vaccines. *QJM* **2021**, *114*, 741–743. [CrossRef]
38. Oster, M.E.; Shay, D.K.; Su, J.R.; Gee, J.; Creech, C.B.; Broder, K.R.; Edwards, K.; Soslow, J.H.; Dendy, J.M.; Schlaudecker, E.; et al. Myocarditis Cases Reported After mRNA-Based COVID-19 Vaccination in the US from December 2020 to August 2021. *JAMA* **2022**, *327*, 331–340. [CrossRef]
39. Uesako, H.; Fujikawa, H.; Hashimoto, S.; Wakabayashi, T. Prominent J waves and ventricular fibrillation due to myocarditis and pericarditis after BNT162b2 mRNA COVID-19 vaccination. *Can. J. Cardiol.* **2022**. [CrossRef]
40. Krug, A.; Stevenson, J.; Hoeg, T.B. BNT162b2 Vaccine-Associated Myo/Pericarditis in Adolescents: A Stratified Risk-Benefit Analysis. *Eur. J. Clin. Invest.* **2022**, *52*, e13759. [CrossRef]
41. Bews, H.; Bryson, A.; Bortoluzzi, T.; Tam, J.W.; Jassal, D.S. COVID-19 vaccination induced myopericarditis: An imager’s perspective. *CJC Open* **2022**, *4*, 497–500. [CrossRef]
42. Toida, R.; Uezono, S.; Komatsu, H.; Toida, T.; Imamura, A.; Fujimoto, S.; Kaikita, K. Takotsubo cardiomyopathy after vaccination for coronavirus disease 2019 in a patient on maintenance hemodialysis. *CEN Case Rep.* **2021**, *11*, 220–224. [CrossRef]
43. Lin, Y.T.; Chen, P.Y.; Su, Y.J. Paroxysmal supra-ventricular tachycardia after AstraZeneca COVID-19 vaccine injection. *New Microbes New Infect.* **2022**, *45*, 100965. [CrossRef]
44. Klein, N.P.; Lewis, N.; Goddard, K.; Fireman, B.; Zerbo, O.; Hanson, K.E.; Donahue, J.G.; Kharbanda, E.O.; Naleway, A.; Nelson, J.C.; et al. Surveillance for Adverse Events After COVID-19 mRNA Vaccination. *JAMA* **2021**, *326*, 1390–1399. [CrossRef] [PubMed]
45. Stark, K.; Massberg, S. Interplay between inflammation and thrombosis in cardiovascular pathology. *Nat. Rev. Cardiol.* **2021**, *18*, 666–682. [CrossRef] [PubMed]
46. Sulemankhil, I.; Abdelrahman, M.; Negi, S.I. Temporal association between the COVID-19 Ad26.COV2.S vaccine and acute myocarditis: A case report and literature review. *Cardiovasc. Revasc. Med.* **2021**, *38*, 117–123. [CrossRef] [PubMed]
47. Olsen, M.B.; Gregersen, I.; Sandanger, O.; Yang, K.; Sokolova, M.; Halvorsen, B.E.; Gullestad, L.; Broch, K.; Aukrust, P.; Louwe, M.C. Targeting the Inflammasome in Cardiovascular Disease. *JACC Basic Transl. Sci.* **2022**, *7*, 84–98. [CrossRef]
48. Lu, J.; He, Y.; Terkeltaub, R.; Sun, M.; Ran, Z.; Xu, X.; Wang, C.; Li, X.; Hu, S.; Xue, X.; et al. Colchicine prophylaxis is associated with fewer gout flares after COVID-19 vaccination. *Ann. Rheum. Dis.* **2022**. [CrossRef]
49. Kawasaki, T.; Sueyoshi, K.; Nakamura, Y.; Okamoto, K.; Tanaka, H. Can the coronavirus disease-2019 vaccine induce an asthma attack? *Acute Med. Surg.* **2021**, *8*, e714. [CrossRef]
50. Sharma, A.; Upadhyay, B.; Banjade, R.; Poudel, B.; Luitel, P.; Kharel, B. A Case of Diffuse Alveolar Hemorrhage with COVID-19 Vaccination. *Cureus* **2022**, *14*, e21665. [CrossRef]
51. Yoshifuji, A.; Ishioka, K.; Masuzawa, Y.; Suda, S.; Murata, S.; Uwamino, Y.; Fujino, M.; Miyahara, H.; Hasegawa, N.; Ryuzaki, M.; et al. COVID-19 vaccine induced interstitial lung disease. *J. Infect. Chemother.* **2022**, *28*, 95–98. [CrossRef]
52. Matsuo, T.; Honda, H.; Tanaka, T.; Uraguchi, K.; Kawahara, M.; Hagiya, H. COVID-19 mRNA Vaccine-Associated Uveitis Leading to Diagnosis of Sarcoidosis: Case Report and Review of Literature. *J. Investig. Med. High Impact Case Rep.* **2022**, *10*, 23247096221086450. [CrossRef]

53. Barda, N.; Dagan, N.; Ben-Shlomo, Y.; Kepten, E.; Waxman, J.; Ohana, R.; Hernan, M.A.; Lipsitch, M.; Kohane, I.; Netzer, D.; et al. Safety of the BNT162b2 mRNA COVID-19 Vaccine in a Nationwide Setting. *N. Engl. J. Med.* **2021**, *385*, 1078–1090. [[CrossRef](#)]
54. Kantar, A.; Seminara, M.; Odoni, M.; Verde, I.D. Acute Mild Pancreatitis Following COVID-19 mRNA Vaccine in an Adolescent. *Children* **2021**, *9*, 29. [[CrossRef](#)] [[PubMed](#)]
55. Zhou, T.; Fronhoffs, F.; Dold, L.; Strassburg, C.P.; Weismuller, T.J. New-onset autoimmune hepatitis following mRNA COVID-19 vaccination in a 36-year-old woman with primary sclerosing cholangitis—Should we be more vigilant? *J. Hepatol.* **2022**, *76*, 218–220. [[CrossRef](#)] [[PubMed](#)]
56. López Romero-Salazar, F.; Lista, M.V.; Gómez-Domínguez, E.; Ibarrola-Andrés, C.; Gómez, R.M.; Vázquez, I.F. SARS-CoV-2 vaccine, a new autoimmune hepatitis trigger? *Rev. Esp. Enferm. Dig.* **2022**. [[CrossRef](#)] [[PubMed](#)]
57. Garg, K.R.; Paliwal, V.K. Spectrum of neurological complications following COVID-19 vaccination. *Neurol. Sci.* **2022**, *43*, 3–40. [[CrossRef](#)] [[PubMed](#)]
58. Vogrig, A.; Janes, F.; Gigli, G.L.; Curcio, F.; Negro, I.D.; D’Agostini, S.; Fabris, M.; Valente, M. Acute disseminated encephalomyelitis after SARS-CoV-2 vaccination. *Clin. Neurol. Neurosurg.* **2021**, *208*, 106839. [[CrossRef](#)]
59. Ancau, M.; Liesche-Starnecker, F.; Niederschweiberer, J.; Krieg, S.M.; Zimmer, C.; Lingg, C.; Kumpfmüller, D.; Ikenberg, B.; Ploner, M.; Hemmer, B.; et al. Case Series: Acute Hemorrhagic Encephalomyelitis After SARS-CoV-2 Vaccination. *Front. Neurol.* **2021**, *12*, 820049. [[CrossRef](#)]
60. Zlotnik, Y.; Gadoth, A.; Abu-Salameh, I.; Horev, A.; Novoa, R.; Ifergane, G. Case Report: Anti-LGI1 Encephalitis Following COVID-19 Vaccination. *Front. Immunol.* **2021**, *12*, 813487. [[CrossRef](#)]
61. Takeyama, R.; Fukuda, K.; Kouzaki, Y.; Koga, T.; Hayashi, S.; Ohtani, H.; Inoue, T. Intracerebral hemorrhage due to vasculitis following COVID-19 vaccination: A case report. *Acta Neurochir.* **2022**, *164*, 543–547. [[CrossRef](#)]
62. de Gregorio, C.; Colarusso, L.; Calcaterra, G.; Bassareo, P.P.; Ieni, A.; Mazzeo, A.T.; Ferrazzo, G.; Noto, A.; Koniari, I.; Mehta, J.L.; et al. Cerebral Venous Sinus Thrombosis following COVID-19 Vaccination: Analysis of 552 Worldwide Cases. *Vaccines* **2022**, *10*, 232. [[CrossRef](#)]
63. Suri, V.; Pandey, S.; Singh, J.; Jena, A. Acute-onset chronic inflammatory demyelinating polyneuropathy after COVID-19 infection and subsequent ChAdOx1 nCoV-19 vaccination. *BMJ Case Rep.* **2021**, *14*, e245816. [[CrossRef](#)]
64. Shapiro Ben David, S.; Potasman, I.; Rahamim-Cohen, D. Rate of Recurrent Guillain-Barré Syndrome after mRNA COVID-19 Vaccine BNT162b2. *JAMA Neurol.* **2021**, *78*, 1409–1411. [[CrossRef](#)] [[PubMed](#)]
65. Havla, J.; Schultz, Y.; Zimmermann, H.; Hohlfeld, R.; Danek, A.; Kumpfel, T. First manifestation of multiple sclerosis after immunization with the Pfizer-BioNTech COVID-19 vaccine. *J. Neurol.* **2022**, *269*, 55–58. [[CrossRef](#)] [[PubMed](#)]
66. Lupica, A.; di Stefano, V.; Iacono, S.; Pignolo, A.; Quartana, M.; Gagliardo, A.; Fierro, B.; Brighina, F. Impact of COVID-19 in AChR Myasthenia Gravis and the Safety of Vaccines: Data from an Italian Cohort. *Neurol. Int.* **2022**, *14*, 406–416. [[CrossRef](#)]
67. Mahajan, S.; Zhang, F.; Mahajan, A.; Zimnowodzki, S. Parsonage Turner syndrome after COVID-19 vaccination. *Muscle Nerve* **2021**, *64*, E3–E4. [[CrossRef](#)]
68. Syed, K.; Chaudhary, H.; Donato, A. Central Venous Sinus Thrombosis with Subarachnoid Hemorrhage Following an mRNA COVID-19 Vaccination: Are These Reports Merely Co-Incidental? *Am. J. Case Rep.* **2021**, *22*, e933397. [[CrossRef](#)]
69. Ikechi, D.; Hashimoto, H.; Nakano, H.; Nakamura, K. A Case of Suspected COVID-19 Vaccine-related Thrombophlebitis. *Intern. Med.* **2022**, *61*, 1631. [[CrossRef](#)]
70. Pagenkopf, C.; Sudmeyer, M. A case of longitudinally extensive transverse myelitis following vaccination against COVID-19. *J. Neuroimmunol.* **2021**, *358*, 577606. [[CrossRef](#)]
71. Takeshita, Y.; Obermeier, B.; Cotleu, A.C.; Spampinato, S.F.; Shimizu, F.; Yamamoto, E.; Sano, Y.; Kryzer, T.J.; Lennon, V.A.; Kanda, T.; et al. Effects of neuromyelitis optica-IgG at the blood-brain barrier in vitro. *Neurol. Neuroimmunol. Neuroinflamm.* **2017**, *4*, e311. [[CrossRef](#)]
72. Uzawa, A.; Mori, M.; Arai, K.; Sato, Y.; Hayakawa, S.; Masuda, S.; Taniguchi, J.; Kuwabara, S. Cytokine and chemokine profiles in neuromyelitis optica: Significance of interleukin-6. *Mult. Scler. J.* **2010**, *16*, 1443–1452. [[CrossRef](#)]
73. Lin, Y.H.; Huang, H.; Hwang, W.Z. Moyamoya disease with Sjogren disease and autoimmune thyroiditis presenting with left intracranial hemorrhage after messenger RNA-1273 vaccination: A case report. *Medicine* **2022**, *101*, e28756. [[CrossRef](#)]
74. Bardazzi, F.; Guglielmo, A.; Abbenante, D.; Sacchelli, L.; Sechi, A.; Starace, M.V.R. New insights into alopecia areata during COVID-19 pandemic: When infection or vaccination could play a role. *J. Cosmet. Dermatol.* **2022**, *21*, 1796–1798. [[CrossRef](#)] [[PubMed](#)]
75. Dell’Antonia, M.; Anedda, S.; Usai, F.; Atzori, L.; Ferrel, C. Bullous pemphigoid triggered by COVID-19 vaccine: Rapid resolution with corticosteroid therapy. *Dermatol. Ther.* **2022**, *35*, e15208. [[CrossRef](#)]
76. Johnston, M.S.; Galan, A.; Watsky, K.L.; Little, A.J. Delayed Localized Hypersensitivity Reactions to the Moderna COVID-19 Vaccine: A Case Series. *JAMA Dermatol.* **2021**, *157*, 716–720. [[CrossRef](#)] [[PubMed](#)]
77. McMahan, D.E.; Amerson, E.; Rosenbach, M.; Lipoff, J.B.; Moustafa, D.; Tyagi, A.; Desai, S.R.; French, L.E.; Lim, H.W.; Thiers, B.H.; et al. Cutaneous reactions reported after Moderna and Pfizer COVID-19 vaccination: A registry-based study of 414 cases. *J. Am. Acad. Dermatol.* **2021**, *85*, 46–55. [[CrossRef](#)]
78. de Las Vecillas, L.; Lopez, J.; Morchon, E.; Rodriguez, F.; Drake, M.; Martino, M. Viral-like Reaction or Hypersensitivity? Erythema Multiforme Minor Reaction and Moderate Eosinophilia after the Pfizer-BioNTech BNT162b2 (mRNA-Based) SARS-CoV-2 Vaccine. *J. Invest. Allergol. Clin. Immunol.* **2021**, *32*, 77–78. [[CrossRef](#)] [[PubMed](#)]

79. Lee, C.; Cotter, D.; Basa, J.; Greenberg, H.L. 20 Post-COVID-19 vaccine-related shingles cases seen at the Las Vegas Dermatology clinic and sent to us via social media. *J. Cosmet. Dermatol.* **2021**, *20*, 1960–1964. [[CrossRef](#)]
80. Fukuoka, H.; Fukuoka, N.; Kibe, T.; Tubbs, R.S.; Iwanaga, J. Oral Herpes Zoster Infection Following COVID-19 Vaccination: A Report of Five Cases. *Cureus* **2021**, *13*, e19433. [[CrossRef](#)]
81. Cohen, S.R.; Prussick, L.; Kahn, J.S.; Gao, D.X.; Radfar, A.; Rosmarin, D. Leukocytoclastic vasculitis flare following the COVID-19 vaccine. *Int. J. Dermatol.* **2021**, *60*, 1032–1033. [[CrossRef](#)]
82. Durmaz, I.; Turkmen, D.; Altunisik, N.; Toplu, S.A. Exacerbations of generalized pustular psoriasis, palmoplantar psoriasis, and psoriasis vulgaris after mRNA COVID-19 vaccine: A report of three cases. *Dermatol. Ther.* **2022**, *35*, e15331. [[CrossRef](#)]
83. Dash, S.; Sirka, C.S.; Mishra, S.; Viswan, P. COVID-19 vaccine-induced Stevens-Johnson syndrome. *Clin. Exp. Dermatol.* **2021**, *46*, 1615–1617. [[CrossRef](#)]
84. Kreuter, A.; Licciardi-Fernandez, M.J.; Burmann, S.N.; Burkert, B.; Oellig, F.; Michalowitz, A.L. Induction and exacerbation of subacute cutaneous lupus erythematosus following mRNA-based or adenoviral vector-based SARS-CoV-2 vaccination. *Clin. Exp. Dermatol.* **2022**, *47*, 161–163. [[CrossRef](#)]
85. Zengarini, C.; Pileri, A.; Salamone, F.P.; Piraccini, B.M.; Vitale, G.; la Placa, M. Subacute cutaneous lupus erythematosus induction after SARS-CoV-2 vaccine in a patient with primary biliary cholangitis. *J. Eur. Acad. Dermatol. Venereol.* **2022**, *36*, e179–e180. [[CrossRef](#)]
86. Tomaszewska, K.; Kozłowska, M.; Kaszuba, A.; Lesiak, A.; Narbutt, J.; Zalewska-Janowska, A. Increased Serum Levels of IFN-gamma, IL-1beta, and IL-6 in Patients with Alopecia Areata and Nonsegmental Vitiligo. *Oxid Med. Cell Longev.* **2020**, *2020*, 5693572. [[CrossRef](#)]
87. Moseley, I.; Yang, E.J.; Mathieu, R.J.; Elco, C.; Massoud, C.M. Wells syndrome as a presenting sign of COVID-19 in the setting of allergic rhinitis and iron deficiency anemia. *JAAD Case Rep.* **2022**, *23*, 27–30. [[CrossRef](#)]
88. Jafarzadeh, A.; Nemati, M.; Jafarzadeh, S.; Nozari, P.; Mortazavi, S.M.J. Thyroid dysfunction following vaccination with COVID-19 vaccines: A basic review of the preliminary evidence. *J. Endocrinol. Investig.* **2022**, 1–29. [[CrossRef](#)] [[PubMed](#)]
89. Sriprapradang, C. Aggravation of hyperthyroidism after heterologous prime-boost immunization with inactivated and adenovirus-vectored SARS-CoV-2 vaccine in a patient with Graves' disease. *Endocrine* **2021**, *74*, 226–227. [[CrossRef](#)] [[PubMed](#)]
90. Murvelashvili, N.; Tessnow, A. A Case of Hypophysitis Following Immunization with the mRNA-1273 SARS-CoV-2 Vaccine. *J. Investig. Med. High Impact Case Rep.* **2021**, *9*, 23247096211043386. [[CrossRef](#)] [[PubMed](#)]
91. Oyibo, S.O. Subacute Thyroiditis After Receiving the Adenovirus-Vectored Vaccine for Coronavirus Disease (COVID-19). *Cureus* **2021**, *13*, e16045. [[CrossRef](#)]
92. Lindner, G.; Ryser, B. The syndrome of inappropriate antidiuresis after vaccination against COVID-19: Case report. *BMC Infect. Dis.* **2021**, *21*, 1000. [[CrossRef](#)]
93. Vojdani, A.; Vojdani, E.; Kharrazian, D. Reaction of Human Monoclonal Antibodies to SARS-CoV-2 Proteins with Tissue Antigens: Implications for Autoimmune Diseases. *Front. Immunol.* **2020**, *11*, 617089. [[CrossRef](#)]
94. Obata, S.; Hidaka, S.; Yamano, M.; Yanai, M.; Ishioka, K.; Kobayashi, S. MPO-ANCA-associated vasculitis after the Pfizer/BioNTech SARS-CoV-2 vaccination. *Clin. Kidney J.* **2022**, *15*, 357–359. [[CrossRef](#)] [[PubMed](#)]
95. Jinno, S.; Naka, I.; Nakazawa, T. Catastrophic antiphospholipid syndrome complicated with essential thrombocythaemia after COVID-19 vaccination: In search of the underlying mechanism. *Rheumatol. Adv. Pract.* **2021**, *5*, rkab096. [[CrossRef](#)] [[PubMed](#)]
96. Gouda, W.; Albasri, A.; Alsaqabi, F.; al Sabah, H.Y.; Alkandari, M.; Abdelnaby, H. Dermatomyositis Following BNT162b2 mRNA COVID-19 Vaccination. *J. Korean Med. Sci.* **2022**, *37*, e32. [[CrossRef](#)] [[PubMed](#)]
97. Sauret, A.; Stievenart, J.; Smets, P.; Olagne, L.; Guelon, B.; Aumaitre, O.; Andre, M.; Trefond, L. Case of Giant Cell Arteritis After SARS-CoV-2 Vaccination: A Particular Phenotype? *J. Rheumatol.* **2022**, *49*, 120. [[CrossRef](#)] [[PubMed](#)]
98. Manzo, C.; Natale, M.; Castagna, A. Polymyalgia rheumatica as uncommon adverse event following immunization with COVID-19 vaccine: A case report and review of literature. *Aging Med.* **2021**, *4*, 234–238. [[CrossRef](#)]
99. Patil, S.; Patil, A. Systemic lupus erythematosus after COVID-19 vaccination: A case report. *J. Cosmet. Dermatol.* **2021**, *20*, 3103–3104. [[CrossRef](#)]
100. Cole, A.; Thomas, R.; Goldman, N.; Howell, K.; Chakravarty, K.; Denton, C.P.; Ong, V.H. Diffuse cutaneous systemic sclerosis following SARS-Co V-2 vaccination. *J. Autoimmun.* **2022**, *128*, 102812. [[CrossRef](#)]
101. Tabata, S.; Hosoi, H.; Murata, S.; Takeda, S.; Mushino, T.; Sonoki, T. Severe aplastic anemia after COVID-19 mRNA vaccination: Causality or coincidence? *J. Autoimmun.* **2022**, *126*, 102782. [[CrossRef](#)]
102. Radwi, M.; Farsi, S. A case report of acquired hemophilia following COVID-19 vaccine. *J. Thromb. Haemost.* **2021**, *19*, 1515–1518. [[CrossRef](#)]
103. Fatima, Z.; Reece, B.R.A.; Moore, J.S.; Means, R.T., Jr. Autoimmune Hemolytic Anemia after mRNA COVID Vaccine. *J. Investig. Med. High Impact Case Rep.* **2022**, *10*, 23247096211073258. [[CrossRef](#)]
104. Julian, J.A.; Mathern, D.R.; Fernando, D. Idiopathic Thrombocytopenic Purpura and the Moderna COVID-19 Vaccine. *Ann. Emerg. Med.* **2021**, *77*, 654–656. [[CrossRef](#)] [[PubMed](#)]
105. Greinacher, A.; Langer, F.; Makris, M.; Pai, M.; Pavord, S.; Tran, H.; Warkentin, T.E. Vaccine-induced immune thrombotic thrombocytopenia (VITT): Update on diagnosis and management considering different resources. *J. Thromb. Haemost.* **2022**, *20*, 149–156. [[CrossRef](#)] [[PubMed](#)]

106. Alghamdi, A.N.; Alotaibi, M.I.; Alqahtani, A.S.; al Aboud, D.; Abdel-Moneim, A.S. BNT162b2 and ChAdOx1 SARS-CoV-2 Post-vaccination Side-Effects among Saudi Vaccinees. *Front. Med.* **2021**, *8*, 760047. [CrossRef] [PubMed]
107. Kubota, K.; Saginoya, T.; Ishiwata, K.; Nakasato, T.; Munechika, H. [¹⁸F]FDG uptake in axillary lymph nodes and deltoid muscle after COVID-19 mRNA vaccination: A cohort study to determine incidence and contributing factors using a multivariate analysis. *Ann. Nucl. Med.* **2022**, *36*, 340–350. [CrossRef]
108. Minamimoto, R.; Kiyomatsu, T. Effects of COVID-19 vaccination on FDG-PET/CT imaging: A literature review. *Glob. Health Med.* **2021**, *3*, 129–133. [CrossRef] [PubMed]
109. Nassar, M.; Chung, H.; Dhayaparan, Y.; Nyein, A.; Acevedo, B.J.; Chicos, C.; Zheng, D.; Barras, M.; Mohamed, M.; Alfishawy, M.; et al. COVID-19 vaccine induced rhabdomyolysis: Case report with literature review. *Diabetes Metab. Syndr.* **2021**, *15*, 102170. [CrossRef]
110. Sahu, D.; Shetty, G. Frozen shoulder after COVID-19 vaccination. *JSES Int.* **2022**, *4*, 234–238. [CrossRef]
111. Suzuki, Y.; Ishihara, H. Difference in the lipid nanoparticle technology employed in three approved siRNA (Patisiran) and mRNA (COVID-19 vaccine) drugs. *Drug Metab. Pharmacokinet.* **2021**, *41*, 100424. [CrossRef]
112. Suhr, O.B.; Coelho, T.; Buades, J.; Pouget, J.; Conceicao, I.; Berk, J.; Schmidt, H.; Waddington-Cruz, M.; Campistol, J.M.; Bettencourt, B.R.; et al. Efficacy and safety of patisiran for familial amyloidotic polyneuropathy: A phase II multi-dose study. *Orphanet J. Rare Dis.* **2015**, *10*, 109. [CrossRef]
113. Kimura, A.; Kishimoto, T. IL-6: Regulator of Treg/Th17 balance. *Eur. J. Immunol.* **2010**, *40*, 1830–1835. [CrossRef]
114. Tseng, C.T.; Sbrana, E.; Iwata-Yoshikawa, N.; Newman, P.C.; Garron, T.; Atmar, R.L.; Peters, C.J.; Couch, R.B. Immunization with SARS coronavirus vaccines leads to pulmonary immunopathology on challenge with the SARS virus. *PLoS ONE* **2012**, *7*, e35421. [CrossRef]
115. Lindsley, A.W.; Schwartz, J.T.; Rothenberg, M.E. Eosinophil responses during COVID-19 infections and coronavirus vaccination. *J. Allergy Clin. Immunol.* **2020**, *146*, 1–7. [CrossRef] [PubMed]
116. Ramos, S.G.; Rattis, B.; Ottaviani, G.; Celes, M.R.N.; Dias, E.P. ACE2 Down-Regulation May Act as a Transient Molecular Disease Causing RAAS Dysregulation and Tissue Damage in the Microcirculatory Environment among COVID-19 Patients. *Am. J. Pathol.* **2021**, *191*, 1154–1164. [CrossRef] [PubMed]
117. Bukowska, A.; Spiller, L.; Wolke, C.; Lendeckel, U.; Weinert, S.; Hoffmann, J.; Bornfleth, P.; Kutschka, I.; Gardemann, A.; Isermann, B.; et al. Protective regulation of the ACE2/ACE gene expression by estrogen in human atrial tissue from elderly men. *Exp. Biol. Med.* **2017**, *242*, 1412–1423. [CrossRef]
118. Agha-Alinejad, H.; Hekmatikar, A.H.A.; Ruhee, R.T.; Shamsi, M.M.; Rahmati, M.; Khoramipour, K.; Suzuki, K. A Guide to Different Intensities of Exercise, Vaccination, and Sports Nutrition in the Course of Preparing Elite Athletes for the Management of Upper Respiratory Infections during the COVID-19 Pandemic: A Narrative Review. *Int. J. Environ. Res. Public Health* **2022**, *19*, 1888. [CrossRef]
119. Piercy, K.L.; Troiano, R.P.; Ballard, R.M.; Carlson, S.A.; Fulton, J.E.; Galuska, D.A.; George, S.M.; Olson, R.D. The Physical Activity Guidelines for Americans. *JAMA* **2018**, *320*, 2020–2028. [CrossRef]
120. Sahin, U.; Muik, A.; Derhovanessian, E.; Vogler, I.; Kranz, L.M.; Vormehr, M.; Baum, A.; Pascal, K.; Quandt, J.; Maurus, D.; et al. COVID-19 vaccine BNT162b1 elicits human antibody and TH1 T cell responses. *Nature* **2020**, *586*, 594–599. [CrossRef]
121. Mizuno, Y.; Hokimoto, S.; Harada, E.; Kinoshita, K.; Yoshimura, M.; Yasue, H. Variant Aldehyde Dehydrogenase 2 (ALDH2*2) in East Asians Interactively Exacerbates Tobacco Smoking Risk for Coronary Spasm-Possible Role of Reactive Aldehydes. *Circ. J.* **2016**, *81*, 96–102. [CrossRef]
122. Voskoboinik, A.; Kalman, J.M.; de Silva, A.; Nicholls, T.; Costello, B.; Nanayakkara, S.; Prabhu, S.; Stub, D.; Azzopardi, S.; Vizi, D.; et al. Alcohol Abstinence in Drinkers with Atrial Fibrillation. *N. Engl. J. Med.* **2020**, *382*, 20–28. [CrossRef]
123. Kageyama, T.; Ikeda, K.; Tanaka, S.; Taniguchi, T.; Igari, H.; Onouchi, Y.; Kaneda, A.; Matsushita, K.; Hanaoka, H.; Nakada, T.A.; et al. Antibody responses to BNT162b2 mRNA COVID-19 vaccine and their predictors among healthcare workers in a tertiary referral hospital in Japan. *Clin. Microbiol. Infect.* **2021**, *27*, 1861.e1–1861.e5. [CrossRef]
124. Watanabe, M.; Balena, A.; Tuccinardi, D.; Tozzi, R.; Risi, R.; Masi, D.; Caputi, A.; Rossetti, R.; Spoltore, M.E.; Filippi, V.; et al. Central obesity, smoking habit, and hypertension are associated with lower antibody titres in response to COVID-19 mRNA vaccine. *Diabetes Metab. Res. Rev.* **2022**, *38*, e3465. [CrossRef] [PubMed]
125. Tochihiro, Y. A review of Japanese-style bathing: Its demerits and merits. *J. Physiol. Anthropol.* **2022**, *41*, 5. [CrossRef] [PubMed]
126. Japanese Government Statistics by Ministry of Health, Labour and Welfare. Available online: <https://www.mhlw.go.jp/content/10601000/000675088.pdf> (accessed on 26 April 2022). (In Japanese)
127. US Centers for Disease Control and Prevention. Science Brief: Evidence Used to Update the List of Underlying Medical Conditions Associated with Higher Risk for Severe COVID-19. Available online: <https://www.cdc.gov/coronavirus/2019-ncov/science/science-briefs/underlying-evidence-table.html> (accessed on 20 May 2022).
128. Machado, P.M.; Lawson-Tovey, S.; Strangfeld, A.; Mateus, E.F.; Hyrich, K.L.; Gossec, L.; Carmona, L.; Rodrigues, A.; Raffener, B.; Duarte, C.; et al. Safety of vaccination against SARS-CoV-2 in people with rheumatic and musculoskeletal diseases: Results from the EULAR Coronavirus Vaccine (COVAX) physician-reported registry. *Ann. Rheum. Dis.* **2022**, *81*, 695–709. [CrossRef] [PubMed]
129. Japanese Government Statistics by Ministry of Health, Labour and Welfare. Available online: <https://www.cov19-vaccine.mhlw.go.jp/qa/0028.html> (accessed on 20 May 2022). (In Japanese)