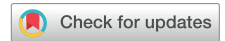

# An Unrecognized Contraindication to Transesophageal Echocardiographic Probe Placement: The Aberrant Right Subclavian Artery



David A. Apatov, MD, Jessica L. Spellman, MD, Hiroo Takayama, MD, PhD, and Mark J. Heath, MD, *New York, New York*

## INTRODUCTION

The aberrant right subclavian artery (ARSA) is a vascular anomaly of the aortic arch, seen in 0.16% to 2% of the population, that originates distal to the left subclavian artery rather than its usual anatomic location from the brachiocephalic trunk (Figure 1).<sup>1,2</sup> The ARSA tracks across the mediastinum to the right arm along a retroesophageal course in 85% of patients but can take courses between the esophagus and trachea or in front of the trachea.<sup>3,4</sup> An ARSA can cause symptoms such as dysphagia, cough, dyspnea, and chest pain, but the majority of patients with this anomaly are asymptomatic.<sup>5</sup>

Patients with an ARSA may require cardiac surgery using intraoperative transesophageal echocardiographic (TEE) imaging given that there is an association between congenital aortic arch abnormalities and cardiac defects. Current guidelines for TEE imaging do not address screening of this anomaly or the risks of performing TEE examinations in patients with ARSAs.<sup>6</sup> Prolonged examinations and frequent probe manipulations during cardiac surgery may lead to undesired consequences in patients with ARSAs. This case highlights an adult patient with this vascular anomaly presenting for cardiac surgery and describes the observed effects of a TEE probe on the patient's ARSA.

## CASE PRESENTATION

A 54-year-old woman with severe aortic stenosis and a bicuspid aortic valve presented for open aortic valve replacement. The patient had a history significant for hypothyroidism, coarctation of the aorta surgically repaired as an infant and stented 10 years before presentation, and an ARSA that was incidentally found on computed tomography angiography performed during preoperative testing. The ARSA took a retroesophageal course to the right arm (Figure 2). The patient denied any dysphagia, dyspnea, or any other symptoms thought to be due to the ARSA.

From the Department of Anesthesiology (D.A.A., J.L.S., M.J.H.), and the Department of Cardiothoracic Surgery (H.T.), New York-Presbyterian/Columbia University Irving Medical Center, New York, New York.

Keywords: Transesophageal echocardiography, Aberrant right subclavian artery, Vascular anomaly, Thoracic outlet obstruction, Arterioesophageal fistula

Conflicts of interest: The authors reported no actual or potential conflicts of interest relative to this document.

Copyright 2020 by the American Society of Echocardiography. Published by Elsevier Inc. This is an open access article under the CC BY-NC-ND license (<http://creativecommons.org/licenses/by-nc-nd/4.0/>).

2468-6441

<https://doi.org/10.1016/j.case.2020.07.003>

448

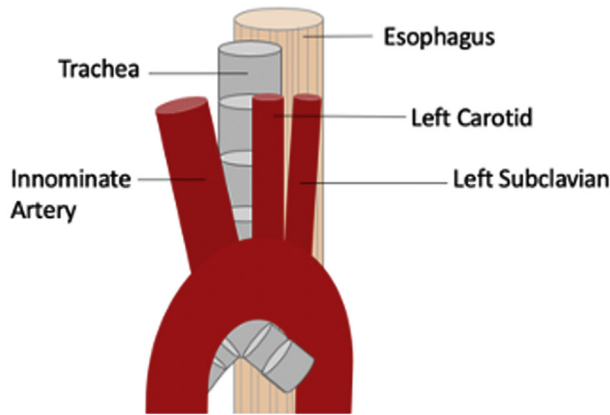
A preinduction arterial line was placed in the right radial artery to monitor right arm perfusion in the setting of eventual TEE probe advancement, and a noninvasive blood pressure cuff was placed on the left arm for comparison. The anesthesiologists induced general anesthesia without issue. A TEE probe (Phillips X7-2t TEE transducer; Philips Medical Systems, Andover, MA) was then carefully advanced without encountering resistance, but the probe caused dampening of the arterial line waveform, followed by a total lack of pulsatility when the probe was positioned to about 25 cm at the patient's lips. With further advancement of the TEE probe to 27 cm, the right radial arterial line pulsatility returned. Because the TEE probe proved to affect right arm perfusion at certain depths, a left radial arterial line was placed to provide a continuous comparison between right arm perfusion and perfusion not supplied by the ARSA. The right and left radial arterial lines showed a slight difference in arterial pressure when the TEE probe was at a depth of  $\geq 27$  cm. However, at a depth of 25 cm, the right radial arterial line showed a lack of pulsatility and a mean arterial pressure of 45 mm Hg, while the left radial arterial line showed normal pulsatility and a mean arterial pressure of 73 mm Hg (Figure 3).

On the basis of these findings, it appeared that the TEE probe's tip (maximum width 15 mm) was large enough to compress the ARSA, while the probe's more narrow shaft (maximum width 10 mm) did not have any effect on ARSA blood flow. The anesthesia and surgical teams decided that the benefits of intraoperative TEE imaging outweighed the potential vascular consequences related to the patient's ARSA, and the operation proceeded with the TEE probe in place. The anesthesia team vigilantly monitored right arm perfusion and avoided withdrawing the probe to a depth of 25 cm, to prevent the head of the TEE probe from compressing the ARSA.

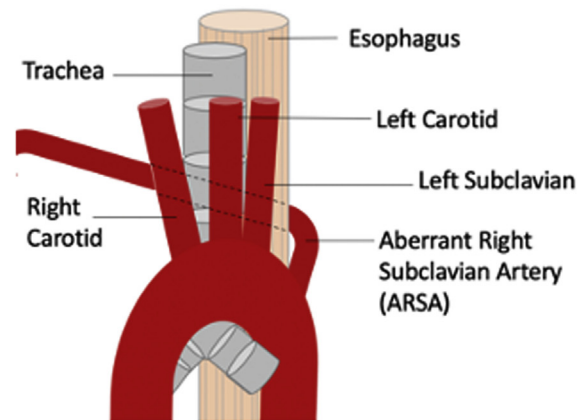
The TEE probe remained in the patient's esophagus for a total duration of about 5 hours, and the right and left radial arterial line pressures remained similar throughout the operation. At the conclusion of the procedure, the TEE probe was removed without resistance and again caused a brief loss of right arm perfusion when it was at a depth of 25 cm at the patient's lips. There was no noticeable blood on the TEE probe, and normal gastric contents were suctioned from an orogastric tube.

The patient was brought to the intensive care unit in stable condition, and the operating room teams communicated the events related to the patient's ARSA to the intensive care unit providers. She was extubated on the day of surgery and denied any dyspnea or dysphagia. Right and left radial arterial lines continued to show similar blood pressure readings and were removed on postoperative day 1. The remainder of her hospital stay was uneventful. She continued to deny any symptoms related to the ARSA and was discharged home on postoperative day 3. She continued to do well and reported no symptoms during a follow-up visit 1 month after surgery.

**A. Normal Arch Anatomy**



**B. ARSA (shown most common, retroesophageal)**



**Figure 1** ARSA illustration.

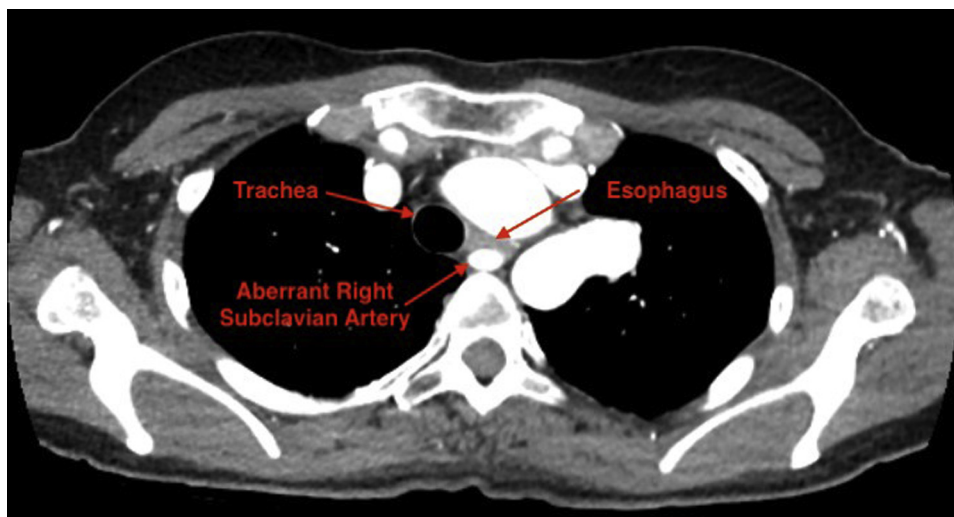
**DISCUSSION**

In a radiologic analysis of patients with retroesophageal ARSAs, the median distance between the ARSA and trachea was 5.5 mm (range, 0–13 mm).<sup>2</sup> On the basis of these findings, any object placed in the esophagus could cause contact between the esophageal wall and the ARSA, which can decrease right arm perfusion and potentially compromise arterial wall integrity, similar to thoracic outlet obstruction. An arterioesophageal fistula is potentially the most devastating consequence of prolonged contact between these two structures. Previous case reports describe unique events in which esophageal stents, salivary bypass tubes, and nasogastric tubes caused arterioesophageal fistulas in patients with ARSAs. In each of these reports, the authors speculated that the fistulas formed because of multiple days of pressure necrosis incited by the rigid esophageal devices.<sup>7-9</sup>

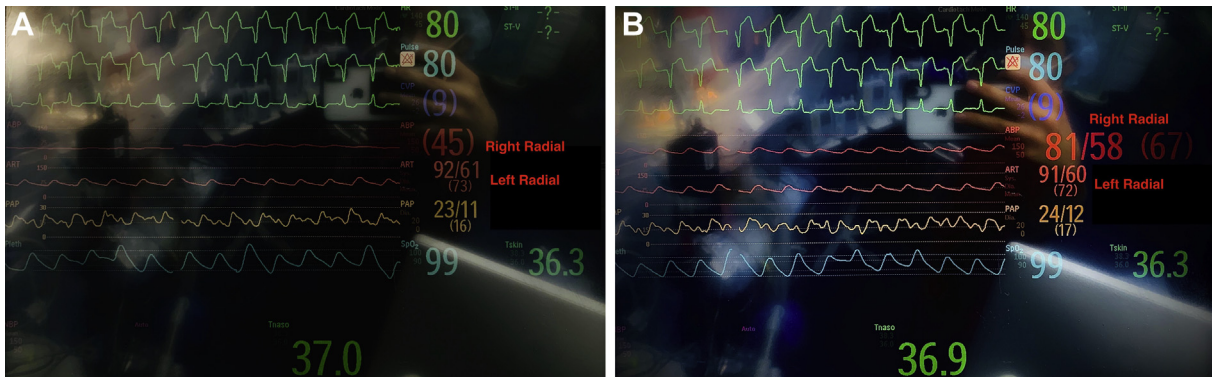
Previous reports describe the use of TEE imaging for cardiac surgery in adult and pediatric patients with ARSAs. Within the pediatric population, certain authors describe omitting the intraoperative TEE examination while proceeding with surgery after noticing ARSA

compression from probe placement, while others report the use of intraoperative TEE imaging in the setting of an ARSA without complications.<sup>10,11</sup> Park *et al.*<sup>12</sup> described safely using a pediatric-sized TEE probe (maximum diameter 10.9 mm) for cardiac surgery in an adult with an ARSA after they noticed effects on ARSA blood flow due to compression from an adult-sized probe (maximum diameter 14 mm). Patient size, TEE probe width, and the necessity of TEE imaging are all factors to consider in determining the appropriateness of performing a TEE examination in a patient with an ARSA.

This is the first report of an adult patient undergoing cardiac surgery with an adult TEE probe in the setting of ARSA outlet obstruction. The adult-sized probe did not appear to compress the ARSA after the probe's head was advanced past the level of the ARSA. However, this may not be the case in every patient with an ARSA requiring TEE imaging. As described by Krupiński *et al.*,<sup>2</sup> an ARSA's diameter at the level of the esophagus, as well as its distance from the trachea, can vary. Placing a TEE probe in a patient with a large ARSA, or one nearly adjacent to the esophagus, could potentially lead to right arm injury or damage to the ARSA. As seen in reports involving other



**Figure 2** Preoperative computed tomographic angiogram showing retroesophageal course of ARSA.



**Figure 3** Intraoperative monitors displaying right and left radial artery tracings with TEE probe at 25 cm (A) and 27 cm (B).

esophageal devices, it is plausible that in extreme instances, a probe could even lead to an arterioesophageal fistula.

## CONCLUSION

This case and the publications reviewed in this report highlight important considerations to take into account before placing a TEE probe in a patient with an ARSA. First, it is imperative to review imaging to assess the ARSA's diameter, path to the right arm, and distance from the esophagus, keeping in mind that these factors can affect a TEE probe's ability to compress the artery. Additionally, imaging can help determine whether the right vertebral artery is attached to the ARSA. In instances in which the right vertebral artery is attached to the ARSA, cerebral oximetry and intraoperative neuromonitoring may be useful to ensure adequate cerebral perfusion while the TEE probe is in place.

Planning to place an arterial line in the right upper extremity will help determine the extent of ARSA compression. A second mode of measuring blood pressure using the left upper extremity or either lower extremity can help ensure that right arm perfusion is similar to perfusion throughout the rest of the body. As always, practitioners should exercise great caution when encountering resistance during TEE probe placement. In a patient with an ARSA, advancing past resistance may indicate significant force applied to the ARSA and could presumably lead to damage to the arterial wall. After determining the extent of compression of the artery, it is important to evaluate if the compression resolves with further advancement of the TEE probe head past the artery's course to the right arm. As seen in this patient and previous ARSA case reports, significant damage to the artery or right arm seems unlikely if the ARSA is compressed for just a brief period of time. If ARSA compression appears to be significant and unrelenting regardless of TEE probe depth, it may be prudent to consider the option of using a pediatric probe or omitting the intraoperative TEE examination to avoid prolonged ARSA compression. Although TEE probe dimensions may vary by size and brand, the extent of ARSA compression will ultimately depend on the artery's characteristics, such as width and proximity to the esophagus.

After deciding that it is safe to proceed with intraoperative TEE imaging, it is imperative to continue to monitor right arm perfusion throughout the operation. Surgical retraction and manipulation of thoracic structures can potentially cause a probe to exert force upon the ARSA. In addition, monitor for changes in right arm perfusion when manipulating the TEE probe. Because upper esophageal views may bring the probe's head closer to the ARSA, it may be necessary to

avoid performing these views in patients who prove to be very susceptible to ARSA compression.

These recommendations are relevant only when a patient presents for cardiac surgery with a known diagnosis of an ARSA. Given the prevalence of ARSA of 0.16% to 2% of the population and the fact that ARSAs are usually asymptomatic, patients may present to the operating room before this aortic arch anomaly is diagnosed.<sup>1,2</sup> With this in mind, it may be necessary to ensure appropriate right arm perfusion with TEE imaging in patients who have not undergone preoperative aortic arch imaging. Practitioners should consider undiagnosed ARSA in patients who exhibit decreased right arm perfusion during or soon after TEE probe placement.

The American Society of Echocardiography guidelines list absolute and relative contraindications to performing TEE imaging, but the guidelines do not address the safety of placing a TEE probe in a patient with an ARSA.<sup>6</sup> On the basis of this case description of a patient undergoing cardiac surgery with TEE imaging without complications, an ARSA should not be an absolute contraindication to performing a TEE examination. However, an ARSA may be a relative contraindication on the basis of its anatomic susceptibility to compression and the potential for significant harm as a result of prolonged compression or large amounts of force applied to the arterial wall. Categorizing an ARSA as a relative contraindication to TEE imaging may prevent negative outcomes in patients with this vascular anomaly.

## REFERENCES

1. Choi Y, Chung SB, Kim MS. Prevalence and anatomy of aberrant right subclavian artery evaluated by computed tomographic angiography at a single institution in Korea. *J Korean Neurosurg Soc* 2019;62:175-82.
2. Krupiński M, Irzyk M, Moczulski Z, Banyś R, Dwojak I, Urbańczyk-zawadzka M. CT evaluation of aberrant right subclavian artery: anatomy and clinical implications. *Cardiol Young* 2019;29:128-32.
3. Chadha NK, Chiti-Batelli S. Tracheostomy reveals a rare aberrant right subclavian artery; a case report. *BMC Ear Nose Throat Disord* 2004;4:1.
4. Sukumaran TT. An anomalous right subclavian artery with a retrotracheal course: a case report. *J Clin Diagn Res* 2015;9:AD01-2.
5. Janssen M, Baggen MG, Veen HF, Smout AJ, Bekkers JA, Jonkman JG, et al. Dysphagia lusoria: clinical aspects, manometric findings, diagnosis, and therapy. *Am J Gastroenterol* 2000;95:1411-6.
6. Hahn RT, Abraham T, Adams MS, Bruce CJ, Glas KE, Lang RM, et al. Guidelines for performing a comprehensive transesophageal echocardiographic examination: recommendations from the American Society of Echocardiography and the Society of Cardiovascular Anesthesiologists. *Anesth Analg* 2014;118:21-68.

7. Feugier P, Lemoine L, Gruner L, Bertin-maghit M, Rousselet B, Chevalier JM. Arterioesophageal fistula: a rare complication of retroesophageal subclavian arteries. *Ann Vasc Surg* 2003;17:302-5.
8. Hosn MA, Haddad F, El-Merhi F, Safadi B, Hallal A. Repair of an aberrant subclavian arterioesophageal fistula following esophageal stent placement. *World J Gastrointest Surg* 2014;6:117-21.
9. Inman JC, Kim P, McHugh R. Retroesophageal subclavian artery-esophageal fistula: a rare complication of a salivary bypass tube. *Head Neck* 2008;30:1120-3.
10. Koinig H, Schlemmer M, Keznickl FP. Occlusion of the right subclavian artery after insertion of a transoesophageal echocardiography probe in a neonate. *Paediatr Anaesth* 2003;13:617-9.
11. Bensky AS, O'Brien JJ, Hammon JW. Transesophageal echo probe compression of an aberrant right subclavian artery. *J Am Soc Echocardiogr* 1995;8:964-6.
12. Park SY, Kim DH, Joe HB, Park SK, Hwang JH, Hong YW. Occlusion of the right subclavian artery after insertion of a transesophageal echocardiography probe in an adult with a vascular ring—a case report. *Korean J Anesthesiol* 2010;59:283-5.