



Contents lists available at ScienceDirect

International Journal of Surgery Case Reports

journal homepage: www.casereports.com

Successful endovascular management of endoleak-like phenomenon following open abdominal aortic aneurysm repair

Haider Khan Bangash^a, Mitra Rahmatzeh^a, Bibombe P. Mwiripatayi^{a,b,*}^a Department of Vascular Surgery, Royal Perth Hospital, Perth, Western Australia, Australia^b School of Surgery, Faculty of Medicine, Dentistry and Health Sciences, Western Australia, Australia

ARTICLE INFO

Article history:

Received 5 September 2016

Accepted 30 October 2016

Available online 3 November 2016

Keywords:

Case report

Abdominal aortic aneurysm

Endoleak

Anastomotic dehiscence

Endovascular management

ABSTRACT

INTRODUCTION: Endoleaks are a well-known complication after endovascular aortic repair. Type I endoleak-like phenomenon (also defined as a proximal pseudoaneurysm) post-open abdominal aortic aneurysm (AAA) repair is described as an anastomotic leak causing recurrent pressurization of the original aneurysm sac. It is rare but may result in aneurysmal sac rupture into the peritoneal cavity.

REPORT: A 78-year-old man presented with a progressively enlarged aneurysmal sac due to proximal anastomotic degeneration of the proximal suture line associated with an outflow through a patent large lumbar vessel following a previous emergency open AAA repair. This was successfully treated using a combination coils and ethylene-vinyl alcohol copolymer. An Endoluminal tube stent graft was successfully deployed to seal the aortic anastomotic dehiscence.

CONCLUSION: Endovascular treatment of an anastomotic dehiscence associated with a large outflow lumbar artery post-open AAA repair is feasible and safe.

© 2016 The Authors. Published by Elsevier Ltd on behalf of IJS Publishing Group Ltd. This is an open access article under the CC BY-NC-ND license (<http://creativecommons.org/licenses/by-nc-nd/4.0/>).

1. Introduction

Endoleak is defined as blood flow outside an endoluminal graft but within an adjacent aneurysm sac or segment [1]. This was first described in patients following endovascular repair of abdominal aortic aneurysm (AAA), and its occurrence was similarly established in patients who underwent open AAA repair, after a series of 6 patients with a type I endoleak-like phenomenon (also defined as a proximal pseudoaneurysm) was reported [2]. It is related with a proximal anastomotic dehiscence, resulting in a recurrent aneurysmal sac. It remains a rare but serious complication of open AAA repair; only a few type I or II endoleak cases have since been reported [3].

We describe a patient, who presented with a proximal endoleak associated with a large lumbar outflow vessel (6 years after emergency open repair for a ruptured AAA) that may result in a development of a potential future type II endoleak. It was successfully managed with a combination of endovascular therapeutic procedures.

Patient consent was obtained for reporting this case.

* Corresponding author at: School of Surgery, University of Western Australia, Department of Vascular Surgery, Royal Perth Hospital, Level 2, MRF Building, Perth, Australia.

E-mail address: bibombe@inet.net.au (B.P. Mwiripatayi).

<http://dx.doi.org/10.1016/j.ijscr.2016.10.072>

2210-2612/© 2016 The Authors. Published by Elsevier Ltd on behalf of IJS Publishing Group Ltd. This is an open access article under the CC BY-NC-ND license (<http://creativecommons.org/licenses/by-nc-nd/4.0/>).

2. Case report

In 2009, a 78-year-old man presented with a ruptured AAA and underwent emergency open AAA repair with a 20 mm × 15 cm Ultramax graft™ (Atrium Maquet Getinge Group, NH, USA).

He presented to the emergency department in 2015 with abdominal discomfort. Urgent abdominal computed tomography (CT) detected an 88-mm aneurysmal sac and type I endoleak-like phenomenon associated with an outflow through a patent lumbar vessel (Fig. 1a & b) that had the potential to develop a late type II endoleak. This was due to partial dehiscence of the posterior proximal suture line, with the leak communicating with a large lumbar artery anterior to the mid-body of the L4 vertebra, causing recurrent pressurization of the original aneurysm sac. A semi-urgent endovascular repair was performed using combined femoral and brachial approaches. Through a left brachial approach, a 90-cm, 7-Fr Flexor® Shuttle® Guiding Sheath (COOK® Medical, Bloomington, IN, USA) was introduced into the aneurysmal sac via the dehisced portion of the suture line. A 120-cm MPA-A2 guiding catheter (Cordis Cardinal Health, Dublin, OH, USA) was inserted to the lumbar vessel (Fig. 2). A 2.7-mm Progreat® microcatheter (TERUMO® Medical Corporation, Tokyo, Japan) was inserted into the guiding catheter using a co-axial technique. A left femoral approach was considered but a left brachial approach was used because it offers direct and easy access to the pseudoaneurysm sac and lumbar artery and allows the 7-Fr Flexor® Shuttle® Guiding Sheath to remain in situ without any interference. Moreover, we wanted to keep left femoral access available

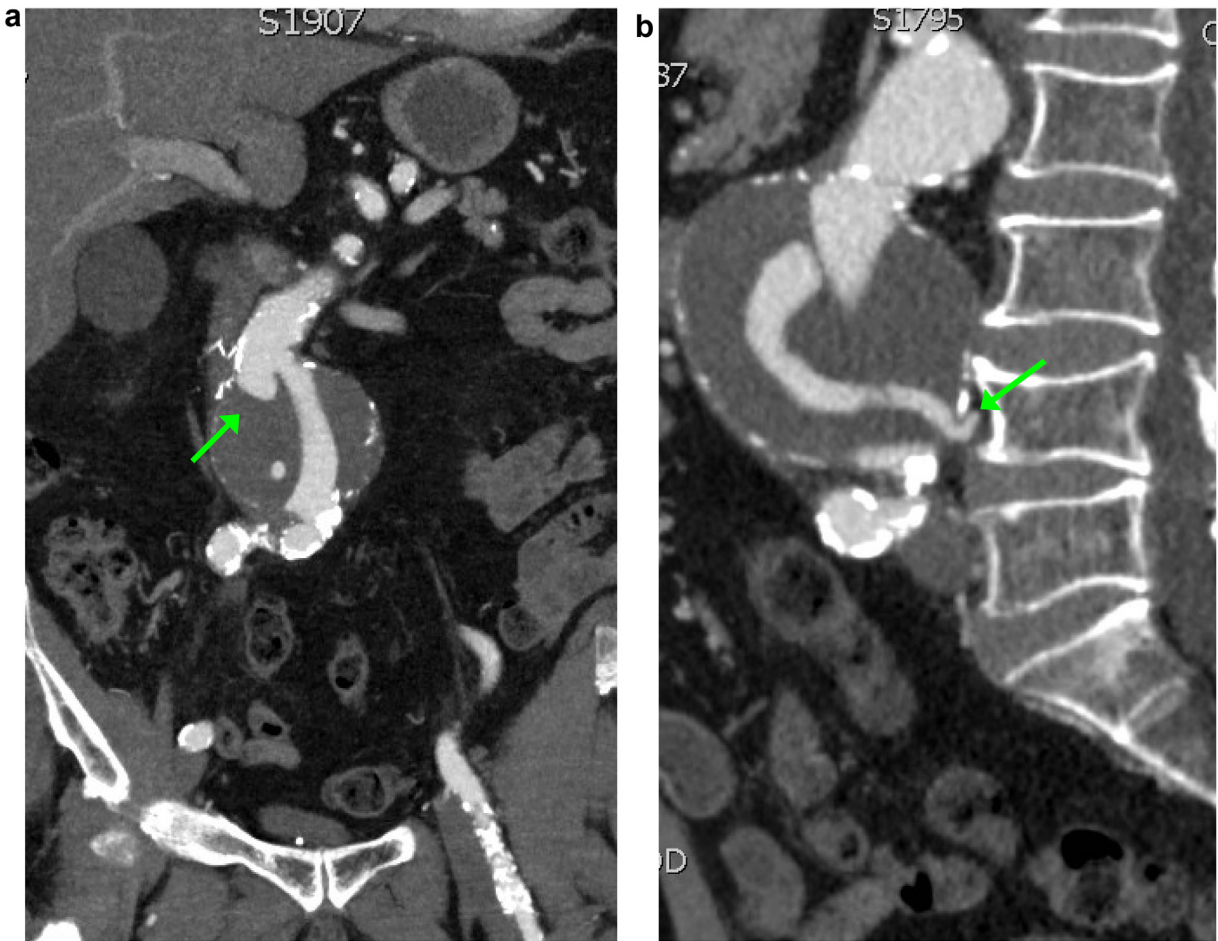


Fig. 1. (a) Computed tomography angiogram (CTA), coronal reconstruction view, showing Type Ia endoleak filling aneurysmal sac. (b) CTA sagittal reconstruction view demonstrating the type Ia endoleak associated with an outflow through a patent lumbar vessel (green arrow) that potentially will cause a type II endoleak.

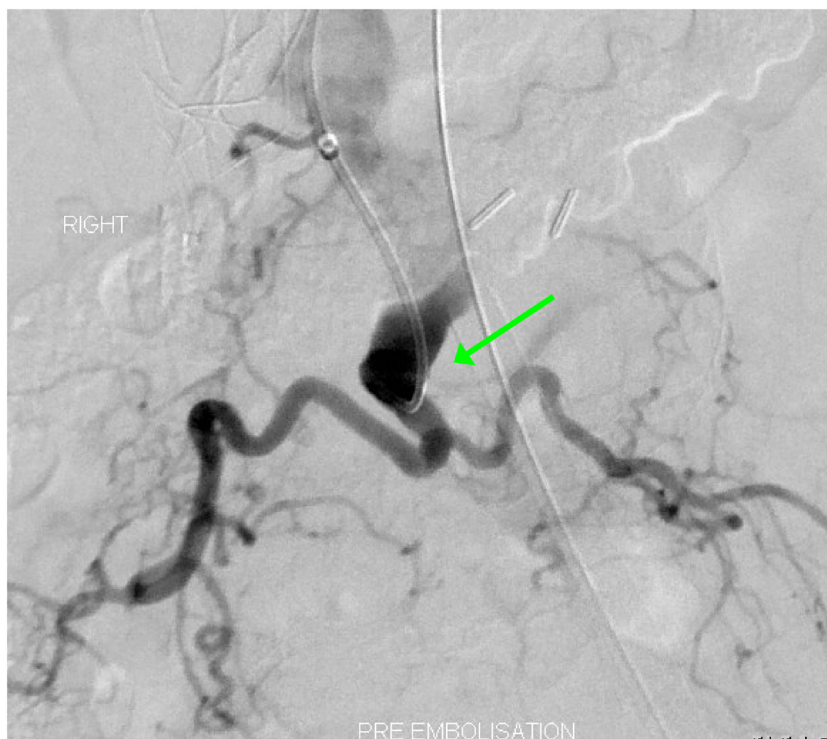


Fig. 2. Digital subtraction angiography (DSA) demonstrating outflow type II endoleak into patent lumbar artery and branches (green arrow).

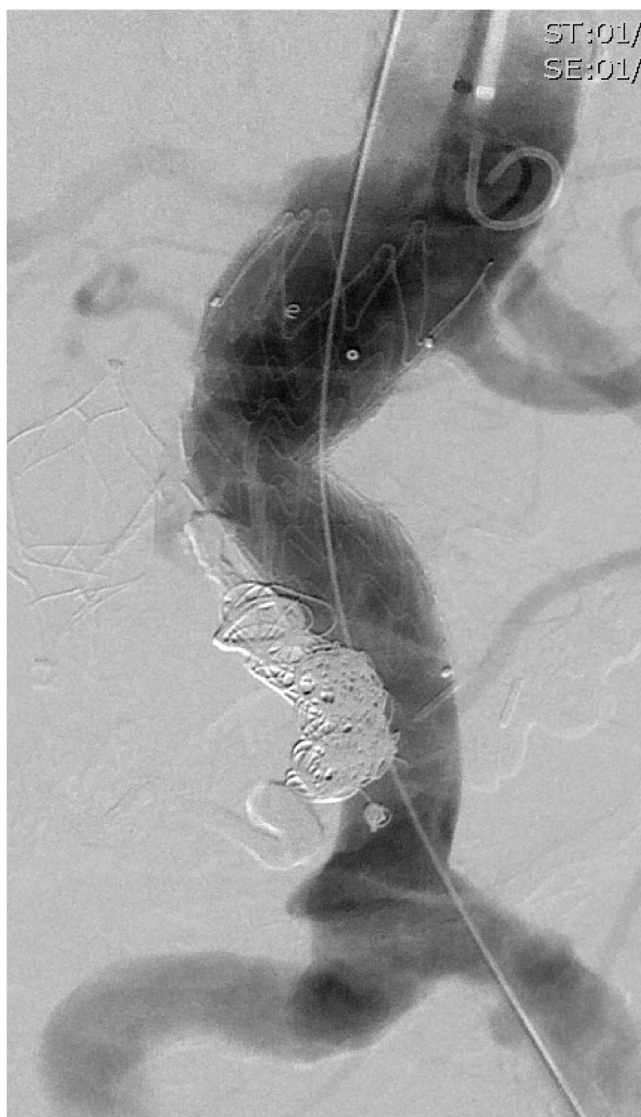


Fig. 3. DSA post coil embolization of lumbar vessel and deployment of Endurant stent graft showing no endoleak.

for any unexpected intra-operative interventions. Using a preclose technique, the right common femoral artery was accessed, and a 35-cm long 20-Fr sheath (Cordis Cardinal Health™, Dublin, OH, USA) was inserted over a Lunderquist® extra-stiff wire (COOK® Medical, Bloomington, IN, USA) up to the level of the renal arteries. The lumbar artery and branches were coiled prophylactically using an AZUR® CX (TERUMO® Medical Corporation) and Onyx® LES (Medtronic Cardiovascular, Santa Rosa, CA, USA). An angiogram confirmed no post-coiling flow in the lumbar branch. An Endurant tube stent graft (Medtronic Cardiovascular, Santa Rosa, CA, USA) was adequately deployed. The completion angiogram confirmed no endoleak (Fig. 3). The follow-up CT at 6 weeks post-operative showed no evidence of endoleak, and the patient remained well.

3. Discussion

Complications following open AAA repair are well described, with a 1.4% rupture rate and 3.7% rate of any aneurysmal-related intervention over an 8-year follow-up period [4]. Given the low rate of long-term complications, surveillance of patients following open repair is usually not performed.

In the first description of endoleak following conventional open aneurysm surgery in a series of 6 patients with type I endoleak-like phenomenon, all patients underwent open repair with successful outcomes on subsequent surveillance [2]. Although type I/II endoleak-like phenomenon has since been recognised as a rare complication of open AAA repair, there have been only a few published reports of endoleak-like phenomenon that have resulted in recurrent pressurization of the original aneurysm sac [3].

Our patient presented with type I endoleak-like phenomenon, secondary to breakdown of the proximal suture line. Interestingly, there was antegrade filling of a large lumbar artery that did require a prophylactic embolization, to prevent any future type II endoleak after deployment of the aortic stent graft. In our institution, we selectively embolise the lumbar arteries, mostly the 3rd and 4th lumbar arteries, if the diameter is ≥ 2.5 mm and the inferior mesenteric artery if the diameter is >3.5 mm [4,5].

The timing of endoleak detection following open repair of AAA varies, ranging up to 12 years for detection of type I endoleak-like phenomenon presenting as a rupture [6]. This raises the issue of optimal follow-up after open AAA repair. No long-term follow up study has identified a case of endoleak after open AAA repair [7]. Another study using follow-up CT and MRI for open AAA repair reported a 2% late graft complication rate over a mean 87-month follow-up period, with no reported endoleaks [8]. Given the low complication rate, it would be hard to justify a similar protocol to that of endovascular repair after open AAA repair.

Nonetheless, endoleak-like phenomenon post-open AAA repair must be considered as a potential complication. They are related with anastomotic breakdown from loose sutures; this term, which had previously been used for occurrences after endovascular aortic repair, can be adopted for similar complications after open AAA repair, as long there is recurrent pressurization of the original aneurysm sac [2]. The challenge in the management of the present case was the combination of a patent large lumbar artery that would definitely result in a type II endoleak.

Type II endoleaks are the most common endoleaks encountered in clinical practice, accounting for approximately 40% of all endoleaks [9]. They occur when there is retrograde flow of blood into the aneurysm sac via an excluded aortic branch, most commonly the inferior mesenteric artery or a lumbar artery. Many type II endoleaks close spontaneously over time [9]. However, data suggest that patients with a persistent type II endoleak (>6 months) should be considered for more frequent follow-up and/or a more aggressive approach to reintervention [10]. The lumbar artery in the present case could have been accessed via the femoral approach using the Detino™ steerable sheath (Oscor®, Palm Harbor, Florida); unfortunately, this sheath is not available in Western Australia (Perth), and an alternative that avoids a brachial approach is not available.

4. Conclusion

Type I endoleak-like phenomenon following open repair remains a rare complication. Endovascular repair of endoleak-like phenomenon post-open AAA repair is feasible and safe and can be achieved via combined coiling and stent graft insertion.

Conflict of interests

The authors have no conflict of interest to declare.

Funding

Authors have no sources of funding to declare.

Ethical approval

No ethical approval needed for this manuscript.

Informed consent

Written informed consent was obtained from the patient. All specific patient information is de-identified.

Author contribution

BPM participated in the idea for the paper.
BPM and HKB were responsible for data collection.
BPM, HKB, and MR helped to draft this manuscript
All authors read and approved the final manuscript.

Guarantor

Dr Bibombe Patrice Mwipatayi.

References

- [1] G.H. White, W. Yu, J. May, Endoleak: a proposed new terminology to describe incomplete aneurysm exclusion by an endoluminal graft, *J. Endovasc. Surg.* 3 (1996) 23–25.
- [2] C.L. Chan, S.A. Ray, P.R. Taylor, S.C. Fraser, A.E. Giddings, Endoleaks following conventional open abdominal aortic aneurysm repair, *Eur. J. Vasc. Endovasc. Surg.* 19 (2000) 313–317.
- [3] M.D. Wheatcroft, R.J. Lonsdale, D. Turner, A complication of open abdominal aortic aneurysm repair closely resembling a type II endoleak, *J. Vasc. Surg.* 54 (2011) 1798–1800.
- [4] D. Löwenthal, L. Herzog, B. Rogits, K. Bulla, S. Weston, F. Meyer, Z. Halloul, M. Pech, J. Ricke, O. Dudeck, Identification of predictive CT angiographic factors in the development of high-risk type II endoleaks after endovascular aneurysm repair in patients with infrarenal aortic aneurysms, *Rofo* 187 (2015) 49–55.
- [5] T.J. Ward, S. Cohen, R.S. Patel, E. Kim, A.M. Fischman, F.S. Nowakowski, S.H. Ellozy, P.L. Faries, M.L. Marin, R.A. Lookstein, Anatomic risk factors for type-2 endoleak following EVAR: a retrospective review of preoperative CT angiography in 326 patients, *Cardiovasc. Interv. Radiol.* 201 (37) (2016) 324–328.
- [6] M. Matsushita, T. Ikezawa, H. Banno, Type 1 endoleak-like phenomenon causing rupture of the replaced aneurysm sac 12 years after open repair of abdominal aortic aneurysm, *Ann. Vasc. Dis.* 1 (2008) 118–120.
- [7] P.G. Kalman, D.C. Rappaport, N. Merchant, K. Clarke, K.W. Johnston, The value of late computed tomographic scanning in identification of vascular abnormalities after abdominal aortic aneurysm repair, *J. Vasc. Surg.* 29 (1999) 442–450.
- [8] M.F. Conrad, R.S. Crawford, J.D. Pedraza, D.C. Brewster, G.M. Lamuraglia, M. Corey, et al., Long-term durability of open abdominal aortic aneurysm repair, *J. Vasc. Surg.* 46 (2007) 669–675.
- [9] N. Arya, H.F. O’Kane, R.J. Hannon, B. Lee, C.V. Soong, Endoleak and endotension following open abdominal aortic aneurysm repair: a report of two cases, *Ann. Vasc. Surg.* 19 (2005) 431–433.
- [10] J.E. Jones, M.D. Atkins, D.C. Brewster, T.K. Chung, C.J. Kwolek, G.M. LaMuraglia, T.M. Hodgman, R.P. Cambria, Persistent type 2 endoleak after endovascular repair of abdominal aortic aneurysm is associated with adverse late outcomes, *J. Vasc. Surg.* 46 (2007) 1–8.

Open Access

This article is published Open Access at sciendoirect.com. It is distributed under the [IJSCR Supplemental terms and conditions](#), which permits unrestricted non commercial use, distribution, and reproduction in any medium, provided the original authors and source are credited.