






## CLINICAL ARTICLE

# Kirschner Wire as a Reference Marker for the Positioning of a Syndesmotic Screw: A Radiological Study and Clinical Evaluation

Congming Zhang, MD<sup>†</sup> , Chengcheng Zhang, MD<sup>†</sup> , Qiang Huang, MD<sup>†</sup>, Liang Sun, MD, Chen Ren, MD , Yao Lu, MD , Yibo Xu, MD , Hua Lin, MD, Kun Zhang, MD, Teng Ma, MD, Zhong Li, MD

Department of Orthopaedics and Traumatology, Xi'an Jiaotong University College of Medicine, Hong-Hui Hospital, Xi'an, China

**Objective:** No consensus has been reached regarding optimal implantation for a syndesmotic screw. Thus, we aimed to explore the feasibility of a reliable and static fibular incisura plane reference for ideal syndesmotic screw placement.

**Methods:** A retrospective review of computed tomography (CT) scans of 42 uninjured adult ankles with foot fractures were analyzed to measure the tibiofibular vertical distance (TFVD) at 2.5 cm proximal to the plafond from August 2016 to June 2017 in our hospital. The patients (20 females, 22 males) were divided into four groups according to their TFVD: 0–1, 1–2, 2–3, and 3–4 mm, and patients in each group were counted. We retrospectively assessed 41 patients (15 females, 26 males) who underwent syndesmotic screw fixation for ankle fractures from December 2015 to June 2020. We performed t-testing of two independent samples to determine the differences in the angle between the anatomic axis of the syndesmosis and screw axis (AAS) and ankle function using the American Orthopaedic Foot and Ankle Society (AOFAS) score at 3 and 6 months postoperatively between the conventional (20 patients) and K-wire marker (21 patients) groups. The correlation between the AAS and AOFAS score was analyzed.

**Results:** The TFVD measured  $2.23 \pm 1.01$  mm at 2.5 cm proximal to the plafond, and occurred at 25% of the distance from 2 to 3 mm in 47.6% of the patients. This new technique decreased AAS deformation by 62%, from  $13.01^\circ \pm 2.84^\circ$  to  $4.89^\circ \pm 2.43^\circ$ , in the conventional group ( $p < 0.001$ ). At 3 months postoperatively, the AOFAS scores of ankle function were similar in both groups, but it was significantly better in the new group than that of conventional group at the 6-month follow-up ( $p = 0.024$ ). There was a moderate negative correlation between AAS and AOFAS score at 6 months postoperatively ( $R = -0.684$ ). No obvious complications affecting ankle function were observed in either group postoperatively.

**Conclusions:** Surgeons can accurately place a screw trajectory using the fibular incisura plane as a reliable intraoperative reference. A 1.6-mm K-wire placed in the syndesmosis at 2.5 cm proximal to the tibial plafond could act as a static marker of the syndesmotic plane.

**Key words:** American Orthopaedic Foot and Ankle Society score; screw trajectory; syndesmosis; tibiofibular vertical distance

## Introduction

Approximately 13% of all ankle fractures are accompanied by injury to the syndesmosis<sup>1</sup>. To optimize outcomes and prevent the development of ankle arthritis, anatomic

reduction of the displaced syndesmosis is a critical step in the treatment of ankle fractures with syndesmotic injury<sup>2–4</sup>. More importantly, syndesmosis anatomic reduction has been the only significant predictor of improved functional outcome in

**Address for correspondence:** Zhong Li and Teng Ma, Department of Orthopaedics and Traumatology, Xi'an Jiaotong University College of Medicine, Hong-Hui Hospital, 555 Youyi Road, Xi'an City, 710054, China Email: [lizhong0607@126.com](mailto:lizhong0607@126.com) and [free40@126.com](mailto:free40@126.com)

<sup>†</sup>Represents co-first authors.

Received 15 November 2021; accepted 24 August 2022

short- and long-term studies<sup>5-7</sup>. Trans-syndesmotic fixation *via* dynamic or static methods is considered the most common technique for maintaining accurate reduction, although a meta-analysis of other methods revealed similar clinical outcomes<sup>8,9</sup>.

While numerous surgeons have recognized the importance of anatomic reduction and stabilization of the syndesmosis, the proportions of syndesmotic malreductions range from 16% to 52%<sup>2,10-12</sup>. Previous data indicate that an eccentric clamp or screw trajectory may lead to syndesmotic malreduction<sup>13,14</sup>. Ideally, the reductional clamp and screw would be placed in line with the trans-syndesmotic angle to avoid malreduction<sup>15</sup>. Although the syndesmotic screw is suggested to be angulated at 20°–30° (usually closer to 30°) to the horizontal plane, different opinions have been reported in recent literature<sup>16-18</sup>. Park *et al.* reported that the ideal angle of screw trajectory, using the second toe as reference, is approximately 18°<sup>19</sup>. Putnam *et al.* measured this angle to be around 21° on two-dimensional computed tomography (CT) slices using a lateral radiograph as reference<sup>16</sup>. One possible explanation for the discrepancy in the angle is the application of varying marker for syndesmotic screw placement. Given the continued debates related to the inclination angle of syndesmotic screw and reference during operation, further studies are needed to determine a reliable and static reference for syndesmotic screw placement.

To find a more ideal marker for trans-syndesmotic screw placement, it is important to understand the anatomical structure of the syndesmosis. The syndesmosis is externally rotated approximately 30° in relation to the femoral trans-epicondylar axis<sup>20</sup>. The tibial incisura is a concave triangle that aims to match the convex shape of the fibula, with its apex 6–8 cm above the level of the ankle joint plafond<sup>21</sup>. The direct contact area between the tibia and fibula has been a significant reference of syndesmotic joint reduction during operation. The contacted surfaces are covered with a small strip of hyaline cartilage with thickness of 0.5 mm–1.0 mm<sup>22</sup>. During operation, constructing the axis of the reduction forceps through the tibiofibular contact is a reliable method for reducing excessive reduction, based on our experiences. The facet of the tibial side cartilage is continuous to the cartilage covering the tibial plafond, and its average maximum height is  $5.7 \pm 1.7$  (range, 5.6–5.8) mm<sup>22</sup>.

By reviewing the distal tibiofibular syndesmosis anatomy, it is clear that ideal trans-syndesmotic screw placement during surgery is dependent of an accurate marker of the fibular incisura plane. After examining continuous pictures of CT scans, the plane of fibular incisura of the tibia and the medial border of the fibula were gradually separated from closed contact and the gap became increasingly larger. Therefore, the research hypothesis proposed in this study is that it was possible to mark the surface of the fibular incisura during operation by finding a suitable position in the syndesmosis by inserting a K-wire with a suitable diameter above the ankle joint.

Therefore, the purpose of this study was to (i) detect the ideal position for the insertion of a K-wire between the

tibia and fibula above the ankle joint line and (ii) explore the reliability and operability of this K-wire as a static intraoperative syndesmotic reference.

## Patients and Methods

### *Measurement of TVDF; Selection Criteria for Patient Inclusion or Exclusion*

Our experiment was conducted under the principles of the Declaration of Helsinki. To evaluate the ideal positional gap between the tibia and fibula in the syndesmosis for the placement of the K-wire marker, we analyzed cross-sectional CT images of the ankle of patients with foot fractures accompanied by an uninjured ankle. After obtaining approval from the institutional biomedical research ethics committee in our hospital (No. 202205003), we initiated data collection. The inclusion criteria were (i) patients tested by CT scans owing to foot fractures in short splints to maintain neutral foot and ankle positions; (ii) patients with uninjured ankle were identified by physical and radiological tests. The exclusion criteria were (i) patients with ankle osteoarthritis; (ii) patients with a history of prior injury; (iii) patients with foot and ankle malformations. In cases of bilateral foot fractures, we only measured one side to avoid bias due to a two-sided similar result. We reviewed the records of 42 patients (22 males, 20 females; mean age:  $38.8 \pm 13.8$  years [range 21–72 years]) who underwent a CT scan for foot fractures from August 2016 to June 2017 in our hospital to find an ideal position for K-wire placement. Patient demographics, medical records, fracture type, and clinical outcomes were collected and analyzed (Tables 1 and 3). Informed consent was obtained from all patients whose data was recorded and published in this study.

To determine the main distribution range of the tibiofibular vertical distance (TFVD), all patients were divided into four groups according to the TFVD: 0–1, 1–2, 2–3, and 3–4 mm. The number of patients in each group was calculated.

### *Verification of a Novel Marker in the Process of Placing the Syndesmotic Screw*

To assess the value of this new reference in clinical application, we performed a retrospective analysis of patients who underwent syndesmotic screw fixation due to syndesmotic disruption combined with ankle fractures. The classification of fractures was based on the Danis–Weber classification because Weber type B and C fractures were closely related to injury of the distal tibiofibular syndesmosis<sup>23,24</sup>. The inclusion criterion was the availability of CT scans of the ankles within 1 week postoperatively. The exclusion criteria were (i) patients with open ankle injury; (ii) patients <18 years of age; (iii) patients with tibial pilon fractures; and (iv) patients with previous ankle deformation and osteoarthritis. Finally, 20 patients (six females, 14 males; mean age:  $52.5 \pm 15.3$  years [range 28–72 years]) with syndesmotic injury fixated by syndesmotic screw using the conventional method as a reference (30° from posterolateral to anteromedial) from December 2015 to March 2017 and 21 (nine females, 12 males;

**TABLE 1 Tibiofibular vertical distance (mm) according to independent variables**

	Number	Minimum	Maximum	Mean	SD	Statistical value	P value
Total	42	0	3.6	2.23	1.01		
Side						0.463	0.646
	Right	0	3.6	2.23	1.11		
	Left	0	3.6	2.07	1.00		
Fractures						1.512	0.230
	Talus	0	3.5	1.82	1.11		
	Calcaneus	0.1	3.6	2.35	1.11		
	Metatarsus	1.6	3.5	2.46	0.65		

There was no statistically significant difference in the tibiofibular vertical distance (TFVD) between the left and right sides of the patients, and TFVD was not affected by the fracture type. TFVD of healthy adults is a uniform and stable value.

**TABLE 2 Demographic and clinical data**

	Conventional group (20 patients)	New group (21 patients)	Statistical value	P value
Age	52.5 (SD 15.3)	45.0 (SD 15.3)	1.546	0.130
Gender			0.730	0.393
	Female	6		
	Male	14		
Side			1.192	0.275
	Right	11		
	Left	9		
Fracture type			0.605	0.437
	Weber B	11		
	Weber C	9		
AOFAS Score				
	3 months post operation	77.80 ± 4.05	-0.947	0.349
	6 months post operation	81.00 ± 6.84	-2.354	0.024

Comparison of age, gender, side, and fracture type between the two groups. There was no statistical difference. The AOFAS score of ankle function in the two groups at 6 months after operation was statistically significant, although the AOFAS score at 3 months after operation was not statistically significant.

mean age:  $45.0 \pm 15.3$  years [range 21–68 years]) patients who underwent the new technique described in this study from November 2018 to June 2020 in Honghui hospital were included in the analysis (Table 2). All patients were followed up for at least half a year. Patient demographics, medical records, fracture type, and clinical outcomes were collected and analyzed (Tables 2 and 4). The distal tibiofibular screw was removed before ankle weight-bearing at 11 weeks after the operation. The AOFAS score of ankle function was assessed at 1 week after syndesmotic screw removal (3 months postoperatively) to reduce the influence of ankle function due to trauma caused by screw removal. Another functional evaluation of the ankle joint was performed at 6 months postoperatively according to the AOFAS scoring system<sup>25</sup> (Table 2). Finally, a correlation analysis was performed between the AAS and AOFAS score at 6 months postoperatively (Figure 1).

### CT Scan Analysis

The CT scans of all patients were analyzed using a similar method. The standard syndesmotic screw trajectory lies perpendicular and central to the fibular incisura in the axial

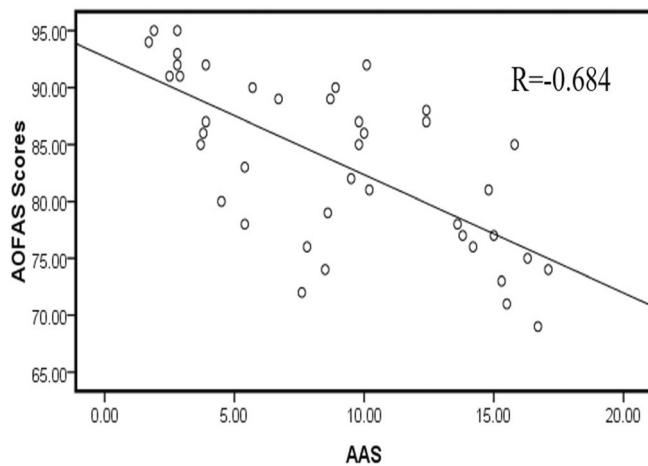
plane<sup>8</sup>. Putnam *et al.* defined the line passing the fibular ridge and perpendicular to the fibular incisura as the anatomic axis of the syndesmosis<sup>16</sup>. According to abovementioned studies, this axis has two critical points: the fibular ridge, which is easily visualized during operation, and another point perpendicular to the fibular incisura. It is imperative for surgeons to find a static and visible reference for the fibular incisura plane.

### Image Processing

All CT scans were obtained using a 128-slice detector scanner (Siemens AG, Wittelsbacherplatz, Muenchen, Germany). These images were measured using the Picture Archiving and Communication System (Synapse 3.0, FUJI TECHNOLOGY Co., Ltd., Tokyo, Japan), and two orthopaedic surgeons independently recorded each measurement at separate dates.

### Measurement Methods

Firstly, we defined the TFVD as the distance between the fibular incisura plane of the tibia and the medial border of fibula. In a preliminary experiment, we aimed to determine a position proximal to the tibial plafond where the TFVD of



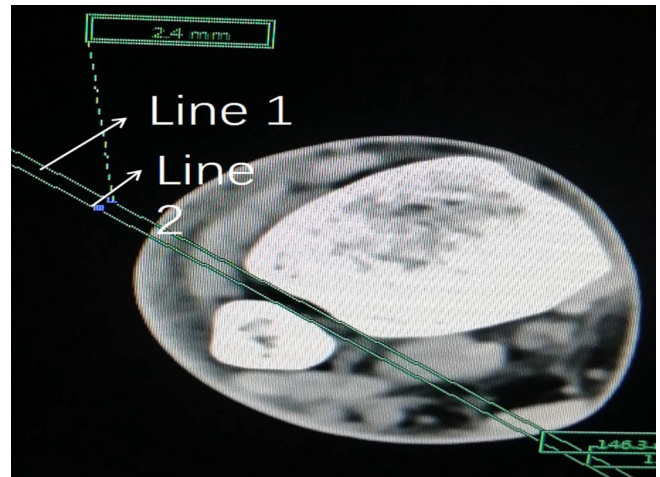
**Fig. 1** The correlation analysis between the angle between the anatomic axis of the syndesmosis and screw axis (AAS) and ankle function using the American Orthopaedic Foot and Ankle Society (AOFAS) score was exhibited in this picture

all patients was just  $>0$ . The TFVD of each CT slice from the start of the tibial plafond was measured using our methods. Finally, we observed that the distance of the 25th slice from the beginning of the plafond of all patients was just  $>0$ . As the height of each slice was 1 mm, measuring a TFVD of 2.5 cm proximal to the plafond was our objective. The choice of using a 1.6-mm K-wire was dependent on our experiences. Through a preliminary experiment, we discovered that it was very easy to place a 1.6-mm K-wire 2.5 cm proximal to the tibial plafond. Injury to the distal tibiofibular syndesmosis because of the placement of a 1.6-mm K-wire at this position may be mild due to the ease of insertion. We drew a line along the anterior and posterior borders of the fibular incisura on a transverse CT slice. This line was defined as Line 1. Then, we drew another line parallel to Line 1 and tangent to the medial border of the fibula, defined as Line 2 (Figure 2). The vertical distance between the two lines was considered to be the path width of the K-wire marker (Figure 3).

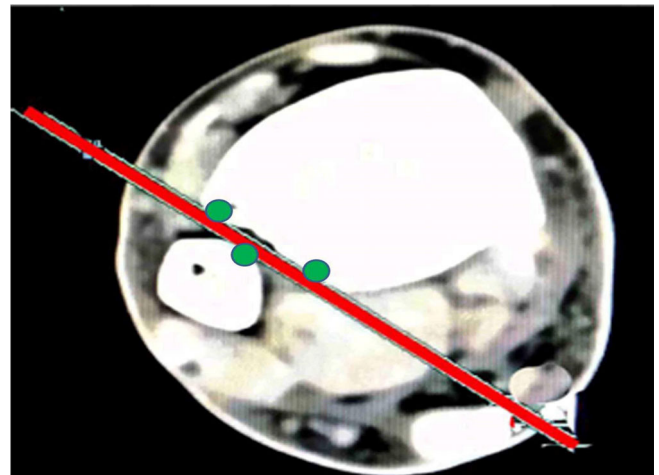
Finally, the reliability of the K-wire marker was verified through clinical application. The angle between the trans-syndesmotomic line and screw axis was confirmed on the transverse CT slices within 7 days postoperatively (Figure 4). The choice of CT slice related to the AAS measurement depended on whether the axis of screw could be accurately determined in this slice. Line 1 represented the fibular incisura tangent, and Line 2 perpendicular to Line 1 represented the trans-syndesmotomic line. The angle between Line 2 (anatomic axis of the syndesmosis) and the screw axis (Line 3) was defined as the AAS (Figure 4). The data on the angle were compared between the two groups.

### Operative Technique

Before fracture internal fixation, the ankle joint line was marked under fluoroscopy. Then, the position 2.5 cm above the ankle joint plane was located and marked to help to place



**Fig. 2** The tibiofibular vertical distance (TFVD) was defined as the vertical distance between L1 and L2 on an axial CT at 2.5 cm proximal to the ankle joint. L1 is the line along the anterior and posterior borders of the fibular incisura. L2 is the line parallel to L1 and at a tangent to the medial border of the fibula

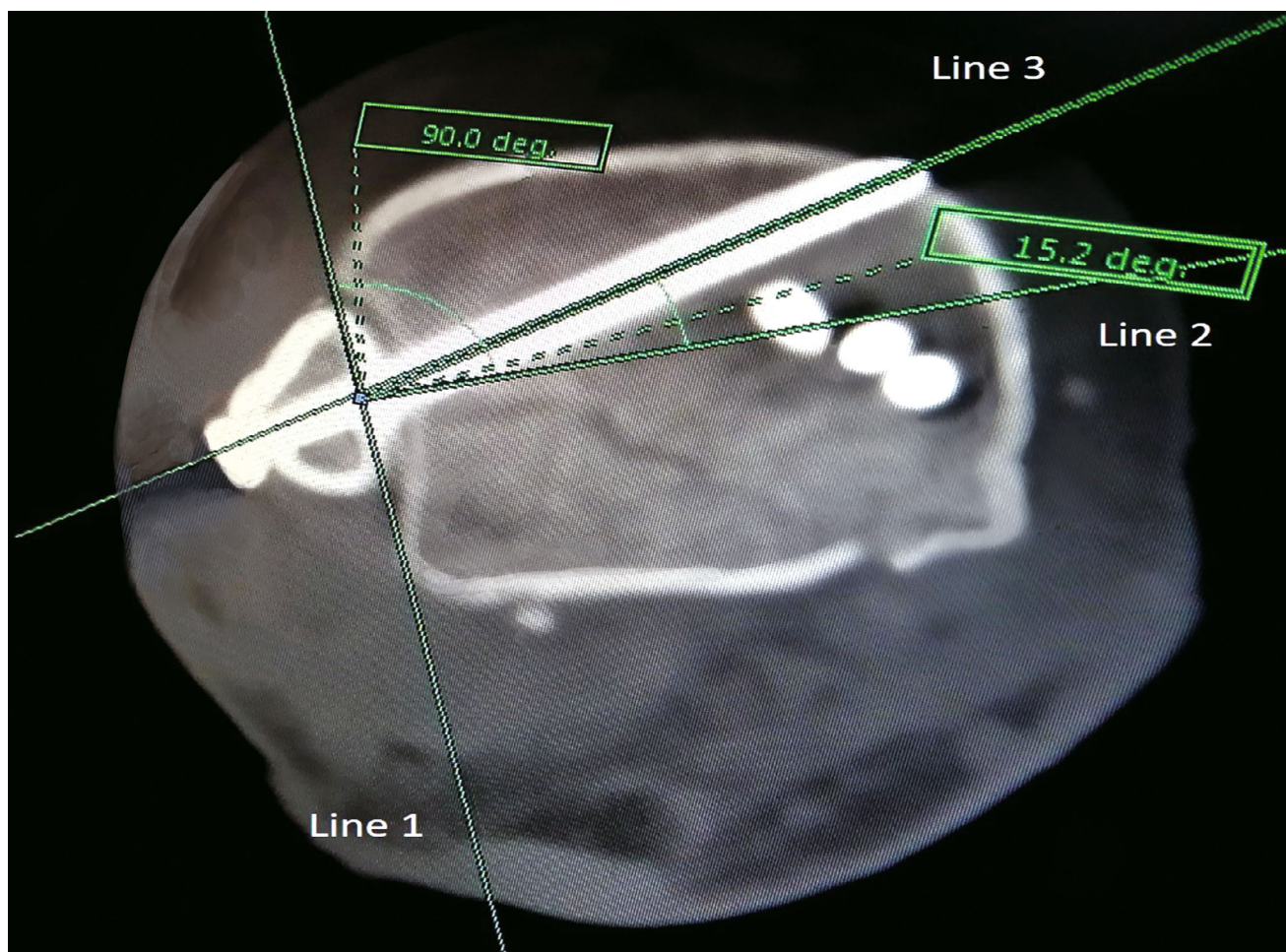


**Fig. 3** The red line represents the path of the K-wire marker. The three green points represent the anterior and posterior borders of the tibia incisura and the medial border of the fibula

a K-wire as a marker of trans-syndesmotomic screw. This process was presented by a healthy volunteer (Figure 5).

### Anesthesia and Position

The procedure was performed after providing general anesthesia to the patients and using a lower limb tourniquet. The patient's body position was selected according to the type of fracture. For patients with ankle joint fractures involving medial malleolar fracture or triangular ligament injury requiring surgical treatment, the floating position (from



**Fig. 4** The angle between the anatomic axis of the syndesmosis (Line 2) and screw axis (Line 3) is shown

lateral to supine position) was used, and for patients with only syndesmotic injury or syndesmotic injury combined with fibular fracture, the lateral position was used in this study. The foot and toes were covered with a sterile glove after the whole lower limb was disinfected and sterile sheets were laid.

#### **Approach and Exposure**

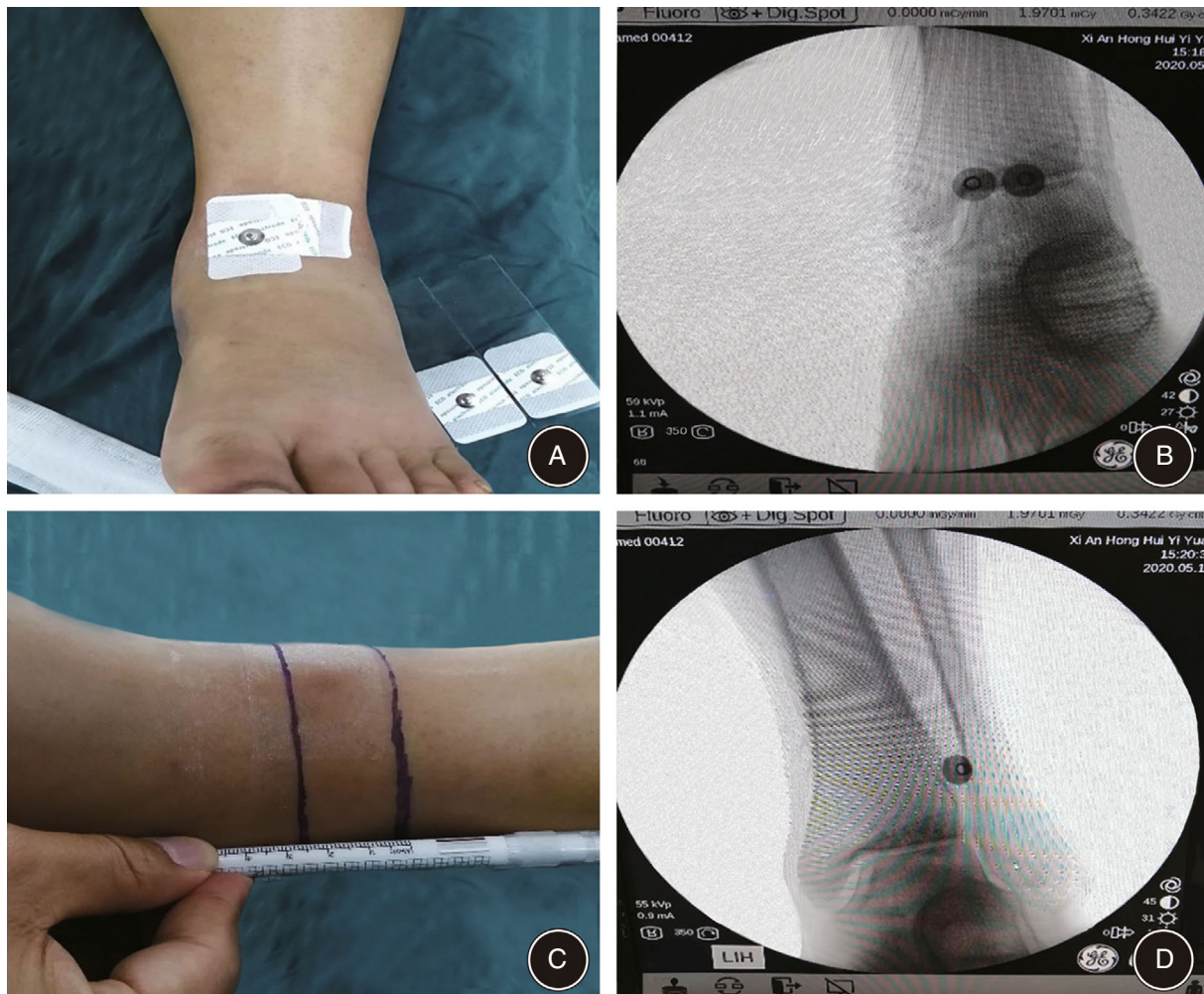
All procedures of open reduction and internal fixation of ankle fractures were operated according to the Standard AO-ASIF principles<sup>26</sup>. Generally, three kinds of incisions were used during operation: (i) lateral incision was used for patients with syndesmotic injury or syndesmotic injury combined with fibular fracture; (ii) posterolateral incision was used for patients with above-mentioned injury combined with posterior ankle fracture; and (iii) internal and external double incisions were used for patients with syndesmotic injury combined with medial malleolar fracture or triangular ligament injury requiring surgical treatment.

#### **Testing the Stability of the Syndesmosis**

The instability of the syndesmosis was usually evaluated by the measurement of diastasis between the distal tibia and fibula and/or the width of the space between the medial malleolus and talus under stress radiographs. If radiographical examination was not confirmed, another intraoperative assessment method, the Cotton test, was used to indicate distal syndesmotic instability. Once the instability of syndesmosis was established based on preoperative radiographs or intraoperative examination, the distal syndesmotic joint was reduced with the help of a reduction clamp. To prevent excessive reduction of the syndesmosis caused by excessive force, our reduction forceps were usually placed within 0.5 cm above the ankle, which is the direct contact area between the tibia and fibula.

#### **The Process for Placing a Standard Syndesmotic Screw**

Once it was determined that the reduction of syndesmosis was satisfactory under fluoroscopy, a 1.6-mm K-wire was inserted depending on the spot preoperatively marked by



**Fig. 5** (A) Stick some electrode pieces on the position of the predicted ankle joint line and (B) determine the electrode piece that can most mark the ankle line under fluoroscopy. (C) The two lines of ankle joint and 2.5 cm above it were marked. (D) The electrode film showed the projection of 2.5 cm above the ankle on the lower tibiofibular joint

free hands. For patients with posterior malleolus fracture treated using the posterolateral approach, it is easier or less invasive to insert a K-wire from the posterior to the front as a marker. A 2.5-mm drill was used to prepare the trans-syndesmotric trajectory on the position where it needed to be inserted according to preoperative design, perpendicular to this marker of K-wire (Figure 6). The position of screw trajectory and K-wire did not necessarily coincide. A single 3.5-mm cortical screw (IRENE, Tianjin, China) was inserted through three cortices of bone when the pre-prepared screw trajectory was completed. A syndesmotric screw was implanted between 2.0 cm and 5.0 cm above the ankle plane at our institute. Generally, the screw should pass through the fibular ridge. When the implanted position of the syndesmotric screw was blocked by the plate, it was also a good choice to implant the syndesmotric screw through the nail hole on the plate. The remaining surgical steps were performed in the traditional manner. All operative procedures and the evaluation of the

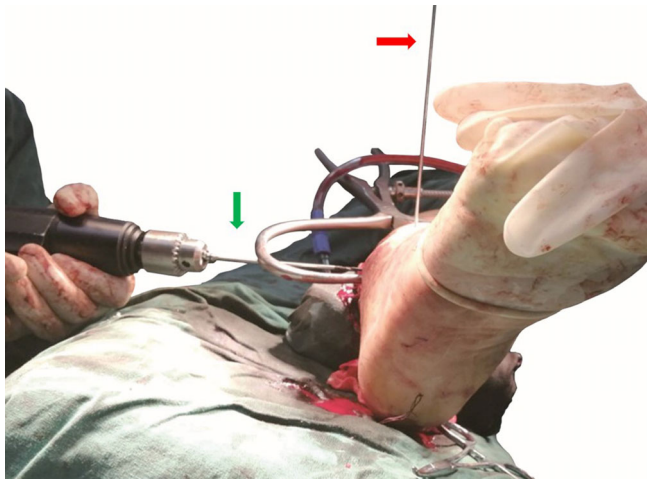
AOFAS score regarding ankle function postoperatively were completed by the same senior physician.

#### **Postoperative Management**

Postoperative management in the immediate postoperative period included non-weight ankle joint exercise, encouraged crutch use, and appropriate deep venous thrombosis (DVT) prevention. The affected extremity was elevated to reduce swelling and pain of limb extremity.

Prior to the removal of the syndesmotric screw, patients underwent a dressing change and wound check, suture removal. Patients were encouraged to get out of bed and to perform non-weight bearing exercise with the help of crutches.

Syndesmotric screw removal was performed 11 weeks after the operation. After 1 week, patients were encouraged to get out of bed and perform partial weight bearing exercises with the help of crutches. Crutches were gradually discontinued according to radiographic sign of fracture union.



**Fig. 6** The K-wire may be used as a definite static landmark for the placement of an ideal screw trajectory during syndesmotic screw fixation. The red arrow refers to the mark of the K-wire. The green arrow refers to a drill used to place a screw trajectory during syndesmotic fixation

### Statistical Analysis

Levene's test was performed to confirm the equality of variances. The Shapiro–Wilk test was performed to evaluate normal distribution. Independent t-tests and chi-square tests performed to compare intergroup differences, and  $p$ -value of  $<0.05$  was considered statistically significant. Statistical analyses were performed using SPSS (version 13.0; SPSS Corp., Chicago, IL, USA). According to the methods reported by Putnam *et al.*<sup>16</sup>, we estimated the reliability of the described measurements with an interclass correlation coefficient (ICC). Two independent observers measured and recorded data on separate dates. The classification related to the results of the ICC was comparable to that reported by Putnam *et al.*: poor ( $<0.2$ ), fair (0.21–0.4), moderate (0.41–0.6), good (0.61–0.8), or very good (0.81–1)<sup>16</sup>. Pearson's correlation analysis was performed between the AAS and AOFAS score. The correlation coefficient was graded according to the R value: no ( $<0.3$ ), low (0.3–0.49), moderate (0.5–0.79), high (0.8–0.95), and significantly high ( $>0.95$ ) correlation.

## Results

### Outcomes of TFVD Measurement

The ideal vertical distance between the tibial and fibular cortex was determined to be  $2.23 \pm 1.01$  mm (range 0–3.6 mm)

at 2.5 cm proximal to the tibial plafond, with no significant difference noted between males and females ( $n = 22$  and  $20$ , respectively,  $P = 0.995$ ) (Table 3). There was also no difference between the right and left sides ( $n = 23$  and  $19$ , respectively,  $P = 0.646$ ) (Table 1). The vertical distance in 20 out of 42 patients was 2–3 mm (Figure 7). The ICC for the measurement of TFVD was 0.915, indicating very good reliability between the two independent observers.

### Accuracy of Trans-Syndesmotic Screw Placement Postoperatively

The AAS for K-wire insertion in the syndesmosis as an intra-operative reference for syndesmotic screw placement measured  $4.89^\circ \pm 2.43^\circ$  (range  $1.7^\circ$ – $9.8^\circ$ ), while the AAS depending on limb extremity neutral position measured  $13.01^\circ \pm 2.84^\circ$  (range  $8.7^\circ$ – $17.1^\circ$ ). The AAS in the conventional group was approximately three times larger than that in the new technique group ( $p < 0.001$ ) (Table 4).

### Assessment of Ankle Function and Correlation Analysis between AAS and AOFAS Score

At 3 months postoperatively, the AOFAS score in conventional group was  $77.80 \pm 4.05$  (range, 70–85), which has no statistical difference when compared to that of  $79.00 \pm 4.06$  (range, 71–88) ( $p = 0.810$ ) in the new group. However, there was a significant difference between the conventional group ( $81.00 \pm 6.84$ ; range, 71–92) and the new group ( $87.00 \pm 7.15$ , range, 72–95) at the 6-month postoperative follow-up (Table 2). Compared with the AOFAS scores at 3 months postoperatively, the scores of ankle function in both groups were found to increase at 6 months postoperatively. Ankle function in the new group was obviously better than that in the conventional group ( $p = 0.024$ ) at 6 months postoperatively. A greater difference in AAS resulted in a worse ankle function (smaller AOFAS score). There was a moderate negative correlation between them ( $R = -0.684$ ).

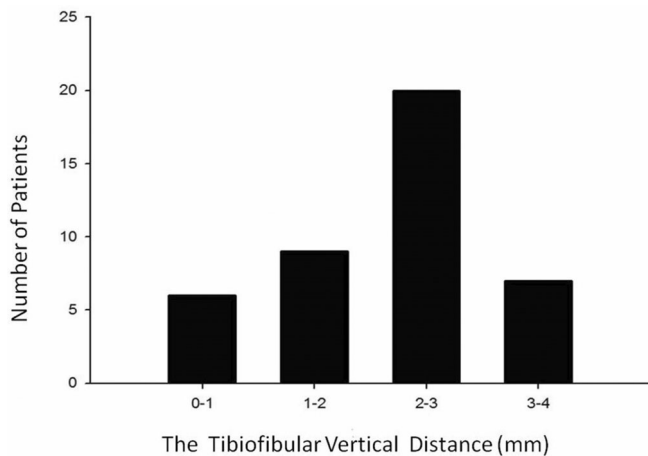
### Clinical Complications

Five adverse events were documented between the two groups. In the conventional group, two patients developed DVT on the affected side 2 days postoperatively, which disappeared at 2 weeks after receiving anticoagulation therapy with low molecular weight heparin calcium. Another patient had blister formation around the incision

**TABLE 3** Conventional computed cross-sectional image measures for male and female patients

	All	Male	Female	Statistical value	P Value
Patients (n)	42	22	20		
Age (years)	$38.8 \pm 13.8$	$36.9 \pm 13.5$	$40.9 \pm 14.1$	–0.915	0.366
TFVD (mm)	$2.23 \pm 1.01$	$2.23 \pm 1.17$	$2.23 \pm 0.81$	0.006	0.995

There was no statistically significant difference between gender and age. TFVD: tibiofibular vertical distance.



**Fig. 7** Histogram demonstrating the distribution of the tibiofibular vertical distance ( $n = 42$ ). In 69% (29/42) of the patients, TFVD was between 1 and 3 mm, which indicated the approximate gap of patients would be enough for placing a 1.6-mm K-wire

**TABLE 4** Conventional computed cross-sectional image measures according to different markers

	Conventional group	New group	Statistical value	$p$ value
Patients (n)	20	21		
AAS	$13.01 \pm 2.84^\circ$	$4.89 \pm 2.43^\circ$	51.813	<0.001

The accuracy of the syndesmotom screw placement was significantly promoted in the new technique compared to that in the conventional technique. AAS: the angle between the anatomic axis of the syndesmosis and screw axis.

that improved after 1 week of dressing changes. In the new technique group, one patient developed implant irritation postoperatively. Another patient had inflammation, including superficial inflammation and swelling around the incision 1 week postoperatively, and recovered after 1 week of antibacterial treatment. The incidence of complications in the conventional and new group was 15% and 9.5%, respectively.

## Discussion

The key step to implant a standard lower tibiofibular screw is to accurately estimate the syndesmosis plane during the operation. In this study, we introduced a method of direct estimation of the syndesmotom plane in which a 1.6-mm K-wire is placed 2.5cm proximal to the ankle platform. Based on this case-control study, we believe that this method provides a new and reliable intraoperative reference for implantation of a standard syndesmotom screw.

## Why Find a New Reference for Syndesmotom Screw Implantation?

A standard screw trajectory placed perpendicular and central to the fibular incisura is important for obtaining favorable postoperative outcomes of injured ankles<sup>8</sup>. The conventional method, in which the screw trajectory is placed parallel to the ankle joint line and inclined 30° from post-lateral to anteromedial in transverse, has been used for decades<sup>17</sup>. Although the operative guideline of syndesmotom screw placement is very clear, the rate of malpositioned syndesmotom screws is very high, and this malpositioning could lead to reoperations of the ankle fracture<sup>8,27</sup>. One possible reason for this malpositioning is the lack of reliable and static intraoperative references for surgeons. Previously, the references markers used for the insertion of the screw trajectory comprise expert opinions (most used)<sup>17</sup>, followed by the second toe<sup>19</sup> and malleolar tips<sup>8</sup>. To overcome the variation in the axial orientation of the syndesmosis dependent upon experiences and surgeon's eyeballing, Park *et al.*<sup>19</sup> detected an incline angle of around 18° to the horizontal plane when they used the second toe as a reference with the ankle joint in the neutral position. One possible explanation for this variation is that different foot positions could lead to a falsely estimated horizontal plane when the ankle joint is neutral. Given that the estimation of the horizontal plane dependent on the ankle and foot position is difficult for surgeons, finding a static reference independent of the ankle and foot position is necessary. Although Kumar *et al.*<sup>8</sup> have used malleolar tips as static reference points independent of ankle and foot rotation to position syndesmotom screws, it may be difficult for surgeons to touch the malleolar tips due to ankle swelling associated with ankle injury. Therefore, there is still a need to find reference points without interference of the ankle and foot position and soft tissue swelling so that surgeons can accurately estimate the plane of tibia incisura and place an ideal screw trajectory. Once we detected the fibula incisura plane by a marker, we placed an ideal distal syndesmotom screw perpendicular to it because the plane of the tibial incisura did not interfere with the position and soft tissue swelling of the ankle and foot. Therefore, we hypothesized that one optimal space proximal to the tibia plafond existed for placing a K-wire touching the anterior and posterior borders of the tibial incisura, which could be used as an accurate marker of the fibular incisura for surgeons to observe during the operation.

## Compared with the Conventional Method, Using a 1.6-mm K-Wire as a Marker of Syndesmotom Screw Placement Could Promote Accuracy of Screw Implantation

With the ankle joint in the neutral position, we found that the average TFVD was 2.23 mm at 2.5 cm above the ankle joint line. A 1.6-mm K-wire could be easily inserted in this gap without assistance from any other instruments. Although the K-wire insertion process is still affected by the anatomic variance of the distal tibiofibular joint, reduction, and surrounding soft tissue, it still has higher stability, facilitating placement of the syndesmotom screw compared with that of



the conventional method based on our clinical data. To avoid the separation and additional injury of the distal syndesmosis caused by the free-hand implantation of a K-wire, it is necessary to avoid withdrawing the syndesmotomic reduction forceps when the K-wire is implanted. Therefore, this K-wire could be used as a static and stable marker for the accurate placement of the syndesmotomic screw without the influence of ankle position and soft tissue swelling around the ankle joint. The syndesmotomic screw could be precisely placed perpendicular to the K-wire and parallel to the ankle joint. In general, the syndesmotomic screw was implanted between 2.0 and 5.0 cm above the ankle plane at our institute. Compared to that in the conventional method, using K-wire as an intraoperative marker, as described in this study, can significantly increase the accuracy of syndesmotomic screw placement. AAS in the conventional group was significantly larger than that in the new technique group ( $13.01^\circ \pm 2.84^\circ$  and  $4.89^\circ \pm 2.43^\circ$ , respectively) ( $p < 0.001$ ).

#### ***The 1.6-mm K-Wire Could Be Used as a Reasonable and Reliable Marker for Ideal Syndesmotomic Screw Placement***

We analyzed ankle CT scans of patients with foot fractures to locate the optimal position for K-wire marker placement for several reasons. First, many patients with foot fractures require CT for the estimation of foot injury. This allowed us to easily complete our study without additional medical costs or radiation exposure damage to patients. Second, short leg braces for patients with foot fractures ensured a neutral ankle position. From plantar flexion to dorsiflexion, the ankle joint allows 1–2 mm of widening normally. As such, the consistency of measurements on CT scans may vary without braces. In this study, patients protected by short leg braces because of foot fractures were examined by CT scans to ensure measurement consistency.

Our study found that the gap between the tibia and fibula at 2.5 cm proximal to the tibial plafond was suitable for the insertion of a 1.6-mm K-wire, with no obvious deformation. The vertical distance between the tibia and fibula measured  $2.23 \pm 1.01$  mm. This path consisted of three points (the anterior and posterior borders of the tibial incisura and the medial border of the fibula) (Figure 3). Theoretically, these three points form a three-bone claw and hold the 1.6-mm K-wire along the fibular incisura tangent. Then, the K-wire can be a definite visible landmark during syndesmotomic screw fixation (Figure 6). Ankle movements, swelling, or leg and foot position did not influence the accuracy of this marker. Using our marker, intraoperative screw trajectory may be closer to the line perpendicular to the fibular incisura tangent. To verify the reliability of this new marker in clinical application, we measured AAS in patients who underwent syndesmotomic fixation for ankle fracture within 7 days post operation and compared the difference between the conventional and new technique groups. This study found that the new marker technique decreased AAS deformation by up to 62%. Thereby, this K-wire is a reliable and static marker of the fibular incisura plane for drilling an ideal syndesmotomic trajectory. Meanwhile, this study also found

that, at the follow-up of 6 months after operation, the AOFAS score of ankle function in the new marker group was significantly better than that in the conventional group, although there was no significant difference between the two groups at 3 months after operation. One possible explanation for this is that when the axis of the screw is not perpendicular to the fibular incisura, the cutting force between the tibia and fibula affects ligament healing and ankle function. Moreover, there is a moderate negative correlation between AAS and the AOFAS score at 6 months postoperatively. AAS may be used as a predictor for the recovery of ankle function according to our findings.

#### ***Study Limitations***

This study has some limitations. First, we used only CT scans of foot fractures with a splint; this should exclude any discrepancies in the distance between the tibia and fibula at varying talus positions. Although we did not analyze CT scans for the ankles without any damage, the syndesmosis was uninjured, and no malformation was observed in any of these patients. Moreover, additional medical costs and radioactive injuries were avoided by comparing the existing CT scans of injured extremities. Therefore, we believe that these data were suitable for this study. Second, the gap located 2.5 cm proximal to the plafond was not well-matched for the positioning of a 1.6-mm K-wire. Any mismatch between the gap and the K-wire could lead to an error in fibular incisura plane marking. Therefore, we believe that the K-wire should be inserted by free-hand, not drilled, which would make the K-wire more closely touch the anterior and posterior borders of the fibular incisura. In addition, the accurate width of the TVDF at 2.5 cm above the ankle joint can also be measured through the tangent positioning radiography of the distal tibiofibular joint under fluoroscopy after intraoperative displaced syndesmosis reduction. The K-wire of an appropriate diameter can be selected based on measured outcomes. However, accurate measurement of the TVDF may not be a necessary step based on our experiences. Free-hand insertion of the K-wire marker was very easy in all patients who underwent syndesmotomic screw fixation for ankle fractures in this study. Third, the number of patients was quite small, and the time of follow-up was short, making it difficult to draw firm conclusions. However, this is a preliminary report, and this study will be continued with a larger case number and a longer follow-up time, which may validate our conclusion in the future.

#### ***Conclusion***

In this study, we analyzed cross-sectional images of CT scans to locate an ideal position above the ankle joint line for the insertion of a 1.6-mm K-wire. Using a K-wire for reference, syndesmotomic screw trajectories could be more accurately placed perpendicular to the fibular incisura. Further, a more accurate syndesmotomic screw may be a predictor for long-term ankle function. Our method has the advantage of a clear and static reference without interference of ankle and foot

position, making it a suitable alternative to conventional methods.

### Acknowledgments

I wish to thank professor Zhong Li and Teng Ma for their valuable suggestions regarding the manuscript. The successful completion of the operation and article is a result of the efforts of all the authors, whose contributions are highly appreciated.

### Conflicts of Interest

We declare that all authors have no conflict of interest.

### Author's Contribution

Congming Zhang, Chengcheng Zhang, and Qiang Huang were responsible for the study design, data collection,

and manuscript generation. Liang Sun, Chen Ren, and Yao Lu was responsible for collecting postoperative data. Yibo Xu, Hua Lin, and Kun Zhang participated in the study design. Teng Ma and Zhong Li were the senior authors who performed the surgery and contributed to study design and manuscript editing. All authors have read and approved the final manuscript.

### Declaration

None of the authors of this paper have a financial or personal relationship with other people or organizations that could inappropriately influence or bias the content of the paper.

### Disclosure Statement

The authors declare no conflicts of interest.

### References

- Chissell HR, Jones J. The influence of a diastasis screw on the outcome of weber type-C ankle fractures. *J Bone Jt Surg Br.* 1995;77:435–8.
- Court-Brown CM, McBirnie J, Wilson G. Adult ankle fractures - an increasing problem. *Acta Orthop Scand.* 1998;69:43–7.
- Davidovitch RI, Weil Y, Karia R, Forman J, Looze C, Liebergall M, et al. Intraoperative syndesmotom reduction: three-dimensional versus standard fluoroscopic imaging. *J Bone Jt Surg Am.* 2013;95:1838–43.
- Ebramzadeh E, Knutsen AR, Sangiorgio SN, Brambila M, Harris TG. Biomechanical comparison of syndesmotom injury fixation methods using a cadaveric model. *Foot Ankle Int.* 2013;34:1710–7.
- Franke J, von Recum J, Suda AJ, Grützner PA, Wendl K. Intraoperative three-dimensional imaging in the treatment of acute unstable syndesmotom injuries. *J Bone Jt Surg Am.* 2012;94:1386–90.
- Gan K, Zhou K, Hu K, Lu L, Gu S, Shen Y. Dynamic fixation versus static fixation for distal tibiofibular syndesmosis injuries: a meta-analysis. *Med Sci Monit.* 2019;25:1314–22.
- Gardner MJ, Demetrakopoulos D, Briggs SM, Helfet DL, Lorich DG. Malreduction of the tibiofibular syndesmosis in ankle fractures. *Foot Ankle Int.* 2006;27:788–92.
- Kumar A, Goel L, Chouhan D, Agnihotri A, Chauhan S, Passey J. Malleolar tips as reference points for positioning of syndesmotom screw: a preliminary CT based analysis. *J Clin Orthop Trauma.* 2020;11:438–41.
- Lübbeke A, Salvo D, Stern R, Hoffmeyer P, Holzer N, Assal M. Risk factors for post-traumatic osteoarthritis of the ankle: an eighteen year follow-up study. *Int Orthop.* 2012;36:1403–10.
- Miller AN, Barei DP, Iaquinio JM, Ledoux WR, Beingessner DM. Iatrogenic syndesmosis malreduction via clamp and screw placement. *J Orthop Trauma.* 2013;27:100–6.
- Müller ME, Allgöwer M, Schneider R, Willenegger H. Malleolar fractures. *Manual of Internal Fixation.* Berlin Heidelberg, New York: Springer-Verlag; 1991. p. 595–612.
- Ovaska MT, Mäkinen TJ, Madanat R, Kiljunen V, Lindahl J. A comprehensive analysis of patients with malreduced ankle fractures undergoing re-operation. *Int Orthop.* 2014;38:83–8.
- Park YH, Choi WS, Choi GW, Kim HJ. Ideal angle of syndesmotom screw fixation: a CT-based cross-sectional image analysis study. *Injury.* 2017;48:2602–5.
- Penera K, Manji K, Wedel M, Shofler D, Labovitz J. Ankle syndesmotom fixation using two screws: risk of injury to the perforating branch of the peroneal artery. *J Foot Ankle Surg.* 2014;53:534–8.
- Phisitkul P, Ebinger T, Goetz J, Vaseenon T, Marsh JL. Forceps reduction of the syndesmosis in rotational ankle fractures: a cadaveric study. *J Bone Jt Surg Am.* 2012;94:2256–61.
- Putnam SM, Linn MS, Spraggs-Hughes A, McAndrew CM, Ricci WM, Gardner MJ. Simulating clamp placement across the trans-syndesmotom angle of the ankle to minimize malreduction: a radiological study. *Injury.* 2017;48:770–5.
- Rudloff M. Fractures of the lower extremity. In: Canale ST, Beaty JH, Campbell WC, editors. *Campbell's Operative Orthopaedics.* Philadelphia, PA: Elsevier/Mosby; 2013.
- Sagi HC, Shah AR, Sanders RW. The functional consequence of syndesmotom joint malreduction at a minimum 2-year follow-up. *J Orthop Trauma.* 2012;26:439–43.
- Sipahioglu S, Zehir S, Isikan U. Syndesmotom screw fixation in tibiofibular diastasis. *Niger J Clin Pract.* 2018;21:692–7.
- Mendelsohn ES, Hoshino CM, Harris TG, Zinar DM. CT characterizing the anatomy of uninjured ankle syndesmosis. *Orthopedics.* 2014;37:e157–60.
- Akseki D, Pinar H, Yaldiz K, Akseki NG, Arman C. The anterior inferior tibiofibular ligament and talar impingement: a cadaveric study. *Knee Surg Sports Traumatol Arthrosc.* 2002;10:321–6.
- Shuler FD, Woods D, Tankersley Z, McDaniel C, Hamm J, Jones J, et al. An anatomical study on the safe placement of orthopedic hardware for syndesmosis fixation. *Orthopedics.* 2017;40:e329–33.
- Brosky T, Nyland J, Nitz A, Caborn DN. The ankle ligaments: consideration of syndesmotom injury and implications for rehabilitation. *J Orthop Sports Phys Ther.* 1995;21:197–205.
- Heim D, Schmidlin V, Ziviello O. Do type B malleolar fractures need a positioning screw. *Injury.* 2002;33:729–34.
- Kitaoka HB, Alexander IJ, Adelaar RS, Nunley JA, Myerson MS, Sanders M. Clinical rating systems for the ankle-hindfoot, midfoot, hallux, and lesser toes. *Foot Ankle Int.* 1994;7:349–53.
- Heim UPKM. *Small Fragment Set Manual: Technique Recommended by the ASIF Group.* 2nd ed. New York: Springer-Verlag; 1982.
- Weening B, Bhandari M. Predictors of functional outcome following transsyndesmotom screw fixation of ankle fractures. *J Orthop Trauma.* 2005;19:102–8.