

# Nasoorbitoethmoid fractures in a tertiary care hospital of eastern India: A prospective study

## ABSTRACT

**Purpose:** The purpose of this study was to report on the pattern of occurrence of nasoorbitoethmoid (NOE) fractures in Odisha and the various factors that influence their distribution.

**Methods:** The study period was from January 1, 2016 to December 15, 2017. After approval from the Institutional Ethics Committee, all patients diagnosed with naso-orbito-ethmoid fractures reporting to the department of OMFS and Level-1 trauma centers were included in the study. Sociodemographic data along with the etiology and type of fracture were mentioned. Associated injuries to other body parts were noted. Open reduction was possible only in five cases of NOE fractures. The treatment plan including the operative approach and postoperative results was evaluated.

**Results:** A total of 1192 patients with facial fracture were seen, of which 52 (4.36%) patients had NOE fractures. Males far outnumbered females in a ratio of 9:1. Thirty-three patients (63.46%) had unilateral NOE fracture, while the rest 19 (36.54%) had bilateral NOE fracture. Sixteen (30.76%) cases were classified as Type I, 35 (67.30%) as Type II, and 1 (1.92%) as Type III. Road traffic accidents were the most common cause of NOE fractures (69%), followed by fall (17%) and assault (10%). The most common neurological injury to be associated with NOE fractures was pneumocephalus (29%), followed by diffuse axonal injury (8%). Telecanthus (100%) was found to be the primary clinical feature in patients of NOE fracture, followed by a depressed nasal bridge (92%). Fracture of the nasal bone was invariably associated with NOE fracture. Complications observed due to untreated NOE fractures included a shortened and retruded nose, shortened palpebral fissures, telecanthus, and enophthalmos.

**Conclusion:** Contemporary management of NOE complex fractures demands precise diagnosis and immediate surgical management with anatomic reduction and rigid fixation of the involved bone segments. With an improvement in socioeconomic status and increased awareness among maxillofacial surgeons, hopefully, a greater number of NOE fracture patients will avail the benefits of open reduction in future.

**Keywords:** Facial trauma, medial canthal tendon, midface fracture, naso-ethmoidal fracture, nasoorbitoethmoid fracture

## INTRODUCTION

As per the AO foundation, nasoorbitoethmoid (NOE) fracture refers to injuries involving the area of confluence of the nose, orbit, ethmoids, the base of the frontal sinus, and the floor of the anterior cranial base. Four of the following fractures must be present to create this injury: the lateral nose, the inferior orbital rim, the medial orbital (ethmoidal) wall, the nasomaxillary buttress at the piriform aperture, and the frontal process of the maxilla at the internal angular process of the frontal bone. The segment isolated by these fractures, the frontal process of the maxilla, is the lower two-third of

**DEBASHISH PATI, NIRANJAN MISHRA, INDUBHUSAN KAR, BRUNDABATI MEHER, DIPTI SAMAL, KRUSHNA CHANDRA RATH**

Department of Oral and Maxillofacial Surgery, SCB Dental College and Hospital, Cuttack, Odisha, India


**Address for correspondence:** Dr. Niranjana Mishra, Department of Oral and Maxillofacial Surgery, SCB Dental College and Hospital, Cuttack, Odisha, India.  
E-mail: drniranjanmishra@gmail.com

**Received:** 17 July 2020, **Revised:** 17 October 2020, **Accepted:** 02 December 2020, **Published:** 16 March 2021

This is an open access journal, and articles are distributed under the terms of the Creative Commons Attribution-NonCommercial-ShareAlike 4.0 License, which allows others to remix, tweak, and build upon the work non-commercially, as long as appropriate credit is given and the new creations are licensed under the identical terms.

**For reprints contact:** WKHLRPMedknow\_reprints@wolterskluwer.com

**How to cite this article:** Pati D, Mishra N, Kar I, Meher B, Samal D, Rath KC. Nasoorbitoethmoid fractures in a tertiary care hospital of eastern India: A prospective study. *Natl J Maxillofac Surg* 2021;12:42-9.

Access this article online	
<b>Website:</b> www.njms.in	<b>Quick Response Code</b> 
<b>DOI:</b> 10.4103/njms.NJMS_151_20	

the medial orbital rim and represents the central fragment of a NOE injury. The medial canthal tendon inserts onto this fragment. This central fragment may be a single segment or comminuted either external to or within the canthal tendon insertion.

NOE fractures differ from other common facial fractures as occlusion is typically unaffected in case of NOE fractures and thus does not require precise restoration of occlusion. However, it also precludes manipulation of the teeth bearing segments to achieve any kind of closed reduction. Inadequate or no treatment results in a short and retruded nose, shortened palpebral fissures, telecanthus, enophthalmos, and ocular dystopia. Thus, an accurate assessment of the injury and a comprehensive treatment plan that is implemented as soon as possible are necessary for optimal results.

Even with the availability of modern imaging modalities, advanced surgical techniques, and miniaturized implants for rigid fixation, NOE fracture still remains the most difficult facial fracture to treat.

The purpose of this observational study was to report on the pattern of occurrence of NOE fractures in a tertiary care hospital of eastern India and the various factors that influence their distribution.

**Aim of the study**

- The aim of this study was to document the epidemiology, etiology, and clinical features of NOE fractures in a tertiary care hospital of eastern India
- To assess the associated injuries of the brain, cervical spine, limbs, chest, abdomen and eyes, and complicating factors.

**METHODS**

The study period was from January 1, 2016, to December 15, 2017. After approval from the Institutional Ethics Committee, all patients diagnosed with NOE fractures reporting to the department of Oral and Maxillofacial Surgery and Level-1 trauma centers were included in the study. The patients who did not give consent to participate in the study were excluded from the study. Diagnosis of NOE fracture was done by direct palpation of the medial orbital rim and perception of crepitus or movement. Bimanual palpation by placing a long artery forcep into the nose confirmed the diagnosis [Figure 1]. All patients were advised computed tomography (CT) scans with three-dimensional (3D) reconstruction. Sociodemographic data along with the etiology and type of fracture were mentioned. Associated injuries to other body parts were noted.

Most of our patients were very poor and unable to pay for implants. This along with the associated life-threatening injuries precluded open reduction of NOE fractures in our setup. Open reduction was possible only in five cases of NOE fractures. In three patients, the fracture site was exposed through hemicoronal incision, while in the rest two cases, an existing laceration combined with upper vestibular incision gave adequate access. The nasal bones and the central fragment were visualized, reduced, and fixed with 1.5 mm plating system.

**RESULTS**

A total of 1192 patients of facial fracture were seen, of which 52 (4.36%) patients had NOE fractures. Males far outnumbered females in a ratio of 9:1. The average age of the patients was 29.63 years (range: 17–71; mode, 28) [Table 1]. Road traffic accidents (RTA) were the most common cause of NOE fractures (69%), followed by fall (17%) and assault (10%). One patient had sports as the etiology, while another one had NOE injury from bear attack. In RTAs, motorcycles were more commonly involved contributing to 25 cases (69%) of NOE fractures, followed by four-wheelers (22%). Among the two-wheeler victims, 19 were drivers, while the rest 6 were

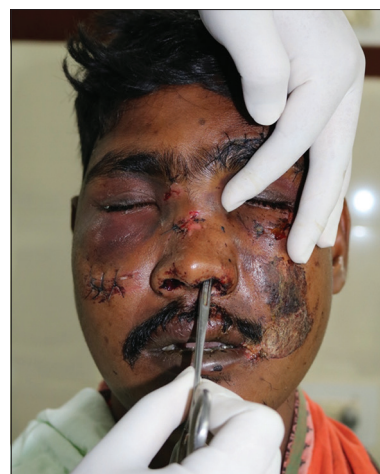

Figure 1: Bimanual palpation for diagnosis of nasoorbitoethmoid fracture

Table 1: Age distribution of nasoorbitoethmoid fracture patients

Age (years)	Male (%)	Female (%)	Number of cases (%)
0-10	0	0	0
11-20	2	1	3 (5.76)
21-30	36	1	37 (71.15)
31-40	7	2	9 (17.30)
41-50	1	1	2 (3.84)
51-60	0	0	0
>61	1	0	1 (1.92)
Total	47 (90.38)	5 (9.62)	52 (100)

pillion riders. Only 1 patient was wearing a helmet at the time of the accident, while the other 24 were not. The 8 four-wheeler victims, all of them drivers, did not wear seat belt at the time of accident. Five of the eight four-wheelers were equipped with airbags. Twenty-eight patients (54%) were under the influence of alcohol at the time of facial injury.

About two-third of the patients had associated injuries in nonfacial regions [Table 2]. The most common neurological injury to be associated with NOE fractures was pneumocephalus (29%), followed by diffuse axonal injury (8%). Contusion and extradural hemorrhage were detected in 4% of cases each. Subdural hemorrhage was found only in one case [Table 3].

Telecanthus (100%) was found to be the primary clinical feature in patients of NOE fracture, followed by a depressed nasal bridge (92%). Cerebrospinal fluid (CSF) rhinorrhea was found in 4 patients (8%). Five of our patients (10%) had epiphora indicating obstruction of nasolacrimal duct. Only 3 (6%) patients complained of transient diplopia, while 9 patients (17%) had a total loss of vision in one eye [Table 4].

The NOE fractures observed in our study were isolated in 4 cases (7.69%) and associated with panfacial fractures in 12 cases (23.07%). Other facial fractures when considered individually, to be associated with NOE fractures, fracture of nasal bone was invariably associated with NOE fractures [Table 5].

Of the total of 52 patients. 33 (63.46%) had unilateral NOE fracture, while the rest 19 (36.54%) had bilateral NOE

fracture [Figure 2]. Combining both unilateral and bilateral NOE fractures and considering each side of bilateral fractures as a unique central segment, 49 (69%) were found to be Type-I injury, 21 (29.57%) were found to be Type-II injury, and 1 (1.43%) was found to be Type-III injury. However, as per the Markowitz classification, bilateral injuries are classified (and treated) according to the most severe injury.<sup>[1]</sup> Thus, 16 (30.76%) cases were classified as Type I, 35 (67.30%) as Type II, and 1 (1.92%) as Type III [Figures 3 and 4].

Complications observed due to untreated NOE fractures included a shortened and retruded nose, shortened palpebral fissures, telecanthus, and enophthalmos. Moreover, soft-tissue retraction and scarring occurred in all of our operated patients. One patient complained of regurgitation of liquid through the nose while drinking in the postoperative period. One patient suffered from a stitch abscess in the NOE region.

### DISCUSSION

Fractures of the NOE bony complex and injuries of the adjacent soft tissues usually occur as a result of a direct force to the dorsum of the nose. This type of injury results in severe cosmetic and functional deformity due to the collapse of the nasal structures and interruption of attachment of the medial palpebral ligaments. The best results are obtained by an early aggressive surgical approach preceded by careful preoperative evaluation and precise documentation of the extent of the injury.

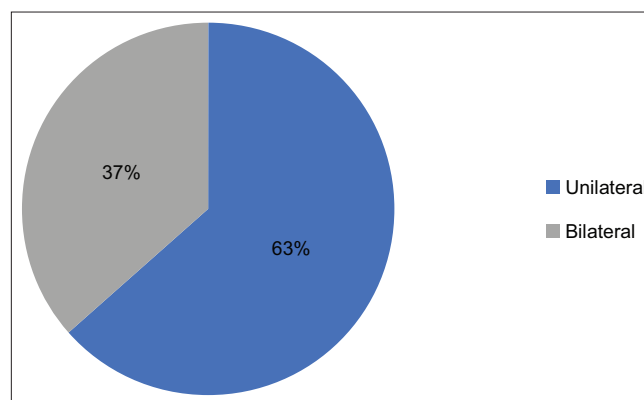
This incidence rate of NOE fracture in our study (4.36%) is similar to that reported by Kelley *et al.*<sup>[2]</sup> (4.76%) and Kyrgidis *et al.*<sup>[3]</sup> (4.8%). However, this is in contrast to a previous study in our institution, in which the incidence of NOE fracture was found only to be 0.53%.<sup>[4]</sup> This may be due to increased awareness among patients as well as utilization of CT scan

**Table 2: Associated other injury in nasoorbitoethmoid fracture patients**

Associated other injury	Number of patients (%)
Head injury	24 (46.15)
Orthopedic injury	29 (55.76)
Ophthalmologic injury	9 (17.30)
Cervical spine injury	4 (7.69)
Abdominal injury	6 (11.53)
Soft-tissue injury	46 (88.46)

**Table 3: Associated neurologic injury in nasoorbitoethmoid fracture patients**

Associated neurological injury	Number of patients (%)
Pneumocephalus	15 (28.84)
Contusion	2 (3.84)
Extradural haemorrhage	2 (3.84)
Subdural haemorrhage	1 (1.92)
Diffuse axonal injury	4 (7.69)
Sub-arachnoid hemorrhage	0 (0)
Total	24 (46.15)



**Figure 2: Unilateral/bilateral nasoorbitoethmoid fracture distribution in the study population**

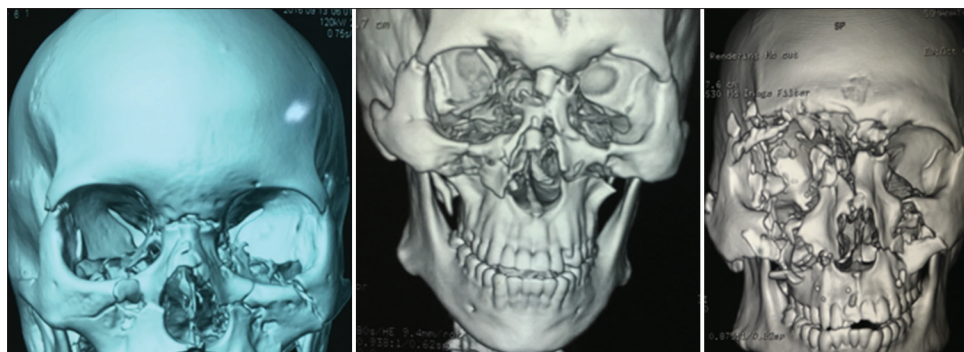


Figure 3: Different types of naso-orbito-ethmoid fractures in the study population

Table 4: Clinical features in naso-orbito-ethmoid fracture patients

Clinical features	Number of patients (%)
Telecanthus	52 (100)
Depressed nasal bridge	48 (92.30)
Facial edema	45 (86.53)
Laceration	32 (61.53)
Paraesthesia	25 (48.07)
Epistaxis	22 (42.30)
Loss of vision	9 (17.30)
Epiphora	5 (9.61)
CSF rhinorrhea	4 (7.69)

CSF: Cerebrospinal fluid

Table 5: Associated facial bone injury in naso-orbito-ethmoid fracture patients

Associated fracture site	Number of patients (%)
Nasal bone	52 (100)
Maxilla	46 (88.46)
Zygomatic complex	39 (75)
Frontal bone	32 (61.53)
Mandible	27 (51.92)
Dentoalveolar injury	17 (32.69)

with 3D reconstruction for diagnosis of every case of NOE fracture in the present study.

The most affected age group in this study was 21–30 years (71.15%) followed by the age group of 31–40 years (17.30%). Males accounted for 90.38% of all patients. The possible explanation for this is that males between the ages of 21 and 30 years drive motor vehicles carelessly without wearing helmets or seat belts and are more likely to be involved in interpersonal violence.

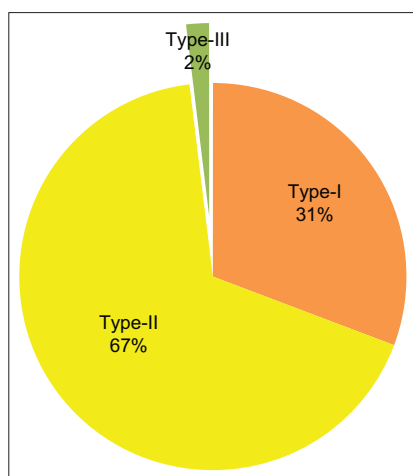
The mean time of reporting of the patients to OMFS OPD or emergency, in this study, was found to be 3.87 days (range: 1–21 days) after trauma. The factors contributing to delay were the distance from the maxillofacial unit, priorities given to more serious injuries, failure of other specialists to recognize facial fractures, and lack of facilities in the nearby

state government hospitals. The delay in reporting sometimes precluded surgical management in our setup.

In the present study, the etiology of NOE fractures in the decreasing order of frequency was RTAs (69.23%), fall (17.30%), assault (9.61%), sports (1.92%), and animal attack (1.92%). This is in agreement with the study by Kar and Mahavoi on facial fractures in Odisha.<sup>[4]</sup> The probable explanation for this is that a large proportion of the population in India uses a two-wheeler as the primary mode of transport. High-speed imprudence not using helmets can explain the high number of NOE fractures secondary to two-wheeler accidents.

Four-wheeler accidents contributed to 15.38% of our NOE fracture patients, all of who were drivers and did not wear a seat belt at the time of accident. A retrospective review of the US data collected by the National Automotive Sampling System Crashworthiness Data System between 1993 and 2005 has shown yearly decreases in facial injuries as a result of motor vehicle collision.<sup>[5]</sup> Interestingly, the authors found that restraint with seat belt was of paramount importance and airbags alone do not always prevent facial injury. Unfortunately, in India, only 25% of car drivers fasten seat belt, as per the findings of the pan-India study “Seat belt usage in India, 2017” conducted by market research firm Millward Brown and IMRB (Kantar Group) for Maruti Suzuki recently.<sup>[6]</sup> With the recent mandate by the Union Road Transport Ministry, Government of India that all four-wheelers that come off the production line after July 1, 2019, will have to be compulsorily equipped with airbags and seat belt reminders, hopefully, the incidence of facial fractures, especially NOE fractures, due to four-wheeler accidents will go down significantly.<sup>[7]</sup>

Interpersonal violence or assault (9.61%) remains a common cause for NOE fractures. These types of injuries tend to be lower-energy injuries compared with RTA and are generally less likely to have concomitant brain injuries. NOE fractures are relatively rare from sporting injuries.<sup>[8]</sup> In our study, only



**Figure 4: Distribution of various types of naso-orbitoethmoid fractures in the study population**

1 patient (1.92%) had NOE fracture due to trauma from a cricket ball.

About 53.84% of our patients were under the influence of alcohol at the time of facial injury. Alcohol causes increased reckless behavior leading to RTAs and interpersonal violence, in turn, contributing to increased incidence of NOE fractures.

The friends and relatives of every patient were asked for pretraumatic photograph of the patient. Unfortunately, in the limited number of cases where they were available, the photographs were not of very good quality. Nonetheless, it allowed for a subjective assessment of the pretraumatic facial features. A pretraumatic photograph of the individual, if available, assures that an existing deformity (e.g., depressed nasal bridge or deviated nose) was not present<sup>[9]</sup> and also allows the evaluation of pretraumatic intercanthal distance in some cases.<sup>[10]</sup>

Telecanthus invariably accompanies severe NOE injuries.<sup>[11]</sup> In our study, telecanthus was a consistent clinical feature detected in all cases (100%) of NOE fractures in contrast to Cruse *et al.*<sup>[12]</sup> who have noted traumatic telecanthus in 70% of cases. Short and retruded nasal bridge was found in 92.30% of cases. There was no depression of nasal bridge in some unilateral cases of undisplaced or minimally displaced NOE fractures. Enophthalmos and shortened palpebral fissure were found in 84.61% and 90.38% cases, respectively.

The intercanthal distance is a measurement taken between the medial ends of the palpebral fissure and it should be approximately half of the interpupillary distance.<sup>[13]</sup> Soft-tissue intercanthal distances greater than 35 mm are suggestive of a displaced NOE fracture and distances greater than 40 mm are diagnostic.<sup>[14]</sup> The diagnosis of telecanthism

is important because it is the most compelling reason for the open treatment of NOE injury.<sup>[13]</sup>

The diagnosis of NOE fractures is suggested by direct palpation of the medial orbital rim and perception of crepitus or movement. The “eyelid traction test”<sup>[15]</sup> is only helpful in comminuted injuries.<sup>[13]</sup> In our study, it diagnosed only 7 (13.46%) of 52 patients correctly. Bimanual palpation by placing an instrument, like a long artery forcep into the nose, is the gold standard for physical examination of NOE fractures.<sup>[16,17]</sup> Indeed, it confirmed NOE fracture in all of our patients, although it can sometimes precipitate nasal bleeding, especially in patients with a history of epistaxis.

CSF rhinorrhea, though common after NOE fractures,<sup>[18]</sup> is not diagnostic because this may accompany frontal sinus, orbital roof, and Le Fort fractures. Neither is its absence evidence against an NOE fracture because many patients do not have CSF rhinorrhea. Cruse *et al.*<sup>[12]</sup> reported CSF rhinorrhea in 40% cases of NOE fractures, while Ellis<sup>[13]</sup> reported it to be 42.30%. In our study, the incidence of CSF rhinorrhea was lower (7.69%). This may be attributed to the fact that some of the NOE fracture patients were evaluated very late, in few cases as late as 21 days post trauma, by which time the CSF rhinorrhea would have subsided on its own. All of them were prescribed acetazolamide (250 mg qid) and lactulose syrup (1 tablespoon bid) and managed conservatively, as advised by the neurosurgeon. The CSF rhinorrhea ceased spontaneously in all patients within 3–4 days which is in agreement with the literature.<sup>[19,20]</sup>

NOE injuries frequently result in epiphora secondary to interference with the physiology or continuity of the lacrimal drainage apparatus.<sup>[9]</sup> We noticed epiphora only in 9.61% of cases, which is somewhat similar to that reported by Markowitz *et al.* (5%).<sup>[11]</sup> Epiphora in all of our patients was resolved without any intervention. Merckx *et al.*<sup>[21]</sup> have reported a 19% incidence of epiphora. Gruss *et al.*<sup>[11]</sup> have reported an incidence of 45.65% epiphora in NOE fractures, of which 28.26% of cases resolved spontaneously and the rest 17.4% required eventual dacryocystorhinostomy. Similarly, Becelli *et al.*<sup>[22]</sup> reported the incidence of epiphora to be 46.5%, of which 17.24% recovered spontaneously and 29.31% required dacryocystorhinostomy. Once again, the lower incidence of epiphora in our study can be attributed to the delayed reporting of some patients.

Every patient with facial trauma should be considered at risk for ocular injury.<sup>[23,24]</sup> In this study, 3 (5.76%) patients complained of transient diplopia, while 9 patients (17.30%) had a total loss of vision in one eye. These data are somewhat

lower than that reported in literature. Al-Qurainy *et al.*<sup>[25]</sup> have reported 19.8% diplopia in patients of midfacial fractures. In a study reported by Holt and Holt,<sup>[26]</sup> 89% of frontal fractures and 59% each of midfacial and nasal fractures sustained some degree of ocular injury. Among these ocular injuries, 18% were considered serious, whereas 3% resulted in blindness. Other series<sup>[20,23,24,27]</sup> have reported an incidence of ocular injuries with facial trauma ranging from as low as 4% to as high as 67%. Most of the series report the incidence of significant ocular injury with initial or subsequent loss of sight to be in the 20%–25% range, while Cruse *et al.*<sup>[12]</sup> have reported an incidence as high as 30% of NOE fracture patients. Thus, a thorough examination of the eye should accompany any physical examination of NOE fracture patients.

NOE fractures are difficult to detect on plain radiographs.<sup>[28-30]</sup> CT is considered the gold standard for diagnosing fractures of the nasofrontal region.<sup>[8]</sup> Coronal and axial images spaced at 1.5 mm are necessary to determine the extent and degree of comminution of the fractures.<sup>[31,32]</sup> Remmler *et al.*<sup>[33]</sup> recommended the combination of 3D CT with 2D CT for NOE injuries. 3D reformatting of the CT data can be extremely useful for diagnosis and treatment planning of fractures involving the nasofrontal region.<sup>[8,34]</sup>

The NOE fractures observed in our study were isolated in 4 cases (7.69%) and associated with panfacial fractures in 12 cases (23.07%) which is similar to that reported by Becelli *et al.*<sup>[22]</sup> Other facial fractures when considered individually to be associated with NOE fractures included maxilla fracture in 46 (88.46%) patients, followed by zygomatic complex fracture (75%), frontal bone fracture (61.53%), mandible fracture (51.92%), and dentoalveolar injury (32.69%). Among the maxilla fracture patients, 28.84% had Le-Fort I, 53.84% had Le-Fort II, and only 5.76% had Le-Fort III fracture which is higher than reported literature. Herford *et al.*<sup>[35]</sup> reported that fracture of the zygomaticomaxillary complex was the most common additional fracture in patients of severely comminuted (Type III) NOE injury.

In a study by Ellis,<sup>[13]</sup> 17 of 26 (65.38%) patients with NOE fractures had associated facial fractures, most commonly Le Fort maxillary and/or frontal sinus fractures. Daly *et al.*<sup>[36]</sup> reported associated Le Fort II or III maxilla fractures in 29% of naso-ethmoidal trauma patients. Depressed naso-ethmoidal fractures may also extend posteriorly into the sphenoid sinus and optic canals. Such injuries were uncommon in our series though Unger<sup>[37]</sup> noted that such fractures may be clinically unsuspected but detectable on high-resolution CT or pluridirectional tomography.

In this study, intracranial injury was reported in 46.15% of cases and orthopedic injury in 55.76% of cases. The most common associated injury in NOE fracture patients was soft-tissue injuries in the extremities (88.46%). Ophthalmologic injury was found in a significant number of patients (23.07%), of which 17.30% suffered vision loss. Cervical spine injury was detected in 7.69% of cases, while blunt trauma to the abdomen was found in 11.53% of patients. Neurosurgical intervention, management of orthopedic injuries, or cervical spine injuries superceded treatment of NOE fractures. Sometimes, delay of a number of days was required to allow for subsidence of the cranial hematoma or edema and to await clarification on the neurosurgical status of the patient.

We observed that of the total of 52 patients, 33 (63.46%) had unilateral NOE fracture, while the rest 19 (36.54%) had bilateral NOE fractures. These data concur with Kyrgidis *et al.*<sup>[3]</sup> and Lauer and Pinzer.<sup>[38]</sup> Interestingly, this is opposite to that reported by Markowitz *et al.*<sup>[1]</sup> in a series of 234 patients. They have reported the incidence of unilateral NOE fractures to be 33%–36% and bilateral NOE fractures to be 64%–67%. Paskert *et al.*<sup>[14]</sup> have observed approximately one-third of patients to have unilateral NOE fracture. Ellis<sup>[13]</sup> in a series of 26 NOE fracture patients found 11 cases (42.30%) to be unilateral and the remaining 15 (57.69%) to be bilateral.

The most common classification method for NOE fractures suggested by Markowitz *et al.*<sup>[1]</sup> is clinically useful for both the diagnosis and management of NOE fractures. Type I fractures include a single-segment central fragment, in which the medial canthal ligament is attached to a relatively large segment of the fractured bone. In Type-II fractures, the central fragment is comminuted, although the fractures remain external to the medial canthal ligament insertion. Type-III fractures are conditions in which the insertion of the medial canthal ligament is comminuted.

In our study, 16 (30.76%) cases were classified as Type-I NOE fracture, 35 (67.30%) as Type-II NOE fracture, and 1 (1.92%) as Type-III NOE fracture which is similar to that reported by Markowitz *et al.*<sup>[1]</sup> According to the literature, the least common fractures in this classification are Type-III fractures, accounting for 1%–5% of all NOE fractures.<sup>[1,13,39]</sup> The canthal tendon is usually attached to a sizeable bony fragment and not avulsed from bone.<sup>[13,14,40]</sup>

The surgical treatment of NOE fractures is guided by the pattern and classification of injury. The surgical approach also varies according to the fracture type and other concomitant facial injuries. Nondisplaced Type-I fractures with a single

central fragment and an intact medial canthal tendon attachment often require no surgical intervention, and the patients can be followed clinically.<sup>[41]</sup> However, most NOE fractures are best treated by open reduction and internal fixation. Secondary deformities that accompany inadequate therapy are extremely difficult to correct.<sup>[13]</sup>

Poor patients unconcerned about esthetics, inability to pay for implants, and associated life-threatening injuries precluded open reduction of NOE fractures in most of our cases. We did dorsal nasal bone grafting in one patient. The graft was taken from the outer table of the parietal calvarium and fixed with plates and screws. However, the result was not very much encouraging, and the nasal dorsum became depressed postoperatively. This might be due to bone resorption, soft-tissue contraction, and possibly bone displacement.

Markowitz *et al.*<sup>[1]</sup> used dorsal nasal bone grafts in 42% of their NOE fractures. Ellis<sup>[3]</sup> used dorsal nasal bone grafts in 8 of 26 cases of NOE fracture but thought that the need for this procedure was certainly greater because there is a perceived reciprocal relationship between dorsal nasal projection and interorbital/intercanthal width. Overprojection of the nasal dorsum should be the goal with treatment of NOE injuries as it is much more esthetically acceptable than under projection.

A 5-year prospective study involving 1024 cases of facial fractures demonstrated that NOE fractures present the highest rate of complications of all facial fractures.<sup>[42]</sup> Most complications associated with NOE fractures result from inadequate treatment at the time of the initial injury.

In this study, characteristic deformities seen due to untreated NOE fractures include a shortened and retruded nose, shortened palpebral fissures, telecanthus, and enophthalmos. Moreover, soft-tissue retraction and scarring occurred in cases where the fracture site was exposed through an existing laceration. One of our patients who was operated for NOE fracture and concomitant Le Fort II maxilla fracture complained of regurgitation of liquid through the nose while drinking postoperatively. The oronasal communication was repaired secondarily with a vascularized palatal island flap and it healed without any further complications.

Concomitant infection is rarely reported in NOE fractures. In a study of 1239 cases of maxillofacial fractures, Kyrgidis *et al.*<sup>[3]</sup> reported 7 (11.66%) cases of infection of 60 NOE fractures. In our study, only one patient suffered from a stitch abscess in the NOE region which was promptly relieved after drainage and administration of antibiotics.

We did not encounter any significant complications due to infection. This may be due to routine prophylactic use of antibiotics (cefoperazone + sulbactam 1.5 g bid/ceftriaxone 1 g bid) in all patients of maxillofacial trauma in our setup.

## CONCLUSION

Contemporary management of NOE complex fractures demands precise diagnosis with physical assessment and high-resolution imaging. Surgical management of these injuries is based on the principles of anatomic reduction and rigid fixation of the involved bone segments. With an improvement in socioeconomic status and increased awareness among maxillofacial surgeons in this part of the world, hopefully, a greater number of NOE fracture patients will avail the benefits of open reduction in future.

## Declaration of patient consent

The authors certify that they have obtained all appropriate patient consent forms. In the form the patient(s) has/have given his/her/their consent for his/her/their images and other clinical information to be reported in the journal. The patients understand that their names and initials will not be published and due efforts will be made to conceal their identity, but anonymity cannot be guaranteed.

## Financial support and sponsorship

Nil.

## Conflicts of interest

There are no conflicts of interest.

## REFERENCES

1. Markowitz BL, Manson PN, Sargent L, Vander Kolk CA, Yaremchuk M, Glassman D, *et al.* Management of the medial canthal tendon in nasoethmoid orbital fractures: The importance of the central fragment in classification and treatment. *Plast Reconstr Surg* 1991;87:843-53.
2. Kelley P, Crawford M, Higuera S, Hollier LH. Two hundred ninety-four consecutive facial fractures in an urban trauma center: Lessons learned. *Plast Reconstr Surg* 2005;116:42e-9e.
3. Kyrgidis A, Koloutsos G, Kommata A, Lazarides N, Antoniadis K. Incidence, aetiology, treatment outcome and complications of maxillofacial fractures. A retrospective study from Northern Greece. *J Cranio-Maxillofac Surg* 2013;41:637-43.
4. Kar IB, Mahavoi BR. Retrospective analysis of 503 maxillo-facial trauma cases in Odisha during the period of Dec'04-Nov'09. *J Maxillofac Oral Surg* 2012;11:177-81.
5. McMullin BT, Rhee JS, Pintar FA, Szabo A, Yoganandan N. Facial fractures in motor vehicle collisions: Epidemiological trends and risk factors. *Arch Facial Plast Surg* 2009;11:165-70.
6. Available from: <https://timesofindia.indiatimes.com/india/only-25-of-drivers-fasten-seat-belts-in-india-study/articleshow/61513168.cms>. [Last accessed on 2021 Jan 04].
7. Available from: <https://timesofindia.indiatimes.com/india/>

- from-2019-airbag-speed-alert-parking-sensor-must-in-cars/articleshow/61313493.cms. [Last accessed on 2021 Jan 04].
8. Morrison AD, Gregoire CE. Management of fractures of the nasofrontal complex. *Oral Maxillofac Surg Clin North Am* 2013;25:637-48.
  9. Dingman RO, Grabb WC, Oneal RM. Management of injuries of the naso-orbital complex. *Arch Surg* 1969;98:566-71.
  10. Tharanon W, Ellis E 3<sup>rd</sup>. A method to accurately determine the preinjury intercanthal distance. *J Oral Maxillofac Surg* 1991;49:1023-5.
  11. Gruss JS, Hurwitz JJ, Nik NA, Kassel EE. The pattern and incidence of nasolacrimal injury in naso-orbital-ethmoid fractures: The role of delayed assessment and dacryocystorhinostomy. *Br J Plast Surg* 1985;38:116-21.
  12. Cruse CW, Blevins PK, Luce EA. Naso-ethmoid-orbital fractures. *J Trauma* 1980;20:551-6.
  13. Ellis E 3<sup>rd</sup>. Sequencing treatment for naso-orbito-ethmoid fractures. *J Oral Maxillofac Surg* 1993;51:543-58.
  14. Paskert JP, Manson PN, Iliff NT. Nasoethmoidal and orbital fractures. *Seminars in Ophthalmology* 1989;4:148-60.
  15. Furnas DW, Bircoll MJ. Eyelash traction test to determine if the medial canthal ligament is detached. *Plast Reconstr Surg* 1973;52:315-7.
  16. Paskert JP, Manson PN. The bimanual examination for assessing instability in naso-orbitoethmoidal injuries. *Plast Reconstr Surg* 1989;83:165-7.
  17. Papadopoulos H, Salib NK. Management of naso-orbital-ethmoidal fractures. *Oral Maxillofac Surg Clin North Am* 2009;21:221-5.
  18. Maxwell JA, Goldware SI. Use of tissue adhesive in the surgical treatment of cerebrospinal fluid leaks. Experience with isobutyl 2-cyanoacrylate in 12 cases. *J Neurosurg* 1973;39:332-6.
  19. Beyer CK, Fabian RL, Smith B. Naso-orbital fractures, complications, and treatment. *Ophthalmology* 1982;89:456-63.
  20. Beyer CK, Smith B. Naso-orbital fractures, complications and treatment. *Ophthalmologica* 1971;163:418-27.
  21. Merckx MA, Freihofer HP, Borstlap WA, van 't Hoff MA. Effectiveness of primary correction of traumatic telecanthus. *Int J Oral Maxillofac Surg* 1995;24:344-7.
  22. Becelli R, Renzi G, Mannino G, Cerulli G, Iannetti G. Posttraumatic obstruction of lacrimal pathways: A retrospective analysis of 58 consecutive naso-orbitoethmoid fractures. *J Craniofac Surg* 2004;15:29-33.
  23. Weisman RA, Savino PJ. Management of patients with facial trauma and associated ocular/orbital injuries. *Otolaryngol Clin North Am* 1991;24:37-57.
  24. Al-Qurainy IA, Dutton GN, Ilankobvan V, Moos KF, El-Attar A, Titterington DM. Midfacial fractures and the eye: The development of a system for detecting patients at risk of eye injury-a prospective evaluation. *Br J Oral Maxillofac Surg* 1991;29:368-9.
  25. Al-Qurainy IA, Stassen LF, Dutton GN, Moos KF, El-Attar A. Diplopia following midfacial fractures. *Br J Oral Maxillofac Surg* 1991;29:302-7.
  26. Holt GR, Holt JE. Incidence of eye injuries in facial fractures: An analysis of 727 cases. *Otolaryngol Head Neck Surg* 1983;91:276-9.
  27. Ioannides C, Treffers W, Rutten M, Noverraz P. Ocular injuries associated with fractures involving the orbit. *J Cranio Maxillofac Surg* 1988;16:157-9.
  28. Johnson DH Jr., Colman M, Larsson S, Garner OP Jr., Hanafee W. Computed tomography in medial maxilla-orbital fractures. *J Comp Assisted Tomography* 1984;8:416.
  29. Meara DJ. Acquired defects of the nose and naso-orbitoethmoid (NOE) region. *Oral Maxillofac Surg Clin North Am* 2013;25:131-49.
  30. Hoffmann JF. Naso-orbital-ethmoid complex fracture management. *Facial Plast Surg* 1998;14:67-76.
  31. Manson PN, Markowitz B, Mirvis S, Dunham M, Yaremchuk M. Toward CT-based facial fracture treatment. *Plast Reconstr Surg* 1990;85:202-12.
  32. Rosenberger E, Kriet JD, Humphrey C. Management of nasoethmoid fractures. *Curr Opin Otolaryngol Head Neck Surg* 2013;21:410-6.
  33. Remmler D, Denny A, Gosain A, Subichin S. Role of three-dimensional computed tomography in the assessment of naso-orbitoethmoidal fractures. *Ann Plast Surg* 2000;44:553-62.
  34. Fedok FG, Goldenberg D, Park SS. Treatment of frontal sinus and nasoethmoid orbital fractures. In: *Rhinology and Facial Plastic Surgery*. Berlin, Heidelberg: Springer; 2009. p. 809-15.
  35. Herford AS, Ying T, Brown B. Outcomes of severely comminuted (type III) naso-orbitoethmoid fractures. *J Oral Maxillofac Surg* 2005;63:1266-77.
  36. Daly BD, Russell JL, Davidson MJ, Lamb JT. Thin section computed tomography in the evaluation of naso-ethmoidal trauma. *Clin Radiol* 1990;41:272-5.
  37. Unger JM. Orbital apex fractures: The contribution of computed tomography. *Radiology* 1984;150:713-7.
  38. Lauer G, Pinzer T. Transcaruncular-transnasal suture: A modification of medial canthopexy. *J Oral Maxillofac Surg* 2008;66:2178-84.
  39. Nguyen M, Koshy JC, Hollier LH Jr., Pearls of naso-orbitoethmoid trauma management. *Semin Plast Surg* 2010;24:383-8.
  40. Sargent LA. Acute management of nasoethmoid orbital fractures. *Operat Techniques Plastic Reconstruct Surg* 1998;5:213-22.
  41. Sh ME, Shahnasari S, Soltani P, Motamedi MR. Management of Naso-Orbito-Ethmoid Fractures: A 10-Year Review. *Trauma Monthly*, 2017;22:1-10. doi: 10.5812/traumamon.29230.
  42. Brasileiro BF, Passeri LA. Epidemiological analysis of maxillofacial fractures in Brazil: A 5-year prospective study. *Oral Surg Oral Med Oral Pathol Oral Radiol Endod* 2006;102:28-34.