



Multicompartmental Osteochondral Allografts of Knee and Concomitant High Tibial Osteotomy

Jonathan A. Godin, M.D., M.B.A., Zaamin B. Hussain, B.A., Anthony Sanchez, B.S., George Sanchez, B.S., Márcio B. Ferrari, M.D., Mark E. Cinque, M.S., Nicholas I. Kennedy, M.D., and CAPT Matthew T. Provencher, M.D., M.C., U.S.N.R.

Abstract: Chondral lesions of the knee can occur secondary to limb malalignment. To address these interrelated problems, a high tibial osteotomy with concomitant osteochondral allograft transfer may be performed. It is important to address these chondral lesions as they often affect the young and active population and cause morbidity in an otherwise healthy population. Although numerous approaches for the treatment of chondral lesions have been described, long-term results demonstrating regeneration of hyaline cartilage have yet to be reported. Furthermore, larger, full-thickness cartilage defects, which can be caused by limb malalignment, have proven to be particularly challenging to treat. This Technical Note details our technique for multicompartmental osteochondral allograft transplantation with concomitant high tibial osteotomy in a patient with 2 focal cartilage lesions in the knee.

Focal articular cartilage injuries of the knee are common and debilitating, particularly for young, active patients.¹⁻³ The avascularity of articular cartilage limits its native healing potential and predisposes the injured cartilage to early-onset osteoarthritis.^{3,4} Osteoarthritis is also more likely to occur in the presence of abnormal biomechanics, such as varus or valgus knee malalignment, which can produce imbalanced joint contact forces in the knee and increased unicompartamental pressure. In the context of both of these risk factors in young patients, the goal should be to prevent early-onset osteoarthritis and preserve the joint wherever possible.

Various options have emerged for small chondral lesions of the knee, in the range of 1 to 4 cm²,

From the Steadman Clinic (J.A.G., M.T.P.); Steadman Philippon Research Institute (J.A.G., Z.B.H., A.S., M.B.F., M.E.C., N.I.K., M.T.P.), Vail, Colorado; and Geisel School of Medicine at Dartmouth (G.S.), Hanover, New Hampshire, U.S.A.

The authors report the following potential conflicts of interest or sources of funding: M.T.P. receives support from Arthrex and SLACK. Full ICMJE author disclosure forms are available for this article online, as [supplementary material](#).

Received March 31, 2017; accepted July 12, 2017.

Address correspondence to CAPT Matthew T. Provencher, M.D., M.C., U.S.N.R., Steadman Philippon Research Institute, 181 West Meadow Drive, Suite 1000, Vail, CO 81657, U.S.A. E-mail: mprovencher@thesteadmanclinic.com

© 2017 by the Arthroscopy Association of North America. Published by Elsevier. This is an open access article under the CC BY-NC-ND license (<http://creativecommons.org/licenses/by-nc-nd/4.0/>).

2212-6287/17476

<https://doi.org/10.1016/j.eats.2017.07.026>

including, microfracture, autologous chondrocyte implantation, and osteochondral autograft transfer. These treatment options have shown encouraging results in medium sized lesions^{5,6} but limited potential for scalability to large chondral lesions. Osteochondral allograft transfer has shown promise as a joint-preserving technique for large chondral lesions, without the disadvantages of donor site comorbidity, slow recovery, or the need for a 2-stage procedure. It can be noted in some patients receiving osteochondral allograft transfer that malalignment is also present, which is defined by a weight-bearing axis that passes medial or lateral to the tibial eminences. These patients should undergo a concurrent tibial osteotomy to realign the mechanical axis.

This Technical Note details our technique for multicompartmental osteochondral allograft transplantation with concomitant high tibial osteotomy in a patient with 2 focal cartilage lesions in the knee.

Indications and Contraindications for Surgery

The main indication for multicompartmental osteochondral allograft transplantation and concurrent high tibial osteotomy is the presence of multiple symptomatic full-thickness articular cartilage defects >3 cm², with any degree of varus malalignment of the medial to the apex of the medial tibial eminence. Contraindications include an ipsilateral tibial cartilage lesion, ligamentous instability,

Table 1. Pearls and Pitfalls

Pearls	Pitfalls
Use of fluoroscopy repeatedly throughout the high tibial osteotomy prevents error and maximizes potential for a positive result.	Infrequent use of fluoroscopy during the high tibial osteotomy results in greater likelihood of surgical error.
Richard staples may be placed in the lateral tibial cortex to reduce the risk of fixation failure and lateral tibial fracture.	Although not necessary, lateral tibial fracture is possible especially without the accessory use of Richard staples.
Verify that the patella allograft matches the defect site circumferentially. Therefore, verify the height of the allograft at each clock position prior to graft implantation into defect site.	Lack of circumferential verification of the patella allograft may lead to improper allograft size and surgical failure.
Use of pulse lavage and platelet-rich plasma solution maximizes potential for incorporation of allograft and postoperative success.	Without pulse lavage and platelet rich plasma, the likelihood of nonunion or mal-union of the allograft to the native bone is greater.
Further fixation of the lateral femoral condyle allograft is possible through use of 2 bioabsorbable screws.	Poor fixation of the lateral femoral condyle allograft may lead to surgical failure.

malalignment, more than minor peripheral osteophytes, joint space narrowing, or the absence of >50% of the meniscus in the affected compartment. Patients with >50% loss of the meniscus in the ipsilateral compartment should undergo a concurrent meniscal transplantation.

Surgical Technique

Prior to surgery, measurement of the varus malalignment and the amount of correction that needs to be done via the high tibial osteotomy is performed. These measurements were taken with weightbearing hip-knee-ankle radiographs to examine the mechanical axis, a straight line drawn from the center of the femoral head through the center of the talar dome. The necessary correction, based on this measurement, was carried out during surgery.

Patient Positioning and Anesthesia

The patient is placed in the supine position on the operating table, and general anesthesia is used for induction. A well-padded high-thigh tourniquet is subsequently placed on the operative leg, and then a bump is placed under the knee so that it rests at approximately 30° of flexion. The contralateral leg is secured to the table in full extension with a pneumatic compression device to help prevent deep vein thrombosis. Pearls and pitfalls associated with this procedure are listed in [Table 1](#).

Objective Diagnosis

Preoperative evaluation should start with a thorough history and physical examination. Diagnostic imaging should consist of long-leg standing radiographs to assess mechanical alignment and the desired amount of correction. Magnetic resonance imaging of the knee allows confirmation of the size and extent of the chondral lesion, as well as any concomitant ligamentous, meniscal, or other soft-tissue injuries.

Operative Technique

The narrated video provides an overview of the described surgical technique ([Video 1](#)). General endotracheal anesthesia may be combined with regional nerve blocks to maximize postoperative pain control. Perioperative antibiotic prophylaxis is administered intravenously prior to incision. Prior to exposure, 60 mL of blood is drawn from the patient by the anesthesiologist and spun down using an Arthrex ACP spinning machine (Arthrex, Naples, FL) for approximately 10 minutes in preparation for soaking of the patella allograft in platelet-rich plasma solution.

High Tibial Osteotomy. A longitudinal incision is made over the anteromedial aspect of the proximal tibia. In this case example, the incision is extended proximally for a parapatellar approach. Soft-tissue dissection is carried out to the level of the superficial medial collateral ligament, which is subsequently reflected posteriorly. The interval between the patellar tendon and patellar fat pad is developed with a scalpel and freer elevator. Two osteotomy guide pins are drilled from the medial tibial metaphysis toward the superior aspect of the fibular head ([Fig 1](#)). These pins should

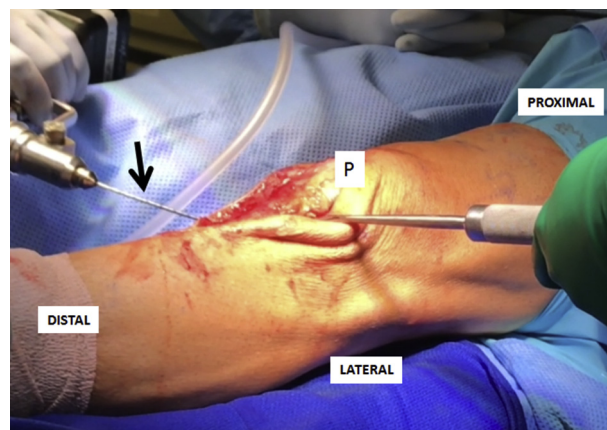


Fig 1. Under fluoroscopic guidance in this left knee, 2 osteotomy guide pins (black arrow) are drilled from the proximal medial tibial metaphysis toward the proximal superior lateral aspect of the tibia at the same level as the fibular head. These pins will be used as a guide for the use of the oscillating saw. (P, patella.)

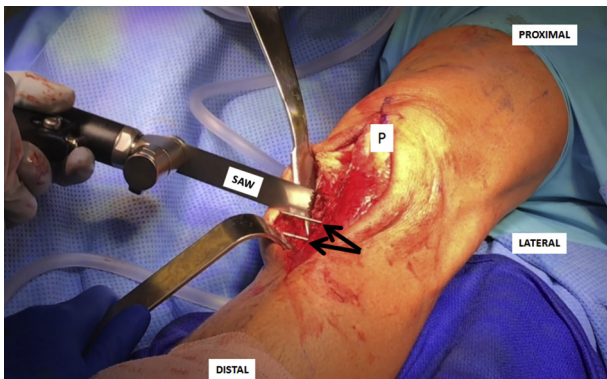


Fig 2. Once the 2 guide pins are inserted in the correct position (black arrows), an oscillating saw is used to perform the high tibial osteotomy in this left knee. Care must be taken to avoid a complete osteotomy. The correct position of the osteotomy should be 1 cm from the lateral cortex as a complete osteotomy can result in instability and fixation failure. If the osteotomy is not enough lateral (more than 1 cm from the lateral cortex), a fracture of the tibial plateau may occur during correction of limb alignment. (P, patella.)

stop approximately 1 cm medial to the lateral tibial cortex.

An oscillating saw positioned against the inferior surface of the cutting guide is used to cut the tibial cortex medially, anteriorly, and posteriorly (Fig 2). A single blade from the Osteotome Jack (Arthrex) may be used to complete the osteotomy. Fluoroscopic confirmation should be checked repeatedly throughout the cutting process. Insert both blades of the Osteotome Jack in the bone cut, aligning both blades to each other. Using a 3.5-mm hex screwdriver, turn the screw slowly, opening the jack to the desired correction (Fig 3). Be sure to maintain the lateral tibial cortex hinge. If the lateral cortex fractures, or if fracture is a concern, one

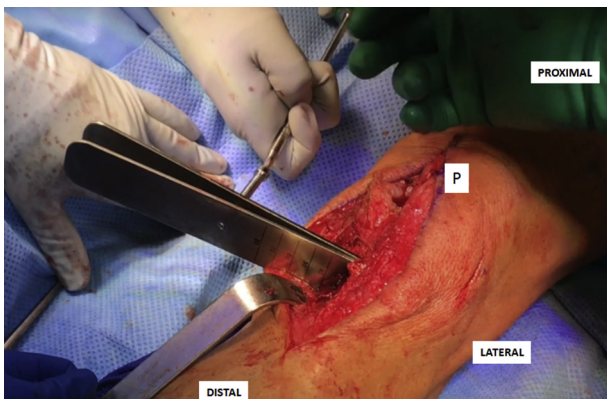


Fig 3. To achieve optimal correction of alignment in the left knee, 2 blades of the Osteotome Jack are inserted into the osteotomy site. A 3.5-mm hex screwdriver is used to open the blades. The degree of correction needed depends on the measurement of the deformity completed prior to surgery. (P, patella.)

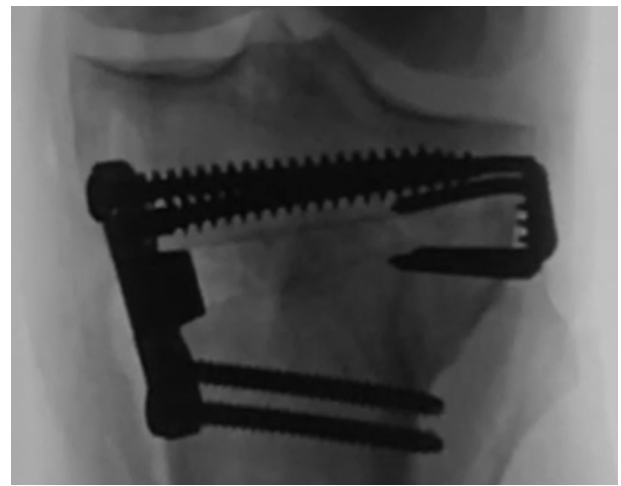

Fig 4. The final fluoroscopic image of the osteotomy performed in this left knee is demonstrated. Note the use of the plate and screws in the proximal medial tibial aspect with Richard staples placed in the lateral tibial cortex to reduce the risk of fixation failure and lateral tibial fracture.

or 2 Richards staples (Smith & Nephew, Andover, MA) may be inserted under fluoroscopic guidance.

The high tibial osteotomy wedge plate (Arthrex) is then positioned in the osteotomy site centered along the anteroposterior plane. Two 6.5-mm fully threaded cancellous screws are placed proximally, and 2 4.5-mm cortical screws are placed distally. Cancellous bone chips and demineralized bone matrix (AlloFuse, AlloSource, Centennial, CO) are packed into the remainder of the osteotomy site. Once complete, fluoroscopy is used to verify the completed high tibial osteotomy (Fig 4).

Patellar Osteochondral Allograft. A parapatellar approach (medial or lateral) is used to access the chondral

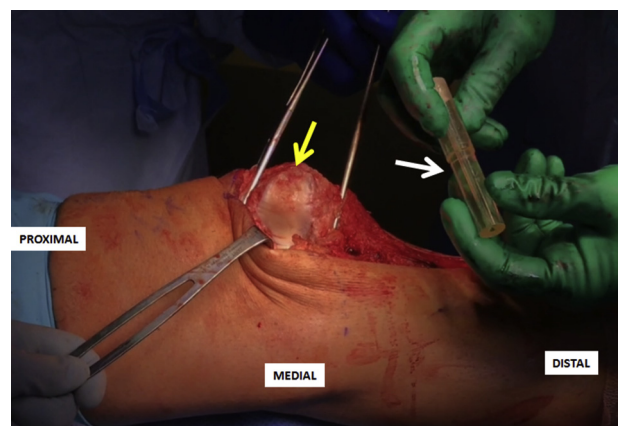


Fig 5. Once the high tibial osteotomy is performed, attention is turned to the patellar osteochondral lesion. A medial parapatellar incision is performed, and then the patella is everted to properly expose the cartilage surface (yellow arrow). The osteochondral lesion is identified, and then the correct sizer (white arrow) is chosen to ensure the full resection of the lesion. The same sizer will be used in the patella allograft.




Fig 6. An allograft workstation is used to form the patella allograft for this left knee. The allograft (black arrows) is carefully marked and secured to safely perform the cuts (A). Once the initial cuts were performed, the workstation is withdrawn. Then final steps to arrive at a graft ready for insertion are done manually using a small oscillating saw (B).

lesion. In this case, a medial parapatellar approach is employed with careful attention to avoid injury to the anterior horn of the medial meniscus. The patella is everted, and retractors are used to maintain eversion throughout this portion of the procedure. Next the osteochondral autograft transfer system (OATS) sizers (Arthrex) are used to identify the most appropriate coverage of the patella lesion (Fig 5). While holding the selected sizer in position, an indelible marker is used to outline the sizer. Care should be made to ensure adequate native osteochondral shoulders both medially and laterally for secure graft fixation.

The selected sizer used to establish the recipient defect site is then placed over the patella allograft until the appropriate donor site has been identified. The sizer should be outlined with indelible ink while denoting the superior and inferior aspects of the graft. The patella allograft is mounted in the workstation with 2.8-mm guide pins (Fig 6A). An appropriately sized circular reamer is used to harvest the graft. Ensure the marks denoting the superior and inferior aspects of the graft are visible and remark if necessary. Afterward, a small oscillating sagittal saw is used to perform all final cuts prior to graft implantation (Fig 6B). Insert the implant into the appropriately sized donor trial to confirm sizing. Thereafter, pulse lavage the graft to remove

antigenic elements. Then soak the graft in platelet-rich plasma solution previously prepared from the 60 mL of blood withdrawn prior to exposure.

Moving back to the chondral defect, place the sizer over the previously outlined recipient site while ensuring the sizer is flush on all sides and covers the defect. Place a central 4-mm guide pin through the sizer. Remove the sizer and place the scoring device over the drill pin to create a cut in the cartilage approximately 2 to 3 mm deep. Place the appropriately sized reamer and advance it slowly to a depth of 5 to 6 mm (Fig 7A). The recipient site may be microfractured with a k-wire to prepare for graft implantation (Fig 7B). Place the graft into the recipient site by hand (Fig 8). Gently impact the graft into place using a tamp and mallet, if necessary.

Lateral Femoral Condyle BioUni OATS. Z-retractors are placed medially and laterally to maximize exposure. Next, the BioUni sizers (Arthrex) are used to identify the most appropriate coverage of the lesion. While holding the selected sizer in position, an indelible marker is used to outline the sizer (Fig 9). Care should be taken to ensure adequate native osteochondral shoulders both medially and laterally for secure graft fixation. The selected sizer used to establish the

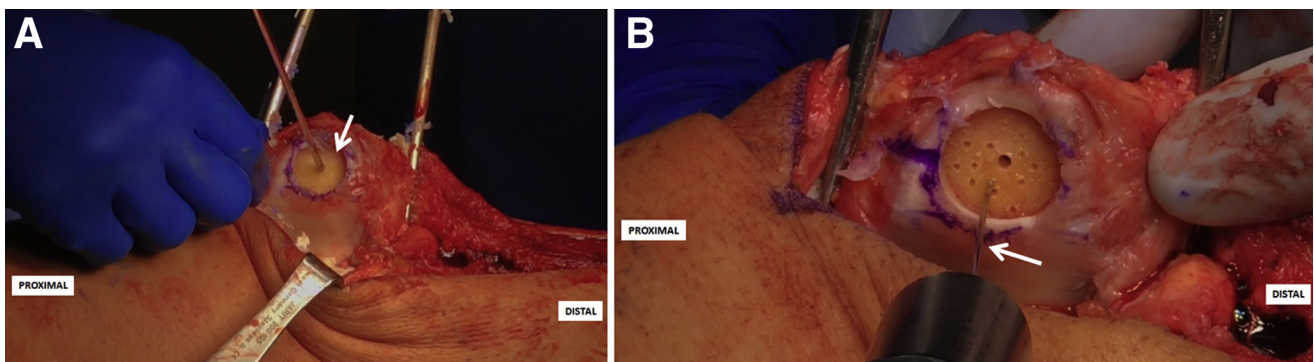


Fig 7. The complete resection of the patellar osteochondral lesion (white arrow) in this left knee is demonstrated. Note the full exposure of the subchondral bone with maintenance of the cartilage margins (A). Following this, a microfracture technique is performed in the subchondral bone to maximize healing potential (B).

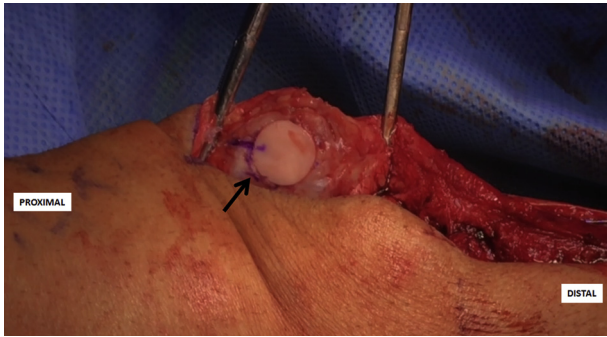


Fig 8. Final image of the patella allograft once it has been placed in the defect in this left knee. Note the placement of the graft (black arrow) with even leveling between the allograft and native, surrounding patella.

recipient defect site is then placed over the allograft condyle until the appropriate donor site has been identified. The sizer should be outlined with indelible ink while denoting the superior and inferior aspects of the donor graft. The condyle is mounted in the workstation with 2.8-mm guide pins.

Place the oblong cutter inserter into the oblong cutter and position it over the allograft until it aligns with the previously demarcated harvest site (Fig 10A). Drill a 2.8-mm guide pin through the guide pin hole and advance it fully through the allograft. Screw the impactor handle onto the oblong cutter. Use a mallet to drive the oblong cutter into the graft until the third laser line is flush with the surrounding cartilage. Insert the distractor tool into the driver handle and insert it into the oblong cutter. Remove the 2.8-mm pin and advance the distractor to remove the oblong cutter.

Assemble the saw depth guide over the sagittal saw guide and screw on the impactor handle. Place the assembly into the previously made cut and impact into place. Using a sagittal saw, advance the blade through the sagittal saw guide until it advances through the condyle to create the base of the graft. Remove the impactor handle

and sagittal saw attachments. The donor graft will be contained within the sagittal saw depth guide. Insert the distraction tool to slowly extract the allograft implant. Ensure the marks denoting the superior and inferior aspects of the graft are visible and remark if necessary. Insert the implant into the appropriately sized donor trial to confirm sizing (Fig 10B). Thereafter, pulse lavage the graft to remove antigenic elements.

Moving back to the chondral defect, place the sizer over the previously outlined recipient site while ensuring the sizer is flush on all sides and covers the defect. Place 2 4-mm drill pins into the drill holes. Remove the sizer while leaving the drill pins in place. Place the scoring device over the drill pins and impact it to create a cut in the cartilage approximately 2 to 3 mm deep. Place the appropriately sized drill depth guide over the bottom drill pin and advance it down to the cartilage. Place the appropriately sized reamer over the top drill pin and advance the reamer until it stops on the depth guide. Create a second circle by repeating this process with the opposite drill pins.

Advance the box cutter over the drill pins until the tabs on the box cutter are abutting the cancellous bone and will no longer advance. Remove the drill pins and remove any remaining cartilage and bone with a combination of curettes and rongeurs (Fig 11). Use a dilator to dilate the recipient site and confirm the fit. If the trial is proud, attach the reamer to a Jacob's chuck and ream by hand, taking care not to resect too much cancellous bone. If the trial is recessed, autologous bone chips or demineralized bone matrix can be used to make minor adjustments. The recipient site may be microfractured with a 2.0-mm guide pin to prepare for graft implantation.

Place the graft into the recipient site by hand (Fig 12A). Gently impact the graft into place using a tamp and mallet. The use of 2 bioabsorbable screws for greater fixation is possible, if necessary. In this case, 2 k-wires were initially placed to mark the location of the

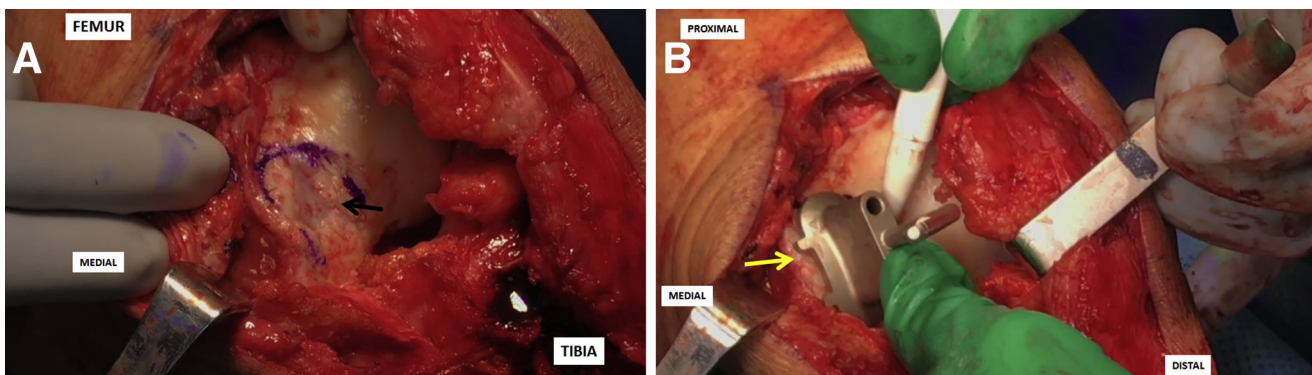


Fig 9. Once the patella allograft has been formed and inserted, attention is turned to the osteochondral lesion in the lateral femoral condyle of this left knee. The lesion is exposed (black arrow) and marked using a surgical pen (A). Following this, the correct sizer (yellow arrow) is placed over the lesion to ensure that the entirety of the lesion is addressed (B).

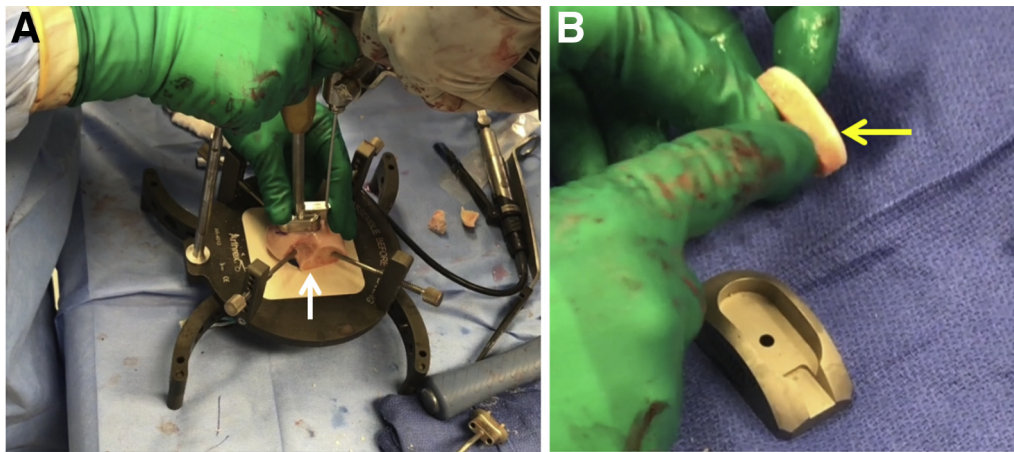


Fig 10. The condyle allograft is placed in the allograft workstation (white arrow, A) and carefully secured to perform necessary cuts. Once the femoral condyle allograft (yellow arrow, B) to be used in this left knee is formed, its size and shape are verified and confirmed as correct. Any necessary adjustments are made at this time to ensure that the graft will properly fit into the created defect.

bioabsorbable screws to be inserted. Afterward, the holes for each of the screws were formed. Then for final fixation of the allograft the bioabsorbable screws were screwed into position through the allograft and into the native bone of the lateral femoral condyle (Fig 12B). Finally, thoroughly irrigate the wound and then complete a standard, layered closure.

Discussion

This Technical Note details our technique using multicompartamental osteochondral allograft transplantation and concurrent high tibial osteotomy for the treatment of large patellar and femoral condyle articular cartilage defects in the context of knee malalignment. When both of these risk factors, articular cartilage defect and knee malalignment, for osteoarthritis progression are present, they should be addressed concomitantly. However, the literature evaluating the outcomes of a dual procedure is sparse.

Alone, osteochondral allograft transfers have shown significant promise. Clinical studies have demonstrated OATS to produce a subjective improvement in pain in 74% to 85% of patients at midterm follow-up.^{7,8} Gross et al.^{7,9} reported an osteochondral allograft survival rate of 95% at 5 years, 85% at 10 years, and 74% at 15 years, while Levy et al.⁸ reported a survivorship of 82% at 10 years with improved pain and function. Additionally, LaPrade et al.¹⁰ followed 23 patients for a mean of 3 years and demonstrated improvements in Cincinnati Knee Scores and International Knee Documentation Committee scores from 49.2 to 62 ($P < .02$) and 52 to 69 ($P < .03$), respectively, after transplantation of grafts that were refrigerated preoperatively for 15 to 28 days. Moreover, McCulloch et al.¹¹ also reported significant improvement in all subjective outcome scores and found an incorporation rate of 88% (22 patients), at 2-year follow-up. Although OATS

procedures offer many advantages, the literature on OATS when performed alongside other procedures, including high tibial osteotomy, is limited.

High tibial osteotomy is intended to transfer the mechanical axis to the midline of the knee, to reduce the unicompartmental load and subsequently delay osteoarthritis. This is particularly important for younger, active patients who wish to avoid arthroplasty. Medial open wedge osteotomy has recently become popularized over lateral wedge osteotomy, displaying superior outcomes¹² with additional advantages of ability to correct knee alignment in 2 planes (coronal and sagittal), no need for fibular osteotomy, little risk of peroneal nerve injury, no limb shortening, use of a single cut with no need to detach musculature, no bone loss, easier conversion to arthroplasty, and ability to adjust the amount of correction during surgery. Nevertheless, disadvantages are associated with

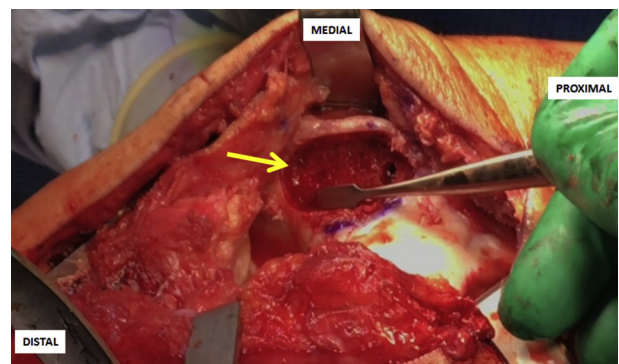


Fig 11. Final image of the left lateral femoral condyle osteochondral lesion resected and prepared prior to insertion of the allograft. To ensure optimal fixation of the femoral condyle allograft, curettes and rongeurs are used to remove any remaining bone or cartilage (yellow arrow).

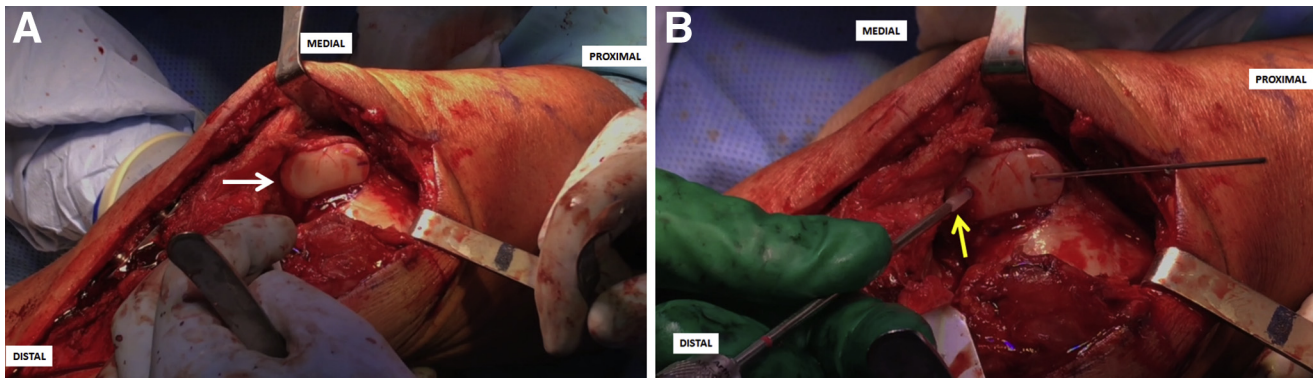


Fig 12. The lateral femoral condyle allograft (white arrow) is placed in the created defect in this left knee (A). Care must be taken to ensure that the graft demonstrates equal leveling with the native femoral condyle. Once leveling is confirmed, 2 bioabsorbable screws (yellow arrow) are placed to secure the graft in the desired position (B).

this procedure and include the need for bone graft as well as the risk of delayed union or nonunion. Studies on medial open wedge high tibial osteotomy showed a 10-year delay in arthroplasty in 63% in 73 patients¹³ and 85% in 203 patients.¹⁴

Although clinical studies have yielded promising results when these 2 procedures are performed separately, additional long-term follow-up studies of osteochondral allograft transfer alongside high tibial osteotomy are needed. We recommend our described technique for the treatment of an osteochondral defect(s) alongside our high tibial osteotomy technique when malalignment is present but encourage further studies focused on the assessment and validation of the described technique.

References

1. Rotterud JH, Risberg MA, Engebretsen L, Aroen A. Patients with focal full-thickness cartilage lesions benefit less from ACL reconstruction at 2-5 years follow-up. *Knee Surg Sports Traumatol Arthrosc* 2012;20:1533-1539.
2. Rotterud JH, Sivertsen EA, Forssblad M, Engebretsen L, Aroen A. Effect of meniscal and focal cartilage lesions on patient-reported outcome after anterior cruciate ligament reconstruction: a nationwide cohort study from Norway and Sweden of 8476 patients with 2-year follow-up. *Am J Sports Med* 2013;41:535-543.
3. Spahn G, Hofmann GO. [Focal cartilage defects within the medial knee compartment. predictors for osteoarthritis progression]. *Z Orthop Unfall* 2014;152:480-488.
4. Mankin HJ. The response of articular cartilage to mechanical injury. *J Bone Joint Surg Am* 1982;64:460-466.
5. Filardo G, Kon E, Perdisa F, Balboni F, Marcacci M. Autologous osteochondral transplantation for the treatment of knee lesions: results and limitations at two years' follow-up. *Int Orthop* 2014;38:1905-1912.
6. Mandelbaum B, Browne JE, Fu F, et al. Treatment outcomes of autologous chondrocyte implantation for full-thickness articular cartilage defects of the trochlea. *Am J Sports Med* 2007;35:915-921.
7. Gross AE, Kim W, Las Heras F, Backstein D, Safir O, Pritzker KP. Fresh osteochondral allografts for post-traumatic knee defects: long-term followup. *Clin Orthop Rel Res* 2008;466:1863-1870.
8. Levy YD, Gortz S, Pulido PA, McCauley JC, Bugbee WD. Do fresh osteochondral allografts successfully treat femoral condyle lesions? *Clin Orthop Rel Res* 2013;471:231-237.
9. Gross AE, Shasha N, Aubin P. Long-term followup of the use of fresh osteochondral allografts for posttraumatic knee defects. *Clin Orthop Rel Res* 2005:79-87.
10. LaPrade RF, Botker J, Herzog M, Agel J. Refrigerated osteoarticular allografts to treat articular cartilage defects of the femoral condyles. A prospective outcomes study. *J Bone Joint Surg Am* 2009;91:805-811.
11. McCulloch PC, Kang RW, Sobhy MH, Hayden JK, Cole BJ. Prospective evaluation of prolonged fresh osteochondral allograft transplantation of the femoral condyle: minimum 2-year follow-up. *Am J Sports Med* 2007;35:411-420.
12. Brouwer RW, Raaij van TM, Bierma-Zeinstra SM, Verhagen AP, Jakma TS, Verhaar JA. Osteotomy for treating knee osteoarthritis. *Cochrane Database Syst Rev* 2007:CD004019.
13. Weale AE, Lee AS, MacEachern AG. High tibial osteotomy using a dynamic axial external fixator. *Clin Orthop Rel Res* 2001:154-167.
14. Hernigou P, Ma W. Open wedge tibial osteotomy with acrylic bone cement as bone substitute. *Knee* 2001;8:103-110.