




CASE REPORT

Case Report: Partial nephrectomy in primary renal sarcoma presenting as Wunderlich syndrome; a rare tumour with rare presentation managed atypically [version 1; peer review: 1 approved, 2 approved with reservations]

Ramanitharan Manikandan¹, Ketan Mehra ¹, Lalgudi Narayanan Dorairajan¹, Rajesh Nachiappa Ganesh², Sreerag K. Sreenivasan¹, Rajeev Kumar¹

¹Department of Urology, Jawaharlal Institute of Postgraduate Medical Education and Research (JIPMER), Pondicherry, 605006, India

²Department of Pathology, Jawaharlal Institute of Postgraduate Medical Education and Research (JIPMER), Pondicherry, 605006, India

V1 First published: 10 Apr 2019, 8:423 (<https://doi.org/10.12688/f1000research.18698.1>)
 Latest published: 10 Apr 2019, 8:423 (<https://doi.org/10.12688/f1000research.18698.1>)

Abstract

Spontaneous retroperitoneal haemorrhage also called Wunderlich Syndrome (WS) may be caused by various aetiologies. One of the most common causes is renal tumour. Renal sarcoma is a rare cause of WS, and renal sarcoma in itself is a rare entity. In the era of nephron-sparing surgery, optimum management of primary renal sarcoma remains a dilemma as there are limited number of cases available in the literature. Nevertheless, radical nephrectomy remains the recommended treatment, keeping in mind the aggressiveness of the tumour. We report a case of primary undifferentiated renal sarcoma, which presented as WS, and which was managed by partial nephrectomy.

Keywords

Renal Sarcoma, Wunderlich syndrome, Partial nephrectomy, Undifferentiated sarcoma.

Open Peer Review

Reviewer Status

	Invited Reviewers		
	1	2	3
version 1 published 10 Apr 2019	 report	 report	 report

- Nikhil Khattar**, Medanta, The Medicity, Gurugram, India
- Bipinchandra Pal**, Institute of Kidney Diseases and Research Centre and Institute of Transplantation Sciences, Ahmedabad, India
- Hammad Ather**, Aga Khan University, Karachi, Pakistan

Any reports and responses or comments on the article can be found at the end of the article.

Corresponding author: Ketan Mehra (drketanmehra@gmail.com)

Author roles: **Manikandan R:** Conceptualization, Methodology, Project Administration, Supervision, Writing – Review & Editing; **Mehra K:** Conceptualization, Methodology, Writing – Original Draft Preparation; **Dorairajan LN:** Conceptualization, Supervision, Writing – Review & Editing; **Nachiappa Ganesh R:** Investigation, Supervision; **Sreenivasan SK:** Supervision; **Kumar R:** Project Administration, Visualization, Writing – Original Draft Preparation

Competing interests: No competing interests were disclosed.

Grant information: The author(s) declared that no grants were involved in supporting this work.

Copyright: © 2019 Manikandan R *et al.* This is an open access article distributed under the terms of the [Creative Commons Attribution Licence](#), which permits unrestricted use, distribution, and reproduction in any medium, provided the original work is properly cited.

How to cite this article: Manikandan R, Mehra K, Dorairajan LN *et al.* **Case Report: Partial nephrectomy in primary renal sarcoma presenting as Wunderlich syndrome; a rare tumour with rare presentation managed atypically [version 1; peer review: 1 approved, 2 approved with reservations]** F1000Research 2019, 8:423 (<https://doi.org/10.12688/f1000research.18698.1>)

First published: 10 Apr 2019, 8:423 (<https://doi.org/10.12688/f1000research.18698.1>)

Introduction

Wunderlich syndrome (WS) is a life-threatening medical emergency defined as spontaneous non-traumatic bleeding confined to the perinephric region¹. It is often characterised by Lenk's triad consisting of acute flank pain, flank mass and hypovolemic shock². Various aetiologies, including benign and malignant conditions attributable to renal and extra-renal origin, have been reported to cause WS in the literature³. We report a rare presentation of WS in a young woman secondary to an underlying renal sarcoma, which was managed by robotic assisted laparoscopic partial nephrectomy. Furthermore, this report aims to address the difficulties in preoperative diagnosis and concerns of partial nephrectomy in the setting of renal sarcoma.

Case report

A 21-year-old woman presented to the emergency department with a history of severe left flank pain and giddiness. She did not report any history of trauma, but had a past history of hypertension. The patient's pulse rate was 96/min (reference range: 60–80/minute), blood pressure was 90/60 mmHg (reference range: 120/80 mmHg), haemoglobin was 5 gm% (reference

range: 12–15 gm%), and serum creatinine was 1.8 mg/dL (reference range: 0.5–1.1 mg/dL). Ultrasonogram revealed a large left perirenal hematoma of size 8x6 cm. Non contrast CT scan suggested an 8 cm lesion in the left kidney without any other information about the aetiology. The patient received blood transfusions and intravenous fluids.

As the patient was stable, she was managed conservatively for the resolution of the hematoma to facilitate better surgical planning. After two weeks, the patient underwent MRI in which the hematoma had decreased in size to 5 cm, but the underlying cause could not be ascertained (Figure 1). Keeping in mind that a renal tumour, either benign or malignant, could be the cause of haemorrhage, the patient underwent robotic assisted laparoscopic left partial nephrectomy with guidance of intra-operative ultrasonography to delineate the lesion margins (Figure 2A). The warm ischemia time was 25 min with a blood loss of about 200 ml. The patient was discharged on day three with normal serum creatinine.

Macroscopically, the tumour was 5 cm in largest dimension, fleshy with yellow-brown appearance possibly due to haemorrhage

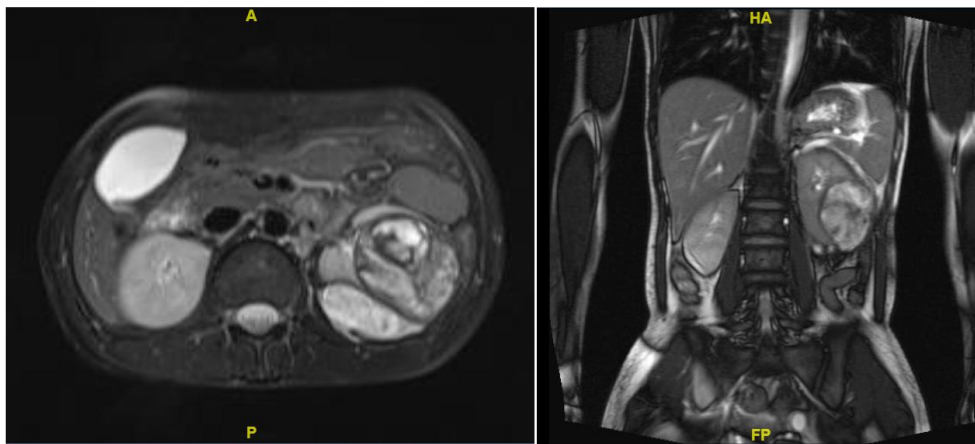


Figure 1. MRI abdomen coronal and transverse images depicting renal lesion in middle and lower pole of the left kidney.

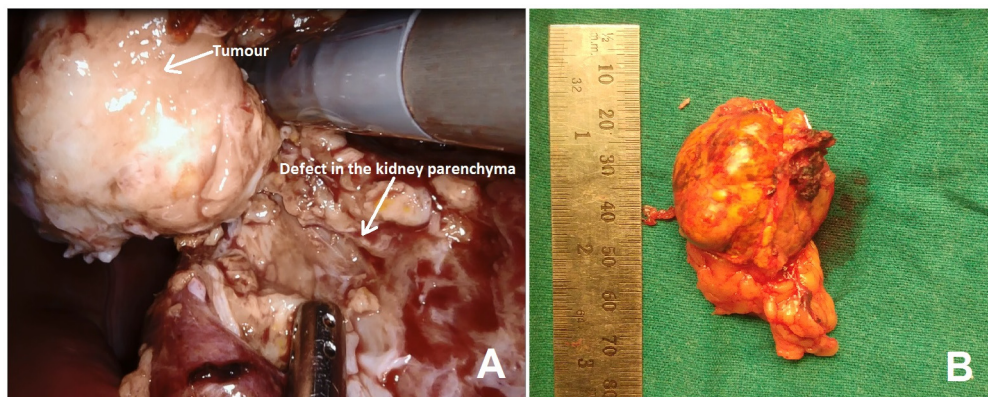


Figure 2. Robotic assisted laparoscopic left partial nephrectomy with guidance of intra-operative ultrasonography. (A) Intraoperative image during partial nephrectomy of the left kidney; (B) gross morphology of the resected tumour.

(Figure 2B). Microscopically, the tumour cells appeared small, round to oval shaped, with scant cytoplasm vesicular chromatin and tiny nucleoli with extensive haemorrhagic areas with hemosiderin laden macrophages. The tumour cells were about 5mm away from the resected margins. The tumour cells were positive for vimentin, BCL2 and FL1, and negative for Pan CK, CK7, CD10, CD31, S100, HMB45, SMA, ER, PR and WT-1, suggestive of “primary undifferentiated renal sarcoma” with hematoma (Figure 3 and Figure 4).

Since there are no definite guidelines regarding the role of partial nephrectomy in the background of renal sarcoma, we offered completion radical nephrectomy taking into account the young age of the patient. But the patient refused radical nephrectomy. Observation with regular follow-up was chosen by the patient as the best course of action. At the last follow-up of 12 months, there is no evidence of recurrence on contrast enhanced computerised tomography scan (Figure 5).

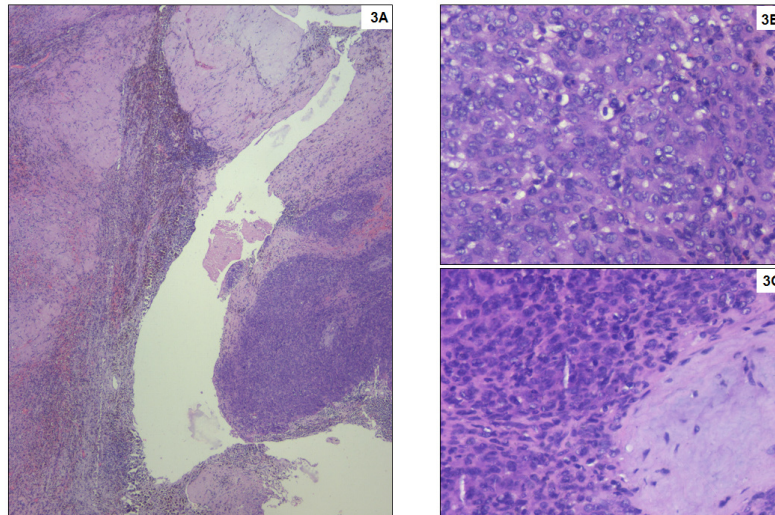


Figure 3. Haematoxylin and eosin staining of the tissue. (A) Small round blue tumour cells arranged in sheets and nests infiltrating the adjacent stroma. Numerous hemosiderin laden macrophages are seen at the interface. No viable renal parenchyma is preserved, which is entirely replaced by dense fibrosis. Haematoxylin and eosin stain, x40; (B) Tumour cell morphology at higher magnification with high nuclear cytoplasmic ratio, inconspicuous cytoplasm and occasional mitoses. Haematoxylin and eosin stain, x400; (C) Tumour with adjacent bluish immature myxoid connective tissue. Haematoxylin and eosin stain, x400.

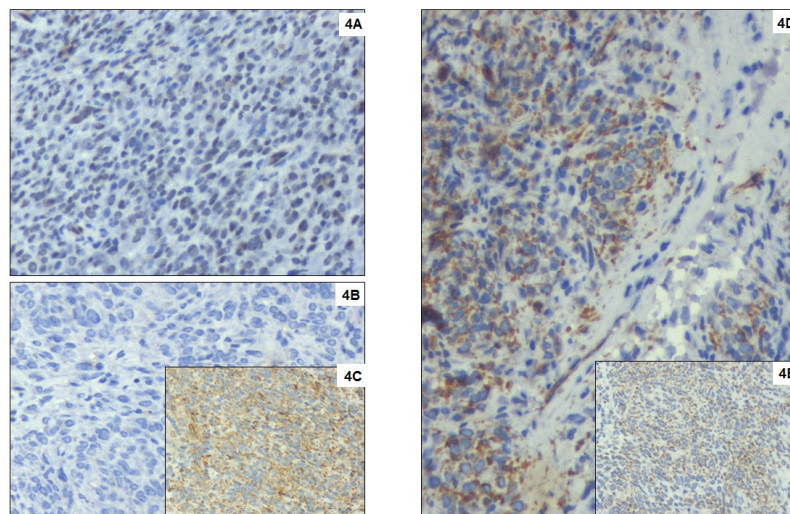


Figure 4. Immunohistochemical markers. (A) Tumour cells with strong diffuse nuclear expression for FLI1. Immunohistochemistry with DAB counterstain, DAKO monoclonal antibody, x400; (B) Negative staining of tumour cells with CD99. Immunohistochemistry with DAB counterstain, DAKO monoclonal antibody, x400; (C) Strong diffuse staining of tumour cells for Vimentin. Immunohistochemistry with DAB counterstain, DAKO monoclonal antibody, x400; (D) Strong cytoplasmic and Golgi expression of WT1 and no nuclear expression in tumour cells. Immunohistochemistry with DAB counterstain, DAKO monoclonal antibody, x400; (E) Tumour cells showing strong cytoplasmic expression for Bcl2. Immunohistochemistry with DAB counterstain, DAKO monoclonal antibody, x400.

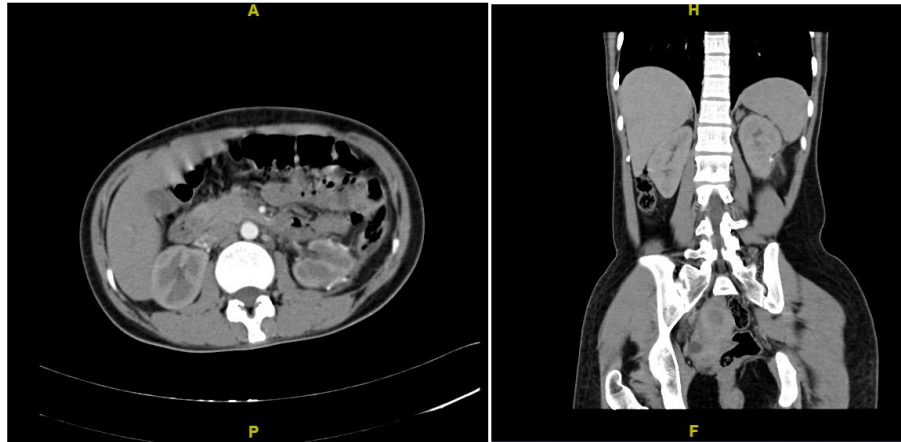


Figure 5. Follow-up contrast enhanced CT scan at 12 months showing no evidence of recurrence.

Discussion

In 1856, Wunderlich first described the condition of spontaneous renal bleeding with dissection of blood into the sub capsular and/or perinephric spaces¹. In a series of 165 patients with WS, Zhang *et al.* observed that renal neoplasm was the most common cause, with angiomyolipoma being the most common neoplasm⁴. There are only scant reports of renal sarcomas presenting with primarily as WS^{5,6}.

Sarcomas of the kidney constitute a heterogeneous group of rare neoplasms with aggressive clinical course and account for < 1% of renal cancers¹. Sarcomas usually present at a young age with a large tumour size. Renal sarcomas present with similar clinical and radiologic features as renal cell carcinoma and are rarely suspected pre-operatively⁷. The 5-year overall survival rate for localised renal sarcoma is 46% in comparison to 8% for metastatic disease⁸. As this tumour is rare, appropriate guidelines for the management and follow-up have not yet been established.

Moreira *et al.* performed a study with 489 patients of primary renal sarcoma. Primary treatment modality data was available for 367 patients; 210 (57%) underwent surgery, 51 (14%) underwent only radiation, 46 (13%) had both radiation and surgery, and 60 (16%) received neither radiation or surgery. The authors reported that surgery as the modality of treatment had a lower cancer specific mortality rate as compared to other measures. Nephron Sparing Surgery (NSS) or radical nephrectomy was not segregated in their study⁸. The role of NSS in renal sarcomas is controversial. Wang *et al.* reported NSS in a patient with sarcoma with a disease-free interval of 42 months⁵. Cocuzza *et al.* suggested that renal sarcomas with a diameter of 5 cm may be considered for NSS⁹. Satoh *et al.* reported a case of cystic renal leiomyosarcoma, which was managed by partial nephrectomy with a normal follow up of 44 months¹⁰. As long as the surgical margins are negative after NSS, it would be unnecessary to perform salvage radical nephrectomy in

patients presumed to be renal cell carcinoma pre-operatively, but ultimately turns out to be a sarcoma in the final histology.

Our case presented as spontaneous renal haemorrhage at a young age. All three imaging modalities (ultrasonography, CT and MRI) were unable to delineate the cause of haemorrhage. In view of renal tumours being the most common cause, partial nephrectomy, through a minimal invasive approach, was accomplished. The final histopathology suggested it was a primary renal undifferentiated sarcoma. We were able to manage a case of renal sarcoma with nephron sparing surgery without disease recurrence on follow up. But due to lack of substantial literature, intense follow-up will be needed.

Conclusion

Renal sarcoma presenting as Wunderlich syndrome is a rare phenomenon, which can mask its preoperative diagnosis. Due to scarcity of cases, optimum management of renal sarcoma is still debatable. Keeping in mind lack of evidence and aggressive nature of primary renal sarcoma, radical nephrectomy seems to be the optimum treatment. In the era of nephron sparing surgery, partial nephrectomy can be offered to patients of primary renal sarcoma with negative surgical margins.

Consent

Written informed consent for publication of their clinical details and images was obtained from the patient.

Data availability

All data underlying the results are available as part of the article and no additional source data are required.

Grant information

The author(s) declared that no grants were involved in supporting this work.

References

1. Albi G, Del Campo L, Tagarro D: **Wunderlich's syndrome: causes, diagnosis and radiological management.** *Clin Radiol.* 2002; **57**(9): 840–5.
[PubMed Abstract](#) | [Publisher Full Text](#)
2. Baishya RK, Dhawan DR, Sabnis RB, *et al.*: **Spontaneous subcapsular renal hematoma: A case report and review of literature.** *Urol Ann.* 2011; **3**(1): 44–6.
[PubMed Abstract](#) | [Publisher Full Text](#) | [Free Full Text](#)
3. Molina Escudero R, Castillo OA: **Spontaneous retroperitoneal haemorrhage of renal origin (Wunderlich syndrome): analysis of 8 cases.** *Arch Esp Urol.* 2013; **66**(10): 925–9.
[PubMed Abstract](#)
4. Zhang JQ, Fielding JR, Zou KH: **Etiology of spontaneous perirenal hemorrhage: a meta-analysis.** *J Urol.* 2002; **167**(4): 1593–6.
[PubMed Abstract](#) | [Publisher Full Text](#)
5. Wang X, Xu R, Yan L, *et al.*: **Adult renal sarcoma: Clinical features and survival in a series of patients treated at a high-volume institution.** *Urology.* 2011; **77**(4): 836–41.
[PubMed Abstract](#) | [Publisher Full Text](#)
6. Kim JW, Kim JY, Ahn ST, *et al.*: **Spontaneous perirenal hemorrhage (Wunderlich syndrome): An analysis of 28 cases.** *Am J Emerg Med.* 2019; **37**(1): 45–7.
[PubMed Abstract](#) | [Publisher Full Text](#)
7. Wang Z, Zhong Z, Zhu L, *et al.*: **Primary synovial sarcoma of the kidney: A case report.** *Oncol Lett.* 2015; **10**(6): 3542–4.
[PubMed Abstract](#) | [Publisher Full Text](#) | [Free Full Text](#)
8. Moreira DM, Gershman B, Thompson RH, *et al.*: **Clinicopathologic characteristics and survival for adult renal sarcoma: A population-based study.** *Urol Oncol.* 2015; **33**(12): 505.e15–20.
[PubMed Abstract](#) | [Publisher Full Text](#)
9. Cocuzza M, Arap S, Lucon AM, *et al.*: **Renal leiomyosarcoma treated with partial nephrectomy.** *Clinics (Sao Paulo).* 2005; **60**(4): 345–6.
[PubMed Abstract](#) | [Publisher Full Text](#)
10. Satoh Y, Kakinoki H, Tokuda Y, *et al.*: **Cystic renal leiomyosarcoma treated with partial nephrectomy.** *UroToday Int J.* 2010; **3**(4).
[Publisher Full Text](#)

Open Peer Review

Current Peer Review Status:



Version 1

Reviewer Report 22 July 2019

<https://doi.org/10.5256/f1000research.20474.r50127>

© 2019 Ather H. This is an open access peer review report distributed under the terms of the [Creative Commons Attribution Licence](#), which permits unrestricted use, distribution, and reproduction in any medium, provided the original work is properly cited.



Hammad Ather

Section of Urology, Aga Khan University, Karachi, Pakistan

Authors have described a case of young woman presenting with spontaneous rupture of a renal sarcoma managed by RA partial nephrectomy. The management was unconventional as the standard approach to such a case is to manage conservatively as they did in the first few days, waiting for the resolution of hematoma and stabilization of the kidney function. Once the serum creatinine is normal she can be imaged either with contrast enhanced CT or MRU or contrast enhanced MRI. If the diagnosis is still uncertain a percutaneous biopsy and followed by definitive management. The definitive management, as the authors also pointed out is radical nephrectomy.

The differential diagnoses included anaplastic sarcoma of the kidney (ASK), anaplastic Wilms tumor, mesenchymal chondrosarcoma, sarcomatoid renal cell carcinoma, clear cell sarcoma of the kidney, rhabdoid tumor of the kidney, congenital mesoblastic nephroma, and synovial sarcoma. The management is highly dependent of the histology(Chen and Liao. *Ci Ji Yi Xue Za Zhi*. 2019 Apr-Jun;31(2):129-132¹)

My suggestions to the authors are:

1. Justify the indication of RA partial prior to establishing a diagnosis in a stable patient.
2. Discuss the histopathological aspects of the tumor and how to differentiate various types of sarcoma.
3. How the authors intend to follow up patient considering her young age. Is there a role of re biopsy of the tumor bed, for how long should the CT contrast or MRI scan be done. Are there any recommendations for just doing ultrasound if the CT or MRI are normal after first year.

References

1. Chen C, Liao K: Anaplastic sarcoma of the kidney: Case report and literature review. *Tzu Chi Medical Journal*. 2019; **31** (2). [Publisher Full Text](#)

Is the background of the case's history and progression described in sufficient detail?

Yes

Are enough details provided of any physical examination and diagnostic tests, treatment given and outcomes?

Yes

Is sufficient discussion included of the importance of the findings and their relevance to future understanding of disease processes, diagnosis or treatment?

Partly

Is the case presented with sufficient detail to be useful for other practitioners?

Partly

Competing Interests: No competing interests were disclosed.

Reviewer Expertise: Urological oncologist (Bladder, prostate and kidney cancer), Endourology

I confirm that I have read this submission and believe that I have an appropriate level of expertise to confirm that it is of an acceptable scientific standard, however I have significant reservations, as outlined above.

Reviewer Report 08 July 2019

<https://doi.org/10.5256/f1000research.20474.r46982>

© 2019 Pal B. This is an open access peer review report distributed under the terms of the [Creative Commons Attribution Licence](#), which permits unrestricted use, distribution, and reproduction in any medium, provided the original work is properly cited.



Bipinchandra Pal

Department of Urology and Transplantation Surgery, Institute of Kidney Diseases and Research Centre and Institute of Transplantation Sciences, Ahmedabad, India

- Little more clarification is needed in the radiological findings.
- How was a plan decided for partial in presence of haematoma?
- Was a serum creatinine repeated before taking the case for surgery? Initially it was 1.8 mg% and after 3 days of surgery it was normal. Better to write the value.
- What is the follow up schedule?

Is the background of the case's history and progression described in sufficient detail?

Yes

Are enough details provided of any physical examination and diagnostic tests, treatment given and outcomes?

Yes

Is sufficient discussion included of the importance of the findings and their relevance to future understanding of disease processes, diagnosis or treatment?

Yes

Is the case presented with sufficient detail to be useful for other practitioners?

Yes

Competing Interests: No competing interests were disclosed.

Reviewer Expertise: Uro-Oncology

I confirm that I have read this submission and believe that I have an appropriate level of expertise to confirm that it is of an acceptable scientific standard.

Reviewer Report 30 April 2019

<https://doi.org/10.5256/f1000research.20474.r46984>

© 2019 Khattar N. This is an open access peer review report distributed under the terms of the [Creative Commons Attribution Licence](#), which permits unrestricted use, distribution, and reproduction in any medium, provided the original work is properly cited.



Nikhil Khattar

Department of Urology, Medanta, The Medicity, Gurugram, Haryana, India

Well written case report.

It will be good if the authors can provide the NCCT picture at initial presentation with hematoma alongside the already provided MRI images.

The authors should detail the follow up plan with duration considering the patients young age and propensity of renal sarcomas to recur even after 13-15 years¹.

Are there any preoperative hints to suspect a sarcoma on imaging or with biomarkers published in the literature? A word about the same should find a place in the manuscript.

References

1. Alameddine M, Zheng I, Yusufali A, Mackrides N, Ciancio G: Adult renal sarcoma: A rare case of recurrence 13 years after initial resection. *Clinical Case Reports*. 2019; 7 (1): 47-50 [Publisher Full Text](#)

Is the background of the case's history and progression described in sufficient detail?

Yes

Are enough details provided of any physical examination and diagnostic tests, treatment given and outcomes?

Yes

Is sufficient discussion included of the importance of the findings and their relevance to future understanding of disease processes, diagnosis or treatment?

Partly

Is the case presented with sufficient detail to be useful for other practitioners?

Yes

Competing Interests: No competing interests were disclosed.

Reviewer Expertise: Reconstructive Urology, urinary Incontinence, stricture urethra, female and functional urology

I confirm that I have read this submission and believe that I have an appropriate level of expertise to confirm that it is of an acceptable scientific standard, however I have significant reservations, as outlined above.

The benefits of publishing with F1000Research:

- Your article is published within days, with no editorial bias
- You can publish traditional articles, null/negative results, case reports, data notes and more
- The peer review process is transparent and collaborative
- Your article is indexed in PubMed after passing peer review
- Dedicated customer support at every stage

For pre-submission enquiries, contact research@f1000.com

F1000Research