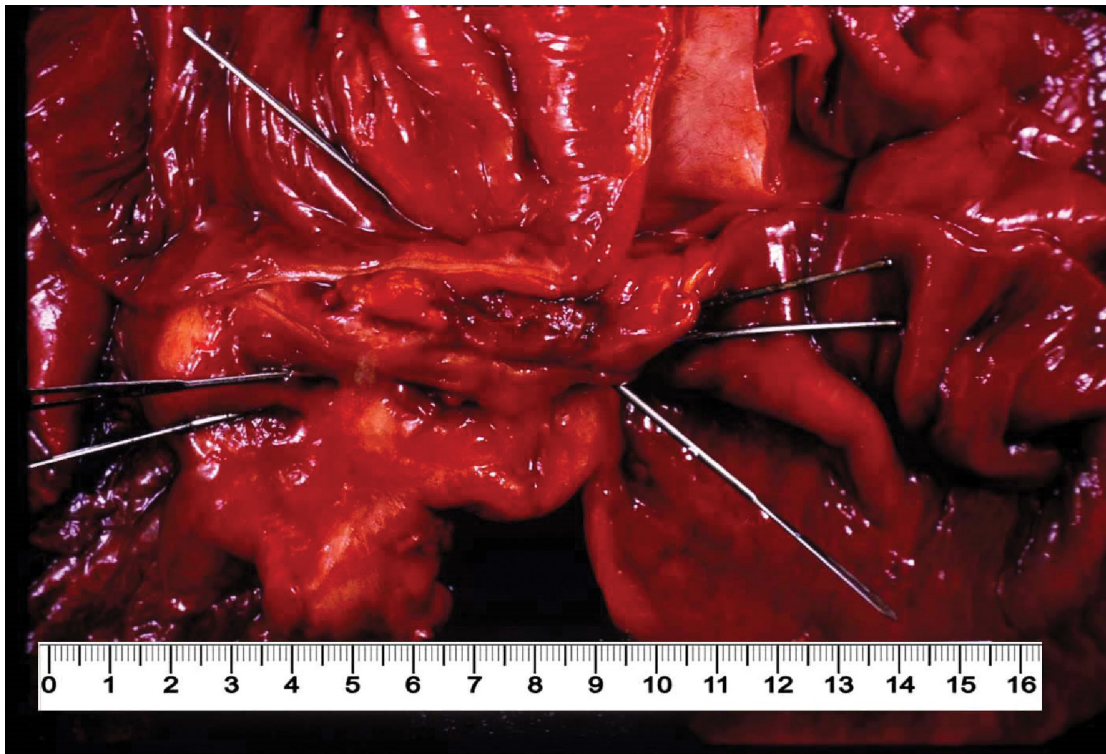


## Crohn disease

Stephen A Geller<sup>ab</sup>, Fernando P F de Campos<sup>c</sup>

Geller SA, Campos FPF. Crohn disease. Autopsy Case Rep [Internet]. 2015; 5(2):5-8. <http://dx.doi.org/10.4322/acr.2015.001>



Dr. Stephen A Geller personal archive

Aretaeus of Cappadocia (1<sup>st</sup> century CE) described a young man with chronic and recurring abdominal distress possibly representing the first recorded instance of Crohn disease (CD).<sup>1-3</sup> More evidence that this disease was extant for many years comes from the description of the 10<sup>th</sup> century English king, Alfred “the great,” who suffered for many years from what was a typical enteritis but also had anal fistula and/or abscess.<sup>4</sup> In medieval times, Antonio Benivieni (1443-1502) described the multi-ulcerated small intestine in a

patient dying after a prolonged dysentery-like course. Louis XIII, King of France (1601-1643) died at the age of 42 after decades of abdominal pain, fever, bloody diarrhea and rectal/perianal abscesses.<sup>4</sup> However, it was in 1761 that Giovanni Battista Morgagni (1682-1771), a towering figure in the history of medicine, described a 20-year-old man with typical regional ileitis, who died. Morgagni autopsied him and described typical CD lesions of both the small and large intestine, including erosions, ulcerations and perforations with

<sup>a</sup> Department of Pathology and Laboratory Medicine – David Geffen School of Medicine – University of California, Los Angeles/CA – USA.

<sup>b</sup> Department of Pathology and Laboratory Medicine – Weill Cornell Medical College, New York/NY – USA.

<sup>c</sup> Internal Medicine Division – Hospital Universitário – Universidade de São Paulo, São Paulo/SP – Brazil.

lymphadenopathy. In the following 150 years, cases likely to be Crohn disease were reported by Mathew Baillie, Colles, Cruveilhier, Fenwick, Fröhlich and many others. Notable was the description of “singular case of stricture and thickening of the ileum” by Coombe and Saunders in 1813 and “inflammatory fibrous colon tumour” by Rudolph Virchow.<sup>5,6</sup> None of these, however, described completely the unique pathological and clinical entity that is Crohn disease, although the Scottish surgeon Thomas Kennedy Dalziel (1861-1924), in his report of “chronic interstitial enteritis,” came close.

It remained to the group of clinician-investigators at The Mount Sinai Hospital, New York, Burrill B. Crohn, Gordon Oppenheimer and Leon Ginzburg, to publish the classic paper, entitled “Regional ileitis: a pathological and clinical entity” in 1932<sup>7-9</sup>, identifying 14 patients with symptoms and surgical intestinal abnormalities, which they recognized as a singular entity.

Crohn disease, as this entity was later coined, is a chronic inflammatory disease of unknown etiology, which potentially involves the gastrointestinal tract from the mouth to the perianal area.

CD may affect people in early childhood until late adulthood, but younger individuals, including teenagers and young adults, are more often affected. Afflicted patients have a significant decrease in the quality of life because of the marked morbidity. This disease also has a significant economic impact since most patients are affected in their productive years. The incidence seems to be increasing worldwide, even in low-incidence regions, probably because of better diagnosis. Environmental factors as well as changes in life style may also have an impact. The highest incidence rate has been reported in Canada (248/100,000 inhabitants), while in Asia the rate is less than 6.3/100,000 inhabitants.

Although the etiology is still not understood, several theories have been proposed over the years.

*Mycobacterium avium* subspecies *paratuberculosis* has been implicated in the pathogenesis of CD, reinforced by the great similarity between CD and cattle’s Johne disease. This association has been supported by many studies<sup>10</sup> but has not been proven by either identification of mycobacteria in tissue samples or by consistent culture of an organism. Another theory

suggests there is an inherited abnormal response to the high burden of bacteria in the gastrointestinal lumen, resulting in an exaggerated inflammatory response.<sup>11</sup> A third theory claims that these genetic defects are responsible for a diminished inflammatory response and therefore accumulation of stimuli in the intestinal lumen which activate the adaptive immune system.<sup>12</sup>

Clinical manifestations vary greatly in the manner gastrointestinal and extra-intestinal involvement is expressed. The majority of patients have small bowel involvement, predominantly in the ileum, while as many as 20% have the disease confined to the colon. Quite frequently, symptoms are present two to three years before the diagnosis is established. Patients typically have diarrhea, often bloody, abdominal pain, fatigue, weight loss with emaciation, and fever.<sup>13</sup> Transmural inflammation is characteristic often leading to sinus tract(s) formation which, because of the characteristic serositis, leads to bowel-to-bowel adhesions and subsequent fistulas. The image above shows many of the characteristic features of Crohn disease with adherent loops of thick-walled (“transmural inflammation”) bowel showing acute and chronic serositis and fistula formation as evidenced by the metal probes.<sup>14</sup> Perianal involvement is often seen with pain, fissures, perianal abscesses, and fistulas. Other gastrointestinal manifestations include oral aphthous ulcers, odynophagia or dysphagia, gastric outlet obstruction<sup>15</sup> and gallstones.<sup>16</sup>

Extraintestinal manifestations that can be seen are arthritis, skin and eye involvement, primary sclerosing cholangitis leading to secondary biliary cirrhosis, secondary amyloidosis, hypercoagulability, renal stones, osteoporosis, vitamin B12 deficiency and pulmonary involvement.<sup>17-22</sup>

Currently, diagnosis of CD usually requires imaging studies, endoscopy, serologic markers and evaluation of inflammatory-marker protein tests.

Colonoscopy with terminal ileum examination is used to establish the diagnosis of ileocolonic CD. Focal ulcerations intermingled with normal-appearing (“skip”) areas is typical. Polypoid mucosal changes give a distinctive cobblestone appearance, characteristic of CD, although, in the large intestine, longitudinal ulcers, resembling furrows made by a garden rake, are often seen. Carcinoma can develop after many years of active disease, but is exceedingly rare with modern

methods of following patients as well as with effective therapies.<sup>23</sup> Wireless capsule endoscopy is an option to study the proximal segments of the intestine, when ileocolonoscopy fails to disclose a diagnostic lesion.<sup>24</sup> The upper gastrointestinal tract may also be studied by small bowel follow-through series, which allows for the documentation of the length and location of any strictures. Serologic markers are often helpful in distinguishing CD from ulcerative colitis, as well as in monitoring the disease course. In this setting, antineutrophil cytoplasmic antibody (pANCA) and anti-*Saccharomyces cerevisiae* antibody (ASCA) have a sensitivity of 40% - 60% with greater than 90% specificity in distinguishing patients with inflammatory bowel disease from controls.<sup>25</sup>

**Keywords:** Crohn Disease, Pathology, History of Medicine.

## REFERENCES

- Banerjee AK, Peters TJ. The history of Crohn's disease. *J R Coll Physicians Lond.* 1989;23(2):121-4. PMID:2659781.
- Mulder DJ, Noble AJ, Justinich CJ, Duffin JM. A tale of two diseases: the history of inflammatory bowel disease. *J Crohn's Colitis.* 2014;8(5):341-8. <http://dx.doi.org/10.1016/j.crohns.2013.09.009>. PMID:24094598.
- Kirsner JB. The historical basis of the idiopathic inflammatory bowel diseases. *Inflamm Bowel Dis.* 1965;1:2-26.
- Horspool D. King Alfred: burnt cakes and other legends. London: Profile Books; 2006. p.154.
- Bernier JJ, Chevallier P, Teyssiere D, André J. La maladie de Louis XII. Tuberculose intestinale ou maladie de Crohn? *Nouv Presse Med.* 1981;10(27):2243, 2247-50. PMID:7022367.
- Aufses AH Jr. The history of Crohn's disease. *Surg Clin North Am.* 2001;81(1):1-11, vii. [http://dx.doi.org/10.1016/S0039-6109\(05\)70270-X](http://dx.doi.org/10.1016/S0039-6109(05)70270-X). PMID:11218157.
- Crohn BB, Ginzburg L, Oppenheimer GD. Regional ileitis: a pathological and clinical entity. *JAMA.* 1932;99(16):1323-9. <http://dx.doi.org/10.1001/jama.1932.02740680019005>.
- Campos FGMC, Kotze PG. Burrill Bernard Crohn (1884-1983): the man behind the disease. *Arq Bras Cir Dig.* 2013;26(4):253-5. <http://dx.doi.org/10.1590/S0102-67202013000400001>. PMID:24510030.
- Mekhjian HS, Switz DM, Melnyk CS, Rankin GB, Brooks RK. Clinical features and natural history of Crohn's disease. *Gastroenterology.* 1979;77(4 Pt 2):898-906. PMID:381094.
- Naser SA, Sagramsingh SR, Naser AS, Thanigachalam S. Mycobacterium avium subspecies paratuberculosis causes Crohn's disease in some inflammatory bowel disease patients. *World J Gastroenterol.* 2014;20(23):7403-15. <http://dx.doi.org/10.3748/wjg.v20.i23.7403>. PMID:24966610.
- Marks DJB, Segal AW. Innate immunity in inflammatory bowel disease: a disease hypothesis. *J Pathol.* 2008;214(2):260-6. <http://dx.doi.org/10.1002/path.2291>. PMID:18161747.
- Comalada M, Peppelenbosch MP. Impaired innate immunity in Crohn's disease. *Trends Mol Med.* 2006;12(9):397-9. <http://dx.doi.org/10.1016/j.molmed.2006.07.005>. PMID:16890491.
- Mekhjian HS, Switz DM, Melnyk CS, Rankin GB, Brooks RK. Clinical features and natural history of Crohn's disease. *Gastroenterology.* 1979;77(4 Pt 2):898-906. PMID:381094.
- Geller SA. Pathology of inflammatory bowel diseases. In: Targan S, Shanahan F, editors. *Inflammatory bowel disease.* Baltimore: Williams and Wilkins; 1994. chap. 23; p. 336-351.
- Annunziata ML, Caviglia R, Papparella LG, Cicala M. Upper gastrointestinal involvement of Crohn's disease: a prospective study on the role of upper endoscopy in the diagnostic work-up. *Dig Dis Sci.* 2012;57(6):1618-23. <http://dx.doi.org/10.1007/s10620-012-2072-0>. PMID:22350786.
- Hutchinson R, Tyrrell PN, Kumar D, Dunn JA, Li JK, Allan RN. Pathogenesis of gall stones in Crohn's disease: an alternative explanation. *Gut.* 1994;35(1):94-7. <http://dx.doi.org/10.1136/gut.35.1.94>. PMID:8307459.
- Gravallese EM, Kantrowitz FG. Arthritic manifestations of inflammatory bowel disease. *Am J Gastroenterol.* 1988;83(7):703-9. PMID:3289378.
- Huang BL, Chandra S, Shih DQ. Skin manifestations of inflammatory bowel disease. *Front Physiol.* 2012;3:13. <http://dx.doi.org/10.3389/fphys.2012.00013>. PMID:22347192.
- Felekis T, Katsanos K, Kitsanou M, et al. Spectrum and frequency of ophthalmologic manifestations in patients with inflammatory bowel disease: a prospective single-center study. *Inflamm Bowel Dis.* 2009;15(1):29-34. <http://dx.doi.org/10.1002/ibd.20584>. PMID:18626979.
- Headstrom PD, Rulyak SJ, Lee SD. Prevalence of and risk factors for vitamin B(12) deficiency in patients with Crohn's disease. *Inflamm Bowel Dis.* 2008;14(2):217-23. <http://dx.doi.org/10.1002/ibd.20282>. PMID:17886286.
- Lu DG, Ji XQ, Liu X, Li HJ, Zhang CQ. Pulmonary manifestations of Crohn's disease. *World J Gastroenterol.* 2014;20(1):133-41. <http://dx.doi.org/10.3748/wjg.v20.i1.133>. PMID:24415866.

22. Marineață A, Rezuș E, Mihai C, Prelipcean CC. Extra intestinal manifestations and complications in inflammatory bowel disease. *Rev Med Chir Soc Med Nat Iasi*. 2014;118(2):279-88. PMID:25076688.
23. Greenstein AJ, Sachar D, Pucillo A, et al. Cancer in Crohn's disease after diversionary surgery. A report of seven carcinomas occurring in excluded bowel. *Am J Surg*. 1978;135(1):86-90. [http://dx.doi.org/10.1016/0002-9610\(78\)90015-6](http://dx.doi.org/10.1016/0002-9610(78)90015-6). PMID:623378.
24. Levesque BG, Cipriano LE, Chang SL, Lee KK, Owens DK, Garber AM. Cost effectiveness of alternative imaging strategies for the diagnosis of small-bowel Crohn's disease. *Clin Gastroenterol Hepatol*. 2010;8(3):261-7, 267.e1-4. <http://dx.doi.org/10.1016/j.cgh.2009.10.032>. PMID:19896559.
25. Papp M, Norman GL, Altorjay I, Lakatos PL. Utility of serological markers in inflammatory bowel diseases: gadget or magic? *World J Gastroenterol*. 2007;13(14):2028-36. PMID:17465443.

### Correspondence

Stephen A. Geller  
Department of Pathology and Laboratory Medicine  
David Geffen School of Medicine, UCLA  
Los Angeles/CA – USA  
**E-mail:** geller16st@gmail.com

Fernando P. F. de Campos  
Divisão de Clínica Médica  
Hospital Universitário  
University of São Paulo  
São Paulo/SP – Brazil  
**E-mail:** fpfcampos@gmail.com