

Case Report

Open Access

Antonio Cortese, Giuseppe Pantaleo*, Giuseppe D'Alessio, Alfredo Garzi, Massimo Amato

Hemangiomas of the maxillofacial area: Case Report, Classification and Treatment Planning

DOI: 10.1515/med-2015-0066

received October 24, 2015; accepted November 4, 2015.

Abstract: Vascular lesions of the maxillofacial area are even more challenging than in other different body district, because of the high aesthetic and functional relevance of this area for the sense organs presence like eye, brain, tongue, ear and nose. For these reasons, we propose an accurate classification based on hemodynamic and histologic aspects useful that is for diagnostic and therapeutic planning. A female, 60 years old patient came to our observation showing a vascular lesion of the lower left lip, and complaining for aesthetical and functional impairment. To confirm the diagnosis of vascular malformation and to detect lesion flow rate or other possible localization, a Tc red blood cell scintigraphy was carried out. Result was a venous low flow lesion; hence, sclerotherapy by a 3% Polidocanol solution (Atossisclerol) followed by surgery was planned. The aim of this work was to propose a diagnostic and therapeutic scheme with an integration of ISSVA and a flow rate classifications for a three-step planning based on 1) the biological findings in an early age at the lesion discover with a pharmacological treatment; 2) Hemodynamic study of the lesions at growing age followed by sclerotherapy or embolization; 3) Imaging study of these lesions for patients candidate to surgery when after step 1 and step 2 diagnostic and therapeutic planning results were incompletely successful.

Keywords: hemangiomas, vascular lesion, sclerotherapy

1 Introduction

Treatment of vascular lesions is still a great challenge for surgeons because of the difficulties in the proper treatment for very different kind of lesions and surgical risks related to the conspicuous bleeding during surgery, particularly when carried out without an adequate hemodynamic study and preoperative endovascular treatment. Vascular lesions of the maxillofacial area are even more challenging than in other body districts because of the high aesthetic and functional relevance of this area due to the presence of the sense organs such as eye, brain, tongue, ear and nose [1]. For these reasons, we propose an accurate classification based on hemodynamic and histologic aspects useful for diagnostic and therapeutic planning. Actual classifications are based on the histological and biological classification from Mulliken and Glowacki [2], but significant confusion is still detectable in the literature for the improper and interchangeable use of different terms with different meanings similar to the original ones used. In the original classification [2], hemangiomas are benign neoplasm of the endothelial cells. They have to be differentiated from vascular malformations, which were considered like localized defects of the vascular morphogenesis [3]. Nowadays, the widely accepted classification from the International Society for the Studies of Vascular Anomalies (ISSVA) tries to overcome these problems in order to correctly manage these different lesions. In this classification, a double evaluation of vascular lesions is carried out: a histological and biological evaluation that is useful for predicting evolution and clinical behavior of these lesions based on the classification [1] and an hemodynamic evaluation of vascular lesions based on high flow and slow flow lesions classification [3]. Emodinamic evaluation is particularly useful for the vascular malformations where sclerotherapy for low flow lesions and embolization for high flow lesions are indicated followed, if necessary, by surgery [3]. Hemangiomas are very common neoplasia that affect infants and children, found with great frequency in girls, premature infants, and children with mothers of older age. Vascular tumors (Hemangiomas) are usually detected

*Corresponding author: **Giuseppe Pantaleo**, Department of Neurosciences, Reproductive and Odontostomatological Sciences, University of Naples Federico II, Corso Umberto I, 40, 80138 Napoli, Italy, E-mail: giuseppepantaleo88@gmail.com

Antonio Cortese: Department of Medicine and Surgery, Unit of Maxillofacial Surgery, University of Salerno, Salerno, Italy

Giuseppe D'Alessio, Alfredo Garzi, Massimo Amato: Department of Medicine and Surgery, University of Salerno, Salerno, Italy

at birth and arise within 3–4 weeks revealing different clinical characteristic and course showing an intensive growth period and an involution long process [4]. The proliferation phase usually starts from the third up to ten month of the first year of age followed by a first involution phase (1 – 5 years of age) and a late involution which usually ends at about 10–12 years of age [5-6]. During the growing phase, endothelial cells, fibroblasts, mastocytes and macrophages will grow very fast and during these phases hemangiomas classically don't require any particular treatment because of the natural involution. Only in cases of extensive growth, local or intravenous corticosteroids therapy is given. Nowadays, for good results with propranolol therapy without any significant side effects, a change of therapeutic approach to hemangiomas has developed. Because of the high localization rate into the maxillofacial area (60% of the total lesions, while 25% are localized at the trunk and 15% at the limbs), a new approach by an early therapy with propranolol is particularly useful [7]. Vascular malformations are divided into slow and high flow lesions that can be classified in the relation to the formation of vessels into capillary, venous, lymphatic, arterial and hybrid lesions with different treatment indications for each particular case. There are various kinds of treatment methods for vascular malformations ranging from embolization, sclerotherapy, surgery, laser therapy, crio-therapy to electrocoagulation [2,8]. The aim of this work was to propose a diagnostic and therapeutic scheme with a three-step organization based on 1) biological findings in early age; 2) hemodynamic study of the lesions at growing age; 3) imaging study of these lesions for patients candidate to surgery when after step 1 and step 2 diagnostic and therapeutic planning results were incompletely successful.

2 Clinical Case

A female, 60 years old patient came to our observation showing a vascular lesion of the lower left lip, and complaining from aesthetical and functional impairment. At physical examination, a right cervical lymph node and a thyroidal nodule were detected. Before the treatment of the vascular treatment, a fine-needle cytology examination of both the lesions was performed as reported elsewhere [9-18]. FNAC demonstrated a benign hyperplasia of the lymph node and a nodular goiter of the thyroid. The vascular lesion involved full thickness of the lower lip from the cutaneous plane to the intraoral mucosa plane through the lip muscles. Distortion of the lower lip at rest

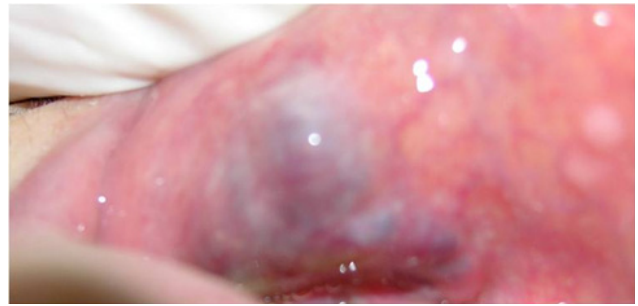


Figure 1: Lesion of the lower left lip.

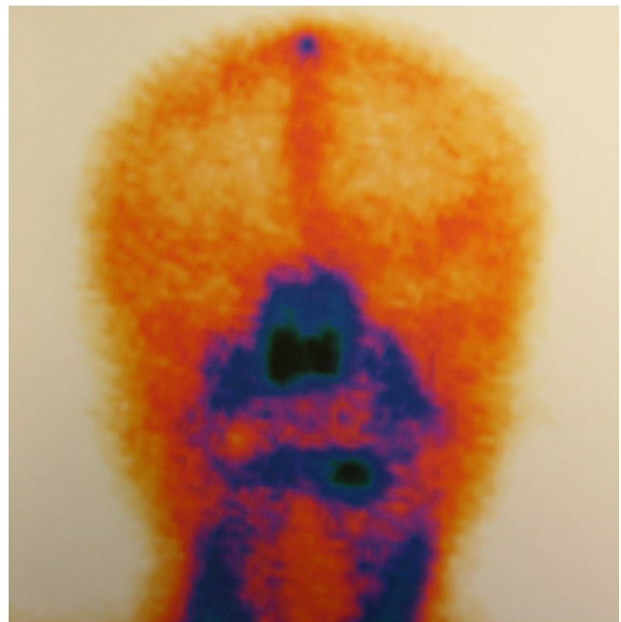


Figure 2: Tc red blood cell scintigraphy of the lesion.

and during swallowing and smiling movement was evident (Fig. 1). Patient was in a good general health and didn't suffer for any major or particular disease. History lesion was suggestive for a vascular malformation following the classification of Mulliken and Glowacki modified by the ISSVA [4]: the patient reported that the lesion was present at birth and showed slow enlargement coherent with whole body growth. The lesion was never treated because of high treatment risk referred to the patient by healthcare institutes at patient infantile and juvenile age. To confirm the diagnosis of vascular malformation and to detect lesion flow rate or other possible localization, a Tc red blood cell scintigraphy was carried out (Fig. 2). Result was a venous low flow lesion; hence sclerotherapy by a 3% Polidocanol solution (Atossisclerol) followed by surgery was planned. Polidocanol is a moderate form of ethanol and is commonly used in European countries: injection of this agent promotes thrombosis and blood vessel

occlusion and hence damaging vascular endothelial cells. Aseptic inflammation and subsequent fibrosis will result in obliteration of vascular lumen and fibrosis. This agent is particularly useful for superficial vascular lesions; for larger lesions treatment, involving muscular planes, multiple injections in different puncture sites are indicated: multiple fractioning of the injection treatment will also prevent local and general complications. Treatment was performed under hospitalization regimen after routine blood test, electrocardiogram and thorax X-ray examines. Sclerotherapy was performed under hospitalization because of the general risks and complication that may arise from sclerosing agent injection in the vascular lesion lumen, particularly for maxillofacial area. General complications after sclerotherapy are allergic reactions and pulmonary or other organs complication for the sclerosing agent's action to the other systemic organs like lungs, brain, liver, kidney via general vascular system. Local complications that are related to the peculiar site of the maxillofacial area are: cutaneous or mucosal necrosis and sensory or motor nerve injuries; particular attention must be paid during injection for facial nerve paralysis because of its heavy aesthetics relevance. Other rare complications are related to facial venous connection to the angular vein resulting in accidental embolization of the cavernous sinus. For these risks, patient was treated in an operating room theater monitoring general parameters like ECG, pulse oximetry and with a peripheral vein access. Particular attention was paid during sclerosing agent injection: it is important to inject the agent into the vascular lesion compartment avoiding the surrounding tissues or major blood vessels; moreover the lesion area draining veins were compressed to prolong the sclerosing agent time action and prevent pulmonary or other organs complications. After proper disinfection, a 3% Polidocanol solution was injected using a syringe with a 25 Gauge needle. Puncture was performed from the surrounding normal tissue until blood was withdrawn; after injection, compression was applied to the insertion sites to avoid effusion. One ml dosage was administered up to pale lesion appearance. The total dosage was in relation to the extent of the lesion with no more than 3 ml for each injection. In case of poor results, treatment would have been repeated at an interval of 1 to 2 weeks, depending on the extension and the vascular pattern of the lesion. After lesion delimitation by sclerotherapy, ablative surgery was carried out, paying attention to the bleeding risks performing contemporary compression on possible supplying arterial vessels at the lesion area borders. Bleeding was normal during the surgery and the lesion was easily isolated and removed after sclerotherapy with

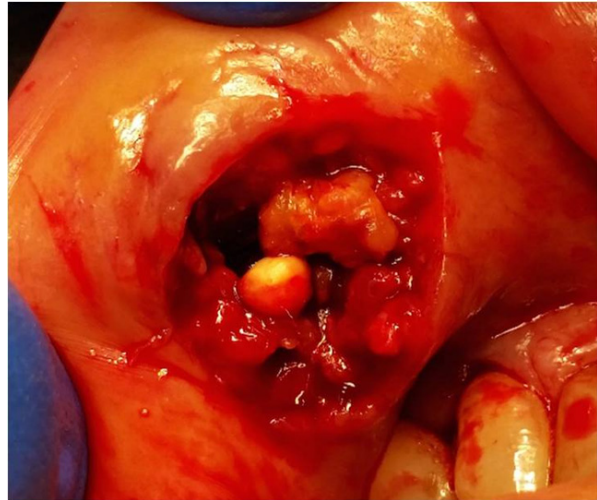


Figure 3: Ablative surgery of the lesion.

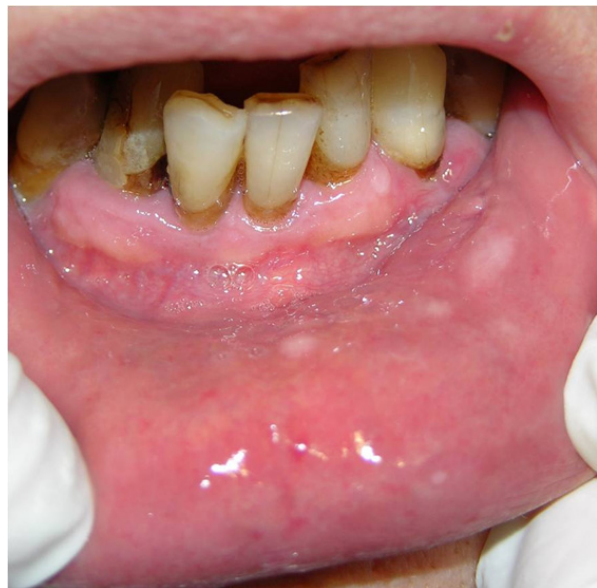

Figure 4: Surgical result at post-operative control.

a phlebolite inside (Fig. 3). Antibiotics and corticosteroids were as usually given after surgery.

Surgical result was good with a complete lesion ablation and patient satisfaction. No signs of residual vascular lesion were found by Doppler Ultrasound sonography at a post-operative control (Fig. 4).

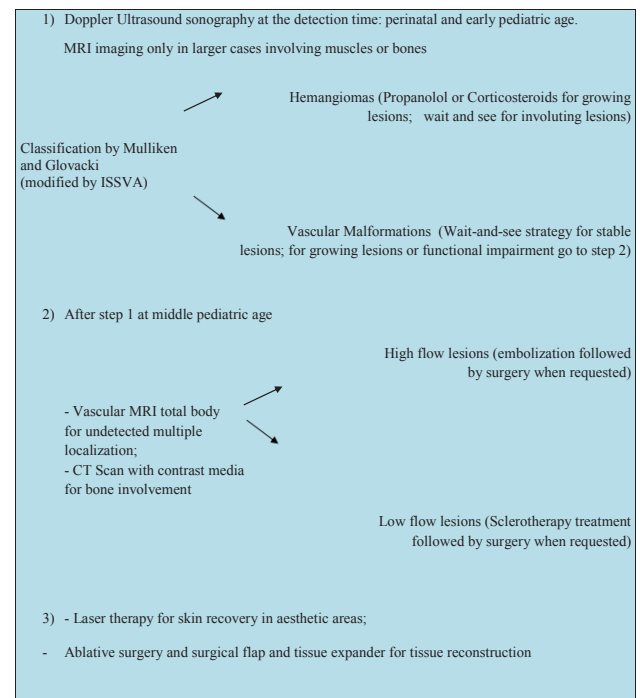
Ethical approval: The research related to human use has been complied with all the relevant national regulations, institutional policies and in accordance the tenets of the Helsinki Declaration, and has been approved by the authors' institutional review board or equivalent committee.

Informed consent: Informed consent has been obtained from all individuals included in this study.

3 Discussion

Following the classification by ISSVA [4], hemangiomas are the most common group of tumors from mesenchymal origins occurring in 5-10 % of new born with a high rate (about 30%) in prematurely born. Vascular malformations are less frequent than hemangiomas with the same incidence in males and females. Body districts incidence for hemangiomas shows 60% localization at the head followed by trunk (25%) and limbs (15%) with a prevalent single lesion incidence (80%). They are usually absent at birth and appear within 3-4 weeks with a proliferation time (from third to tenth month of life), an early involution period from the first to the fifth year of life and a late involution period up to the age of 10-12 [3,18-19]. During the proliferative time, histological specimens show active proliferation of endothelial cells, fibroblasts, macrophages and macrocytes. Vascular malformations widely differ from hemangiomas, showing a congenital incidence or a comparison in an early childhood. Their growth is proportional to the body segments growth, but some trigger factors like infections, hormonal changes or traumatic events can cause rapid increase resulting in a deformation of anatomical structures like bone enlargements for low flow lesions or osteolysis for high flow lesions. Other evolutions are infection, pain, thrombosis and ulceration. To avoid the risks of a high rate growing lesions and consequent late scars after involution or to preserve functional district with sense organs, upper air tracts and aesthetic areas, preventive therapy with propranolol has even more widely administered. (The propranolol therapy starts with an oral dose of 0.5 mg/kg/day and can be gradually increased up to 2 mg/kg/day until the regression of the lesion). During the second year of life, most of the hemangiomas get an involution phase, and 50% of the lesions are completely healed without scares and changes in the skin colors. Anyway, the involution process can cause laxity of the tissues, scarring, production of fibro-fatty mass and teleangiectasias [9]. Theories about hemangioma development include abnormalities in fetal vasculogenesis period at the sixth-tenth week of fetal life, and are not hereditary [1-4]. Some theories evoke endothelial cells mutation, or adhering cells (macrophages and fibroblasts) influence, or proangiogenetic factors influence. Another theory for hemangiomas placental origin advocates a fetal vessel embolization with placental cells in the district sites of the hemangioma lesion [1-4]. Other studies support this theory by the observation of 3 to 4 times higher incidence of hemangiomas in children whose mothers had undergone chorion or trophoblast biopsy [6,7,9]. Also,

Table 1: Diagnostic-therapeutic scheme.



the related estrogen and hormone levels hemangiomas growth can be explained with the placental origin of hemangiomas. Other theories suggest the developmental field disturbance for the hemangiomas origin evidenced by the association with other developmental malformation like PHACE syndrome (acronym for Posterior fossa brain malformation, hemangioma, arteriocerebral vascular anomalies, aortic cohartation, cardiac defects and eye defects and endocrine abnormalities), Sturge-Weber and Kasabach-Merritt syndrome [9]. On the other side, theories about vascular malformation origin suggest a relation with abnormalities of vascular tissue morphogenesis [6,7]. Based on the Mulliken and Glowacki and ISSVA [4] classifications in association with the vascular speed flow classification, we developed a three-step diagnostic and therapeutic scheme useful for adequate treatment planning of the vascular lesions of the maxillofacial area (Tab. 1). In our planning at an early patient age, when the vascular lesion is detected, it will be studied by Doppler Ultrasonography and, only in cases of larger lesions involving muscles or deeper anatomical structures, by a Magnetic Risonance imaging (MRI): the vascular lesion will be classified following the classical classification of Mulliken and Glovacki (modified by the ISSVA) [4]. In this way it was possible a correct therapy planning of the lesion: in case of hemangiomas classified by clinical or histological criteria, a propranolol or corticosteroid therapy

in active lesions during growing phases was carried out; a wait-and-see strategy was adopted in stable or regressive phases [7]. In case of vascular malformations, an hemodynamic study for precise speed flow classification was carried out: high speed flow lesions comprise arterial, arteriovenous and mixed ones, while low flow vascular malformation include venous, capillary, lymphatic and hybrid lesions. In case of functional impairment or active growing phase, sclerotherapy for low flow vascular lesions or embolization for high flow lesions followed by surgery, if needed, was carried out already at an early age. In case of low flow lesions, sclerotherapy was performed by endovascular lumen injection of the lesion; in high flow lesions embolization will be performed usually followed by surgery for a more complete result. In case of mixed lesions with different areas showing different vascular patterns, proper therapy will be adopted for each area. For skin areas involved in the vascular lesions, laser therapy or tissue expanders will be adopted in order to preserve as much as possible skin amount from ablative surgery [20]. Before surgery, detailed evaluation of lesion borders must be carried out by MRI total body and, in case of bone segments involvement, a CT Scan with contrast media will be carried out. In order to detect possible multiple localizations of the vascular lesions in different organs like brain, lungs, liver, and kidneys, a Magnetic Resonance Imaging will be performed extended to the whole body. For large vascular lesions involving deep tissues like muscles or bone segments, local or microsurgical flaps will be used for maximum possible reconstruction of aesthetic maxillofacial areas after ablative surgery [3,21]. Pain is a common problem with venous malformations especially in the upper face and temporal areas. Controlling the pain should be a goal but it may be difficult to accomplish. Bleeding and airway compromise are common with extensive head and neck mucosal lesions and the goal is to decrease the risks of bleeding and to preserve the airway function. In maxillofacial area, particular attention should be paid to the tongue, palate, eye and parotid. The risk of sclerotherapy could be necrosis, in particular with the involvement of the facial nerve and nerve paralysis. In the eye's area, the risk is the formation of edema that can generate visual noises. With sclerotherapy, compression should always be done, to prevent sclerosing agent emigration to distant organs such as lungs, brain, and kidneys, with possible lesions because of the high vascularity of these important organs. Sclerotherapy has to be performed under hospitalization because of the general risks and complication that may arise from sclerosing agent injection in the vascular

lesion lumen, particularly for maxillofacial area. Other possible therapies for hemangiomas are corticosteroid, compression cryotherapy etc. Regarding vascular malformation, therapies are based on the vascular speed flow of the lesion or of the different vascular patterns inside the same lesion: sclerotherapy for low flow and embolization for high flow lesions usually followed by surgery will be carried out.

4 Conclusions

Based on the Mulliken and Glowacki [4] and ISSVA classifications integrated with a vascular speed classification (high flow and slow flow), a three-step diagnostic and therapeutic scheme useful for adequate treatment planning of the vascular lesions of the maxillofacial area has been developed. Regarding the uninvoluting vascular lesions, personalized treatment must be planned depending on patient age, lesion extension, sense organs involvement and disease progression. Multi-specialty competence are required ranging from vascular surgery, plastic surgery, maxillo-facial and orthognatic surgery, neurosurgery, microsurgery to laser therapy. In Particular, maxillofacial and orthognatic surgery competence are needed for the treatment of head and neck lesions involving facial bones for specific new techniques developed in facial bone surgery [23-33] and for differential diagnosis with other lesions of head and neck area [25]. In particular, extended cases complete excision of the lesion is not possible and a multi-stage therapy must be planned following the criteria of maximum conservative therapy particularly for esthetic areas where Nd:Yag laser or Diode laser can be used to save skin from ablative surgery and CO2 laser to treat scars in aesthetic areas.

Conflict of interest statement: Authors state no conflict of interest.

References

- [1] Buckmiller L.M., Richter G.T., Suen J.Y., Diagnosis and management of hemangiomas and vascular malformations of the head and neck, *Oral Dis.*, 2010, 16, 405-418
- [2] Mulliken J.B., Glowacki J., Hemangiomas and vascular malformations in infants and children: a classification based on endothelial characteristics, *Plast. Reconstr. Surg.*, 1982, 69, 412-422
- [3] George A., Mani V., Noufal A., Update on the classification of hemangioma, *J. Oral Maxillofac. Pathol.*, 2014, 18, S117-20

- [4] Wójcicki P., Wójcicka K., Epidemiology, diagnostics and treatment of vascular tumours and malformations, *Adv. Clin. Exp. Med.*, 2014, 23, 475-84
- [5] Dubois J., Garel L., Imaging and therapeutic approach of hemangiomas and vascular malformations in the pediatric age group, *Pediatr. Radiol.* 1999, 29, 879-893
- [6] Hoff S.R., Rastatter J.C., Richter G.T., Head and Neck Vascular Lesions, *Otolaryngol. Clin. North Am.*, 2015, 48, 29-45
- [7] Zheng J.W., Mai H.M., Zhang L., Wang Y.A., Fan X.D., Su L.X., et al., Guidelines for the treatment of head and neck venous malformations, *Int. J. Clin. Exp. Med.*, 2013, 22, 6, 377-89
- [8] Baldi C., Ieni A., Cozzolino I., Cerbone V., Memoli D., Zeppa P., Ultrasound-guided fine needle aspiration cytology of a primary lymph node leiomyoma: a flexible procedure for a complex case, *Acta Cytol.*, 2014, 58, 303-8
- [9] Cozzolino I., Vigliar E., Todaro P., Peluso A.L., Picardi M., Sosa Fernandez L.V., et al., Fine needle aspiration cytology of lymphoproliferative lesions of the oral cavity, *Cytopathology*, 2014, 25, 241-9
- [10] Vigliar E., Cozzolino I., Picardi M., Peluso A.L., Fernandez L.V., Vetrani A., et al., Lymph node fine needle cytology in the staging and follow-up of cutaneous lymphomas, *BMC Cancer*, 2014, 14, 8
- [11] Zeppa P., Barra E., Napolitano V., Cozzolino I., Troncione G., Picardi M., et al., Impact of endoscopic ultrasound-guided fine needle aspiration (EUS-FNA) in lymph nodal and mediastinal lesions: a multicenter experience, *Diagn. Cytopathol.*, 2011, 39, 723-729
- [12] Cozzolino I., Nappa S., Picardi M., De Renzo A., Troncione G., Palombini L., et al., Clonal B-cell population in a reactive lymph node in acquired immunodeficiency syndrome, *Diagn. Cytopathol.*, 2009, 37, 910-914
- [13] Zeppa P., Vitale M., Fine-needle cytology of Hürthle cell tumors and morphometry, *Cancer Cytopathol.*, 2014, 122, 553
- [14] Zeppa P., Sosa Fernandez L.V., Cozzolino I., Ronga V., Genesio R., Salatiello M., et al., Immunoglobulin heavy-chain fluorescence in situ hybridization-chromogenic in situ hybridization DNA probe split signal in the clonality assessment of lymphoproliferative processes on cytological samples. *Cancer Cytopathol.* 2012, 120, 390-400
- [15] Cozzolino I., Picardi M., Lucci R., Petraroli A., Spadaro G., Marone G., et al., Lymph node fine needle aspiration cytology in systemic mastocytosis: Cytological features with ancillary tests and literature review, *Cytopathol.*, 2015, 26, 31-37
- [16] Cortese A., Amato M., Pantaleo G., Claudio PP. A Patient With a Rare Single Mandibular Localization of Non-Hodgkin B-Cell Lymphoma: Early Differential Diagnosis With Dental Lesions, *J. Craniofac. Surg.*, 2015, 26(4), e365-366
- [17] Ulas M., Ozer I., Bostancil E.B., Karaman K., Dalgic T., Polatl E., et al., Giant hemangiomas: effects of size and type of surgical procedure on postoperative outcome, *Hepatogastroenterology*, 2014, 61, 1297-301
- [18] Cortese A., Savastano G., Amato M., Cantone A., Boschetti C., Claudio PP., New palatal distraction device by both bone-borne and tooth-borne force application in a paramedian bone anchorage site: surgical and occlusal considerations on clinical cases, *J. Craniofac. Surg.*, 2014, 25, 589-95
- [19] Cortese A., Savastano G., Amato M., Pantaleo G., Claudio PP., Intraoral epimucosal fixation for reducible maxillary fractures of the jaws; surgical considerations in comparison to current techniques, *J. Craniofac. Surg.*, 2014, 25, 2184-7
- [20] Cortese A., Pantaleo G., Ferrara I., Vatrella A., Cozzolino I., Di Crescenzo V., et al., Bone and soft tissue non-Hodgkin lymphoma of the maxillofacial area: report of two cases, literature review and new therapeutic strategies, *Int. J. Surg.*, 2014, 12, S23-8
- [21] Guerra A., Di Crescenzo V., Garzi A., Cinelli M., Carlomagno C., Pepe S., et al., Diagnostic utility of BRAFV600E mutation testing in thyroid nodules in elderly patients. *BMC Surg.*, 2013, 13, S37
- [22] Di Crescenzo V., Laperuta P., Napolitano F., Carlomagno C., Garzi A., Vitale M., Pulmonary sequestration presented as massive left hemothorax and associated with primary lung sarcoma. *BMC Surg.*, 2013, 13, S34
- [23] Di Crescenzo V., Laperuta P., Napolitano F., Carlomagno C., Garzi A., Vitale M., An unusual case of primary choriocarcinoma of the lung. *BMC Surg.*, 2013, 13, S33
- [24] Di Crescenzo V., Laperuta P., Napolitano F., Carlomagno C., Danzi M., Amato B., et al., Migration of surgical clips through a right lobectomy stump mimicking an asthmatic syndrome. *BMC Surg.*, 2013, 13, S32
- [25] Guerra A., Di Crescenzo V., Garzi A., Cinelli M., Carlomagno C., Tonacchera M., et al., Genetic mutations in the treatment of anaplastic thyroid cancer: a systematic review. *BMC Surg.*, 2013, 13, S44
- [26] Di Crescenzo V., Garzi A., Petruzzello F., Cinelli M., Catalano L., Zeppa P., et al., Nodular goiter with amyloid deposition in an elderly patient: fine-needle cytology diagnosis and review of the literature, *BMC Surg.*, 2013, 13, S43
- [27] Gallelli L., Busceti M.T., Vatrella A., Maselli R., Pelaia G., Update on anticytokine treatment for asthma, *Biomed. Res. Int.*, 2013, 104315
- [28] Pelaia G., Gallelli L., Renda T., Fratto D., Falcone D., Caraglia M., et al., Effects of statins and farnesyl transferase inhibitors on ERK phosphorylation, apoptosis and cell viability in non-small lung cancer cells, *Cell. Prolif.*, 2012, 45, 557-65
- [29] Pelaia G., Terracciano R., Vatrella A., Gallelli L., Busceti M.T., Calabrese C., et al., Application of proteomics and peptidomics to COPD, *Biomed. Res. Int.*, 2014, 764581
- [30] Pelaia G., Renda T., Gallelli L., Vatrella A., Busceti M.T., Agati S., et al., Molecular mechanisms underlying airway smooth muscle contraction and proliferation: implications for asthma, *Respir. Med.* 2008, 102, 1173-81
- [31] Rispoli C., Rocco N., Iannone L., Amato B., Developing guidelines in geriatric surgery: role of the grade system, *BMC Geriatrics*, 2009, 9, A99
- [32] Amato B., Sivero L., Vigliotti G., Rispoli C., Rocco N., Iannone L., Surgery for cancer in the elderly: State of the art, *Chirurgia (Turin)*, 2013, 26, 313-315
- [33] Amato B., Villa F., Compagna R., Donisi M., Markabaoui A.K., Puzziello A., et al., Organizational models in robotic assisted surgery, *Int. J. Clin. Investig.*, 2002, 10, 45-48