

## What is new in the management of rapidly progressive glomerulonephritis?

George H.B. Greenhall and Alan D. Salama

UCL Centre for Nephrology, Royal Free Hospital, London, UK

Correspondence to: Alan D. Salama; E-mail: a.salama@ucl.ac.uk

### Abstract

Rapidly progressive glomerulonephritis (RPGN) results from severe crescentic damage to glomeruli and leads to irreversible kidney failure if not diagnosed and managed in a timely fashion. Traditional treatment has relied on glucocorticoids and cyclophosphamide, with additional plasmapheresis for certain conditions. Here we describe updates in the management of RPGN, according to the underlying renal pathology. However, there remains a paucity of trials that have enrolled patients with more advanced renal disease, dialysis dependence or with RPGN, and we are therefore still reliant on extrapolation of data from studies of patients with a less severe form of disease. In addition, reporting bias results in publication of cases or cohorts showing benefit for newer agents in advanced disease or RPGN, but it remains unclear how many unsuccessful outcomes in these circumstances take place. Since clinical trials specifically in RPGN are unlikely, use of biologic registries or combination of sufficient sized cohort series may provide indications of benefit outside of a clinical trial setting and should be encouraged, in order to provide some evidence for the efficacy of therapeutic regimens in RPGN and advanced renal disease.

**Keywords:** AKI; glomerulonephritis; IgA nephropathy; systemic lupus erythematosus; vasculitis

### Introduction

Rapidly progressive glomerulonephritis (RPGN) is clinical syndrome defined by the rapid loss of renal function, accompanied by features of a nephritic syndrome with proteinuria, glomerular haematuria and often oliguria. Although relatively uncommon, early recognition and prompt diagnosis and treatment are crucial to prevent irreversible loss of renal function. Histologically, RPGN is characterized by a crescentic glomerulonephritis (CGN), which is due to severe glomerular injury, resulting in rupture of the glomerular capillary loops (Figure 1), with accumulation of leucocytes and blood constituents in Bowman's space, which in turn induces visceral epithelial cell proliferation, together forming a cellular crescent. CGN is defined pathologically (for most glomerular diseases) when >50% of glomeruli have crescents, which are identified on light microscopy by the presence of at least two layers of cells in Bowman's space. However, this cut-off is arbitrary and clearly severe glomerular injury can occur and result in a rapid decline of renal function with a lower proportion of crescents. There are other conditions that can lead to a clinical syndrome of RPGN, which are not caused by severe glomerular. These include thrombotic microangiopathies and rarely cases of tubulointerstitial

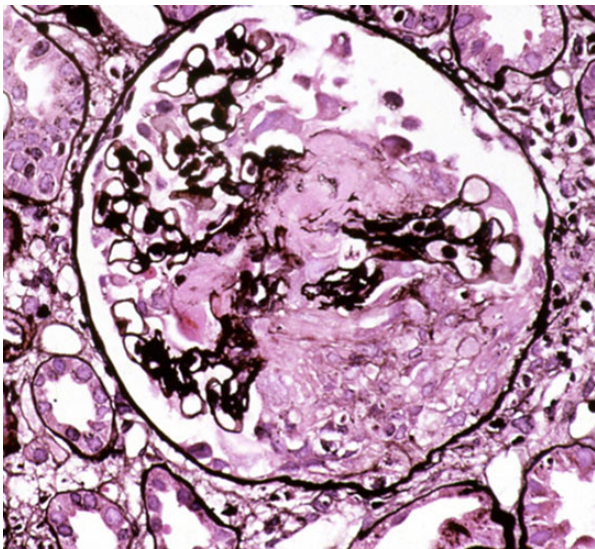
nephritis, making it important to make a firm diagnosis based on clinical, haematological, serological and renal biopsy data (Table 1).

CGN is commonly categorized based on the pattern of immunoglobulin deposition by immunohistochemistry, and is most frequently caused by:

- Anti-glomerular basement membrane (GBM) disease with linear immunoglobulin deposition.
- Immune complex glomerulonephritis with granular immunoglobulin deposition.
- Pauci-immune glomerulonephritis most often associated with anti-neutrophil cytoplasm antibody (ANCA).

The relative likelihood of each of these is dependent on the age of the patient, with pauci-immune (ANCA associated) GN being more common in older patients and immune complex disease predominating in younger subjects, as a result of the propensity for IgA nephropathy (IgAN) post-infectious GN and lupus nephritis (LN) to affect younger patients.

Management of these conditions is based on the underlying aetiology; however, in many instances, due to lack of data, treatment strategies are extrapolated from one indication to another, based on the common clinical presentation and pathology with CGN. In addition, for many



**Fig. 1.** Glomerulus showing crescentic glomerulonephritis due to pauci-immune ANCA-associated vasculitis, with a segmental area of thrombosis, tuft disruption and cells in Bowman's space (Haematoxylin and eosin  $\times 400$ ). Courtesy of Professor Alexander Howie.

**Table 1.** Causes and frequency of crescentic glomerulonephritis in which there are  $>50\%$  glomerular crescents

Pathological causes of crescentic glomerulonephritis	Proportion of conditions with $>50\%$ crescents <sup>a</sup> (%)
Anti-GBM disease	85
ANCA-associated glomerulonephritis	50
Lupus Nephritis	13
Henoch Schonlein Purpura	10
IgA Nephropathy	4

<sup>a</sup>Adapted from Heptinstall's Pathology of the Kidney 6th ed, 2007.

of the conditions, clinical trials have specifically excluded patients with RPGN, and again extrapolations regarding management in this group have to be made. The most detailed and relevant trial data for patients with RPGN comes from studies in ANCA-associated vasculitis (AAV), while smaller cohort data are available for patients with RPGN and underlying lupus nephritis, anti-GBM disease and IgA nephropathy. As a result, various conditions that present with RPGN may be treated with a similar type of regimen, using combinations of immunosuppressive agents, and adjunctive therapies; however, specific dosing protocols may vary. Newer agents that have reached the clinic for one indication may well be/have been applied to others, while there are other agents, effective in animal models, that have yet to be translated to the clinical setting.

Historically, the standard of care has been glucocorticoids, delivered as pulsed therapy and followed by oral treatment, in combination with cyclophosphamide; however, there remains much uncertainty about the most efficacious and least toxic steroid doses and how they may be best used in combination with other newer agents. In addition, the desire to minimise cumulative doses of cyclophosphamide, especially in younger patients, has led to the trialling of other induction therapies. This review will highlight the most recent developments in the management of RPGN, with emphasis on the different approaches in particular clinical settings.

## Small vessel (ANCA associated) vasculitis and pauci-immune CGN

Standard induction therapy has been with cyclophosphamide, given orally or pulsed intravenously, with glucocorticoids. Recent trials have investigated alternative induction therapies. However, many of these studies have included patients without renal involvement, or with less severe renal impairment, limiting their utility to translate for patients with RPGN.

### Rituximab

Rituximab is now firmly established as an option in the management of AAV, and offers a viable alternative for patients with a contraindication to cyclophosphamide. Two landmark trials demonstrated non-inferiority in comparison with cyclophosphamide and glucocorticoids in remission induction. Evidence from the RAVE study ( $n=197$ ) demonstrated that remission maintenance with rituximab and glucocorticoid induction was as effective as cyclophosphamide induction followed by azathioprine and that patients with relapsing disease benefited more from rituximab. However, only two-thirds of patients in this study had renal involvement, and those with creatinine  $>354 \mu\text{mol/L}$  were specifically excluded [1]. In the RITUXIVAS trial ( $n=44$ ), which included 33 patients treated with rituximab, all of whom had some degree of renal impairment (median eGFR  $20 \text{ mL/min/1.73 m}^2$ , 24% dialysis dependent), there were similar outcomes and adverse events compared with those treated with conventional cyclophosphamide and glucocorticoid induction therapy [2].

A recent report in abstract form examined the outcome of 28 patients presenting with advanced kidney disease (eGFR  $<20 \text{ mL/min/1.73 m}^2$ ) who were treated with either rituximab and glucocorticoids ( $n=9$ ) or rituximab, glucocorticoids and cyclophosphamide ( $n=19$ ) [3]. Outcomes with regard end-stage renal disease (ESRD), death, improvement in renal function and infectious complications were equivalent in these two small cohorts. A larger cohort analysis is clearly required; until then, the long-term benefit of using rituximab without cyclophosphamide in patients with RPGN or advanced renal failure is uncertain.

### Mycophenolate Mofetil

Mycophenolate mofetil (MMF) is appealing as a cyclophosphamide-sparing agent in AAV; however, no trials have included patients with advanced renal impairment or RPGN. A randomized, single-centre trial comparing MMF with cyclophosphamide induction in 35 patients with creatinine  $<500 \mu\text{mol/L}$  (mean  $312 \mu\text{mol/L}$ ) demonstrated a benefit for MMF, with regards rates of remission, reduction in Birmingham Vasculitis Activity Score (BVAS) and improvement in renal function [4]. A pilot study in the USA reported remission induction in 76% of patients with mild-to-moderate renal involvement (creatinine  $<240 \mu\text{mol/L}$ ) [5], while an open-label randomised controlled trial (RCT) found no significant difference in efficacy between MMF and intravenous cyclophosphamide in 41 patients with microscopic polyangiitis (MPA) [6]. However, preliminary reports suggest that the international MYCYC study has failed to demonstrate non-inferiority of MMF and a standard glucocorticoid taper in comparison to intravenous cyclophosphamide in 140 patients with MPA and granulomatosis with polyangiitis [7]; although a secondary end

point of MMF regardless of glucocorticoid dosing did demonstrate non-inferiority, suggesting that MMF and more liberal steroid dosing may be equivalent to pulsed cyclophosphamide. However, this trial specifically excluded patients with RPGN or severe renal impairment (defined as an eGFR decline of >20% in prior 2 weeks or eGFR <15 mL/min/1.73 m<sup>2</sup>, respectively). MMF cannot therefore be recommended in cases of RPGN on the basis of current data.

#### Therapeutic Plasma Exchange

The landmark MEPEX trial, which included 137 patients with severe renal AAV, demonstrated a significant benefit from therapeutic plasma exchange (TPE) in comparison with intravenous glucocorticoid [8]. Although mortality did not differ between the two groups, renal survival in patients who received TPE was more favourable at 3 and 12 months. However, subsequent follow-up of this cohort found no difference in patient or renal survival after an average of nearly 4 years; the overall mortality rate was also unexpectedly high in both groups [9]. Additionally, a meta-analysis of TPE in RPGN, which included nine trials and 387 patients (the majority of whom had AAV or idiopathic renal vasculitis), concluded that there was insufficient evidence to demonstrate that TPE reduces the risk of a combined outcome of ESRD and death. Although TPE was associated with a significant reduction in the risk of ESRD alone [relative risk (RR) 0.64], the available data were insufficient to determine this reliably [10]. Therefore, the long-term benefit of TPE in severe AAV is unknown at present. The international PEXIVAS trial aims to address this uncertainty by randomizing 500 patients with AAV and significant renal injury (eGFR <50 mL/min/1.73 m<sup>2</sup>) or pulmonary haemorrhage to receive either TPE and glucocorticoids or glucocorticoids alone. Outcome data will not be available for another few years (NCT00987389, protocol in [11]).

#### Anti-TNF $\alpha$ Agents

Previous studies of anti-TNF $\alpha$  agents in AAV have been conflicting. The Phase 2, open-label ACTIVE trial suggested a role for *infliximab* as an adjunctive therapy in remission induction of AAV [12]; however, a recent open-label trial in 33 patients with AAV (80% with renal involvement) showed no benefit from the addition of *infliximab* to standard care, despite the fact that the *infliximab* group had milder renal involvement at baseline (median eGFR 32.6 versus 13 mL/min/1.73 m<sup>2</sup> in the *infliximab* and standard therapy groups, respectively [P=0.005], of whom 10 were dialysis dependent) [13]. No current trials of *infliximab* in AAV are registered.

The 2005 'WGET' trial [14] also failed to show a benefit from *etanercept* for remission maintenance in 180 patients with GPA, half of whom had renal involvement (mean serum creatinine 164 versus 143  $\mu$ mol/L in treatment and control groups, respectively). No further studies have been published using this agent.

More recently, a pilot Phase 2 study of *adalimumab*, as an adjunctive induction agent in 14 patients with renal AAV (mean eGFR 17 mL/min/1.73 m<sup>2</sup>) reported similar efficacy and safety to standard care [15]. The authors suggest that this may be a viable steroid-sparing agent, but this would need to be confirmed in a larger trial.

#### Other agents

Complement antagonists: C5a, a cleavage product of C5, is a powerful anaphylatoxin and chemoattractant. The C5a

receptor, also known as CD88, is expressed on the surface of monocytes and neutrophils; its importance in the mediation of MPO-induced CGN has been demonstrated in animal studies [16]. *CCX168* is an inhibitor of C5aR/CD88, which has been found to attenuate MPO-induced CGN in mice [17]. A Phase 2 RCT of *CCX168* as a steroid-sparing agent was recently presented in abstract form [18]; results suggested superior remission induction in patients who received *CCX168*. The CLEAR trial (NCT01363388) is currently recruiting (n=60); however, patients with RPGN or eGFR <30 mL/min/1.73 m<sup>2</sup> are excluded from this study.

*Tocilizumab* is an anti-IL 6 receptor monoclonal antibody. One report of successful use of this agent in a case of MPA with RPGN has been published [19]; however, there are no trial data of its use in RPGN.

#### IgA Nephropathy/Henoch Schonlein Purpura

Some crescentic change can often occur in IgAN and Henoch Schonlein Purpura (HSPN), but this rarely results in an RPGN pattern. Significantly less common are cases of RPGN with severe crescentic change (<5% of patients), which are generally associated with a poor prognosis in small series. Previous reports have suggested a benefit from immunosuppression with glucocorticoids and cyclophosphamide [20, 21]; however, even when this regimen is used, the 1- and 5-year renal survival rates in one large contemporary series of crescentic IgAN remained low at 65% and 28%, respectively [22]. The clinical outcomes of adults with HSPN are worse than those of children [23].

#### *Mycophenolate Mofetil*

Recent publications have suggested that MMF may have a role in the treatment of proliferative IgAN. A retrospective study of 119 Chinese patients with crescentic IgAN receiving three different immunosuppressant regimens (MMF or cyclophosphamide in combination with glucocorticoids or glucocorticoids alone) concluded that the combination of MMF and glucocorticoids was associated with the most favourable renal outcome (5-year renal survival 95%, 80% and 70% for MMF/glucocorticoids, cyclophosphamide/glucocorticoids and glucocorticoids alone, respectively) [24]. Differences in disease severity, as well as treatment duration, between the MMF and cyclophosphamide groups may limit the generalisability of these findings. In addition, although all patients had evidence of CGN on renal biopsy, the mean baseline eGFR was ~90 mL/min/1.73 m<sup>2</sup>, suggesting milder renal injury. Other studies of MMF in IgAN and HSPN are limited by their retrospective nature and low proportion of patients with CGN [25].

#### *Rituximab*

There is one published report of successful use of *rituximab* in a patient with drug-induced HSP and crescentic IgAN who was resistant to glucocorticoids cyclophosphamide and plasmapheresis. Serum creatinine was 177  $\mu$ mol/L at presentation, and renal biopsy showed 38% glomeruli with crescents; following treatment with *rituximab*, serum creatinine fell to 141  $\mu$ mol/L [26].

#### Therapeutic Plasma Exchange

A case series of patients with severe HSPN (mean eGFR 67 mL/min/1.73 m<sup>2</sup>, six with endocapillary proliferation,

three with extracapillary proliferation) treated with TPE and glucocorticoids reported a response to therapy in 9 out of 11 patients [27]. After an average of 6 years follow-up, two patients died, one of whom developed ESRD. No other studies on TPE in adult HSPN have recently been published.

#### *Cyclophosphamide*

One randomised open-label trial of cyclophosphamide in HSPN has been published recently [28]. Fifty-four patients with severe HSPN were randomized to treatment with glucocorticoids alone or in combination with intravenous cyclophosphamide. 89% of patients had renal biopsies, of which 48% showed endocapillary proliferation and 33% extracapillary proliferation. Baseline eGFR was 60 and 76 mL/min/1.73 m<sup>2</sup> in the glucocorticoid-only and cyclophosphamide groups, respectively (non-significant difference). The primary end point was complete remission at 6 months (defined as BVAS 0). Improvement in renal function, renal survival and adverse events were secondary end points. There were no differences between the two groups in either primary or secondary end points (10% and 12% remission induction at 6 months in glucocorticoid and cyclophosphamide groups, respectively;  $p = 1.0$ ); one patient in each group developed ESRD during the study period. The authors concluded that the addition of cyclophosphamide provided no benefit in these patients. However, the two groups differed at baseline, with patients in the cyclophosphamide group being younger, less hypertensive and with lower disease activity than those in the steroid-only group. Additionally, the study was underpowered, with an estimated sample of 200 patients needed to detect a significant difference.

### **Anti-GBM Disease**

Anti-GBM disease is essential to diagnose and treat rapidly as more advanced disease is associated with a worse renal recovery. Standard therapy is with cyclophosphamide, glucocorticoids and TPE.

#### *Rituximab*

Evidence for the use of rituximab in the treatment of anti-GBM disease is limited to case reports. In the past 5 years, successful use of rituximab has been reported in seven cases, who were either resistant to or intolerant of conventional treatment [29–32]. Improvement in renal function has been reported in three published cases. Shah *et al.* [30] reported two cases, one of whom recovered from dialysis-dependence to a serum creatinine of 260  $\mu\text{mol/L}$  after treatment, and another whose creatinine fell from 272 to 100  $\mu\text{mol/L}$  after treatment. Bandak *et al.* [31] reported a patient who was dialysis dependent at presentation and had a serum creatinine of 182  $\mu\text{mol/L}$  after treatment.

#### *Mycophenolate Mofetil*

MMF has also been successfully used in refractory or relapsing anti-GBM disease, but the evidence base for this agent does not extend beyond single case reports [33–35].

#### *Therapeutic Plasma Exchange*

The efficacy of TPE in anti-GBM disease was first suggested by an observational study of seven patients in 1976 [36].

The largest case series of patients treated with TPE was published by Levy *et al.* [37] in 2001; these patients also received oral glucocorticoids and cyclophosphamide. More recently, a large retrospective study of 221 patients in China reported more favourable clinical outcomes in patients treated with a combination of TPE, cyclophosphamide and glucocorticoids, compared with those who received either cyclophosphamide and glucocorticoids or glucocorticoids alone [38]. There were differences between the groups at baseline, and less than half of the patients in the study underwent renal biopsy.

#### *Other Forms of Extracorporeal Blood Purification*

*Immunoadsorption* has been proposed as a more efficient method for removing anti-GBM antibodies. A case series of 10 patients reported good patient and renal survival (90% and 63%, respectively) at 1 year; the efficiency of antibody removal was superior to that typically seen in TPE, however, an average of 22 sessions per patient were required [39].

*Double-filtration plasmapheresis* (DFPP) selectively removes immunoglobulins and involves replacement of much lower volumes of plasma than standard TPE (typically 15%). A comparison of DFPP with immunoadsorption found similar patient and renal survival, and a similar efficacy of antibody removal, in 28 patients with severe anti-GBM disease in China [40].

*Combination haemodialysis and plasma exchange* offers a possible benefit of reducing therapy time and manpower in patients who require both treatment modalities due to the severity of their disease as is often seen in anti-GBM disease. The largest case series of this combination therapy was published last year [41]. This included 24 patients with anti-GBM disease and 25 with AAV, treated over an 18-year period in a single centre in Canada. Renal recovery and patient survival were comparable to previously published studies (13% and 75% for anti-GBM disease; 8% and 96% for AAV, respectively), and the safety profile was acceptable.

### **Lupus Nephritis**

RPGN occurs in a small proportion of patients with systemic lupus erythematosus (SLE) and accounts for a persistent number of patients reaching ESRD despite conventional treatment. These patients may have fewer extra-renal symptoms and more frequently are also positive for ANCA [42] and anti-C1q antibodies [43, 44].

There are many studies in progress or recently published on LN, some of which report promising findings. However, most trials specifically exclude patients with RPGN or severe renal impairment. The evidence base for this subset of patients is therefore relatively small.

A retrospective study in China examined the clinical characteristics and outcomes of 33 patients with crescentic LN, using 119 patients with non-crescentic LN as a comparator group [42]. All patients received combinations of glucocorticoids cyclophosphamide and MMF, in an uncontrolled manner. Unsurprisingly, the presence of crescents was associated with more severe renal injury, less favourable response to therapy, higher relapse rates and lower renal survival; patient survival was unaffected. Another study in China reported that renal outcomes in 620 patients with Class IV LN correlated with the percentage of histological crescents [43]. Statistical significance was not reported in this study, and treatment protocols varied.

### Rituximab

Although earlier case series and pilot studies suggested that rituximab might be effective in the treatment of LN, well-designed RCTs subsequently failed to demonstrate a benefit. The EXPLORER trial showed no benefit of rituximab over placebo in moderate-to-severe extra-renal SLE [45]. The LUNAR trial [46] of 144 patients with Class III or IV LN in the USA and Latin America who were randomized to receive either rituximab or placebo in combination with MMF and glucocorticoids also found no difference in the primary end point of renal response at 1 year. Patients with eGFR <25 mL/min/1.73 m<sup>2</sup> were excluded; mean baseline eGFR was around 90 mL/min/1.73 m<sup>2</sup>. The proportion of patients in this study with crescentic LN was not reported, but it is likely to be low.

Davies *et al.* reported a poor response to combination therapy with rituximab, low-dose intravenous cyclophosphamide and intravenous glucocorticoids in an open-label study of 18 patients with Class III–V lupus nephritis who had failed conventional therapy. Although the overall response rate was good (13 out of 18 responded by 6 months), the patients with RPGN fared relatively poorly. All four of the patients with severe proliferative crescentic LN (mean crescents 71%, mean creatinine 178 µmol/L) showed no response and rapidly progressed to ESRD [47].

A retrospective observational study of 20 patients who received rituximab for active Class III–V LN in France reported an overall renal response of 60% after a median of 22 months follow-up [48]. All patients in this study had received standard immunosuppression prior to rituximab initiation, consisting of cyclophosphamide, glucocorticoids and MMF. Renal insufficiency (eGFR <60 mL/min/1.73 m<sup>2</sup>) was present in nine patients. Three patients had evidence of RPGN. None of these patients responded to treatment: two were dialysis dependent at presentation and never recovered; one had severe renal insufficiency (eGFR 16 mL/min/1.73 m<sup>2</sup>) and progressed to ESRD 6 months after rituximab initiation.

An analysis of pooled data from patients with LN treated with rituximab across Europe found that renal impairment (defined as eGFR <60 mL/min/1.73 m<sup>2</sup>) was associated with a lower chance of achieving complete remission (15% versus 35% chance of complete recovery for eGFR below and above 60 mL/min/1.73 m<sup>2</sup>, respectively, *p* <0.05), suggesting that RPGN secondary to LN does not respond well to rituximab [49]. Patients with types III–V LN were included, but the number of patients with CGN was not reported.

In summary, there does not appear to be sufficient published evidence supporting a beneficial effect of rituximab in crescentic LN.

### Mycophenolate mofetil

A retrospective study of 52 patients in China with crescentic LN (>50% crescents on biopsy) compared the outcomes of patients treated with MMF (*n* = 27) and intravenous cyclophosphamide (*n* = 25) [50]. Both groups received pulsed glucocorticoids at induction, followed by maintenance therapy with low-dose oral prednisolone and *Tripterygium wilfordii* (a traditional Chinese herbal-derived medication). Most patients had significant renal insufficiency at baseline (two-thirds had creatinine >110 µmol/L, one-quarter >267 µmol/L). More patients in the MMF group than in the cyclophosphamide group achieved a complete remission at 12 months (54% versus 26%, *p* =

0.047), and the relapse rate in the MMF group was significantly lower than the cyclophosphamide group (11% versus 44%, significance not reported). Adjunctive therapy was not reported in this study, so it is difficult to draw firm conclusions about the relative merits of the drugs studied.

### Tacrolimus

A recent randomised trial compared induction using tacrolimus with MMF in 150 patients with Class III–V LN who also received glucocorticoids. Complete renal remission and a composite outcome of chronic kidney disease (Stage 4–5), reduction of creatinine clearance by 30% or death, were equal in the two arms. However, patients were excluded if creatinine was >200 µmol/L [51]. Morimoto *et al.* [52] reported a case of LN and RPGN with 39% crescents, in association with an MPO-ANCA, who received limited treatment with cyclophosphamide and azathioprine due to adverse effects. The patient went on to receive glucocorticoids and tacrolimus, and successful disease remission was achieved. In a randomised trial comparing intravenous cyclophosphamide and steroids with combined treatment of MMF, tacrolimus and glucocorticoids in LN, there was a greater number of patients achieving complete remission at 6 months in the combination group; however, patients with serum creatinine >265 µmol/L were excluded [53]. One patient with crescentic LN (61% crescents) was separately reported to have successfully entered remission using this multi-targeted approach [54].

### Ocrelizumab

Ocrelizumab is an anti-CD20 monoclonal antibody with some evidence of efficacy in rheumatoid arthritis. A placebo-controlled trial of its use in type III–V LN was terminated early due to serious infections in the intervention arm; outcome data did not demonstrate a clear benefit of this agent [55]. Patients with severe renal impairment (eGFR <25 mL/min/1.73 m<sup>2</sup>) were excluded from this study. It is unlikely that this agent will have a role in the treatment of crescentic LN.

### Belimumab

Belimumab is an anti-soluble B-lymphocyte stimulator, which has been shown to be effective in two large RCT's of extra-renal SLE (BLISS-52 [56] and BLISS-76 [57]). Patients with active severe LN were excluded from these studies. An RCT of this agent in active LN is currently underway (NCT01639339). This study may include some patients with RPGN; patients requiring dialysis are excluded. A safety and efficacy study of the addition of belimumab to rituximab and cyclophosphamide in active proliferative LN has recently commenced (NCT02260934); patients with eGFR <20 mL/min/1.73 m<sup>2</sup> are excluded.

## Potential novel uses of current drugs for treatment of RPGN

*Fostamatinib* is a spleen tyrosine kinase inhibitor, which blocks intracellular signalling and Fc receptor activation. There is some evidence of benefit from this agent in rheumatoid arthritis. Experimental evidence has shown that the agent can completely prevent induction of anti-GBM disease, and delayed administration results in cessation of autoantibody production, reversal of renal injury

and prevention of pulmonary haemorrhage. The benefit is believed to be mediated by impaired activity of antigen-specific B cells, as well as effects on cell-mediated immunity [58, 59]. A Phase 2 trial of treatment for IgAN commenced in 2014; however, patients with RPGN are excluded (NCT02112838).

*Imatinib* is a tyrosine kinase inhibitor with specificity for c-Abl, c-Kit and platelet-derived growth factor receptors, which is used in the treatment of certain leukaemias and GIST tumours. Delayed administration has been shown to attenuate acute injury and chronic damage in experimental anti-GBM disease [60, 61]. It may exert its beneficial effect by targeting activated parietal epithelial cells as well as monocytes/macrophages. A single case report of its successful use in type 2 cryoglobulinaemia with membranoproliferative glomerulonephritis (MPGN) has been published (peak creatinine 248  $\mu\text{mol/L}$ , final creatinine 133  $\mu\text{mol/L}$ ) [62], but no trials are registered for its use in RPGN.

*Bortezomib* (velcade) is a protease inhibitor, which targets plasmablasts and mature plasma cells. It has established use in myeloma and has been shown to be effective in murine models of LN and MPO-associated NCGN [63]. A pilot study of the use of this agent in severe IgAN is underway in the USA (NCT01103778). The potential benefit of other protease inhibitors in autoantibody-mediated diseases, such as SLE, is also being tested.

*Erlotinib* is an epithelial growth factor receptor (EGFR) tyrosine kinase inhibitor used for the treatment of various malignancies. Podocyte and parietal epithelial cell EGFR expression is augmented in human and murine CGN [64, 65]. Delayed administration of erlotinib attenuates renal injury in an experimental mouse model of anti-GBM disease [66]. There are no trials registered for RPGN, but this may represent a promising agent.

*Eculizumab* is a monoclonal antibody that blocks cleavage of C5 to C5a, reducing complement activation via the alternative pathway. It has been shown to be effective in the treatment of atypical HUS and paroxysmal nocturnal haemoglobinuria, conditions characterised by inappropriate activation of the complement system. It has been proposed that it may also benefit patients with IgAN [67] or immune complex disease; however, there are no trials registered for this use at present.

## Future potential therapies

### *Programmed Death-1 Receptor*

The programmed death-1 (PD-1) receptor is a member of CD28 family, which is preferentially expressed on activated T-cells and is important in the maintenance of tolerance. PD-1 stimulation causes reduced proliferation and cytokine expression. Delayed stimulation using a PDL-1/Fc fusion protein attenuates a rat anti-GBM model by inhibiting cell-mediated immunity only, with no effect on antibody production or glomerular IgG deposition [68]. No PD-1 agonists are currently available for clinical use.

### *C-jun Amino Terminal Kinase (JNK) Signalling*

Macrophage JNK signalling is thought to play a pathogenic role in anti-GBM disease [69]. Administration of a JNK

inhibitor on Day 7–24 attenuates experimental anti-GBM disease via a mechanism independent of humoral immunity [70]. Early dose-finding studies are underway at present.

### *Seleiclib (Roscovitine)*

Seleiclib is a cyclin-dependent kinase inhibitor with evidence for a beneficial role in various animal models of GN (MPGN, membranous nephropathy, LN). It attenuates rat anti-GBM when used as treatment, possibly by influencing glomerular macrophage infiltration [76].

### *Stem Cell Therapy*

Stem cell therapy is at an early phase of development, but it may offer a future therapeutic strategy in immune-mediated renal disease (reviewed in [71]). There is some experimental evidence in animal models of anti-GBM disease, where investigators have used mesenchymal stem cells, which are progenitors of renal tissue, with some success [72–74]. A case of NCGN due to MPA successfully treated with stem cell therapy has been reported [75]. The patient's serum creatinine peaked at 690  $\mu\text{mol/L}$ ; standard therapy with cyclophosphamide and glucocorticoids was ineffective, and rituximab was not tolerated; following treatment with autologous mesenchymal stem cells, the patient's creatinine fell to 168  $\mu\text{mol/L}$  in parallel with a reduction in the ANCA titre.

In summary, several novel targets and potential therapeutic agents show some promise for the treatment of CGN, but their clinical role is yet to be determined.

## Conclusions

Although there is a paucity of randomised trial data, the role of commonly used immunosuppressant agents in CGN is becoming clearer. Publication bias and the rarity of the diseases involved mean that international collaborations and sharing of data using clinical registries are essential for the clinical and academic communities to increase understanding and refine therapeutic protocols. Advances in our understanding of the pathogenesis of various forms of CGN have led to the discovery of novel therapeutic targets, and the use of agents already established for the treatment of other diseases shows some promise; however, we are some way from the widespread clinical implementation of these treatments. The results of early clinical trials of newer agents, as well as larger multi-centre trials designed to clarify the role of established therapies such as TPE are eagerly awaited.

*Conflict of interest statement.* None declared.

## References

1. Stone JH, Merkel PA, Spiera R *et al.* Rituximab versus cyclophosphamide for ANCA-associated vasculitis. *N Engl J Med* 2010; 363: 221–232
2. Jones RB, Tervaert JWC, Hauser T *et al.* Rituximab versus cyclophosphamide in ANCA-associated renal vasculitis. *N Engl J Med* 2010; 363: 211–220
3. Geetha D, Specks U, Stone JH *et al.* (November 7, 2014) Rituximab versus cyclophosphamide for ANCA-associated vasculitis

- with renal involvement. *J Am Soc Nephrol*, doi:10.1681/ASN.2014010046
4. Hu W, Liu C, Xie H et al. Mycophenolate mofetil versus cyclophosphamide for inducing remission of ANCA vasculitis with moderate renal involvement. *Nephrol Dial Transplant* 2008; 23: 1307–1312
  5. Silva F, Specks U, Kalra S et al. Mycophenolate mofetil for induction and maintenance of remission in microscopic polyangiitis with mild to moderate renal involvement—a prospective, open-label pilot trial. *Clin J Am Soc Nephrol* 2010; 5: 445–453
  6. Han F, Liu G, Zhang X et al. Effects of mycophenolate mofetil combined with corticosteroids for induction therapy of microscopic polyangiitis. *Am J Nephrol* 2011; 33: 185–192
  7. Jones R, Harper L, Ballarin J et al. A randomized trial of mycophenolate mofetil versus cyclophosphamide for remission induction of ANCA-associated vasculitis: ‘MYCYC’. On behalf of the European vasculitis study group. *Presse Med* 2013; 42: 678–679
  8. Jayne DRW, Gaskin G, Rasmussen N et al. Randomized trial of plasma exchange or high-dosage methylprednisolone as adjunctive therapy for severe renal vasculitis. *J Am Soc Nephrol* 2007; 18: 2180–2188
  9. Walsh M, Casian A, Flossmann O et al. Long-term follow-up of patients with severe ANCA-associated vasculitis comparing plasma exchange to intravenous methylprednisolone treatment is unclear. *Kidney Int* 2013; 84: 397–402
  10. Walsh M, Catapano F, Szpirt W et al. Plasma exchange for renal vasculitis and idiopathic rapidly progressive glomerulonephritis: a meta-analysis. *Am J Kidney Dis* 2011; 57: 566–574
  11. Walsh M, Merkel PA, Peh CA et al. Plasma exchange and glucocorticoid dosing in the treatment of anti-neutrophil cytoplasm antibody associated vasculitis (PEXIVAS): protocol for a randomized controlled trial. *Trials* 2013; 14: 73
  12. Booth A, Harper L, Hammad T et al. Prospective study of TNFalpha blockade with infliximab in anti-neutrophil cytoplasmic antibody-associated systemic vasculitis. *J Am Soc Nephrol* 2004; 15: 717–721
  13. Morgan MD, Drayson MT, Savage COS et al. Addition of infliximab to standard therapy for ANCA-associated vasculitis. *Nephron Clin Pract* 2011; 117: c89–c97
  14. The Wegener’s Granulomatosis Etanercept Trial (WGET) Research Group. Etanercept plus standard therapy for Wegener’s granulomatosis. *N Engl J Med* 2005; 352: 351–361
  15. Laurino S, Chaudhry A, Booth A et al. Prospective study of TNFalpha blockade with adalimumab in ANCA-associated systemic vasculitis with renal involvement. *Nephrol Dial Transplant* 2010; 25: 3307–3314
  16. Schreiber A, Xiao H, Jennette JC et al. C5a receptor mediates neutrophil activation and ANCA-induced glomerulonephritis. *J Am Soc Nephrol* 2009; 20: 289–298
  17. Xiao H, Dairaghi DJ, Powers JP et al. C5a receptor (CD88) blockade protects against MPO-ANCA GN. *J Am Soc Nephrol* 2014; 25: 225–231
  18. Jayne DR, Bruchfeld A, Schaier M et al. OP0227 oral C5a receptor antagonist CCX168 Phase 2 clinical TRIAL in ANCA-associated renal vasculitis. *Ann Rheum Dis* 2014; 73: 148
  19. Sumida K, Ubara Y, Suwabe T et al. Complete remission of myeloperoxidase-anti-neutrophil cytoplasmic antibody-associated crescentic glomerulonephritis complicated with rheumatoid arthritis using a humanized anti-interleukin 6 receptor antibody. *Rheumatol* 2011; 50: 1928–1930
  20. Tumlin JA, Lohavichan V, Hennigar R. Crescentic, proliferative IgA nephropathy: clinical and histological response to methylprednisolone and intravenous cyclophosphamide. *Nephrol Dial Transplant* 2003; 18: 1321–1329
  21. McIntyre CW, Fluck RJ, Lambie SH. Steroid and cyclophosphamide therapy for IgA nephropathy associated with crescentic change: an effective treatment. *Clin Nephrol* 2001; 56: 193–198
  22. Lv J, Yang Y, Zhang H et al. Prediction of outcomes in crescentic IgA nephropathy in a multicenter cohort study. *J Am Soc Nephrol* 2013; 24: 2118–2125
  23. Coppo R, Andrulli S, Amore A et al. Predictors of outcome in Henoch-Schönlein nephritis in children and adults. *Am J Kidney Dis* 2006; 47: 993–1003
  24. Yan L, Junjun Z, Dongwei L et al. Retrospective study of mycophenolate mofetil treatment in IgA nephropathy with proliferative pathological phenotype. *Chin Med J (Engl)* 2014; 127: 102–108
  25. Ren P, Han F, Chen L et al. The combination of mycophenolate mofetil with corticosteroids induces remission of Henoch-Schönlein purpura nephritis. *Am J Nephrol* 2012; 36: 271–277
  26. El-Husseini A, Ahmed A, Sabucedo A et al. Refractory Henoch-Schönlein purpura: atypical aetiology and management. *J Ren Care* 2013; 39: 77–81
  27. Augusto J-F, Sayegh J, Delapierre L et al. Addition of plasma exchange to glucocorticosteroids for the treatment of severe Henoch-Schönlein purpura in adults: a case series. *Am J Kidney Dis* 2012; 59: 663–669
  28. Pillebout E, Alberti C, Guillevin L et al. Addition of cyclophosphamide to steroids provides no benefit compared with steroids alone in treating adult patients with severe Henoch-Schönlein Purpura. *Kidney Int* 2010; 78: 495–502
  29. Syeda UA, Singer NG, Magrey M. Anti-glomerular basement membrane antibody disease treated with rituximab: a case-based review. *Semin Arthritis Rheum* 2013; 42: 567–572
  30. Shah Y, Mohiuddin A, Sluman C et al. Rituximab in anti-glomerular basement membrane disease. *QJM* 2012; 105: 195–197
  31. Bandak G, Jones BA, Li J et al. Rituximab for the treatment of refractory simultaneous anti-glomerular basement membrane (anti-GBM) and membranous nephropathy. *Clin Kidney J* 2014; 7: 53–56
  32. Schless B, Yildirim S, Beha D et al. Rituximab in two cases of Goodpasture’s syndrome. *NDT Plus* 2009; 2: 225–227
  33. Mori M, Nwaogwugwu U, Akers GR et al. Anti-glomerular basement membrane disease treated with mycophenolate mofetil, corticosteroids, and plasmapheresis. *Clin Nephrol* 2013; 80: 67–71
  34. Malho A, Santos V, Cabrita A et al. Severe relapsing Goodpasture’s disease successfully treated with Mycophenolate Mofetil. *Int J Nephrol* 2010; doi: 10.4061/2010/383548
  35. Kiykim AA, Horoz M, Gok E. Successful treatment of resistant antiglomerular basement membrane antibody positivity with mycophenolic acid. *Intern Med* 2010; 49: 577–580
  36. Lockwood CM, Rees AJ, Pearson TA et al. Immunosuppression and plasma-exchange in the treatment of Goodpasture’s syndrome. *Lancet* 1976; 1: 711–715
  37. Levy J, Turner A. Long-term outcome of anti-glomerular basement membrane antibody disease treated with plasma exchange and immunosuppression. *Ann Intern* 2001; 134: 1033–1042
  38. Cui Z, Zhao J, Jia X et al. Anti-glomerular basement membrane disease: outcomes of different therapeutic regimens in a large single-center Chinese cohort study. *Medicine (Baltimore)* 2011; 90: 303–311
  39. Biesenbach P, Kain R, Derfler K et al. Long-term outcome of anti-glomerular basement membrane antibody disease treated with immunoadsorption. *PLoS ONE* 2014; 9: e103568
  40. Zhang Y, Tang Z, Chen D et al. Comparison of double filtration plasmapheresis with immunoadsorption therapy in patients with anti-glomerular basement membrane nephritis. *BMC Nephrol* 2014; 15: 128
  41. Farah M, Levin A, Kiaii M et al. Combination hemodialysis and centrifugal therapeutic plasma exchange: 18 years of Canadian experience. *Hemodial Int* 2013; 17: 256–265

42. Yu F, Tan Y, Liu G *et al.* Clinicopathological characteristics and outcomes of patients with crescentic lupus nephritis. *Kidney Int* 2009; 76: 307–317
43. Chen S, Tang Z, Zhang Y *et al.* Significance of histological crescent formation in patients with diffuse proliferative lupus nephritis. *Am J Nephrol* 2014; 38: 445–452
44. Jourde-Chiche N, Daniel L, Chiche L *et al.* Association between anti-C1q antibodies and glomerular tuft necrosis in lupus nephritis. *Clin Nephrol* 2012; 77: 211–218
45. Merrill JT, Neuwelt CM, Wallace DJ *et al.* Efficacy and safety of rituximab in moderately-to-severely active systemic lupus erythematosus: the randomized, double-blind, phase II/III systemic lupus erythematosus evaluation of rituximab trial. *Arthritis Rheum* 2010; 62: 222–233
46. Rovin BH, Furie R, Latinis K *et al.* Efficacy and safety of rituximab in patients with active proliferative lupus nephritis: the Lupus Nephritis Assessment with Rituximab study. *Arthritis Rheum* 2012; 64: 1215–1226
47. Davies RJ, Sangle SR, Jordan NP *et al.* Rituximab in the treatment of resistant lupus nephritis: therapy failure in rapidly progressive crescentic lupus nephritis. *Lupus* 2013; 22: 574–582
48. Melander C, Sallee M, Trolliet P *et al.* Rituximab in severe lupus nephritis: early B-cell depletion affects long-term renal outcome. *Clin J Am Soc Nephrol* 2009; 4: 579–587
49. Díaz-Lagares C, Croca S, Sangle S *et al.* Efficacy of rituximab in 164 patients with biopsy-proven lupus nephritis: pooled data from European cohorts. *Autoimmun Rev* 2012; 11: 357–364
50. Tang Z, Yang G, Yu C *et al.* Effects of mycophenolate mofetil for patients with crescentic lupus nephritis. *Nephrology (Carlton)* 2008; 13: 702–707
51. Mok CC, Ying KY, Yim CW *et al.* (December 30, 2014) Tacrolimus versus mycophenolate mofetil for induction therapy of lupus nephritis: a randomised controlled trial and long-term follow-up. *Ann Rheum Dis*, doi: 10.1136/annrheumdis-2014-206456
52. Morimoto S, Watanabe T, Lee S *et al.* Improvement of rapidly progressive lupus nephritis associated MPO-ANCA with tacrolimus. *Mod Rheumatol* 2010; 20: 291–294
53. Liu Z, Zhang H, Liu Z *et al.* Multitarget therapy for induction treatment of lupus nephritis: a randomized trial. *Ann Intern Med* 2015; 162: 18–26
54. Mochizuki K, Kayakabe K, Hiromura K *et al.* Successful treatment of severe crescentic lupus nephritis by multi-target therapy using tacrolimus and mycophenolate mofetil. *CEN Case Reports* 2014; doi: 10.1007/s13730-014-0151-0
55. Mysler EF, Spindler AJ, Guzman R *et al.* Efficacy and safety of ocrelizumab in active proliferative lupus nephritis: results from a randomized, double-blind, phase III study. *Arthritis Rheum* 2013; 65: 2368–2379
56. Navarra SV, Guzmán RM, Gallacher AE *et al.* Efficacy and safety of belimumab in patients with active systemic lupus erythematosus: a randomised, placebo-controlled, phase 3 trial. *Lancet* 2011; 377: 721–731
57. Furie R, Petri M, Zamani O *et al.* A phase III, randomized, placebo-controlled study of belimumab, a monoclonal antibody that inhibits B lymphocyte stimulator, in patients with systemic lupus erythematosus. *Arthritis Rheum* 2011; 63: 3918–3930
58. Smith J, McDaid JP, Bhangal G *et al.* A spleen tyrosine kinase inhibitor reduces the severity of established glomerulonephritis. *J Am Soc Nephrol* 2010; 21: 231–236
59. McAdoo SP, Reynolds J, Bhangal G *et al.* Spleen tyrosine kinase inhibition attenuates autoantibody production and reverses experimental autoimmune GN. *J Am Soc Nephrol* 2014; 25: 2291–2302
60. Iyoda M, Shibata T, Kawaguchi M *et al.* Preventive and therapeutic effects of imatinib in Wistar-Kyoto rats with anti-glomerular basement membrane glomerulonephritis. *Kidney Int* 2009; 75: 1060–1070
61. Iyoda M, Shibata T, Wada Y *et al.* Long- and short-term treatment with imatinib attenuates the development of chronic kidney disease in experimental anti-glomerular basement membrane nephritis. *Nephrol Dial Transplant* 2013; 28: 576–584
62. Wallace E, Fogo AB, Schulman G. Imatinib therapy for non-infection-related type II cryoglobulinemia with membranoproliferative glomerulonephritis. *Am J Kidney Dis* 2012; 59: 122–125
63. Bontscho J, Schreiber A, Manz RA *et al.* Myeloperoxidase-specific plasma cell depletion by bortezomib protects from anti-neutrophil cytoplasmic autoantibodies-induced glomerulonephritis. *J Am Soc Nephrol* 2011; 22: 336–348
64. Henique C, Tharoux P-L. Targeting signaling pathways in glomerular diseases. *Curr Opin Nephrol Hypertens* 2012; 21: 417–427
65. Flamant M, Bollée G, Hénique C *et al.* Epidermal growth factor: a new therapeutic target in glomerular disease. *Nephrol Dial Transplant* 2012; 27: 1297–1304
66. Bollée G, Flamant M, Schordan S *et al.* Epidermal growth factor receptor promotes glomerular injury and renal failure in rapidly progressive crescentic glomerulonephritis. *Nat Med* 2011; 17: 1242–1250
67. Davin J-C. Henoch-Schönlein purpura nephritis: pathophysiology, treatment, and future strategy. *Clin J Am Soc Nephrol* 2011; 6: 679–689
68. Reynolds J, Sando GS, Marsh OB *et al.* Stimulation of the PD-1/PDL-1 T-cell co-inhibitory pathway is effective in treatment of experimental autoimmune glomerulonephritis. *Nephrol Dial Transplant* 2012; 27: 1343–1350
69. Flanc RS, Ma FY, Tesch GH *et al.* A pathogenic role for JNK signaling in experimental anti-GBM glomerulonephritis. *Kidney Int* 2007; 72: 698–708
70. Ma FY, Flanc RS, Tesch GH *et al.* Blockade of the c-Jun amino terminal kinase prevents crescent formation and halts established anti-GBM glomerulonephritis in the rat. *Lab Invest* 2009; 89: 470–484
71. Jin M, Xie Y, Li Q *et al.* Stem cell-based cell therapy for glomerulonephritis. *Biomed Res Int* 2014; 2014: 124730
72. Huang Z-Y, Hong L-Q, Na N *et al.* Infusion of mesenchymal stem cells overexpressing GDNF ameliorates renal function in nephrotoxic serum nephritis. *Cell Biochem Funct* 2012; 30: 139–144
73. Furuhashi K, Tsuboi N, Shimizu A *et al.* Serum-starved adipose-derived stromal cells ameliorate crescentic GN by promoting immunoregulatory macrophages. *J Am Soc Nephrol* 2013; 24: 587–603
74. Li Y, Yan M, Yang J *et al.* Glutathione S-transferase Mu 2-transduced mesenchymal stem cells ameliorated anti-glomerular basement membrane antibody-induced glomerulonephritis by inhibiting oxidation and inflammation. *Stem Cell Res Ther* 2014; 5: 19
75. Gregorini M, Maccario R, Avanzini MA *et al.* Antineutrophil cytoplasmic antibody-associated renal vasculitis treated with autologous mesenchymal stromal cells: evaluation of the contribution of immune-mediated mechanisms. *Mayo Clin Proc* 2013; 88: 1174–1179
76. Sheryanna AM, Smith J, Bhangal G *et al.* Treatment with a cyclin-dependent kinase inhibitor, seliciclib, is effective in reducing glomerular macrophage numbers and the severity of established experimental glomerulonephritis. *Nephrology (Carlton)* 2011; 16: 410–416