

CASE REPORT

Trauma

Pseudo-acute kidney injury after minor trauma: A case report and review of literature

Diana Cheung MD¹  | Christophe de Terwangne MD² | Miguel-Ange Guillen MD³ | Antonio Sorgente MD, PhD⁴ | Assma Ballout MD¹ | Jean-Marie Jacques MD¹

¹ Department of Emergency Medicine, Epicura Centre Hospitalier, Brussels, Belgium

² Department of Internal Medicine, Epicura Centre Hospitalier, Brussels, Belgium

³ Department of Nephrology, Epicura Centre Hospitalier, Brussels, Belgium

⁴ Department of Cardiology, Epicura Centre Hospitalier, Brussels, Belgium

Correspondence

Diana Cheung, MD, Department of Emergency Medicine, Epicura Centre Hospitalier, B7301 Hornu (Boussu), Belgium.
Email: drcheungdiana@gmail.com

Diana Cheung and Christophe de Terwangne are first authors as they participated equally in elaborating this case report.

Funding and support: By *JACEP Open* policy, all authors are required to disclose any and all commercial, financial, and other relationships in any way related to the subject of this article as per ICMJE conflict of interest guidelines (see www.icmje.org). The authors have stated that no such relationships exist.

Abstract

Acute kidney injury (AKI), a common diagnosis in the emergency department, is defined as a reduction in renal filtration function, with decrease in urine output, increase in serum creatinine, or both. However, a rise in serum creatinine can occur without AKI: the principal cause of a pseudo-AKI is urinary ascites, caused by urinary tract rupture, followed by reverse intraperitoneal dialysis and resorption of creatinine. The intraperitoneal leak of free urine is mainly traumatic, and half of the cases are iatrogenic. A case of intraperitoneal bladder rupture after minor trauma is presented with a review of the pathology of pseudo-AKI.

KEYWORDS

acute kidney injury, bladder injury, emergency department, pseudo-acute kidney injury, reverse autodialysis, urinary ascites

1 | INTRODUCTION

Acute kidney injury (AKI), which is a common diagnosis in the emergency department, is defined as a reduction in renal filtration function, with a decrease in urine output, increase in serum creatinine, or both. The etiologies are multiple, including trauma.

However, a rise in serum creatinine can occur without AKI and has been previously defined as pseudo-AKI. Pseudo-AKI is caused by urinary tract rupture, which produces urinary ascites, and is followed by reverse intraperitoneal (IP) dialysis and resorption of creatinine.¹

The IP leak of free urine is mainly traumatic, and half of the cases are iatrogenic.¹

Pseudo-AKI, infrequent and less known by the emergency physician, may delay the diagnosis and therefore its management. The emergency physician must consider pseudo-AKI in the case of bladder rupture attributed to trauma.

A case of IP bladder rupture after minor trauma is presented with a review of the pathology of pseudo-AKI.

2 | CASE REPORT

A 40-year-old male patient was admitted to the emergency department with a history of gross hematuria and mictalgia. His only comorbid medical condition was untreated pulmonary sarcoidosis.

Supervising Editor: David Wampler, PhD, LP.

This is an open access article under the terms of the [Creative Commons Attribution-NonCommercial-NoDerivs](https://creativecommons.org/licenses/by-nc-nd/4.0/) License, which permits use and distribution in any medium, provided the original work is properly cited, the use is non-commercial and no modifications or adaptations are made.

© 2021 The Authors. *JACEP Open* published by Wiley Periodicals LLC on behalf of American College of Emergency Physicians

TABLE 1 Blood test results

	Day 0	Day 1	Day 2	Day 30
Blood				
Creatinine (mg/dL)	1.76	3.61	1.01	0.85
Urea (mg/dL)	26	45	19	15
C-reactive protein (mg/L)	7.30	76.3	77.1	67.90
Hemoglobin (g/dL)	14.6	14.5	13.9	13.1
WBC($10^3/mm^3$)	13 670	12 610	9490	3430
Neutrophils ($10^3/mm^3$)	12 860	11 560	8220	2280
Lymphocytes ($10^3/mm^3$)	340	380	640	630
Potassium (mmol/L)	5.2	4.93	4.12	4.29
Bicarbonate (mmol/L)	21	23	24	
Calcium (mmol/L)		2.38	2.35	
Urine				
RBC($/\mu L$)	>1600	100	Not tested	Not tested
WBC ($/\mu L$)	20	0		
Protein	Negative	Negative		

On admission, the patient was fully conscious and reported hematuria that had started in the morning, which was associated with pain during voiding. He related having a party the night before and remembered stumbling and falling on the street while walking home. He reported neither head trauma nor abdominal trauma. Regular drug intake was limited to benzodiazepine when needed, and his alcohol consumption was not regular.

During the examination, the patient was in good general condition. He was afebrile with stable vital parameters. Abdominal examination revealed neither hematoma nor distension, but there was suprapubic tenderness. Blood investigations revealed a serum creatinine of 1.76 mg/dL without anemia, liver dysfunction, or electrolyte abnormalities. A urine sample confirmed massive hematuria (Table 1).

The patient underwent a plain computerized tomography (CT) scan of the abdomen, without contrast. There was neither urolithiasis nor hydronephrosis, but there was right anterolateral abdominal infiltration related to the wall of the bladder, with a thin layer of perihepatic fluid (10 Hounsfield units). This was also confirmed by an abdominal ultrasound. Because of the limited amount of fluid, paracentesis was not performed.

Repeat serum creatinine sampling the following day showed significant deterioration (3.61 mg/dL) and decreased estimated glomerular filtration rate. Other findings included normal hemoglobin coagulation profiles (Table 1).

A retrograde cystogram (Figure 1) was performed, and bladder rupture was diagnosed along with a peritoneal urinary leak. The diagnosis of pseudo-AKI with peritoneal retrodialysis was retained.

3 | DISCUSSION

Commonly, serum creatinine is used as an indicator of kidney function because of its stability and unchanged renal excretion, although

a rise in serum creatinine without AKI is possible. Some medications can decrease creatinine excretion (eg, cimetidine, trimethoprim, dronedarone). Creatine supplement consumption, some molecules (eg, acetoacetate in diabetic ketoacidosis), or drugs (eg, dexamethasone, historically cephalosporins) can interfere with creatinine assays, resulting in false elevations in serum creatinine.²

The most common cause is creatinine resorption from intraperitoneal urinary ascites, which occurs after upper or lower urinary tract rupture, mainly bladder rupture. Bladder rupture is classified as either extraperitoneal (EP) or intraperitoneal (IP); $\approx 60\%$ are extraperitoneal bladder injury, 30% are intraperitoneal bladder injury, and 10% are extra and intra peritoneal injury.³

EP bladder rupture is usually associated with pelvic fracture and is most often a direct result of a deceleration injury and fluid inertia coupled with the shearing force created by pelvic ring deformation. IP bladder rupture generally occurs as a result of a direct blow to a distended urinary bladder. These lesions are more common in alcoholics and after seatbelt or steering wheel trauma.⁴ An empty bladder is protected behind the pelvic bone, but once distended, intravesical pressure rises, and the bladder increases in size until reaching the level of the umbilicus, exposing an area of fragility, the dome.³⁻⁵ Previous bladder pathologies, such as pelvic radiotherapy; bladder cancer; bladder surgery; neurogenic bladder; and bladder diverticulum or bladder infections are risk factors because areas of scarring are weakened and prone to rupture.^{3,5,6}

Binge alcohol drinkers are particularly vulnerable to bladder rupture. Alcohol decreases the sensation of voiding and has a diuretic effect. This causes wall distention and weakening of the bladder walls, which could lead to bladder rupture, spontaneously or after minor trauma.⁵

Pseudo-AKI appears within 24 hours of IP bladder ruptures and relies on the concept of reverse autodialysis of the peritoneal membrane. Urinary concentrations of creatinine are from 30 to 100 times higher than the blood concentration of creatinine.⁷ In the event of a rupture of the urinary tract in the peritoneum or retroperitoneum, the difference in concentration between the urine and blood plasma will allow a significant diffusion of creatinine into the bloodstream. This increase in creatinine is not secondary to a defect in renal function but to this reverse osmosis effect. Blood values of creatinine, urea, and potassium will then elevate, erroneously suggesting acute renal failure. This can be reversed in 24 to 48 hours after drainage of the urinary ascites.^{3,5,8,9}

A clinical triad including suprapubic pain, inability to void, and gross hematuria is usually suggestive of bladder rupture. Gross hematuria is a cardinal clinical sign that is present in 77% to 100% of patients with this diagnosis.^{3,4} Furthermore, clinical examination can also reveal suprapubic tenderness, ileus, absence of bowel sounds, and abdominal distension. For the patients with pelvic ring fractures, a bladder or urethral injury must be evoked and excluded if necessary. Delayed diagnosis of bladder rupture can lead to life-threatening complications, such as major electrolyte disturbances, abdominal sepsis, and peritonitis.⁶

Through paracentesis, the analysis of non-hemorrhagic intra-abdominal fluid can orient to the diagnosis of bladder rupture. An

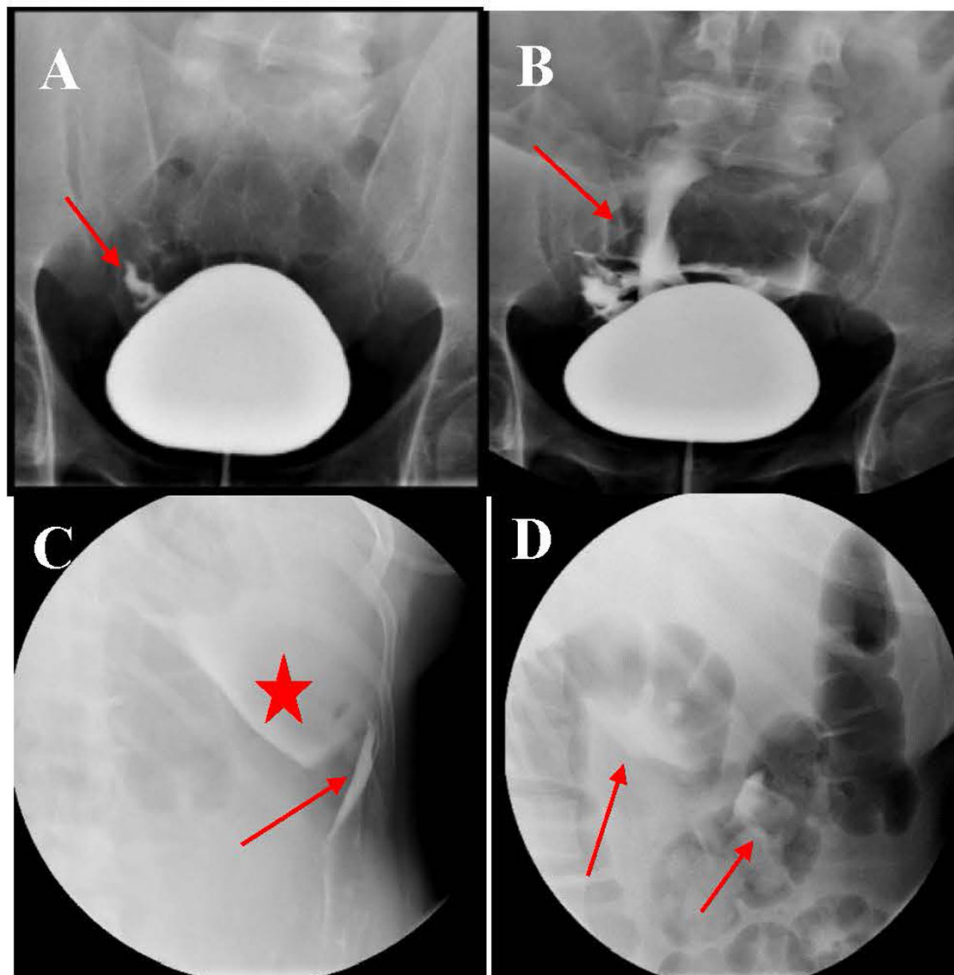


FIGURE 1 Retrograde cystography. (A and B) Frontal view of retrograde cystography of a full bladder. The arrow points to the contrast leaking out of the bladder's dome. (C) Anterior view centered on the left hypochondrium. Contrast material surrounding the spleen is shown by the star. The arrow indicates contrast in the left paracolic gutter. (D) Digestive tract view. The arrow marks the contrast surrounding the bowel loops. The presence of a large amount of the contrast in the peritoneum is suggestive of intraperitoneal bladder rupture

ascites serum creatinine ratio >1 is suggestive of an IP urinary leak.^{10,11}

Beside gross hematuria, a urinalysis can give other clues as to possible bladder rupture. Indeed, the detection of mesothelial cells strongly suggests existence of bladder trauma (specific request to the laboratory).¹² Furthermore, in physiological situations, the ratio of urinary creatinine to serum creatinine concentration is between 30:1 and 100:1,⁷ but in case of peritoneal resorption, this ratio may be reduced.

The gold standard for a high-risk trauma patient, especially in unstable patients, is a contrast-enhanced whole-body CT for the identification of injuries. This is often the first test performed.⁴

A retrograde cystography is the most sensitive exam for identifying bladder perforation.⁶ Indeed, a normal cystographic phase on a standard excretory urogram or a standard contrast-enhanced CT, with only passive bladder filling through catheter clamping, is not sufficient to exclude a bladder injury. During retrogradecystography, the bladder is filled with contrast via a urethral catheter, and the

volume infused increases the intravesical pressure to visualize the leak.^{3,4,6}

Udekwi et al suggest that bladder ruptures should be considered in the differential diagnosis of patients presenting with acute abdominal pain and attenuation values of ascites of <10 Hounsfield units, distinct from hemorrhagic liquid (≈ 45 Hounsfield units).¹³

The American Urological Association guidelines recommend all IP bladder ruptures and complicated EP bladder ruptures be treated by surgical intervention. Uncomplicated EP bladder ruptures, however, could be managed conservatively by urinary catheter for 3 weeks. Yet, if after 4 weeks the injury persists, it is recommended to consider surgical repair.⁴

In the conservative treatment, urinary antibiotic prophylaxis should be administered until closure of the perforation is confirmed by enhanced retrograde cystography. The follow-up is ensured by regular cystography.⁴

In our case, the diagnosis of an IP bladder rupture was delayed because of non-specific symptoms as well as a vague recollection of the

events taking place during the day of the accident because of alcohol intake. A nephrologist's consultation raised the suspicion, and a retrograde cystogram confirmed the IP bladder rupture.

The clinical evolution of our patient was favorable with conservative treatment (urinary catheter for 3 weeks) despite the IP leakage. Other cases have reported the success of conservative treatment of IP bladder lesions.¹⁴

4 | WHY SHOULD AN EMERGENCY PHYSICIAN BE AWARE OF THIS?

Bladder rupture must be considered in case of a patient with ascites, macroscopic hematuria after a traumatic event, and biologic anomalies suggesting AKI, especially with risk factors. Once the most frequent etiologies of AKI have been excluded (eg, hemorrhagic shock, abdominal compartment syndrome, multiple organic injury), the emergency physician should consider possible false renal failure (pseudo-AKI). Indeed, the presence of urine in the peritoneal cavity leads to a reversed IP autodialysis phenomenon caused by the reabsorption of creatinine in the peritoneum, which in turn increases serum creatinine without any renal injury.

Once bladder rupture is suspected, retrograde cystography should be performed to confirm the diagnosis. Depending on the classification of the rupture (IP or EP), the treatment can be either surgical or conservative.

Pseudo-AKI is a rare entity but should be kept in mind to avoid traps and further unnecessary investigations.

ACKNOWLEDGMENT

The authors warmly thank Dr. Jacques for his support, knowledge, and medical corrections.

CONFLICT OF INTEREST

The authors declare no conflict of interest.

ORCID

Diana Cheung MD  <https://orcid.org/0000-0001-5305-1838>

REFERENCES

1. Mirza R, Wong EK, Yang R, Clase C. Abdominal pain, hyperkalemia, and elevated creatinine after blunt trauma: bladder rupture and pseudo-acute-kidney-injury. *Can J Gen Intern Med*. 2018;13(2).
2. Samra M, Abcar AC. False estimates of elevated creatinine. *Perm J*. 2012;16(2):51-52.
3. Barnard J, Overholt T, Hajiran A, et al. Traumatic bladder ruptures: a ten-year review at a level 1 trauma center. *Adv Urol*. 2019;2019:2614586.
4. Simon LV, Sajjad H, Lopez RA, Burns B. Bladder rupture. 2021 Jul 28. In: StatPearls [Internet]. Treasure Island (FL): StatPearls Publishing; 2021 Jan. PMID: 29262195.
5. Martens P. Pseudorenal failure secondary to reversed intraperitoneal autodialysis. *Case Rep Nephrol*. 2013;2013:982391.
6. Gomez RG, Ceballos L, Coburn M, et al. Consensus statement on bladder injuries. *BJU Int*. 2004;94(1):27-32.
7. Qiao P, Tian D, Bao Q. Delayed diagnosis of spontaneous bladder rupture: a rare case report. *BMC Womens Health*. 2018;18(1):124.
8. Heyns CF, Rimington PD. Intraperitoneal rupture of the bladder causing the biochemical features of renal failure. *Br J Urol*. 1987;60(3):217-222.
9. Zhou C, Ying X, Feng W. Pseudo-acute renal failure due to intraperitoneal urine leakage. *Intern Med Tokyo*. 2015;54(14):1777-1780.
10. Arnold WC, Redman JF, Seibert JJ. Analysis of peritoneal fluid in urinary ascites. *South Med J*. 1986;79(5):591-594.
11. Kuroki Y, Mizumasa T, Nagara T, et al. Pseudorenal failure due to intraperitoneal bladder rupture after blunt trauma: usefulness of examining ascitic fluid sediment. *Am J Emerg Med*. 2012;30(7):1326.e1-e3.
12. Hayashi W, Nishino T, Namie S, Obata Y, Furukawa M, Kohno S. Spontaneous bladder rupture diagnosis based on urinary appearance of mesothelial cells: a case report. *J Med Case Reports*. 2014;8(1):46.
13. Udekwo PO, Gurkin B, Oller DW. The use of computed tomography in blunt abdominal injuries. *Am Surg*. 1996;62(1):56-59.
14. Oh SB, Ahn JH. Successful conservative management of a spontaneous intraperitoneal rupture of bladder diverticulum in a critical patient: a case report. A CARE-compliant article. *Medicine*. 2020;99(7):e19262.

How to cite this article: Cheung D, de Terwangne C, Guillen M-A, Sorgente A, Ballout A, Jacques J-M. Pseudo-acute kidney injury after minor trauma: A case report and review of literature. *JACEP Open*. 2021;2:e12564.
<https://doi.org/10.1002/emp2.12564>